

Clinical implications of hypoxia-inducible factor-1 α and caveolin-1 overexpression in isocitrate dehydrogenase-wild type glioblastoma multiforme

WENLI CHEN^{1*}, XING CHENG^{2*}, XIAOBO WANG², JINSHAN WANG¹,
XIAOLING WEN¹, CHAOFAN XIE² and CHUANGXIN LIAO¹

Departments of ¹Neurosurgery and ²Spine Surgery,
The First Affiliated Hospital of Sun Yat-sen University, Guangzhou, Guangdong 510080, P.R. China

Received April 20, 2018; Accepted December 6, 2018

DOI: 10.3892/ol.2019.9929

Abstract. Glioblastoma multiforme (GBM) is the most common type of primary brain tumour in adults, and presents a very low survival rate. Isocitrate dehydrogenase (IDH)1/2 mutations have been found in ~12% of glioblastomas and are associated with long-term GBM survival. However, the risk factors that influence the prognosis of IDH-wild type GBM remain unclear. Hypoxia-inducible factor (HIF)-1 α , an important oxygen-regulated transcription factor, has been demonstrated to serve a crucial role in tumour development and to be associated with a poor prognosis. In addition, caveolin-1 (CAV1) is a plasma membrane organizing protein, the expression of which can also be regulated by a hypoxic microenvironment. The present study therefore aimed to examine the expression levels of HIF-1 α and CAV1, and their association with GBM prognosis. Reverse transcription-quantitative polymerase chain reaction and western blotting were performed to analyse the expression levels of HIF-1 α and CAV1 in paired GBM tumour and adjacent non-tumour tissues. Immunohistochemistry was used to analyse the expression of the two proteins in paraffin-embedded tissues obtained from 42 patients with IDH-wild type GBM. Statistical analyses were performed to examine the correlation between HIF-1 α and CAV1 expression

and patient prognosis. The results revealed that the expression levels of HIF-1 α and CAV1 were upregulated in IDH-wild type GBM tissues compared to their paired non-tumour tissues (P<0.001). The expression of CAV1 was significantly correlated with high HIF-1 α expression (P<0.01). In addition, overexpression of HIF-1 α and CAV1 was markedly associated with a poor prognosis (P<0.001). In conclusion, HIF-1 α and CAV1 may represent potential biomarkers for IDH-wild type GBM prognosis and potential targets for the development of therapies extending GBM survival.

Introduction

Glioblastoma multiforme (GBM) is the most common histological subtype of high-grade glioma and the most prevalent primary brain tumour in adults. The prevalence of GBM is approximately 3-4 cases per 100,000 (1). GBM was previously considered an incurable tumour, with a median survival of ~15 months (2). Isocitrate dehydrogenase (IDH)1/2 mutations have been described in ~12% of patients with GBM and are associated with an improved long-term survival (3). However, the risk factors influencing the prognosis of patients with GBM are still unclear.

GBM is characterized by tissue hypoxia, which is known to mediate expression of the oxygen-regulated transcription factor, hypoxia inducible factor (HIF)-1. It is established that the hypoxic microenvironment of cancer tissue is closely associated with tumour growth and development, and a poor prognosis (4,5). Numerous studies have reported that hypoxia-associated markers, including vascular endothelial growth factor and osteopontin, are correlated with a poor prognosis for patients with GBM (6,7). Kaelin also revealed that the extent of HIF-1 α expression is associated with cancer aggressiveness, resistance to radiation and chemotherapy, and poor prognosis (8). In addition, HIF-1 α has been proposed as a prognostic marker to monitor the development of GBM. It is therefore crucial to understand the expression of HIF-1 α in patients with GBM and to determine its association with patient prognosis.

Caveolin-1 (CAV1) is a plasma membrane organizing protein, the expression of which is increased in various types

Correspondence to: Dr Chaofan Xie, Department of Spine Surgery, The First Affiliated Hospital of Sun Yat-sen University, 183 Huangpu Road, Guangzhou, Guangdong 510080, P.R. China
E-mail: xiechaofan@vip.163.com

Dr Chuangxin Liao, Department of Neurosurgery, The First Affiliated Hospital of Sun Yat-sen University, 183 Huangpu Road, Guangzhou, Guangdong 510080, P.R. China
E-mail: liaocx0206@163.com

*Contributed equally

Key words: hypoxia-inducible factor-1 α , caveolin-1, prognosis, glioblastoma multiforme, IDH

of cancer (9). Previous studies have demonstrated that CAV1 is upregulated by HIF-1 α (10,11), and that HIF-dependent upregulation of CAV1 enhances the oncogenic potential of tumour cells by increasing proliferative, migratory and invasive cell capacities (11). This suggests that there may be an association between CAV1 and HIF *in vitro*. Kannan *et al* reported that CAV1 promotes gastric cancer progression *in vivo* by upregulating epithelial to mesenchymal transition under hypoxic conditions (12). It has also been proposed that hypoxia-induced CAV1 drives tumourigenesis and metastasis in hepatocellular carcinoma (9); however, the expression of CAV1 and HIF-1 α , and their implication in IDH-wild type GBM are still unknown.

The present study aimed to examine the expression levels of HIF-1 α and CAV1 in IDH-wild type tissues from patients with GBM compared to adjacent healthy tissues. In addition, the association between HIF-1 α and CAV1 expression levels and the clinicopathological characteristics of patients with IDH-wild type GBM, including sex, age, weight, methylation of the O6-methylguanine-DNA methyltransferase (MGMT) promoter and prognosis, were assessed.

Materials and methods

Patients and samples. A total of 42 patients diagnosed with IDH-wild type GBM were recruited to the study between June 2012 and June 2014 at the Department of Neurological Surgery, The First Affiliated Hospital of Sun Yat-sen University (Guangzhou, China). Patients were aged 26-76 years, and comprised 17 men and 25 women. Samples were obtained by surgical procedure from patients who had not received chemotherapy or radiotherapy prior to surgical tumour resection. All tumour samples and adjacent samples were obtained from the total resection by microscopy, and tissues were obtained from surgical specimens and immediately snap-frozen in liquid nitrogen until RNA and protein extraction. 42 tumour samples were prepared as archival paraffin blocks. The histopathological diagnosis of the 42 patients was confirmed by pathologists according to the 2016 World Health Organization grading system (malignancy scale) for central nervous system tumours (13).

A total of 17 matched pairs of fresh IDH-wild type GBM and adjacent healthy tissue samples (non-tumour, N-T) from the 42 samples were also obtained to determine mRNA and protein expression levels of HIF-1 α and CAV1. Haematoxylin-eosin staining analysis of frozen sections were used to confirm that the tumour tissues were composed of >70% cancer cells without necrosis, and no cancerous lesions were present in the healthy tissues. The staining protocol was as follows: The sections were stained with Harris's hematoxylin for 7 min, and washed in water for 10 min and following differentiation in 1% acid alcohol for 30 sec, the slides were dipped in lithium carbonate for bluing for 5 min and were stained with eosin for 15 sec. Then dehydrated with 75% alcohol, 95% alcohol and 100% alcohol, 5 min each, cleared in xylene and mounted. All these steps were performed at room temperature. The study was approved by The Medical Ethical Committee of The First Affiliated Hospital of Sun Yat-sen University. Written informed consent was obtained from all patients for use of their clinical specimens.

RNA extraction and reverse transcription-quantitative polymerase chain reaction (RT-qPCR). Total RNA from the IDH-wild type GBM and non-tumour tissue samples was extracted using TRIzol[®] reagent (Invitrogen; Thermo Fisher Scientific, Inc., Waltham, MA, USA) according to the manufacturer's protocol. RNA concentration and quality were assessed spectrophotometrically at 260 and 280 nm. RT-qPCR was performed using an ABI PRISM[®] 7500 Sequence Detection system (Applied Biosystems; Thermo Fisher Scientific, Inc.). Reverse transcription was carried out using the TaKaRa PrimeScript[™] RT reagent Kit with gDNA Eraser (Perfect Real Time) (RR047A, TaKaRa Biotechnology, Inc., Otsu, Japan) according to the manufacturer's protocol. The primer sequences used for the reactions were designed as follows (7): CAV1, forward 5'-TACTGGTTTTACCGCTTGCT-3', reverse 5'-ACGGCTGATGCACTGAATC-3'; HIF-1 α , forward 5'-GTGGATTACCACAGCTGA-3', reverse 5'-GCTCAGTAACTTGATCCA-3'; and 18S, forward 5'-CCTGGA TACCGCAGCTAGGA-3' and reverse 5'-GCGGCGCAATAC GAATGCCCC-3'. According to the qPCR kit (SYBR[®] Premix Ex Taq[™], RR430A, TaKaRa Biotechnology, Inc.) according to the manufacturer's protocol, the qPCR protocol used was as follows: Denaturation at 95°C for 5 min, followed by 40 cycles of denaturation at 95°C for 15 sec and annealing for 32 sec at 60°C. The housekeeping gene 18S was used as the reference gene, and the 2^{- $\Delta\Delta C_q$} method was used to analysis the CAV1 and HIF-1 α Expression. Expression data were normalized to the geometric mean of the housekeeping gene 18S (14).

Western blotting. A total of 17 matched pairs of cancerous tissues and healthy tissues were homogenized in 50 mM Tris (pH 7.5), 100 mM NaCl, 1 mM EDTA, 0.5% NP40, 0.5% Triton X-100, 2.5 mM sodium orthovanadate, 10 μ M protease inhibitor cocktail, and 1 mM phenylmethylsulfonyl fluoride. Protein determination was performed using a Pierce[™] BCA Protein assay kit (Thermo Fisher Scientific Inc.) to quantify the total protein following extraction, and 20 μ g protein were loaded per lane and electrophoretically separated on a 9% SDS polyacrylamide gel and transferred to polyvinylidene fluoride membranes (EMD Millipore, Billerica, MA, USA). The membranes were blocked with 10% BSA (Thermo Fisher Scientific, Inc.) in PBST, at room temperature for 1 h, then were incubated at 4°C overnight with anti-human HIF-1 α rabbit monoclonal antibody (cat no. GTX127309, 1:1,000; GeneTex Inc., Irvine, CA, USA) and CAV1 rabbit monoclonal antibody (cat no. ab192869, 1:1,000; Abcam, Cambridge, USA). HIF-1 α and CAV1 expressions levels were detected with horseradish peroxidase (HRP)-conjugated goat anti-rabbit immunoglobulin G secondary antibody following incubation at room temperature for 1 h (cat no. 4050-05; 1:5,000; SouthernBiotech, Birmingham, AL, USA). Anti-GAPDH mouse monoclonal antibody (cat no. 2118; 1:10,000; Cell Signaling Technology, Inc., Danvers, MA, USA) was used as a loading control. Protein bands were eventually visualized with an automatic chemiluminescence imaging method and the results were analyzed by imaging analysis software (Version 5200, Tanon Science and Technology Co., Ltd., Shanghai, China).

Immunohistochemistry. Immunohistochemical staining was carried out on formalin-fixed, paraffin-embedded sections

(4 μ m) deparaffinized in xylene at room temperature for 10 min twice, rehydrated in an ethanol series (absolute alcohol for 5 min twice, 95% alcohol for 2 min and 70% alcohol for 2 min) at room temperature and rinsed in PBS. Antigen retrieval was then performed in a microwave with 10 mM citrate buffer for 10 min (pH 6.0). Immunohistochemical staining was carried out using the EnVision™ kit (Dako; Agilent Technologies, Inc., Santa Clara, CA, USA) according to the manufacturer's protocol. Endogenous peroxidase activity was quenched by treatment with 3% hydrogen peroxide at room temperature for 15 min. The sections were then incubated with primary anti-rabbit antibody against HIF-1 α (cat no. GTX127309; 1:500; GeneTex Inc.) and CAV1 (cat no. ab192869; 1:500; Abcam) overnight at 4°C. Subsequently, the tissue sections were sequentially incubated with ready-to-use HRP immunoglobulin (EnVision kit) at room temperature for 30 min and developed with 3,3-diaminobenzidine as a chromogen substrate. The nuclei were eventually counterstained with Meyer's haematoxylin at room temperature for 2-5 min. Images were captured using an inverted microscope (x40 and x400 magnification) (Nikon eclipse E100).

The levels of HIF-1 α and CAV1 immunostaining were evaluated independently by two pathologists who did not know the survival outcomes of the participants. Positive CAV1 protein expression was defined as a diffuse brown staining in the cell membrane, whereas positive HIF-1 α immunoreactivity was observed in the cell nuclei.

The immunostaining levels were evaluated by immunoreactive score (IRS). Staining intensity was scored as follows: No staining at all (score 0), faint staining (score 1), moderate staining (score 2) and strong staining (score 3). The protein distribution was defined as the percentage accounting for the whole area in the section: 0% (score 0), 1-25% (score 1), 26-50% (score 2), 51-75% (score 3) and 76-100% (score 4). Total scores were calculated by combining the staining intensity evaluation and the staining distribution. The scores were independently evaluated by two researchers who had to reach an agreement. If divergences appeared, a third researcher participated in the evaluation to obtain the final score.

The median value of CAV1 IRS for all samples was 4. The CAV1 protein expression levels were therefore further analysed and IRS values were classified as low (IRS value <4) or high (IRS value \geq 4). The median value of HIF-1 α IRS for all samples was 5. The HIF-1 α protein expression levels were likewise further analysed, and IRS values were categorized as low (IRS value <5) and high (IRS value \geq 5).

Statistical analysis. Statistical calculations were performed using SPSS 20.0 (IBM Corp., Armonk, NY, USA) and GraphPad Prism v5.0 (GraphPad Software, Inc., La Jolla, CA, USA). Data were expressed as the mean \pm standard error of the mean. Differences in CAV1 and HIF-1 α expression between the two groups were compared by paired t-test. The protein and mRNA levels of CAV1 and HIF-1 α in the tissues of patients with GBM were categorized as low expression or high expression, according to their mean value. A χ^2 test was applied to determine the association between CAV1 expression and the clinicopathological parameters of GBM. The Kaplan-Meier method and log-rank test were used to evaluate and compare the prognosis of patients with GBM. The HIF-1 α IRS of each

tissue was compared with CAV1 IRS using Spearman's correlation coefficients (r) and curve-estimation analysis. $P < 0.05$ was considered to indicate a statistically significant difference.

Results

HIF-1 α and CAV1 are overexpressed in IDH-wild type GBM. In the present study, RT-qPCR and western blotting were performed to determine the mRNA and protein expression levels, respectively, of HIF-1 α and CAV1 in non-tumour and IDH-wild type GBM (Fig. 1). The data revealed that HIF-1 α and CAV1 expression levels were significantly higher in cancerous tissues than in non-tumour tissues.

Upregulation of CAV1 is highly correlated with HIF-1 α expression. To further understand the cellular localization of the CAV1 and HIF-1 α proteins, immunohistochemistry was performed on tissues. The immunohistochemical staining patterns of HIF-1 α and CAV1 in the 42 patients indicated that HIF-1 α was mainly localized in the nucleus of the tumour cells, whereas CAV1 was located in the cell membrane or cytoplasm of the tumour cells. The representative images of immunohistochemical staining are presented in Fig. 2A-H. According to statistical analysis, the expression levels of HIF-1 α and CAV1 protein in GBM tissues were significantly higher ($P < 0.001$) than in non-tumour tissues. In addition, the association between HIF-1 α and CAV1 expression was assessed by nonparametric Spearman's rank test and logistic regression analysis (Fig. 2J). The results demonstrated that the upregulation of CAV1 was positively correlated with HIF-1 α expression ($P < 0.01$; $r = 0.765$).

High levels of HIF-1 α and CAV1 are associated with poor prognosis for patients with IDH-wild type GBM. The association between HIF-1 α and CAV1 expression and the survival time of patients with GBM was further analysed, high HIF-1 α or CAV1 expression associated with larger size and worse prognosis (Table I). The results revealed that patients with IDH-wild type GBM and high HIF-1 α or CAV1 expression had a poorer prognosis compared to patients with low levels of HIF-1 α or CAV1. In addition, patients with higher expression of HIF-1 α and CAV1 had the poorest prognosis (Fig. 3).

Discussion

CAV1, an integral structural component of caveolae, is a direct target of HIF-1. Numerous studies have recently demonstrated that hypoxia-associated biological markers can be used as predictors of treatment, metastasis and prognosis in various types of cancer, including breast, lung and colorectal cancer (15-17). The present study revealed that HIF-1 α and CAV1 were significantly upregulated in patients with IDH-wild type GBM. In addition, the overexpression of HIF-1 α and CAV1 was markedly associated with poor survival rates in GBM. These results suggested that HIF-1 α and CAV1 may be potential markers for treatment and prognosis in IDH-wild type GBM.

At present, the markers available to predict prognosis of IDH-wild type GBM patients are insufficient. Patients with IDH-wild type GBM usually have low survival rates. Although

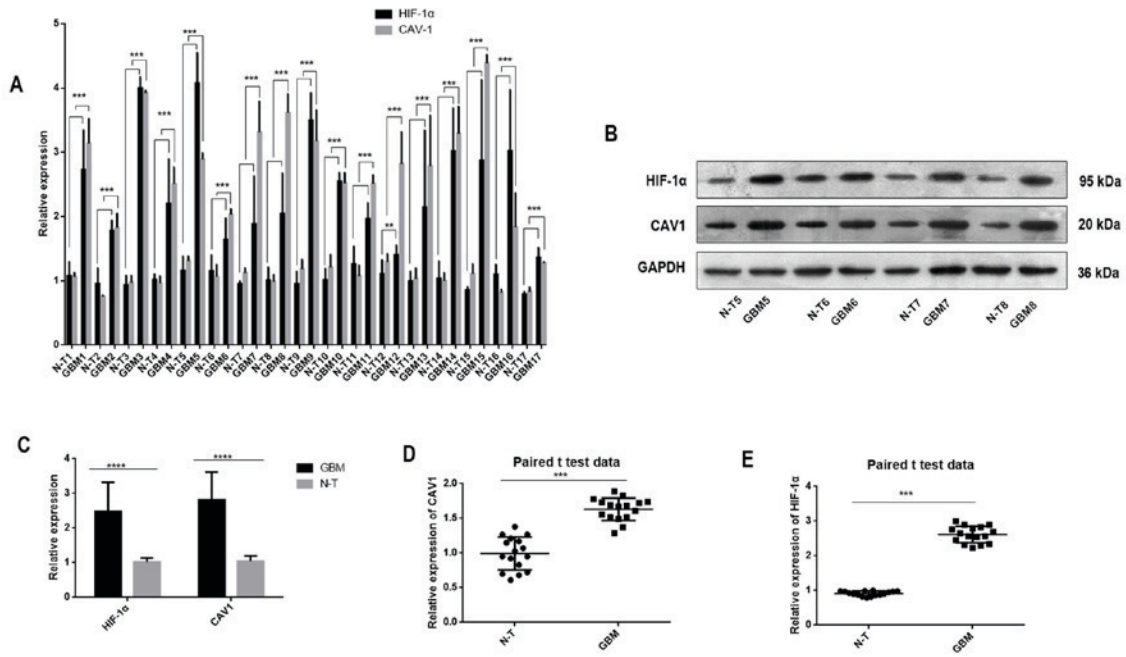


Figure 1. (A) Graphical representation of the mean data of relative density of CAV1 or HIF-1 α protein to GAPDH in all 17 paired samples. CAV1 or HIF-1 α expression was significantly different in each GBM tissue compare with the matched non-tumour tissue by Paired t-test analysis. (B) Western blotting of CAV1 and HIF-1 α protein levels in four paired GBM and adjacent N-T samples (other 13 pairs were not shown). (C) Protein expression levels of CAV1 and HIF-1 α were higher in a total of 17 GBM tissues than in the matched non-tumour tissues after analysis by paired t-test. (D and E) mRNA expression levels of CAV1 and HIF-1 α in a total of 17 GBM tissues and their matched non-tumour tissues were measured by reverse transcription-quantitative polymerase chain reaction. The mRNA expression levels of CAV1 and HIF-1 α were higher in the GBM tissues than in the matched non-tumour tissues after analysis by paired t-test. **P<0.05, ***P<0.01 ****P<0.001. CAV1, caveolin-1; GBM, glioblastoma multiforme; HIF-1 α , hypoxia-inducible factor-1 α ; N-T, non-tumour.

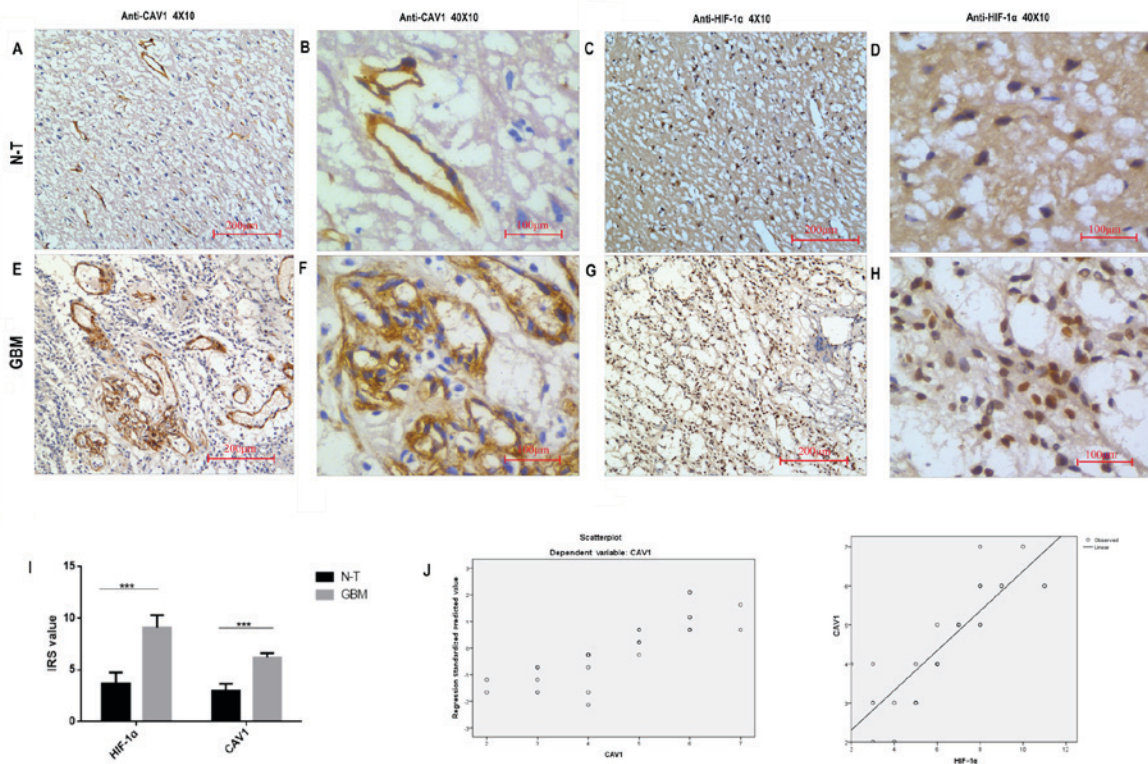


Figure 2. Expression of CAV1 and HIF-1 α in the N-T and GBM tissues, as determined by immunohistochemistry. (A and B) Positive CAV1 protein expression was represented by weak brown staining in the cell membrane in the N-T tissue. (E) Intense immunostaining of CAV1 was observed in the cell membrane in GBM tissues, and (F) nuclear and cytoplasmic immunoreactivity was observed in the GBM tissues at a higher magnification. (G and H) HIF-1 α immunoreactivity was strong in the cell nuclei in the GBM tissues, and (C and D) a few positive HIF-1 α immunoreactive cell nuclei were observed in the matched N-T tissues. (I) Expression levels of HIF-1 α and CAV1 in GBM tissues were significantly higher than in N-T tissue. ***P<0.001. (J) Positive correlations between the immunoreactive score of CAV1 and HIF-1 α by curve-estimation analysis. CAV1 expression in the tumour tissues exhibited a significant positive correlation with HIF-1 α expression ($r=0.765$, $P<0.01$). CAV1, caveolin-1; GBM, glioblastoma multiforme; HIF-1 α , hypoxia-inducible factor-1 α ; N-T, non-tumour.

Table I. Clinicopathological parameters of 42 patients with IDH-wild type GBM.

Variable	Number	CAV1			HIF-1 α		
		Low expression	High expression	P-value	Low expression	High expression	P-value
Age							
<60 years	19	9	10	0.954	11	8	0.358
\geq 60 years	23	12	11		9	14	
Sex							
Male	17	7	10	0.236	8	9	0.764
Female	25	14	11		12	13	
KPS							
\leq 70	28	16	12	0.286	15	13	0.395
<70	14	6	8		5	9	
Size							
<5 cm	19	12	7	<0.0001 ^a	15	4	0.213
\geq 5 cm	23	8	15		5	18	
MGMT							
Positive	26	12	14	0.392	11	15	0.315
Negative	16	10	6		9	7	
Survival							
<13 m	20	6	14	0.029 ^a	7	13	0.013 ^a
\geq 13 m	22	16	6		13	9	

Patients at risk at 13-months survival are indicated. CAV10 mRNA levels and HIF-1 α mRNA levels were defined as high or low. Multivariate analyses were stratified for this variable. CAV1 and HIF-1 α were introduced to the base model that included the factors age, sex, KPS, tumour size, MGMT and survival as transformed continuous variables. χ^2 test was applied to determine the association between CAV1 or HIF-1 α expression and the clinicopathological parameters of GBM. Patients with GBM and high HIF-1 α or CAV1 expression had a worse prognosis when compared with those with low levels of HIF-1 α or CAV1 (^aP<0.05). CAV1, caveolin-1; GBM, glioblastoma multiforme; HIF-1 α , hypoxia-inducible factor-1 α ; KPS, Karnofsky performance score; m, month; MGMT, O⁶-methylguanine-DNA methyltransferase.

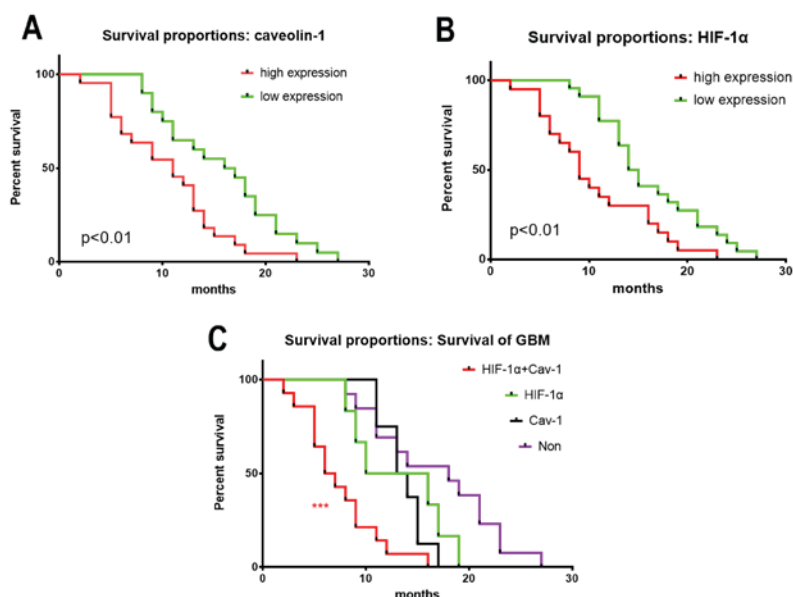


Figure 3. Kaplan-Meier survival curves of patients with high or low expression of (A) CAV1, (B) HIF-1 α and (C) CAV1 + HIF-1 α (Non=low expression of HIF-1 α and CAV1). A total of 42 patients with IDH-wild type GBM were studied. The survival time in patients with low HIF-1 α expression was significantly longer than that in patients with high HIF-1 α expression. The survival time in patients with low CAV1 expression was significantly longer than that in patients with high HIF-1 α expression. In addition, patients with high expression of HIF-1 α and CAV1 had a worse prognosis than patients with low expression of HIF-1 α or CAV1. ***P<0.001. CAV1, caveolin-1; GBM, glioblastoma multiforme; HIF-1 α , hypoxia-inducible factor-1 α ; IRS, immunoreactive score; N-T, non-tumour.

hypoxia is usually present in the tumour environment, it represents an uncertain prognostic marker in various types of cancer. It has been described that HIF-1 α , an important transcription factor, regulates numerous biological functions and activates critical genes involved in angiogenesis, migration, invasion and metastasis (18,19). Cai *et al* (20) reported that HIF-1 α is a biomarker useful for the identification of subgroups of patients with a poor prognosis, and for the early detection of subclinical metastasis. As previously mentioned, hypoxia is a critical feature of the glioma microenvironment and is associated with a poor prognosis and resistance to most therapies (21); however, only a few studies have investigated the expression of HIF-1 α in GBM. Further investigations are therefore required to understand the role of HIF-1 α expression in GBM. In the present study, HIF-1 α expression was upregulated in GBM tissues at the mRNA and protein levels, compared to adjacent healthy tissues, which confirmed previous findings. In addition, the overexpression of HIF-1 α in GBM was significantly associated with poor prognosis.

The role of HIF-1 α in cancer pathogenesis and prognosis is complex. A recent study reported that hypoxia regulates membrane protein endocytosis through CAV1 in cancer cells (21). CAV1 has also been implicated in tumour development and described as a negative regulator of endocytosis (22,23). It has been demonstrated that the lipid raft-associated CAV1 negatively regulates the uptake of exosomes derived from GBM cells via extracellular signal-regulated kinases 1/2-heat shock protein 27 signalling (24). The present study detected higher CAV1 expression in GBM tissues compared to healthy tissues. This result was similar to previous findings. Bourseau-Guilmain *et al* (21) observed significantly enhanced expression of CAV1 in hypoxic regions of tumours from patients with GBM. To further analyse the association between HIF-1 α and CAV1 expression, the present study confirmed that there was a significant correlation between both proteins. In addition, CAV1 was positively associated with poor prognosis for patients with GBM. Therefore, high expression levels of HIF-1 α and CAV1 may be associated with shorter survival rate; however, the underlying molecular mechanisms of action of HIF-1 α and CAV1 in GBM require further investigation.

In conclusion, the present study investigated HIF-1 α and CAV1 expression in IDH-wild type GBM and healthy tissues. High expression levels of HIF-1 α and CAV1 in patients with IDH-wild type GBM were demonstrated. Furthermore, poor patient prognosis was associated with high expression levels of HIF-1 α and CAV1. These findings suggested that HIF-1 α and CAV1 expression levels may aid in the identification of patients with a poor prognosis that require more aggressive treatment.

Acknowledgements

Not applicable.

Funding

The present study was supported by a grant from The Technology Project of Huangpu District Guangzhou City (grant no. 201611).

Availability of data and materials

The datasets used and/or analyzed during the present study are available from the corresponding author on reasonable request.

Authors' contributions

WLC, XC and XBW performed the staining and western blotting. JSW, XLW and CFX performed the data analysis. CFX oversaw the study, and CXL conceived the study and made substantial intellectual contributions. CFX and CXL designed this article, helped to analyse the data and revised the final manuscript. All authors read and approved the final manuscript.

Ethics approval and consent to participate

The study was approved by The Medical Ethics Committee of The First Affiliated Hospital of Sun Yat-sen University. Written informed consent was obtained from all patients for use of their tissues.

Patient consent for publication

Not applicable.

Competing interests

The authors declare that they have no competing interests.

References

1. Kaya V, Yıldırım M, Yazıcı G, Yalçın AY, Orhan N and Güzel A: Prognostic significance of indicators of systemic inflammatory responses in glioblastoma multiforme patients. *Asian Pac J Cancer Prev* 18: 3287-3291, 2017.
2. Koshy M, Villano JL, Dolecek TA, Howard A, Mahmood U, Chmura SJ, Weichselbaum RR and McCarthy BJ: Improved survival time trends for glioblastoma multiforme using the SEER 17 population-based registries. *J Neurooncol* 107: 207-212, 2012.
3. Waitkus M, Diplas B and Yan H: Isocitrate dehydrogenase mutations in gliomas. *Neuro Oncol* 18: 16-26, 2016.
4. Jun JC, Rathore A, Younas H, Gilkes D and Polotsky VY: Hypoxia-inducible factors and cancer. *Curr Sleep Med Rep* 3: 1-10, 2017.
5. Qin J, Liu Y, Lu Y, Liu M, Li M, Li J and Wu L: Hypoxia-inducible factor 1 alpha promotes cancer stem cells-like properties in human ovarian cancer cells by upregulating SIRT1 expression. *Sci Rep* 7: 10592, 2017.
6. Said HM, Hagemann C, Staab A, Stojic J, Kühnel S, Vince GH, Flentje M, Roosen K and Vordermark D: Expression patterns of the hypoxia-related genes osteopontin, CA9, erythropoietin, VEGF and HIF-1alpha in human glioma in vitro and in vivo. *Radiother Oncol* 83: 398-405, 2007.
7. Agrawal R, Pandey P, Jha P, Dwivedi V, Sarkar C and Kulshreshtha R: Hypoxic signature of microRNAs in glioblastoma: Insights from small RNA deep sequencing. *BMC Genomics* 15: 686, 2014.
8. Kaelin WG Jr: Molecular basis of the VHL hereditary cancer syndrome. *Nat Rev Cancer* 2: 673-682, 2002.
9. Mao X, Wong SY, Tse EY, Ko FC, Tey SK, Yeung YS, Man K, Lo RC, Ng IO and Yam JW: Mechanisms through which hypoxia-induced caveolin-1 drives tumorigenesis and metastasis in hepatocellular carcinoma. *Cancer Res* 76: 7242-7253, 2016.
10. Goetz JG, Minguet S, Navarro-Lérida I, Lazcano JJ, Samaniego R, Calvo E, Tello M, Osteso-Ibáñez T, Pellinen T, Echarrí A, *et al*: Biomechanical remodeling of the microenvironment by stromal caveolin-1 favors tumor invasion and metastasis. *Cell* 146: 148-163, 2011.

11. Wang Y, Roche O, Xu C, Moriyama EH, Heir P, Chung J, Roos FC, Chen Y, Finak G, Milosevic M, *et al*: Hypoxia promotes ligand-independent EGF receptor signaling via hypoxia-inducible factor-mediated upregulation of caveolin-1. *Proc Natl Acad Sci USA* 109: 4892-4897, 2012.
12. Kannan A, Krishnan A, Ali M, Subramaniam S, Halagowder D and Sivasithamparam ND: Caveolin-1 promotes gastric cancer progression by up-regulating epithelial to mesenchymal transition by crosstalk of signalling mechanisms under hypoxic condition. *Eur J Cancer* 50: 204-15, 2014.
13. Hoshida R and Jandial R: 2016 world health organization classification of central nervous system tumors: An Era of molecular biology. *World Neurosurg* 94: 561-562, 2016.
14. Livak KJ and Schmittgen TD: Analysis of relative gene expression data using real-time quantitative PCR and the 2(-Delta Delta C(T)) method. *Methods* 25: 402-408, 2001.
15. Milani M, Venturini S, Bonardi S, Allevi G, Strina C, Cappelletti MR, Corona SP, Aguggini S, Bottini A, Berruti A, *et al*: Hypoxia-related biological markers as predictors of epirubicin-based treatment responsiveness and resistance in locally advanced breast cancer. *Oncotarget* 8: 78870-78881, 2017.
16. Khan MN, Haggag YA, Lane ME, McCarron PA and Tambuwala MM: Polymeric nano-encapsulation of curcumin enhances its anti-cancer activity in breast (MDA-MB231) and lung (A549) cancer cells through reduction in expression of HIF-1 α and nuclear p65 (Rel A). *Curr Drug Deliv* 15: 286-295, 2018.
17. Li W, Zong S, Shi Q, Li H, Xu J and Hou F: Hypoxia-induced vasculogenic mimicry formation in human colorectal cancer cells: Involvement of HIF-1 α , claudin-4, and E-cadherin and vimentin. *Sci Rep* 6: 37534, 2016.
18. Cavallo F, De Giovanni C, Nanni P, Forni G and Lollini PL: 2011: The immune hallmarks of cancer. *Cancer Immunol Immunother* 60: 319-26, 2011.
19. Hanahan D and Weinberg RA: Hallmarks of cancer: The next generation. *Cell* 144: 646-674, 2011.
20. Cai FF, Xu C, Pan X, Cai L, Lin XY, Chen S and Biskup E: Prognostic value of plasma levels of HIF-1 α and PGC-1 α in breast cancer. *Oncotarget* 7: 77793-77806, 2016.
21. Bourseau-Guilmain E, Menard JA, Lindqvist E, Indira Chandran V, Christianson HC, Cerezo Magaña M, Lidfeldt J, Marko-Varga G, Welinder C and Belting M: Hypoxia regulates global membrane protein endocytosis through caveolin-1 in cancer cells. *Nat Commun* 7: 11371, 2016.
22. Le PU, Guay G, Altschuler Y and Nabi IR: Caveolin-1 is a negative regulator of caveolae-mediated endocytosis to the endoplasmic reticulum. *J Biol Chem* 277: 3371-3379, 2002.
23. Shvets E, Ludwig A and Nichols BJ: News from the caves: Update on the structure and function of caveolae. *Curr Opin Cell Biol* 29: 99-106, 2014.
24. Svensson KJ, Christianson HC, Wittrup A, Bourseau-Guilmain E, Lindqvist E, Svensson LM, Mörgelin M and Belting M: Exosome uptake depends on ERK1/2-heat shock protein 27 signaling and lipid Raft-mediated endocytosis negatively regulated by caveolin-1. *J Biol Chem* 288: 17713-17724, 2013.



This work is licensed under a Creative Commons Attribution-NonCommercial-NoDerivatives 4.0 International (CC BY-NC-ND 4.0) License.