

## ORIGINAL RESEARCH

# Hot saline irrigation in comparison to nasal packing after sinus surgery

Axel Nordström MSc<sup>1</sup>  | Mattias Jangard MD, PhD<sup>2</sup> | Marie Svedberg PhD<sup>1</sup> |  
Helena Kullenberg RN, MSc<sup>1</sup> | Michael Ryott MD, PhD<sup>2</sup> | Maria Kumlin PhD<sup>1</sup>

<sup>1</sup>Department of Health Promotion Science, Sophiahemmet University, Stockholm, Sweden

<sup>2</sup>Department of Otorhinolaryngology, Sophiahemmet Hospital, Stockholm, Sweden

**Correspondence**

Maria Kumlin, PhD, Department of Health Promotion Science, Sophiahemmet University, P.O. Box 5605, SE-114 86 Stockholm, Sweden.  
Email: maria.kumlin@shh.se

**Funding information**

Sophiahemmet Research foundation

**Abstract**

**Objectives:** Previous studies have shown that hot saline solution (HSS) nasal irrigation is effective against nasal bleeding and is used to treat nasal hemorrhage. In a pilot study, we evaluated hot saline nasal irrigation in comparison to a routinely used nasal packing in terms of self-reported complications and mucosal healing after functional endoscopic sinus surgery.

**Methods:** Patients undergoing surgery for bilateral chronic rhinosinusitis received polyvinyl acetate (PVA) nasal packing in the left nostril, and the right nostril was rinsed with 47°C sterile saline immediately after surgery. Patients' experiences of pain, bleeding, and other types of uncomfortable experiences were measured using a visual analog scale for each nostril before, during, and immediately after nasal packing removal. Two weeks post-surgery, the assessments were repeated including an endoscopic evaluation of the mucosa by the surgeon.

**Results:** Twenty-seven patients completed the study. Prior to removal of the packing, the patients experienced significantly more pain and other uncomfortable experiences in the nostril treated with nasal packing, as compared to the nostril solely rinsed with hot saline. After removal, patients reported significantly more uncomfortable experiences from the packing treated nostril. Two weeks post-surgery, no difference in mucosal healing was observed between the two nostrils.

**Conclusions:** The results from this study indicate that irrigation with HSS could be an alternative postoperative treatment to conventional PVA nasal packing. Hot saline irrigation may contribute to patients experiencing improved control of postoperative bleeding, pain, and less suffering of other causes as well as health-economic benefits, without affecting the mucosal healing up to 2 weeks post-surgery.

**Level of Evidence:** 1b

**KEYWORDS**

chronic rhinosinusitis, endoscopic sinus surgery, hot saline, nonabsorbable packing, postoperative complications

This is an open access article under the terms of the Creative Commons Attribution-NonCommercial-NoDerivs License, which permits use and distribution in any medium, provided the original work is properly cited, the use is non-commercial and no modifications or adaptations are made.

© 2021 The Authors. *Laryngoscope Investigative Otolaryngology* published by Wiley Periodicals LLC on behalf of The Triological Society.

## 1 | INTRODUCTION

Chronic rhinosinusitis (CRS) is a common inflammatory condition that affects 3%-10.9% in Europe<sup>1,2</sup> which heavily impacts the quality of life (QoL).<sup>3,4</sup> The disease is characterized by prolonged and recurring inflammation of the paranasal sinuses, and functional endoscopic sinus surgery (FESS) is routinely employed in cases of ineffective medical therapy. CRS with nasal polyps (CRSwNP) commonly requires several surgical interventions that may further impose anxiety and stress on the patient. After sinus surgery, nasal packing is routinely inserted into the nasal cavity to reduce postoperative complications such as bleeding and synechiae formation.<sup>5</sup> The occurrence of such complications has previously been associated with lowered QoL among CRS patients. However, nasal packing has been frequently reported as painful and uncomfortable as it causes nasal obstruction, sinus pressure, and nasal discharge.<sup>6-8</sup> Bleeding and anxiety are associated with the removal of the packing<sup>9</sup> which is commonly described as the worst step in the surgical procedure.<sup>10</sup>

To minimize the unpleasantness of nasal packing removal, new innovative nasal packing materials have been introduced with absorbable or biodegradable capabilities designed to dissolve by themselves. Studies evaluating absorbable packings have shown beneficial effects in terms of mucosal healing,<sup>11</sup> reduced synechiae formation, nasal discharge, and improved ostiomeatal complex patency when compared to no packing.<sup>12</sup> A meta-analysis reported that absorbable packing was favorable in terms of comfortability and reduced synechiae formation when compared to nonabsorbable and no packing methods, and postoperative bleeding was lower than nonabsorbable packing usage.<sup>13</sup>

However, the benefits of absorbable packings are currently under debate. Hence, several studies are unable to provide conclusive evidence regarding postoperative outcome differences between absorbable, nonabsorbable, and no-packing methods.<sup>14-17</sup> No packing was advantageous in terms of expected QoL related to the extent of experienced postoperative complications, and that packing was not preferable to prevent synechiae formation.<sup>18</sup> In addition, the study also indicated that no-packing methods were more cost-effective and beneficial effects of absorbable packing could only be observed when compared to other nasal packing materials. Nasal packing as a routine for postsurgical treatment has been previously criticized,<sup>19,20</sup> and some studies may even suggest that absorbable packing has negative impact on wound healing.<sup>16,21</sup> Furthermore, absorbable packing materials do not always fully dissolve; thus, the pain-related step of packing removal may still be required in some cases.

Historically, excessive nasal bleeding has been treated with hot water, and a study by Stangerup et al. demonstrated that hot water irrigation had a higher success rate than nasal packing, treating posterior epistaxis.<sup>22</sup> Similarly, hot saline solution (HSS) irrigation is effective in controlling intraoperative nasal bleeding,<sup>23</sup> causing less pain, reducing trauma to the mucosa, and shortening the hospital stay.<sup>24</sup> Irrigation with HSS may therefore be an advantageous alternative to nasal packing as a postoperative treatment, with the possibility to reduce pain and unpleasantness for the patients and to minimize the

cost. The nonabsorbable packing, polyvinyl acetate (PVA), is currently part of the standard care after surgery in Sweden. Thus, the aim of the current pilot study was to evaluate the HSS irrigation method compared to the routinely used PVA nasal packing, in terms of patient-reported complications as well as endoscopic evaluation after FESS in patients with CRS.

## 2 | MATERIALS AND METHODS

### 2.1 | Study design and objectives

A prospective study with intraindividual comparison was conducted applying PVA nasal packing in one nostril and irrigation with HSS in the other nostril as postoperative treatment after bilateral FESS. The primary objective was to compare subjective experiences of postoperative events as bleeding, pain, and other inconveniences between the two treatments, before and after removal of the PVA as well as 2 weeks post-surgery. Secondary objectives were to evaluate the participants' subjective experience of the removal of the PVA and to compare the surgeon's visual evaluation of the nasal cavities 2 weeks after FESS.

### 2.2 | Participants

Patients undergoing FESS for bilateral CRS, CRSwNP, or without nasal polyps (CRSsNP) were consequently recruited at the Ear, Nose, and Throat Clinic at Sophiahemmet Hospital located in Stockholm, Sweden. CRS diagnosis was based on clinical symptoms, nasal endoscopic assessment, and computed tomographic (CT) scanning according to European Position Paper on Rhinosinusitis and Nasal Polyps.<sup>25</sup> The inclusion criteria were bilateral disease, age over 18, and ability to understand Swedish. Bilateral disease was ensured with endoscopic assessment and CT scans. Exclusion criteria were history of abnormal blood coagulation, previous excessive perioperative epistaxis, and treatment with anticoagulants. Patients with only frontal sinus or sphenoid sinus pathology were not included in this study. In total, 38 patients were consecutively recruited and enrolled after giving informed written consent. The study is approved by the Swedish Regional Ethical Review Board Dnr: 2016/945-31/1. Participation was voluntary, and all participants gave written informed consent.

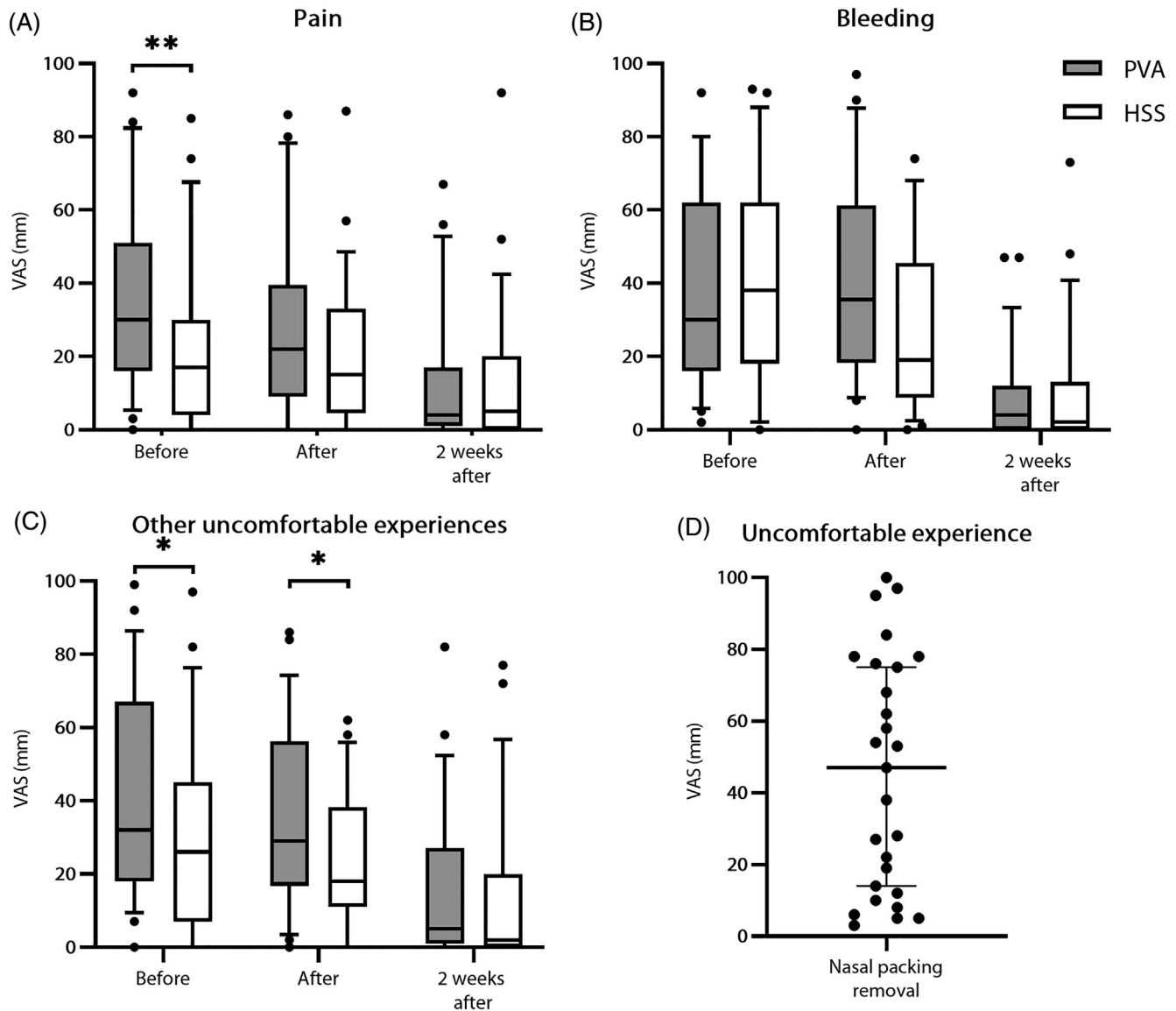
### 2.3 | Surgical procedure and postoperative treatment

All surgeries were performed by the same two surgeons, at the clinic, with similar surgical methods under general anesthesia. As PVA nasal packing is the standard care and treatment procedure in Sweden, our study focused to have such packing as comparator to the HSS irrigation. FESS in our study included middle meatal antrostomy and total

ethmoidectomy (both anterior and posterior) as well as Draf I procedure and a bilateral sphenotomy. Preoperatively, we used lidocaine-naphazoline spray and cocaine hydrochlorine gauze strips placed in the medial meatal area. Messerklinger technique with a micro-bridger was employed, and intraoperative bleeding was controlled with a monopolar suction coagulation electrode or electrocauterization with a

bipolar forceps. None of the participants were treated with oral corticosteroids preoperatively.

Immediately after surgery, all patients were equally treated; PVA nasal packing (8 cm, Meroce) was inserted in the left nostril and the right nostril was rinsed with 200 ml 47°C sterile saline solution. The irrigation method employed in our study was based



**FIGURE 1** Postoperative complications assessed with VAS. Pain (A), bleeding (B), and other uncomfortable experiences (C) were measured before (N = 27) and after nasal packing removal (N = 25-26), and 2 weeks post-surgery (N = 27), comparing PVA nasal packing and HSS irrigation in separate nostrils. Uncomfortable experiences assessed with VAS were measured during (N = 27) nasal packing removal (D). Data are presented as median with IQR. HSS, Hot saline solution; PVA, polyvinyl acetate; VAS, visual analog scale. Significance levels are considered at \*P < .05; \*\*P < .01

**TABLE 1** Proportion of patients experiencing the HSS or PVA as the least unpleasant postoperative treatment, as assessed before nasal packing removal and 2 weeks post-surgery

	Total N	HSS	PVA	No difference
Before nasal packing removal, N (%)	27	21 (78)	4 (15)	2 (7)
Two weeks post-surgery, N (%)	22	13 (59)	9 (41)	0 (0)

Abbreviations: HSS, Hot saline solution; PVA, polyvinyl acetate.

**TABLE 2** Patients' described experiences of discomfort before nasal packing removal and 2 weeks post-FESS

Described discomforts	Before nasal packing removal (no. of comments)			Two weeks post-surgery (no. of comments)		
	PVA	HSS	NS	PVA	HSS	NS
Bleeding						
Bleeding	2	2	6	1		2
Secretions						
Rhinorrhea	2		2	2		
Crusts				1	1	1
General discomforts						
Uncomfortable	1					
Severe discomfort	1					
Sensory discomforts						
Pain	2		2	3		2
Tingling	1		1			
Tickling	2					
Sting			2			2
Sinus pressure	2		3	1		1
Dryness						3
Congestion						
Nasal congestion	2	1	3	2	1	2
Breathing difficulties	2		3			
General symptoms						
Headache			2			1
Fever			1			
Sneezing			3			
Vertigo			1			
Problematic nasal rinsing				1		1
No olfaction improvement						1
Signs of infection						2
No problems	1				1	1
Total	18	3	29	11	3	19

Note: Comments of discomfort were shortened into common denominators and then quantified.

Abbreviations: HSS, Hot saline solution; NS, not specified; PVA, polyvinyl acetate.

on studies by Stangerup et al., showing that a temperature of 47°C saline solution dampens hemorrhage without causing damage and necrosis to the mucosa.<sup>22,26</sup> The patients returned home the same day of the surgery and were instructed to remove the PVA the following day by pulling a string attached to the PVA. Postoperatively, all patients were instructed to irrigate the nasal cavities with 100 ml room tempered saline in each nostril two times daily until the follow-up 2 weeks after surgery. They were also instructed to use nasal corticosteroid spray two times daily starting from the day after surgery.

## 2.4 | Outcome measures

Questionnaires with visual analog scale (VASs) were used to assess the patients' experiences of pain, bleeding, and other types of

uncomfortable experiences from each nostril. VAS data were processed as a number between 0 and 100<sup>27</sup> and was retrieved before, during, and after removal of the PVA as well as at the time for the revisit to the clinic after 2 weeks.

The included patients were asked to report which treatment was regarded as least unpleasant, in a questionnaire. Patients were given the opportunity to give short free-text comments about uncomfortable experiences before, during, and 2 weeks after the removal of the PVA. The comments were compiled and shortened to common denominators, and then quantified, similar to qualitative content analysis<sup>28</sup> with a descriptive approach. The purpose to gather such free-text comments was to explore patients' experiences of the packing and HSS rinsed nostril, respectively. At the 2-week revisit, the surgeons endoscopically evaluated the outcomes of the postoperative treatments in each nasal cavity, in terms of bleeding and mucosal healing.

## 2.5 | Statistical analysis

VAS scores from each nostril were analyzed with Wilcoxon signed rank test as normality of data could not be assumed. To conduct statistical analysis and create graphical presentation, GraphPad Prism (V8.4.2) was utilized. VAS data were presented as percentage and median with interquartile range (IQRs). Significant difference was considered at  $P < .05$ .

## 3 | RESULTS

In the current study, postoperative complications were assessed in 27 out of 38 treated patients with HSS irrigation and PVA nasal packing in separate nostrils. Eleven patients did not fully complete the study; eight did not return the questionnaire, and three canceled their 2-week revisit. The study population consisted of 17 CRSwNP cases and 10 CRSsNP cases, with a distribution of 21 males and 6 females. Patients' age ranged between 23 and 73 (mean age  $43.4 \pm 14.8$  years).

### 3.1 | Postoperative complications experienced by the patients

Before removal of the nasal packing the day after surgery, the patients experienced the HSS as significantly less painful (HSS median 17, IQR: 4-30 vs PVA median 30, IQR: 16-51) and less uncomfortable (HSS median 26, IQR: 7-45 vs PVA median 32, IQR: 18-67) when compared to the PVA nasal packing (Figure 1A,C). At the same time, the perceived postoperative bleeding on the HSS side was slightly elevated (HSS median 38, IQR: 18-62 vs PVA median 30, IQR: 16-62), although the difference in VAS score was not significant (Figure 1B). Most of the patients (78%) reported the HSS irrigation as the least unpleasant postoperative treatment (Table 1).

The unpleasantness upon the removal of the nasal packing was widely scattered along the VAS scoring (median 47, IQR = 12-76), from not unpleasant to very uncomfortable. Approximately one-third of the patients reported a VAS score  $\geq 75$ , that is, very uncomfortable (Figure 1D).<sup>27</sup>

After removal of the nasal packing, the uncomfortable experiences were significantly worse in the nostril treated with PVA nasal packing as compared to HSS irrigation (HSS median 18.00, IQR: 11.00-38.25 vs PVA median 29.00, IQR: 16.75-56.25; Figure 1C). The sensation of bleeding tended to be less in the HSS-treated side (Figure 1B), although the difference in VAS was not significant (HSS median 19.00, IQR: 8.75-45.50 vs PVA median 35.50, IQR: 18.25-61.25). VAS pain score was slightly decreased in the HSS nostril after the removal of the nasal packing, although not significant (HSS median 15.00, IQR: 4.50-33.00 vs PVA median 22, IQR: 9.00-39.50). During the follow-up visit 2 weeks after the surgery, all VAS scores were considerably lower, and no difference in any of the VAS scores was observed between HSS and PVA. A slight majority of the patients (59%) reported the HSS irrigation as least uncomfortable at this time

(Table 1). Endoscopic evaluation, 2 weeks post-surgery, showed that wound healing of the sinonasal mucosa was neither compromised in any nostril nor were any cases of postoperative bleeding discovered in the patients.

### 3.2 | Openly described inconveniences

Post-surgery, participants were asked to comment and describe their perceived inconveniences before, during, and 2 weeks after nasal packing removal, in free text. The patients described a vast number of unpleasant experiences (Table 2). Bleeding, pain, congestion, and sinus pressure were the most frequent postoperative unpleasant experiences.

Several patients pointed out uncomfortable experiences toward a specific nostril, and most of these side-specific experiences were related to the PVA-packed nostril. On the HSS side, a few participants described bleeding, congestion before removal, and more crusting and congestion 2 weeks post-surgery (Table 2). Patients experiencing inconveniences in the PVA-packed nostril described them similarly to the complications in the HSS-treated nostril but also perceived breathing difficulties, pain, sinus pressure, and increased rhinorrhea as well as a general sense of discomfort (Table 2).

The removal of the PVA packing was perceived as painful, uncomfortable, and inducing bleeding. The bleeding or other types of unpleasantness were considered severe for some patients (Table 3). The nasal packing was perceived as surprisingly large, and a relief after removal was described. The packing removal was perceived as generally unproblematic for about one-fifth (19.2%) of the patients.

**TABLE 3** Patients' described experiences of discomfort during nasal packing removal

Described discomforts	During nasal packing removal (no. of comments)
Bleeding	
Bleeding	5
Severe bleeding	3
General discomforts	
Uncomfortable	4
Severe discomfort	4
Sensory discomforts	
Pain	5
Stinging	1
Tickling	1
General comments	
No problems	5
Relief after removal	4
Surprised by the size	3

Note: Comments of discomfort were shortened into common denominator and then quantified.

## 4 | DISCUSSION

To date, the standard treatment strategy in the management of refractory CRS is FESS. To achieve a beneficial therapeutic outcome, proper postoperative care is essential.<sup>25</sup> Currently, most surgeons decide to use nasal packing in the sinonasal cavity post-surgery due to the concern of postoperative hemorrhage and intranasal adhesions.<sup>29</sup> However, nasal packing is a painful procedure that causes rebleeding upon removal and may affect the mucosal healing.<sup>21</sup> The effectiveness of nasal packing is currently an issue of controversy, as studies have been unable to show significant benefits.<sup>16,18</sup> HSS rinsing is an established procedure that has hemostatic effect on the mucosa.<sup>23</sup> In the current pilot study, self-rated postoperative complications of conventional nonabsorbable PVA packing and the alternative no-packing method, HSS, were compared in the same patient.

The results of the current study show a significant better outcome with HSS in terms of pain before as well as for pain and other uncomfortable experiences both before and after removal of the PVA. Moreover, a tendency of less bleeding was documented from the HSS-treated nostril after removal of the PVA. No significant differences in any of the assessed variables were detected 2 weeks post-surgery. In addition, approximately one-third of the patients experienced extreme pain (VAS  $\geq$  75) during the packing removal, and overall, a slight majority of the patients preferred HSS over the PVA.

In line with our findings, a previous study showed that the bleeding, pain, and other uncomfortable experiences were significantly reduced in the nasal cavity without packing as compared to the one packed with PVA.<sup>30</sup> Also, the same study showed no difference in mucosal adhesions between packed and non-packed nostrils. Moreover, results from meta-analyses have concluded that nasal packing did not reduce bleeding post-surgery,<sup>13</sup> and no significant differences in synechiae formation could be observed between no packing and various packing materials.<sup>31</sup> In addition, packing was not advantageous in terms of postoperative adhesion, and no-packing methods were suggested to be a cost-efficient alternative.<sup>18</sup>

However, there are conflicting results in the literature. Less adhesions and other complications were observed with absorbable and non-absorbable packing.<sup>13</sup> Also contradictory to our findings, a similar study showed an increased risk of postoperative bleeding in nostrils without packing.<sup>32</sup> Likewise, no significant difference in nasal congestion, pain, or postoperative bleeding was reported with nonabsorbable packing compared to absent packing.<sup>33</sup> The authors also reported higher incidence of middle meatus adhesion when left unpacked. Thus, those results are in conflict with the present findings, as we observed that the nasal packing significantly increased the pain before packing removal, and the HSS-irrigation-treated nostril significantly reduced the bleeding and other uncomfortable experiences as opposed to the packed side. In addition, no form of synechiae could be observed in any of the patients included in our study, assessed 2 weeks after surgery. Hence, the HSS irrigation technique may be equally effective in terms of avoiding mucosal adhesions.

Although consensus has not been reached, leaving the nasal cavity without packing after FESS appears to neither affect the healing process nor worsen postoperative bleeding in most patients.<sup>19</sup>

Following attentive preoperative and intraoperative hemostatic measures as well as employing a cautious operative technique minimizes bleeding and thereby the necessity to pack.<sup>20,34</sup> However, the need to pack may be warranted in cases of severe nasal hemorrhage which should be carefully investigated before and during surgery by the surgeon to assess the risk for each patient.<sup>19</sup> Thus, we believe nasal packing is needed for patients with imminent risk of postoperative bleeding but not for everyone undergoing sinus surgery.

The qualitative data presented in our study, consisting of openly described discomforts by the included patients, confirm previously established sinonasal symptoms typically experienced by patients with CRS.<sup>25</sup> The stress, pain, and unpleasantness evoked by the nasal packing removal were apparent from the open free-text comments. A wide array of symptoms and experiences were described, and numerous patients expressed excessive discomforts related to one of the nostrils. Thus, the results outline that discomforts experienced post-FESS during recovery are partly related to the utilized postoperative treatment method. The variation and number of perceived discomforts in the PVA-treated nostril exceeded greatly the discomforts experienced in the HSS-treated nostril. However, as some individuals preferred the PVA packing and explicitly expressed troubles with the HSS-treated nostril, it is of importance to acknowledge the problems associated with both methods. Our study highlights the possibility to reduce unpleasantness and pain experienced post-surgery, by giving the patients the opportunity to avoid PVA and have their nostrils rinsed with HSS instead. Individuals with CRS are commonly depicted as a patient group with reduced QoL,<sup>3</sup> assessed by the extent of sinonasal symptoms which were clearly reported here. Thus, minimizing the postsurgical suffering may ultimately improve the QoL during the recovery time after surgery for patients with CRS. We believe that HSS is preferred in most cases of FESS, given that the surgeon considers it appropriate in terms of managed risk of nasal hemorrhage.

To the best of our knowledge, this is the first time HSS has been evaluated postsurgically in an intraindividual study setting; each patient functioned as their own control. The equal bilateral CRS involvement of all included patients ensured the comparability between the HSS and nasal packing treated sides of the nasal cavity, respectively. The surgical procedures were consistently performed by the same two surgeons which further strengthened the validity of our study. Nonetheless, there are some limitations to our study that need to be acknowledged. The dropout rate was relatively high which may be a source of bias. Though the surgical procedure was equally performed in both sinuses, the lack of randomized allocation may have biased the results. An inherent disadvantage with the current study design is the difficulty to maintain treatment blinding. Lastly, the current study lacked assessment of the long-term mucosal healing process, past the 2-week follow-up. Thus, to further confirm the benefits of replacing conventional packing with the HSS rinse method, assessments of QoL and long-term mucosal adhesion complications are needed.

## 5 | CONCLUSION

Our findings indicate that there are no significant benefits to be gained from nonabsorbable packing compared to HSS after FESS, in

terms of patients' comfort or bleeding. From the results of the present study, we conclude that irrigation with 47°C sterile saline could be an alternative postoperative treatment. Hot saline irrigation may contribute to patients experiencing improved control of postoperative bleeding, pain, and less suffering of other causes for the patients as well as health-economic benefits, without affecting the mucosal healing up to 2 weeks post-surgery. In light of our findings, postsurgical nasal packing is still the treatment of choice for patients with risk of excessive hemorrhage.

## ACKNOWLEDGMENTS

We thank Ms. Susana Araya Holmqvist for her substantial contribution and technical assistance. In addition, we thank all the patients and staff at the Department of Otorhinolaryngology for their participation and contribution to our study. The current study was supported by the Sophiahemmet Research Foundation.

## CONFLICT OF INTEREST

The authors declare that they have no competing interests.

## AUTHOR CONTRIBUTIONS

**Mattias Jangard:** Conceptualization and execution; writing – review and editing. **Michael Ryott:** Conceptualization and execution; writing – review and editing. **Axel Nordström:** Data analysis and interpretation; writing – original draft; writing – editing. **Maria Kumlin:** Study design; data collection; writing – review and editing. **Marie Svedberg:** Study design; data collection; writing – review and editing. **Helena Kullenberg:** Qualitative data analysis; writing – review and editing.

## ORCID

Axel Nordström  <https://orcid.org/0000-0003-2314-3322>

## BIBLIOGRAPHY

- Dietz de Loos D, Lourijsen ES, Wildeman MAM, et al. Prevalence of chronic rhinosinusitis in the general population based on sinus radiology and symptomatology. *J Allergy Clin Immunol*. 2019;143(3):1207-1214.
- Hastan D, Fokkens WJ, Bachert C, et al. Chronic rhinosinusitis in Europe—an underestimated disease. A GAZLEN study. *Allergy*. 2011;66(9):1216-1223. doi: 10.1111/j.1398-9995.2011.02646.x.
- Hoehle LP, Phillips KM, Bergmark RW, Caradonna DS, Gray ST, Sedaghat AR. Symptoms of chronic rhinosinusitis differentially impact general health-related quality of life. *Rhinology*. 2016;54(4):316-322.
- Dudvarski Z, Djukic V, Janosevic L, Tomanovic N, Soldatovic I. Influence of asthma on quality of life and clinical characteristics of patients with nasal polyposis. *Eur Arch Otorhinolaryngol*. 2013;270(4):1379-1383.
- Henriquez OA, Schlosser RJ, Mace JC, Smith TL, Soler ZM. Impact of synechia after endoscopic sinus surgery on long-term outcomes in chronic rhinosinusitis. *Laryngoscope*. 2013;123(11):2615-2619.
- Gencer ZK, Özkiriş M, Gencer M, Saydam L. Comparison of Ropivacaine, bupivacaine, Prilocaine, and lidocaine in the Management of Pain and Hemorrhage during nasal pack removal. *Am J Rhinol Allergy*. 2013;27(5):423-425.
- Hydri AS, Alam MJ, Udaipurwala IH, Mirza F. Evaluation of anxiety during nasal pack removal in patients operated under local versus general anesthesia. *J Bahria Univ Med Dent Coll*. 2018;8:226-230.
- Tulaci KG, Arslan E, Tulaci RG, Yazici H. Effect of prilocaine and its combination with tramadol on anxiety and pain during nasal packing removal. *Eur Arch Otorhinolaryngol*. 2020;277(5):1385-1390.
- Özbal Koç AE, Türkoğlu Babakurban S, Kibar SS, Büyüklük F. A comparative study on nasal packing after septoplasty: does it matter in terms of patient comfort, bleeding, and crust or synechia formation? *Kulak Burun Bogaz Ihtis Derg*. 2016;26(3):152-158.
- Samad I, Stevens HE, Maloney A. The efficacy of nasal septal surgery. *J Otolaryngol*. 1992;21(2):88-91.
- Burduk PK, Wierzcowska M, Grześkowiak B, Kaźmierczak W, Wawrzyniak K. Clinical outcome and patient satisfaction using biodegradable (NasoPore) and non-biodegradable packing, a double-blind, prospective, randomized study. *Braz J Otorhinolaryngol*. 2017;83(1):23-28.
- Piski Z, Gerlinger I, Nepp N, et al. Clinical benefits of polyurethane nasal packing in endoscopic sinus surgery. *Eur Arch Otorhinolaryngol*. 2017;274(3):1449-1454.
- Vlastarakos PV, Iacovou E, Fetta M, Tapis M, Nikolopoulos TP. How effective is postoperative packing in FESS patients? A critical analysis of published interventional studies. *Eur Arch Otorhinolaryngol*. 2016;273(12):4061-4071.
- Yan M, Zheng D, Li Y, Zheng Q, Chen J, Yang B. Biodegradable nasal packings for endoscopic sinonasal surgery: a systematic review and meta-analysis. *PLoS One*. 2014;9(12):e115458.
- Wang T-C, Tai C-J, Tsou Y-A, Tsai L-T, Li Y-F, Tsai M-H. Absorbable and nonabsorbable packing after functional endoscopic sinus surgery: systematic review and meta-analysis of outcomes. *Eur Arch Otorhinolaryngol*. 2015;272(8):1825-1831.
- Wee JH, Lee CH, Rhee CS, Kim J-W. Comparison between Gelfoam packing and no packing after endoscopic sinus surgery in the same patients. *Eur Arch Otorhinolaryngol*. 2012;269(3):897-903.
- Leunig A, Betz CS, Siedek V, Kastl KG. CMC packing in functional endoscopic sinus surgery: does it affect patient comfort? *Rhinology*. 2009;47(1):36-40.
- Stern-Shavit S, Nachalon Y, Leshno M, Soudry E. Middle meatal packing in endoscopic sinus surgery—to pack or not to pack?—a decision-analysis model. *Laryngoscope*. 2017;127(7):1506-1512.
- Kim D-K, Rhee CS, Kim J-W. Electrocauterization and no packing may be comparable with nasal packing for postoperative hemorrhage after endoscopic sinus surgery. *Am J Rhinol Allergy*. 2016;30(3):e91-e94.
- Eliashar R, Gross M, Wohlgeleit J, Sichel J-Y. Packing in endoscopic sinus surgery: is it really required? *Otolaryngol Head Neck Surg*. 2006;134(2):276-279.
- Mo JH, Han DH, Shin HW, Cha W, Chang MY, Jin HR. No packing versus packing after endoscopic sinus surgery: pursuit of patients' comfort after surgery. *Am J Rhinol*. 2008;22(5):525-528.
- Stangerup SE, Dommerby H, Siim C, Kemp L, Stage J. New modification of hot-water irrigation in the treatment of posterior epistaxis. *Arch Otolaryngol Head Neck Surg*. 1999;125(6):686-690.
- Gan EC, Alsaleh S, Manji J, Habib AR, Amanian A, Javer AR. Hemostatic effect of hot saline irrigation during functional endoscopic sinus surgery: a randomized controlled trial. *Int Forum Allergy Rhinol*. 2014;4(11):877-884.
- Schlegel-Wagner C, Siekmann U, Linder T. Non-invasive treatment of intractable posterior epistaxis with hot-water irrigation. *Rhinology*. 2006;44(1):90-93.
- Fokkens WJ, Lund VJ, Hopkins C, et al. European position paper on rhinosinusitis and nasal polyps 2020. *Rhinology*. 2020;58(S29):1-464.
- Stangerup SE, Thomsen HK. Histological changes in the nasal mucosa after hot-water irrigation. An animal experimental study. *Rhinology*. 1996;34(1):14-17.
- Doulaptsi M, Prokopakis E, Seys S, Pugin B, Steelant B, Hellings P. Visual analogue scale for sino-nasal symptoms severity correlates with sino-nasal outcome test 22: paving the way for a simple outcome tool of CRS burden. *Clin Transl Allergy*. 2018;8:32.

28. Graneheim UH, Lundman B. Qualitative content analysis in nursing research: concepts, procedures and measures to achieve trustworthiness. *Nurse Educ Today*. 2004;24(2):105-112.
29. Verim A, Şeneldir L, Naiboğlu B, et al. Role of nasal packing in surgical outcome for chronic rhinosinusitis with polyposis. *Laryngoscope*. 2014;124(7):1529-1535.
30. Mehan R, Varghese L, Kurien R, Jeyaseelan V, Vedantam R. Is nasal packing essential after functional endoscopic sinus surgery? A randomized, controlled trial. *Clin. Rhinol*. 2017;10:113-119.
31. Hobson CE, Choby GW, Wang EW, Morton SC, Lee S. Systematic review and metaanalysis of middle meatal packing after endoscopic sinus surgery. *Am J Rhinol Allergy*. 2015;29(2):135-140.
32. Kastl KG, Betz CS, Siedek V, Leunig A. Control of bleeding following functional endoscopic sinus surgery using carboxy-methylated cellulose packing. *Eur Arch Otorhinolaryngol*. 2009;266(8):1239-1243.
33. Bugten V, Nordgård S, Skogvoll E, Steinsvåg S. Effects of non-absorbable packing in middle meatus after sinus surgery. *Laryngoscope*. 2006;116(1):83-88.
34. Orlandi RR, Lanza DC. Is nasal packing necessary following endoscopic sinus surgery? *Laryngoscope*. 2004;114(9):1541-1544.

**How to cite this article:** Nordström A, Jangard M, Svedberg M, Kullenberg H, Ryott M, Kumlin M. Hot saline irrigation in comparison to nasal packing after sinus surgery. *Laryngoscope Investigative Otolaryngology*. 2021;6(6):1267-1274. doi:10.1002/lio2.696