

## Safety of antiplatelet therapy during the perioperative period of revascularization surgery for moyamoya disease patients with ischemic onset

Akihiro Nakamura<sup>1,2</sup>, Syuntaro Takasu<sup>3,4</sup>, Yukio Seki<sup>4</sup> and Ryuta Saito<sup>1</sup>

<sup>1</sup>Department of Neurosurgery, Nagoya University Graduate School of Medicine, Nagoya, Japan

<sup>2</sup>Department of Neurosurgery, Kumiiai Kosei Hospital, Takayama, Japan

<sup>3</sup>Department of Neurosurgery, Japan Community Health Care Organization Chukyo Hospital, Nagoya, Japan

<sup>4</sup>Department of Neurosurgery, Japanese Red Cross Aichi Medical Center Nagoya Daini Hospital, Nagoya, Japan

### ABSTRACT

For patients with moyamoya disease, antiplatelet agents are often used during the perioperative periods of revascularization surgeries to prevent ischemic events. However, antiplatelet therapy is associated with the risk of hemorrhagic complications. Further, the influence of antiplatelet therapy on perioperative ischemic or hemorrhagic complications has not been investigated. This study aimed to determine the impact of antiplatelet agents on adult moyamoya disease patients with ischemic onset during the perioperative period. From January 2016 to December 2020, 183 consecutive combined (direct and indirect) revascularization surgeries for moyamoya disease patients were performed. Among these surgeries, 96 consecutive combined revascularization surgeries for adult moyamoya disease patients with ischemic onset were analyzed and perioperative ischemic and hemorrhagic complications were reviewed. Antiplatelet agents were continued during the perioperative period including on the day of surgery and the day after the surgery. Among 96 surgeries, no hemorrhagic complications occurred postoperatively. Infarction occurred in five cases (5.2%). Among the five cases, neurological deficits persisted in two cases and improved in three. The median value of bleeding volume was 112.5 mL (interquartile range, 80.0–200.0). Twenty-five cases (26.0%) needed blood transfusion. The modified Rankin Scale score deteriorated in two cases due to cerebral infarction. The incidence of hemorrhagic and ischemic complications after combined revascularization surgery in patients with ischemic moyamoya disease under antiplatelet therapy was low, indicating the safety of continued antiplatelet therapy.

Keywords: moyamoya disease, antiplatelet therapy, safety, complications

#### Abbreviations:

MCA: middle cerebral artery

MMD: moyamoya disease

MRI: magnetic resonance imaging

mRS: modified Rankin Scale

STA: superficial temporal artery

This is an Open Access article distributed under the Creative Commons Attribution-NonCommercial-NoDerivatives 4.0 International License. To view the details of this license, please visit (<http://creativecommons.org/licenses/by-nc-nd/4.0/>).

Received: April 17, 2023; accepted: June 15, 2023

Corresponding Author: Syuntaro Takasu MD, PhD

Department of Neurosurgery, Japan Community Health Care Organization Chukyo Hospital,  
1-1-10 Sanjo, Minami-ku, Nagoya 457-0866, Japan

Tel: +81-52-691-7151, Fax: +81-52-692-5220, E-mail: takasu-shuntaro@chukyo.jcho.go.jp

## INTRODUCTION

Moyamoya disease (MMD) is characterized by progressive stenosis or occlusion of the terminal portion of the internal carotid artery with development of collateral vessels, causing hemorrhagic or ischemic stroke.<sup>1</sup> Previous studies have shown that revascularization surgery including superficial temporal artery (STA)-middle cerebral artery (MCA) bypass is effective in preventing future ischemic or hemorrhagic events in patients with MMD.<sup>2,3</sup> Antiplatelet agents are often used while awaiting surgery or during outpatient follow-up.<sup>4</sup>

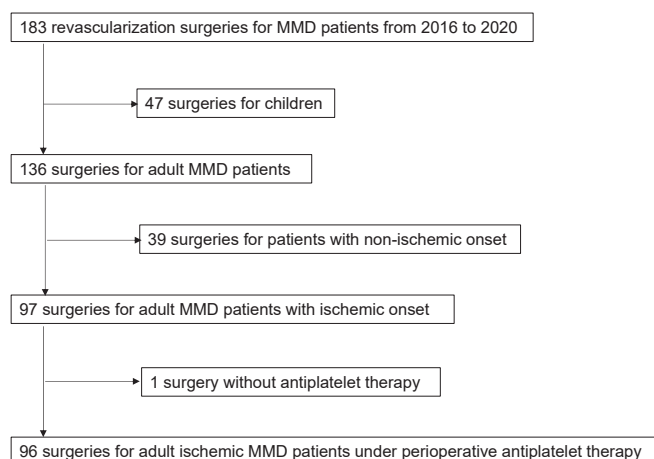
Ischemic events are the common perioperative complications of MMD. In the perioperative period of revascularization procedures, antiplatelet agents are used to avoid ischemic complications,<sup>5</sup> while they may increase the risk of hemorrhagic complications.<sup>5</sup> However, very few reports have investigated the safety and efficacy of perioperative antiplatelet therapy in patients with MMD. Hence, this study aimed to determine the impact of using antiplatelet agents on adult MMD patients with ischemic onset during the perioperative period.

## MATERIALS AND METHODS

This retrospective observational study was approved by the institutional review board of the Japanese Red Cross Aichi Medical Center Nagoya Daini Hospital (approval No. 1519).

*Included surgical procedures*

From January 2016 to December 2020, 183 consecutive combined revascularization surgeries for MMD patients were performed at the Japanese Red Cross Aichi Medical Center Nagoya Daini Hospital. All patients met the diagnostic criteria for MMD according to the guidelines proposed by the Ministry of Health and Welfare of Japan. Forty-seven pediatric cases were excluded. In addition, patients presenting with symptoms other than ischemic symptoms were excluded. Among 97 surgeries for adult MMD patients with ischemic onset, one surgery was excluded because the doctor in charge did not administer antiplatelet agents because of the marked development of moyamoya vessels from the choroid plexus artery, implying a high risk of bleeding. Finally,



**Fig. 1** A flow diagram of the included surgical procedures in this study

MMD: moyamoya disease

96 surgical procedures for MMD patients with ischemic onset were analyzed. These surgical revascularizations were performed under antiplatelet therapy. A flow diagram of the included surgical procedure is shown in Figure 1.

#### *Usage of antiplatelet agents*

The usage of antiplatelet agents was retrospectively reviewed. All of the patients were taking some kind of antiplatelet medication before surgery. Aspirin (100 mg/day) was administered to patients who were not taking any antiplatelet prior to their visit to our hospital. In the case of patients referred from other hospitals, the antiplatelet agents that they were using already were continued, such as clopidogrel (75 mg/day) and cilostazol (200 mg/day). Antiplatelet agents were continued during the perioperative period; continued on the day of surgery and the day after surgery.

#### *Surgical revascularization procedures*

All surgical revascularization procedures were performed by ST, who had 15 years of experience in revascularization surgery for MMD. All surgeries included both direct bypass and indirect revascularization. First, a middle-sized frontotemporal craniotomy was performed within the superior temporal line. Subsequently, single STA-MCA anastomosis was carried out in an end-to-side fashion. There were no cases of unsuccessful direct anastomosis, and bypass patency was confirmed by indocyanine green video-angiography or Doppler ultrasound in all cases. For indirect bypass, encephalo-myo-synangiosis (EMS) was performed within the area of middle-sized frontotemporal craniotomy, which aimed to cover the MCA territory. In addition, another small craniotomy followed by encephalo-periosteal-synangiosis (EPS) was performed to cover the anterior cerebral artery territory.

#### *Perioperative management*

All patients were managed with infusion or blood transfusion to avoid hypovolemia or anemia (above 9 g/dL). Systolic blood pressure was maintained between 80% and 120% of the preoperative value.

In some cases, we used additional agents. When there were concerns about a patient developing ischemic complications due to hyperventilation, sedation with dexmedetomidine was performed upon awakening from anesthesia and during postoperative examination. Minocycline (100 mg/day) was used for 3 days postoperatively to prevent hyperperfusion syndrome. When a patient developed hyperperfusion syndrome, systolic blood pressure was maintained between 80% and 100% of the preoperative value strictly, and edaravone (60 mg/day) and levetiracetam (1000 mg/day) were administered.

#### *Radiographical examinations*

For radiological evaluation, computed tomography (CT) was performed the day after surgery. Magnetic resonance imaging (MRI) and single photon emission computed tomography were performed within 3 days after surgery. MRI included diffusion-weighted imaging (DWI), fluid-attenuated inversion recovery imaging, and MR angiography (MRA). When neurological symptoms were present and ischemic or hemorrhagic complications were suspected, CT and MRI were added as appropriate.

#### *Collected clinical factors and outcomes*

We collected the following parameters as baseline clinical characteristics: sex, age, family history, onset (infarction or transient ischemic attack [TIA]), operation side, stenosis or occlusion

of the posterior cerebral artery (PCA involvement), and preoperative modified Rankin Scale (mRS) score. To assess the influence of antiplatelet treatment on the preoperative period, we recorded the incidences of cerebral infarction and hemorrhagic events reported while the patients were waiting for surgery.

As for the perioperative period, we assessed the radiological and symptomatic stroke (infarction and hemorrhagic complication) during the acute period after revascularization. Radiological and symptomatic cerebral infarction and hemorrhagic complication were assessed individually. Cerebral infarctions were diagnosed according to MRI findings. Hemorrhagic complications were determined by the CT findings. We defined hemorrhagic complications as intracerebral hemorrhage or any epidural/subdural hematoma with cortical compression. In addition, the amount of intraoperative blood loss and numbers of blood transfusions were also evaluated. Furthermore, we assessed the incidence of hyperperfusion syndrome. The diagnostic criteria were as follows: (1) significant increase in cerebral blood flow at the site of the anastomosis that is responsible for apparent neurologic signs including focal neurologic deficit and/or severe headache; (2) apparent visualization of STA-MCA bypass on MRA and the absence of any ischemic changes on DWI, and (3) the absence of other pathologies such as compression of the brain surface by the temporal muscle inserted for indirect bypass.<sup>6</sup> The mRS score was recorded to assess postoperative patient disability. In addition, coagulation function in the blood test just after the surgery was evaluated.

## RESULTS

### *Baseline characteristics*

In this study, 96 procedures for adult MMD patients with ischemic onset were analyzed. Sixty-nine procedures (71.9%) were for females and 27 (28.1%) were for males. The mean age of the patients was 39.2 years. Nineteen cases had a family history of MMD. As for clinical onset, 28 developed infarction, and 68 developed TIA. Preoperative MRI showed old cerebral infarction in 58 cases and PCA involvement in 25. Regarding the antiplatelet agents used, aspirin was administered to 78, clopidogrel, to 10, and cilostazol, to eight. We also evaluated the mRS scores before surgery. The preoperative mRS scores were as follows: 0 in 71 cases, 1 in two cases, 2 in 17 cases, 3 in five cases, and 4 in one case. Detailed data are presented in Table 1.

### *Outcomes*

We performed MRI the day before surgery to check for new lesions. In the preoperative period while waiting for surgery, no patient demonstrated new cerebral infarction and hemorrhagic events after the first visit to the hospital.

During the perioperative periods, no hemorrhagic complications were observed. Cerebral infarction occurred in five cases (5.2%). All five cases were symptomatic, and the symptoms improved in three cases. The postoperative mRS score were deteriorated in two cases due to the cerebral infarction. The median value of bleeding volume was 112.5 mL (interquartile range, 80.0–200.0). The values of coagulation function just after surgery were collected in 92 of 96 cases: prothrombin time-international normalized ratio ([PT-INR], median, interquartile range: 1.0, 0.9–1.0); activated partial thromboplastin time ([APTT], 27.1 sec, 25.8–28.9 sec); fibrinogen (275.0 mg/dL, 235.5–320.0 mg/dL). Detailed data are presented in Table 2.

**Table 1** Baseline characteristics

Characteristics	Outcome (n=96)
Sex	
Female	69 (71.9%)
Male	27 (28.1%)
Mean age $\pm$ SD, years	39.2 $\pm$ 11.1
Family history	
Yes	19 (19.8%)
No	77 (80.2%)
Onset	
Infarction	28 (29.2%)
TIA	68 (70.8%)
Operation side	
Left	45(46.9%)
Right	51(53.1%)
PCA involvement	
Yes	25 (26.0%)
No	71 (74.0%)
Preoperative infarction	
Yes	58 (60.4%)
No	38 (39.6%)
Antiplatelet therapy	
Aspirin	78 (81.3%)
Clopidogrel	10 (10.4%)
Cilostazol	8 (8.3%)
Preoperative mRS	
0	71 (74.0%)
1	2 (2.1%)
2	17 (17.7%)
3	5 (5.2%)
4	1 (1.0%)

mRS: modified Rankin Scale

PCA: posterior cerebral artery

TIA: transient ischemic attack

**Table 2** Clinical outcomes

Characteristic	Outcome (n=96)
Postoperative infarction radiographically	
Yes	5 (5.2%)
No	91 (94.8%)
Postoperative ischemic complications	
Cerebral infarction (symptom improved)	3 (3.1%)
Cerebral infarction (symptom remained)	2 (2.1%)
None	91 (94.8%)

Postoperative hemorrhagic complications	0 (0%)
Postoperative hyperperfusion syndrome	
Yes	13 (13.5%)
No	83 (86.5%)
Median volume of blood loss (interquartile range), mL	112.5 (80.0–200.0)
Transfusion	
Yes	25 (26.0%)
No	71 (74.0%)
Postoperative mRS	
0	70 (73.0%)
1	2(2.1%)
2	17 (17.7%)
3	6 (6.3%)
4	1 (1.0%)

mRS: modified Rankin Scale

Twenty-five cases (26.0%) needed blood transfusion to avoid anemia. For the characteristics in these cases, 24 procedures (96%) were for female, and the median value of bleeding volume was 140.0 mL (interquartile range, 80.0–230.0) that were slightly higher than those of overall cases.

## DISCUSSION

To our knowledge, this is the first report to confirm the safety of preoperative antiplatelet therapy continued until postoperatively in adult MMD patients with ischemic onset. Any hemorrhagic complications were not observed, and cerebral infarction occurred in five cases (5.2%). The mRS score deteriorated in only two (2.1%) out of the five cases with cerebral infarction. Therefore, continued antiplatelet therapy during the perioperative period of combined surgical revascularization can help keep the incidence of ischemic events low without increasing the risk of hemorrhagic complications.

Given its pharmacological action, antiplatelet therapy might increase the risk of perioperative hemorrhagic complications. Although few studies reported the risk of hemorrhagic complications with antiplatelet medication in the field of neurosurgery, intracranial surgery is generally considered a high-risk procedure for perioperative bleeding complications and continuing antithrombotic agents is not recommended.<sup>7</sup> Specifically, in MMD, Zhao et al reported that among patients on antiplatelet agents (aspirin at 100 mg per day orally) from post-surgical day 1 until 1 month after revascularization surgery, postoperative hemorrhage had occurred in 3.4%.<sup>7,8</sup> We used the antiplatelet agents before surgery and continued administration during the perioperative period including the day of surgery and the day after surgery; however, we did not observe any postoperative hemorrhagic complications. To reduce hemorrhagic complications, in terms of surgical technique, we carefully coagulated the small branch of the STA used for direct anastomosis, and also coagulated bleeding points on the periosteum and temporal muscle used for indirect anastomosis. Second, during direct anastomosis, the arteries were sutured so that the intima of the MCA was in contact with that of the STA. Third, we also performed dural tenting of the craniotomy rim and central tenting of the temporalis muscle and pericranium used for indirect anastomosis. These tissues, such as temporalis muscle and pericranium, are less rigid than the original dura mater,

and there is a greater risk of hematoma formation between the cranium and these tissues than the original dura mater. Another treatment strategy to reduce hemorrhagic complications is to prevent hyperperfusion syndrome, which is known as an important cause of cerebral hemorrhage after revascularization in patients with MMD. We maintained the systolic blood pressure between 80% and 120% of the preoperative value after the procedure. In addition, we used minocycline postoperatively. The administration of minocycline with blood pressure control was effective in preventing symptomatic hyperperfusion syndrome after STA-MCA anastomosis for MMD.<sup>9</sup> Furthermore, in cases presenting hyperperfusion syndrome, we strictly maintained systolic blood pressure between 80% and 100% of the preoperative value and administered edaravone and antiepileptic drugs for brain protection. Uchino et al reported that perioperative administration of edaravone reduced the incidence of neurological deficits related to hyperperfusion syndrome after direct bypass procedures in adult patients with MMD.<sup>10</sup> As a result, our study proved that antiplatelet therapy can be said to be safe, as there were no bleeding complications.

Perioperative ischemic complications are the other significant complications that should be avoided.<sup>11</sup> In studies of MMD cohorts not limited to ischemic onsets, several investigators have reported that postoperative ischemic complications for MMD patients occurred in 2.1% to 19.7% of the cases.<sup>12-18</sup> In patients with ischemic MMD, the incidence of ischemic complications was relatively higher than that of other onsets. Park et al reported a 19.7% risk of developing postoperative ischemic complications when antiplatelet agents were discontinued 7 days before surgery.<sup>17</sup> Zhao et al reported that the rate of postoperative ischemic events was 18.6% when they used antiplatelet agents from postoperative day 1 until 1 month.<sup>18</sup> In our study, surgical revascularization was performed under continued antiplatelet therapy in patients with ischemic MMD and postoperative symptomatic infarction occurred only in five cases (5.2%), and sequelae were observed in two (2.1%); this infarction rate is very low compared to those reported in previous studies,<sup>12-18</sup> possibly because the antiplatelet therapy regime was different from our regime, indicating the benefit of continued antiplatelet therapy in the perioperative period. One possible demerit of this perioperative management with antiplatelet treatment was blood transfusion. We used blood transfusion in about 25 % of cases to avoid anemia (above 9 g/dL) for preventing ischemic events, and most of the cases that required blood transfusion were females (96%). Because females tend to be anemic preoperatively due to menstruation, surgeons should well inform female patients about the possibility of blood transfusion.

We administered antiplatelet therapy just after the first visit to our hospital in cases that demonstrated ischemic symptoms but did not take antiplatelet agents. The cerebral infarction while waiting for surgical revascularization is an important problem for patients with ischemic MMD.<sup>19</sup> In our cohort, no patient developed cerebral infarction or hemorrhagic events while waiting for surgery. As a possible merit of antiplatelet therapy, preoperative antiplatelet therapy may prevent infarction without the risk of hemorrhage.

This study has some limitations. First, this was a single-center, retrospective, and observational study. Second, the influence of antiplatelet therapy on other clinical phenotypes of MMD, such as hemorrhagic and asymptomatic MMD, is still unknown. The efficacy of perioperative antiplatelet therapy in patients with hemorrhagic and asymptomatic MMD is limited and not recommended.

In conclusion, our study showed that the incidence of perioperative hemorrhagic and ischemic complications on MMD patients with ischemic onset was low under antiplatelet therapy, indicating that perioperative antiplatelet therapy is safe for adult MMD patients with ischemic onset.

## CONFLICT OF INTEREST

The authors have no relevant financial or non-financial interests to disclose.

## AUTHOR CONTRIBUTIONS

Conceptualization: Akihiro Nakamura, Syuntaro Takasu; methodology: Akihiro Nakamura, Syuntaro Takasu; formal analysis and investigation: Akihiro Nakamura; writing – original draft preparation: Akihiro Nakamura; supervision: Yukio Seki, Ryuta Saito.

## ETHICAL APPROVAL

This study was performed in line with the principles of the Declaration of Helsinki. This retrospective observational study was approved by the institutional review board of the Japanese Red Cross Aichi Medical Center Nagoya Daini Hospital (Approval No. 1519).

## CONSENT TO PUBLISH

Informed consent was obtained from all individual participants included in the study. The participant has consented to the submission of the report to the journal.

## REFERENCES

- 1 Shang S, Zhou D, Ya J, et al. Progress in moyamoya disease. *Neurosurg Rev.* 2020;43(2):371–382. doi:10.1007/s10143-018-0994-5.
- 2 Miyamoto S, Yoshimoto T, Hashimoto N, et al. Effects of extracranial-intracranial bypass for patients with hemorrhagic moyamoya disease: results of the Japan Adult Moyamoya Trial. *Stroke.* 2014;45(5):1415–1421. doi:10.1161/STROKEAHA.113.004386.
- 3 Kuroda S, Houkin K. Moyamoya disease: current concepts and future perspectives. *Lancet Neurol.* 2008;7(11):1056–1066. doi:10.1016/S1474-4422(08)70240-0.
- 4 Oki K, Katsumata M, Izawa Y, et al. Trends of antiplatelet therapy for the management of Moyamoya disease in Japan: results of a nationwide survey. *J Stroke Cerebrovasc Dis.* 2018;27(12):3605–3612. doi:10.1016/J.JSTROKECEREBROVASCDIS.2018.08.030.
- 5 Kanamori F, Araki Y, Yokoyama K, et al. Effects of aspirin and heparin treatment on perioperative outcomes in patients with Moyamoya disease. *Acta Neurochir (Wien).* 2021;163(5):1485–1491. doi:10.1007/S00701-020-04668-0.
- 6 Fujimura M, Mugikura S, Kaneta T, Shimizu H, Tominaga T. Incidence and risk factors for symptomatic cerebral hyperperfusion after superficial temporal artery-middle cerebral artery anastomosis in patients with moyamoya disease. *Surg Neurol.* 2009;71(4):442–447. doi:10.1016/J.SURNEU.2008.02.031.
- 7 Chassot PG, Marcucci C, Delabays A, Spahn DR. Perioperative antiplatelet therapy. *Am Fam Physician.* 2010;82(12):1484–1489.
- 8 Ishikawa T, Yamaguchi K, Kawashima A, et al. Predicting the occurrence of hemorrhagic cerebral hyperperfusion syndrome using regional cerebral blood flow after direct bypass surgery in patients with Moyamoya disease. *World Neurosurg.* 2018;119:e750–e756. doi:10.1016/J.WNEU.2018.07.258.
- 9 Fujimura M, Niizuma K, Inoue T, et al. Minocycline prevents focal neurological deterioration due to cerebral hyperperfusion after extracranial-intracranial bypass for moyamoya disease. *Neurosurgery.* 2014;74(2):163–170. doi:10.1227/NEU.0000000000000238.
- 10 Uchino H, Nakayama N, Kazumata K, Kuroda S, Houkin K. Edoxaban reduces hyperperfusion-related neurological deficits in adult Moyamoya disease: historical control study. *Stroke.* 2016;47(7):1930–1932. doi:10.1161/STROKEAHA.116.013304.



- 11 Hyun SJ, Kim JS, Hong SC. Prognostic factors associated with perioperative ischemic complications in adult-onset moyamoya disease. *Acta Neurochir (Wien)*. 2010;152(7):1181–1188. doi:10.1007/S00701-010-0638-1.
- 12 Cho WS, Kim JE, Kim CH, et al. Long-term outcomes after combined revascularization surgery in adult moyamoya disease. *Stroke*. 2014;45(10):3025–3031. doi:10.1161/STROKEAHA.114.005624.
- 13 Jiang H, Yang H, Ni W, et al. Long-Term Outcomes After Combined Revascularization Surgery in Adult Hemorrhagic Moyamoya Disease. *World Neurosurg*. 2018;116:e1032-e1041. doi:10.1016/J.WNEU.2018.05.153.
- 14 Kashiwazaki D, Akioka N, Kuwayama N, et al. Berlin Grading System can stratify the onset and predict perioperative complications in adult Moyamoya disease. *Neurosurgery*. 2017;81(6):986–991. doi:10.1093/NEUROS/NYX140.
- 15 Kim T, Bang JS, Kwon OK, et al. Hemodynamic changes after unilateral revascularization for Moyamoya disease: serial assessment by quantitative magnetic resonance angiography. *Neurosurgery*. 2017;81(1):111–119. doi:10.1093/NEUROS/NYW035.
- 16 Kazumata K, Ito M, Tokairin K, et al. The frequency of postoperative stroke in moyamoya disease following combined revascularization: a single-university series and systematic review. *J Neurosurg*. 2014;121(2):432–440. doi:10.3171/2014.1.JNS13946.
- 17 Park W, Ahn JS, Lee HS, Park JC, Kwun BD. Risk factors for newly developed cerebral infarction after surgical revascularization for adults with Moyamoya disease. *World Neurosurg*. 2016;92:65–73. doi:10.1016/J.WNEU.2016.03.053.
- 18 Zhao Y, Zhang Q, Zhang D, Zhao Y. Effect of aspirin in postoperative management of adult ischemic Moyamoya disease. *World Neurosurg*. 2017;105:728–731. doi:10.1016/J.WNEU.2017.06.057.
- 19 Funaki T, Takahashi JC, Takagi Y, et al. Unstable moyamoya disease: clinical features and impact on perioperative ischemic complications. *J Neurosurg*. 2015;122(2):400–407. doi:10.3171/2014.10.JNS14231.