

# Evaluation of immunohistochemical expression of epithelial–mesenchymal transition markers E-cadherin, Twist and Snail in oral submucous fibrosis and their possible association with malignant transformation

Mahadevi B Hosur<sup>1</sup>, Rudrayya S Puranik<sup>1</sup>, Shrinivas S Vanaki<sup>1</sup>, Surekha Rudrayya Puranik<sup>2</sup>,  
Sudhakara M<sup>3</sup>, Sushma Das<sup>4</sup>

Departments of <sup>1</sup>Oral Pathology and Microbiology and <sup>2</sup>Oral Medicine and Radiology, PMNM Dental College and Hospital, Bagalkot,

<sup>3</sup>Department of Oral Pathology and Microbiology, Krishnadevaraya College of Dental Sciences and Hospital, Bengaluru, Karnataka,

<sup>4</sup>Department of Periodontics, Chhattisgarh Dental College and Research Centre, Rajnandagaon, Chhattisgarh, India

## Abstract

**Background:** Oral submucous fibrosis (OSMF) is a chronic, potentially malignant condition of the oral mucosa, predominantly seen in people of Asian descent. The reported malignant transformation rate of OSMF is 7%–13%. In the context of the understanding progression of OSMF, the study of prime molecular expressions is essential. Various markers have received more attention, one of them is E-cadherin. Various factors which promote epithelial–mesenchymal transition (EMT) and inhibit E-Cadherin include Snail1, Snail2, Twist and EF1/ZEB1. The intended study was undertaken to evaluate the possible role of E-cadherin and its regulatory markers Twist1 and Snail1 in OSMF.

### Aims and Objectives:

1. To evaluate the expression of E-cadherin, Twist1 and Snail1 in OSMF
2. To evaluate their possible association with malignant transformation of OSMF

**Materials and Methods:** Histologically proven 20 cases of each OSMF with and without dysplasia were taken as the study group, 20 normal mucosa as control group and were subjected for immunohistochemical (IHC) expression with E-cadherin, Twist1 and snail1.

**Results:** Immunohistochemical expression of all the three markers showed statistically significant expression of all the three markers. Intensity and percentage of staining between the groups were statistically significant for E-cadherin between normal oral mucosa (NOM) and OSMF with dysplasia (OSMFD), no significance was found between NOM and OSMF, whereas Snail1 and Twist1 were statistically significant between NOM and OSMF and also between NOM and OSMFD. However, no significance was found for all the three markers when compared between the groups OSMF and OSMFD.

**Conclusion:** The increased expression of Snail1 and Twist1 with concomitant loss of E-cadherin in OSMF suggests the role of the EMT.

**Keywords:** E cadherin, epithelial–mesenchymal transition, oral submucous fibrosis, Snail, twist

**Address for correspondence:** Dr. Mahadevi B Hosur, Department of Oral Pathology, PMNM Dental College and Hospital, Bagalkot, Karnataka, India.

E-mail: maddy2006@rediffmail.com

**Submitted:** 10-Nov-2020, **Revised:** 06-Jan-2021, **Accepted:** 12-Mar-2021, **Published:** 14-May-2021

### Access this article online

#### Quick Response Code:



#### Website:

www.jomfp.in

#### DOI:

10.4103/jomfp.jomfp\_454\_20

This is an open access journal, and articles are distributed under the terms of the Creative Commons Attribution-NonCommercial-ShareAlike 4.0 License, which allows others to remix, tweak, and build upon the work non-commercially, as long as appropriate credit is given and the new creations are licensed under the identical terms.

**For reprints contact:** WKHLRPMedknow\_reprints@wolterskluwer.com

**How to cite this article:** Hosur MB, Puranik RS, Vanaki SS, Puranik SR, Sudhakara M, Das S. Evaluation of immunohistochemical expression of epithelial–mesenchymal transition markers E-cadherin, Twist and Snail in oral submucous fibrosis and their possible association with malignant transformation. *J Oral Maxillofac Pathol* 2021;25:97-104.

## INTRODUCTION

Oral submucous fibrosis (OSMF) is a chronic, potentially malignant condition of the oral mucosa which was first described by Schwartz in 1952.<sup>[1]</sup> The disease is predominantly seen in people of Asian descent with a reported prevalence ranging up to 0.4% in the Indian population.<sup>[2]</sup> Epidemiological and *in vitro* experimental studies have shown that chewing areca nut is the major etiological factor for OSMF.<sup>[3]</sup> OSMF is highly prevalent in the Indian subcontinent. It is of great health concern, as a substantial percentage of this condition culminates into oral squamous cell carcinoma (OSCC).<sup>[4]</sup> The reported malignant transformation rate of OSMF to OSCC is 7%–13%.<sup>[5]</sup> The higher mortality from OSCC is mainly due to delayed diagnosis of the malignant potentiality of the associated precancers.<sup>[4]</sup>

OSMF is characterized by inflammation and progressive generalized submucosal fibrosis, leading to limitation of mouth opening.<sup>[5]</sup> Histopathologically, along with varied epithelial alterations, subepithelial deposition of dense bands of collagen fibers with varying degrees of hyalinization is noted in OSMF. The epithelial alterations may vary from atrophy to hyperplasia and or dysplasia with differing stages of OSMF.<sup>[4]</sup> Some of these epithelial and subepithelial changes plausibly reflect impairment in epitheliomesenchymal interactions. There are reports which implicate that such tissue ambiances favor initiation of carcinomatous processes like epithelial–mesenchymal transition (EMT) enabling epithelial cells to acquire migratory potential.<sup>[4]</sup>

A plethora of studies have been taken up for the early detection of oral cancer due to the limited ability of the current clinical/histological methods to predict high-risk precursor lesions and the lack of adequate early predictive markers with the recent advances in technology, the focus is shifted from clinical to biological behavior and underlined molecular events to achieve better outcomes in early detection, prevention and treatment of the disease.<sup>[6]</sup>

In the context of understanding progression of oral precancer like OSMF, the study of prime molecular expressions associated with the epithelial migratory phenotype and various regulators is thus essential.<sup>[4]</sup> Recently, various tumor markers have received more attention and one among them is E-cadherin.<sup>[7]</sup> E-cadherin is important for maintaining epithelial cell-to-cell adhesion, polarity, differentiation, migration and seems to be the most common target for various EMT signaling pathways.<sup>[7]</sup>

Twist which belongs to the basic helix loop helix transcription factor family has been shown to promote EMT.<sup>[4]</sup> *In vitro* and *in vivo* evidence supports major roles for Twist as a regulator of EMT.<sup>[8]</sup> Twist was observed to be upregulated in fibroblasts of lung tissue from idiopathic pulmonary fibrosis patients. The role of Twist in areca nut chewing-associated OSMF remains unknown. However, it is unclear whether Twist is involved in the pathogenesis of OSMF.<sup>[8]</sup>

Snail is a master gene in regulating E-cadherin during the process of EMT. In an OSCC model, Snail-transfected cells showed complete EMT phenotypes with fibroblast-like appearance, vimentin filaments, E-cadherin/N cadherin switching and lack of hemidesmosomes.<sup>[9]</sup>

Expression of E-cadherin has been studied in OSMF, whereas not many studies are done with regard to Twist and Snail in OSMF; hence, this study aims to evaluate the expression of these EMT markers E-cadherin, Twist1 and Snail1 in OSMF and to study their possible association with the progression and malignant transformation of OSMF.

## Aims and objectives

1. To evaluate the expression of E-cadherin, Twist1 and Snail 1 in OSMF
2. To evaluate their possible association with malignant transformation of OSMF.

## MATERIALS AND METHODS

Following the approval of the institutional ethics committee, forty formalin-fixed paraffin-embedded tissue blocks of histopathologically proven cases of OSMF were retrieved from department archives and were divided into two groups those with and without dysplasia, 20 cases each, i.e., OSMF and OSMF with dysplasia (OSMFD), which constituted the study group. Moreover, data about the clinical details of the same were also recorded. Twenty tissue blocks of normal oral mucosa (NOM) obtained from gingival and vestibular mucosa during minor surgical therapeutic procedures from the archives formed the control group. The sections were subjected for hematoxylin and eosin staining. Staging of OSMF cases was noted down based on Khanna and Andrade's study.<sup>[10]</sup> Further, cases were histologically graded at the light microscopic level using Pindborg and Sirsat criteria<sup>[11]</sup> and also those with epithelial dysplasia were graded using the WHO 2005 criteria into mild, moderate and severe dysplasia.<sup>[12]</sup> Tissue blocks were sent to Dr Sanjay Navani, Lab Surgical Pathology, Mumbai, and were subjected for immunohistochemical (IHC) staining with E-cadherin, Twist1 and Snail1. Histological and immunohistochemical analyses for all the slides were conducted by two independent observers.

### IHC procedure

Five-micron sections were obtained from paraffin block and mounted on superfrost slides. IHC study was carried out using polymer labeling technique. Sections were dewaxed and washed and antigen retrieval was carried out in PT link module with 1 mM ethylenediaminetetraacetic acid solution (pH 9) for 20 min. Endogenous peroxidase was blocked using 3% hydrogen peroxide in methanol at room temperature for 10 min. Immunostaining was carried out in Dako Autostainer. Slides were washed with phosphate-buffered saline (PBS) briefly and incubated with primary antibody for 60 min. Sections were washed with PBS. Diaminobenzidine (DAB) was used as the chromogen in hydrogen peroxide for 10 min. Antibodies used were E-Cadherin, Twist1 and Snail1 and sections were counterstained with hematoxylin and mounted. IHC evaluation of the slides was done by two independent observers. The immuno-expression of the aforementioned markers was studied and compared for both study and control groups in terms of intensity and degree of staining.

### IHC evaluation: E-cadherin

Strong and homogeneous expression of E-cadherin was observed at the cell membrane. Slides were examined for the staining pattern (cytoplasmic or membrane), intensity of the staining and percentage of positive staining of cells. Mainly, membranous staining was taken into consideration. Evaluation of immunohistochemistry was scored by its extent and intensity. The staining intensity was recorded on a 4-step scale (0 – no staining, 1 – weak intensity, 2 – moderate intensity and 3 – strong intensity). For the percentage of positive staining cells, six strongly stained fields were chosen and percentage of positive cells scored based on four scales (1 = <25%, 2 = 25%–50%, 3 = 51%–75% and 4 = more than 75%) and the average score was taken for the whole slide (Modified Simionescu *et al.*).<sup>[13]</sup> Expression of E-cadherin was assessed for all the three groups and compared between the groups.

### Snail 1 staining

Evaluation of immunohistochemistry was performed by two independent investigators. Expression of Snail1 was compared between the study and control groups. Snail-positive expression was defined as detectable immunoreaction in the nuclear and sometimes cytoplasmic reaction. Snail-positive cells were clearly identified by their brown nuclear staining (predominantly). Four areas with the highest expression (hotspots) were selected under a magnification  $\times 100$ . Snail-positive cells were counted in four selected fields per section at  $\times 400$  magnification. Percentages of the Snail-positive cells were taken per field and an average was taken for the whole slide.

### Twist staining

Evaluation of immunohistochemistry was scored by its extent and intensity. The staining intensity was estimated on a 4-step scale (0 – no staining, 1 – weak intensity, 2 – moderate intensity and 3 – strong intensity). The percentage of stained cells was scored according to the following criteria: score 0 – no staining of cells, score 1 – <25% positive cells, score 2 – 25%–50% positive cells and score 3 – more than 50% positive cells.

## RESULTS

20 cases of OSMF and 20 cases of OSMFD were retrieved from the departmental archives. OSMF patients' age ranged from 19 to 40 years and OSMFD ranged from 20 to 65 years. All patients in both the groups were males. Duration of the habit ranged from 2 years to 12 years in the OSMF group, whereas it was 2 years to 30 years in OSMFD. Most of the cases of OSMF were in Stage III and the least in Stage I, whereas OSMFD were in Stage III, followed by Stage II. Histological grading of OSMF group comprised mostly of Grade II (50%), followed by Grade III (45%), whereas OSMFD group comprised mostly of Grade III (65%) followed by Grade II (30%). Most of the cases of OSMF with dysplasia were of mild type (65%), followed by moderate (25%) and severe (10%).

Interobserver variability assessment between two observers for intensity and percentage of staining by different biomarkers using Cohen's kappa statistics showed substantial to perfect agreement in all the three different groups. Comparison of intensity and percentage of staining between the three groups for different biomarkers using Chi-square test showed statistical significance for all the three biomarkers [Tables 1 and 2].

Multiple comparison of intensity of staining between the groups was statistically significant for E-cadherin between NOM and OSMFD ( $P = 0.01$ ), no statistical significance was found between the groups NOM and OSMF and OSMF and OSMFD. Statistical significance was found for Snail 1 expression between the groups NOM and OSMF and NOM and OSMFD with  $P = 0.02$ . However, no significance was found between OSMF and OSMFD. Expression of Twist1 also showed significance between NOM and OSMF ( $P = 0.004$ ) and NOM and OSMFD ( $P = 0.009$ ). No statistical significance was found between the groups OSMF and OSMFD [Table 3]. Multiple comparison of percentage of staining cells between the groups using Chi-square test showed statistical significance for E-cadherin between NOM and OSMFD ( $P = 0.04$ ), no significance was found between NOM and OSMF.

Snail1 and Twist1 expression showed statistical significance between the groups NOM and OSMF and also NOM and OSMFD [Table 4]. However, no statistical significance was found for all the three markers when compared between the groups OSMF and OSMFD.

**DISCUSSION**

Oral submucosal fibrosis is well-recognized as a potentially malignant disorder.<sup>[14]</sup> Worldwide, estimates of OSMF show confinement to Indians and South East Asians, with the overall prevalence rate in India to be around 0.2%–0.5%.<sup>[1]</sup> The incidence of this disease is rising in India, especially among the younger population due to increased access and fascinating marketing strategies that make availability of areca nut.<sup>[5]</sup>

The age range of the patients with OSMF is wide, ranging from 20 years to 40 years of age.<sup>[1]</sup> In the present study,

clinical data of the cases showed that OSMF patient’s age ranged from 19 to 40 years and OSMFD ranged from 20 to 65 years. The age range of patients in the study is in concordance with the literature. Interestingly, the age range for patients with histological dysplasia extends by another two decades than patients without dysplasia. There are not much data available in regard to the difference in the age groups of OSMF patients with and without dysplasia though it subtly reflects the influence of age-related changes in the development of dysplastic features. Further, individuals with OSMF are bound to carry on with addiction of habit until known to experience serious problem may be for years together. Factors such as duration of the disease process, persistence of habits, and host immune factors may influence the development and appearance of morphological changes at the light microscopic level.

**Table 1: Comparison of intensity of staining between three groups for different biomarkers using Chi-square test**

Biomarkers	Intensity	Normal mucosa, n (%)	OSMF, n (%)	OSMF with dysplasia, n (%)	$\chi^2$	P
E cadherin	No stain	0	0	3 (15)	15.100	0.02*
	Weak	0	2 (10)	4 (20)		
	Moderate	3 (15)	7 (35)	5 (25)		
	Strong	17 (85)	11 (55)	8 (40)		
Snail 1	No stain	4 (20)	8 (40)	7 (35)	19.102	0.004*
	Weak	8 (40)	0	0		
	Moderate	4 (20)	6 (30)	5 (25)		
	Strong	4 (20)	6 (30)	8 (40)		
Twist	No stain	15 (75)	8 (40)	8 (40)	14.561	0.02*
	Weak	5 (25)	2 (10)	3 (15)		
	Moderate	0	2 (10)	1 (5)		
	Strong	0	8 (40)	8 (40)		

\*Significant statistically (the level of significance for all the inferential test was set at p less than 0.05), OSMF: Oral submucous fibrosis

**Table 2: Comparison of percentage staining of cells between the three groups for different biomarkers using Chi-square test**

Biomarkers	Percentage of staining cells	Normal mucosa, n (%)	OSMF, n (%)	OSMF with dysplasia, n (%)	$\chi^2$	P
E-cadherin	No expression	0	0	3 (15)	15.350	0.04*
	<25	0	1 (5)	2 (10)		
	25–50	2 (10)	7 (35)	6 (30)		
	51–75	8 (40)	3 (15)	4 (20)		
	76–100	10 (50)	9 (45)	5 (25)		
Snail 1	No expression	4 (20)	8 (40)	7 (35)	20.456	0.002*
	<25	9 (45)	1 (5)	0		
	25–50	5 (25)	4 (20)	4 (20)		
	51–75	2 (10)	7 (35)	9 (45)		
	76–100	0	0	0		
Twist	No expression	15 (75)	8 (40)	8 (40)	16.078	0.01*
	<25	4 (20)	1 (5)	3 (15)		
	25–50	1 (5)	6 (30)	2 (10)		
	>50	0	5 (25)	7 (35)		

\*Significant statistically. OSMF: Oral submucous fibrosis

**Table 3: Multiple comparison of intensity of staining between the groups for different biomarkers using Chi-square test**

Variable	Biomarker	NOM versus OSMF	NOM versus OSMFD	OSMF versus OSMFD
Intensity of staining	E-cadherin	0.09	0.01*	0.22
	Snail 1	0.02*	0.02*	0.80
	Twist	0.004*	0.009*	0.91

\*Significant statistically. NOM: Normal oral mucosa, OSMF: Oral submucous fibrosis, OSMFD: OSMF with dysplasia



**Table 4: Multiple comparison of percentage of staining cells between the groups for different biomarkers using Chi-square test**

Variable	Biomarker	NOM versus OSMF	NOM versus OSMFD	OSMF versus OSMFD
Percentage of staining cells	E-cadherin	0.11	0.04*	0.32
	Snail 1	0.01*	0.002*	0.73
	Twist	0.006*	0.02*	0.34

\*Significant statistically. NOM: Normal oral mucosa, OSMF: Oral submucous fibrosis, OSMFD: OSMF with dysplasia

The EMT is a biological event in which epithelial cells lose many of their phenotypic features and gain extra properties typical of mesenchymal cells.<sup>[15]</sup> These cells undergoing EMT exhibit downregulation of many epithelial markers and up-regulation of mesenchymal markers.<sup>[15]</sup> A characteristic feature of loss of epithelial cell adhesion is the reduction in E-cadherin expression. Twist, Slug and Snail are considered as the major transcription factors modulating EMT in various cancer types by binding to the E-cadherin promoter and repressing E-cadherin transcription.<sup>[15]</sup>

In OSMF, the observation of many cytoskeleton proteins like CK 18 decreased and vimentin increased. The nucleus proteins and cytokines like transforming growth factor  $\beta$  (TGF- $\beta$ ), fibroblast growth factor, tumor necrosis factor- $\alpha$ , interleukin 1, platelet-derived growth factor, endothelin-1, and interstitial growth factor are also increased. Extracellular molecules such as matrix metalloproteinase (MMP) 2 and MMP9 are elevated and signaling pathways involved in EMT have been expressed in OSMF and *in vitro* experiments. The betel-areca nut quid-induced tissue injury releases reactive oxygen species which could mediate TGF- $\beta$ 1-induced EMT. As the elements associated with EMT are also observed in OSMF, it is considered that EMT plays a role in the fibrosis of OSMF.<sup>[16]</sup>

E-cadherin is a cell adhesion protein, which plays a critical role in maintaining intercellular junction in epithelial tissue and regulating tumor cell mobility and invasion.<sup>[17]</sup> E-cadherin is described as major growth or proliferation suppressor biomarker.<sup>[7]</sup> In normal epithelium, E-cadherin is expressed in the spinous and basal layers except for the basal surface of the basal layers and superficial layers as a process of continuous renewal of cells.<sup>[7]</sup> E-cadherin is also known to express in various carcinomas of the head and neck, esophagus, prostate, pancreas, stomach and uterine cervix and its reduced expression has been correlated with aggressive behavior. Several researchers hypothesized that E-cadherin expression is reduced with an increase in the grade of dysplasia.<sup>[7]</sup>

It was shown that there is a significant variation in expression of E-cadherin with the histopathological dysplasia of the oral precancerous lesions and conditions

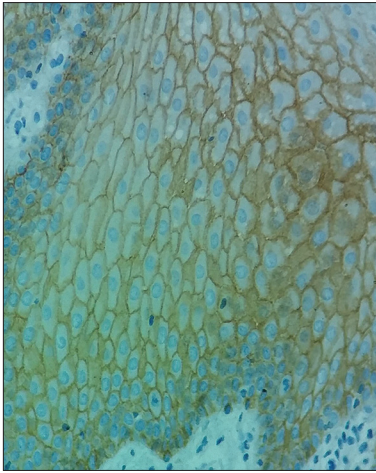
and the tumor differentiation of the oral cancers. However, no correlation found in the degree of loss of expression with the degree of dysplasia or the tumor differentiation of oral cancers. It was concluded in their study that there is a variation in the expression of E-cadherin but its value as a prognostic marker is questionable.<sup>[7]</sup>

In a study conducted by Das *et al.*, E-cadherin depicted remarkable changes at both gene and protein level expressions. Visually, the expression of E-cadherin was found to be membranous in NOM and OSMF in comparison to OSMFD. In OSMFD, broken membranous expression along with a cytoplasmic expression of E-cadherin was observed. Further, it was observed that there was an overall decline in membranous E-cadherin expression throughout the epithelia in OSMFD and OSMF as compared to NOM.<sup>[4]</sup>

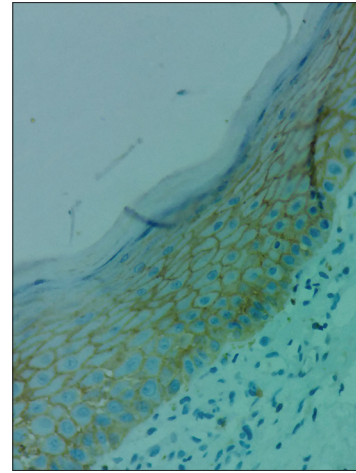
The sizeable percentage of OSMF (10%) and OSMFD (35%) samples in the present study also exhibited a significant reduction in the expression of E-cadherin as compared to NOM [Tables 3 and 4, Figures 1-3] in consistent with the findings of Das *et al.* Interestingly, no such difference in the expression of E-cadherin was observed in comparison between OSMF with or without dysplasia from NOM when analyzed with multiple variants [Tables 3 and 4].

Twist, a basic helix-loop-helix domain-containing transcription factor, functions as a transcription repressor to activate EMT traits by repressing the expression of E-cadherin.<sup>[8]</sup> Overexpression of Twist with concomitant loss of E-cadherin expression plays a distinct role in tumor progression and has also been identified in various kinds of epithelial tumors.<sup>[17]</sup> Twist was observed to be upregulated in fibroblasts of lung tissue from idiopathic pulmonary fibrosis patients. Upregulation of Twist-positive cells is associated with liver and kidney fibrosis.<sup>[8]</sup>

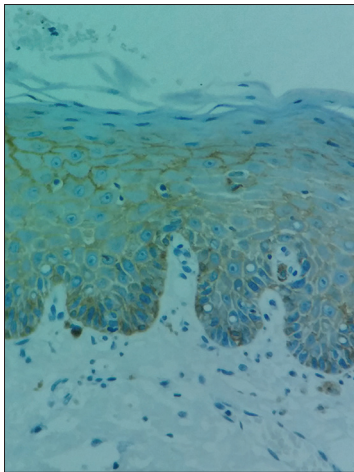
The role of Twist in the pathogenesis of areca quid chewing-associated OSMF is shown mainly due to inducing effect of areca nut resulting in upregulation of buccal mucosal fibroblast, while depletion of Twist by lentiviral knockdown results in reversal of arecoline-induced myofibroblastic differentiation implying its crucial role in the pathogenesis of OSMF.<sup>[8]</sup> Studies involving markers along with P<sup>63</sup>, E-cadherin,



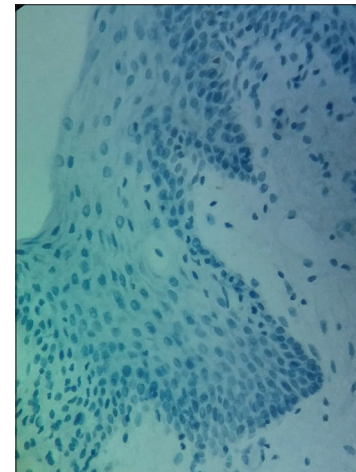
**Figure 1:** High-power view showing strong expression of E-cadherin in normal oral mucosa



**Figure 2:** Photomicrograph showing IHC expression of E-cadherin in oral submucous fibrosis



**Figure 3:** High-power view showing reduced expression of E-cadherin in oral submucous fibrosis with dysplasia



**Figure 4:** Figure showing negative expression of Twist in normal oral mucosa

Twist1 and beta catenin have shown significant expression pattern suggesting its pro-EMT role like changes in OSMF in general and OSMF with dysplasia in particular.<sup>[4]</sup>

Snail proteins regulate various aspects of the EMT phenotype, including overexpression of mesenchymal markers fibronectin and vitronectin and suppression E-cadherin.<sup>[18]</sup> Many researchers have been focusing on the Snail expression and its role in EMT in several types of cancers, especially at the invasive front of OSCC. These facts suggested that Snail1 is a useful marker of EMT and reinforces that EMT is occurring in the invasive front of the carcinoma.<sup>[14]</sup>

Interestingly, this study points that there is a statistically significant difference in expression of Twist and Snail in OSMF process as compared to normal mucosa [Figures 4-6]. However, the difference was not observed when light microscopic dysplastic features were present. Figure 7 shows shows the snail1 expression in OSMFD. This depicts the independent expression

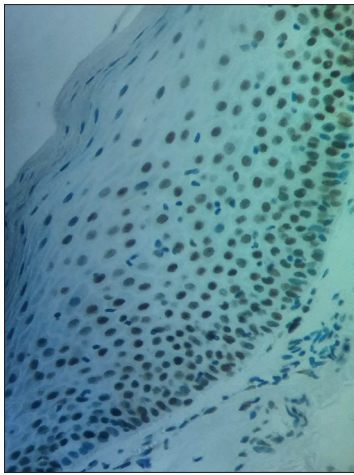
nature of them with respect to dysplasia, although this is the first of its kind to study the snail1 expression in OSMF.

However, no statistical significance was found for all the three markers when compared between the groups OSMF and OSMFD, which may suggest that using these markers may not be helpful in assessing the dysplastic features which is usually taken as indicator of malignant transformation.

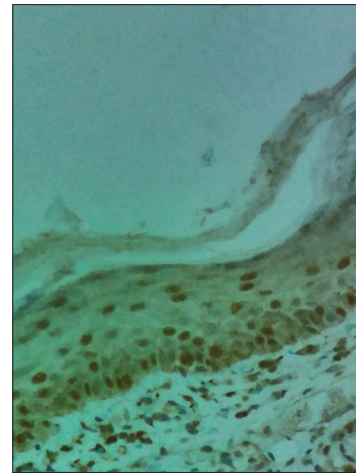
The limitations of the present study may include it is retrospective and immunohistochemical in nature. Clinical application of immunohistochemistry is limited by factors like discrepancies between different antibodies, diversity in interpretation and judgment and inconsistency in specimen preparation and technical procedures.

## CONCLUSION

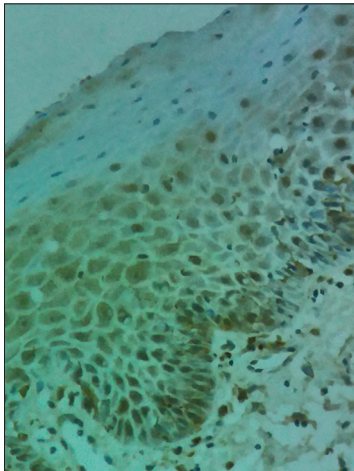
This study is the rare of its kind demonstrating simultaneous



**Figure 5:** Picture showing expression of Twist in oral submucous fibrosis



**Figure 6:** Figure showing Snail expression in oral submucous fibrosis



**Figure 7:** Photomicrograph showing expression of snail in oral submucous fibrosis with dysplasia

expression profile of Snail, Twist and E-cadherin in OSMF. The increased expression profile of Snail1 and Twist1 with concomitant loss of E-cadherin in OSMF suggests the role of the EMT process in pathogenesis of the disease process. This study suggests that EMT signatures are definitely positive in OSMF cases. The current study demonstrates that markers of EMT like Twist1 and Snail1 are expressed in OSMF irrespective of dysplastic features appreciated in routine histopathology. Therefore future studies are required which focus on evaluating the association of markers of EMT and dysplasia at both histopathologic and molecular levels.

### Acknowledgments

The authors would like to thank Dr. Sanjay Navani, M.D., Surgical Pathologist and Immunohistochemist, LABSURGPATH, 204, Bombay Market, 731/1, Tardeo Main Road, Mumbai – 400 034.

### Financial support and sponsorship

Grant – In – Aid for Advanced Research Projects for the year 2016-17 by Rajiv Gandhi University of Health Sciences, Bangalore, Karnataka. (Unique ID ----D008 /2016-17).

### Conflicts of interest

There are no conflicts of interest.

### REFERENCES

1. Kalra SK, Lathi AA, Lathi SA. A comprehensive review of etiopathogenesis of Oral submucous fibrosis. *Int J Head Neck Surg* 2015;6:76-9.
2. Dyavanagoudar SN. Oral submucous fibrosis: Review on Etiopathogenesis. *J Cancer Sci* 2009;1: 072-7.
3. Canniff JP, Harvey W. The aetiology of oral submucous fibrosis: The stimulation of collagen synthesis by extracts of areca nut. *Int J Oral Surg* 1981;10:163-7.
4. Das RK, Anura A, Pal M, Bag S, Majumdar S, Barui A, et al. Epithelio-mesenchymal transitional attributes in oral sub-mucous fibrosis. *Exp Mol Pathol* 2013;95:259-69.
5. Angadi PV, Krishnapillai R. Evaluation of PTEN immunoeexpression in oral submucous fibrosis: Role in pathogenesis and malignant transformation. *Head Neck Pathol* 2012;6:314-21.
6. Prasad RS, Pai A, Shyamala K, Bhadranna A, Shenoy S, Yaji A. Assessment of epithelial-mesenchymal transition signatures in oral submucous fibrosis. *J Oral Maxillofac Pathol* 2019;23:308.
7. Sridevi U, Jain A, Nagalaxmi V, Kumar UV, Goyal S. Expression of E-cadherin in normal oral mucosa, in oral precancerous lesions and in oral carcinomas. *Eur J Dent* 2015;9:364-72.
8. Lee YH, Yang LC, Hu FW, Peng CY, Yu CH, Yu CC. Elevation of twist expression by arecoline contributes to the pathogenesis of oral submucous fibrosis. *J Formos Med Assoc* 2016;115:311-7.
9. Krisanaprakornkit S, Iamaroon A. Epithelial-mesenchymal transition in oral squamous cell carcinoma. *ISRN Oncol* 2012; 2012:1-6.
10. Khanna JN, Andrade NN. Oral submucous fibrosis: A new concept in surgical management. Report of 100 cases. *Int J Oral Maxillofac Surg* 1995;24:433-9.
11. Pindborg JJ, Sirsat SM. Oral submucous fibrosis. *Oral Surg Oral Med Oral Pathol* 1966;22:764-79.
12. Barnes L, Everson JW, Reichart P, Sidransky, editors. WHO Classification of Tumors: Pathology and Genetics of Head and Neck Tumors. Lyon: ARC Press; 2005.

13. Simionescu C, Margaritescu C, Supateanu M, Mogoanta L, Zavori R, Ciurea R, *et al.* The study of E-cadherin and CD44 immunoeexpression in oral squamous cell carcinoma. *Rom J Morphol Emryol* 2008;49:189-93.
14. Kafil Akhtar K, Ara A, Siddiqui SA, Sherwan RK. Transition of Immunohistochemical Expression of E-Cadherin and Vimentin from Premalignant to Malignant Lesions of Oral Cavity and Oropharynx. *Oman Medical Journal* 2016;31:165-9.
15. Sahana NS, Iyengar AR, Mysorekar V, Gopinath P. Snail expression in oral squamous cell carcinoma. *American Journal of Oral Medicine and Radiology* 2016;3:99-103.
16. Ghanta SB, Nayan N, Kumar NG, Pasupuleti S. Epithelial–mesenchymal transition: Understanding the basic concept. *Journal of Orofacial Sciences* 2012;4:82-6.
17. Chi-Chen Fan CC, Wang TY, Cheng TA, Jiang SS, Cheng CC, Lee AY, *et al.* Expression of E-cadherin, Twist, and p53 and their prognostic value in patients with oral squamous cell carcinoma. *Cancer Res Clin Oncol* 2013;139:1735-44.
18. Scanlon CS, Van Tubergen EA, Inglehart RC, and D'Silva NJ. Biomarkers of Epithelial Mesenchymal Transition in Squamous Cell Carcinoma. *J Dent Res* 2013;92:114-21.