




Taibah University

Journal of Taibah University Medical Sciences

www.sciencedirect.com



Case Report

Delayed diagnosis in the maxillofacial region: Two case reports



Ebtihal H. Zain-Alabdeen, MDS^{a,*}, Raed I. Al-Sadhan, MDS^b,
Faisal S. AlSuhaim, BDS^c and Khalid M. AlMutairi, BDS^c

^a Department of Oral and Basic Clinical Sciences, College of Dentistry, Taibah University, Almadinah Almunawwarah, KSA

^b Department of Oral Medicine and Diagnostic Sciences, College of Dentistry, King Saud University, Riyadh, KSA

^c Department of Oral and Maxillofacial Surgery, King Saud Medical City, KSA

Received 31 December 2016; revised 23 March 2017; accepted 27 March 2017; Available online 27 May 2017

المخلص

على الرغم من أنه تاريخياً كانت الأشعة المقطعية التقليدية تستخدم لتصوير عظام الوجه والفكين، فإن دخول الأشعة المخروطية في الألفية الجديدة قد أحدث ثورة في استخدام الأشعة المقطعية لتشخيص أمراض الأسنان والوجه والفكين. نستعرض في هذه الورقة حالتين سريريتين تأخر تشخيصهما باستخدام تصوير الوجه والفكين، وأسباب التأخير والتدابير الوقائية الممكنة. الحالة الأولى تحكي تأخر تشخيص لمفومة لاهودجكينية لسيدة عمرها ٤٩ عاماً وتمت معالجتها على أن لديها مشكلة سنية. وتعرض الحالة الثانية تأخر التشخيص لمریضة تبلغ من العمر ٩ أعوام تعاني من تحدد القدرة على فتح الفم وتم تشخيصها على أنها تعاني من تشنج العضلات. وبعد ذلك، تم تشخيصها بوجود تمدد في اللوحة الجناحية الجانبية مما أدى إلى تداخلها مع عظم الفك السفلي الأيمن مسبباً عدم القدرة على فتح الفم. سنشرح الحالة وكيفية تفادي التأخر في التشخيص. الفحص السريري المتكامل والتصوير الإشعاعي جنباً إلى جنب مع التاريخ المرضي يمكن أن يقلل التأخر في التشخيص. يجب على طبيب الأسنان تحويل المريض عاجلاً للمتخصص الذي يمكنه علاج المشكلة الطبية المحددة إذا لم يتوصل هو إلى التشخيص.

الكلمات المفتاحية: التشخيص؛ الوجه والفكين؛ لمفومة لاهودجكينية؛ المفصل الصدغي الفك السفلي

Abstract

While conventional CT scan has historically been used for maxillofacial bone imaging. The introduction of cone beam CT (CBCT) in the new millennium has

revolutionized the use of CT for dental and maxillofacial diagnoses. This paper presents two clinical examples of delayed diagnoses associated with maxillofacial imaging, describes the reasons for the delays and offers potential preventive measures. The first case involves a delay in the diagnosis of non-Hodgkin's lymphoma in a 49-year-old female who was being treated for an odontogenic problem. In the second case, a 9-year-old female who presented with a limited ability to open her mouth was mistakenly diagnosed with muscles spasm. Subsequently, she was found to have an elongation of the right lateral pterygoid plate that interfered with her right mandibular body, which restricted the degree to which she could open her mouth. A thorough clinical examination and accurate radiographic interpretation combined with a complete medical history can minimize these types of diagnostic delays. If the dentist is unable to conclusively reach a diagnosis, the patient should be referred immediately to a specialist who can better manage the specific medical problem.

Keywords: Diagnosis; Maxillofacial; Non-Hodgkin's lymphoma; TMJ

© 2017 The Authors.

Production and hosting by Elsevier Ltd on behalf of Taibah University. This is an open access article under the CC BY-NC-ND license (<http://creativecommons.org/licenses/by-nc-nd/4.0/>).

* Corresponding address: Department of Oral and Basic Clinical Sciences, College of Dentistry, Taibah University, Almadinah Almunawwarah, KSA.

E-mail: ebtihalh@gmail.com (E.H. Zain-Alabdeen)

Peer review under responsibility of Taibah University.



Production and hosting by Elsevier

Introduction

Oral and maxillofacial radiology plays a dynamic and comprehensive role in patient care. Pre- and postdoctoral dental and radiology students not only prescribe, obtain

and interpret radiographs, but they also diagnose diseases and develop treatment plans for temporomandibular joint (TMJ) disorders, implants, trauma, pathologies, orthognathic surgery and craniofacial abnormalities. Proper education of students with respect to biomedical and clinical knowledge, cognitive and psychomotor skills, and professional and ethical values is essential. Hence, it is important to develop an active and successful education program for students, as well as a reliable protocol for referring to and consulting with oral and maxillofacial radiologists.^{1,2}

Current imaging techniques include digital intra-oral radiographs, dental panoramic tomography, multi-detector helical computed tomography (CT) and magnetic resonance imaging (MRI). Although CT scanners were used for maxillofacial bone and soft tissue imaging in the 1980s and 1990s, the introduction of cone beam CT (CBCT) in the new millennium revolutionized the use of CT for dental and maxillofacial diagnostics. CBCT has become the modality of choice for all diagnostic and treatment planning in dentistry because it overcomes the need to superimpose plane radiographs of the complex cranio-facial structures.³⁻⁵

While the introduction of CBCT ushered in a new age of radiographic diagnostic imaging, it also introduced more complications in terms of patient health and legal issues. Misdiagnosis or a delay in diagnosis can occur if the dentist does not refer the patient to a maxillofacial radiologist for a suspected lesion or when an incidental finding is missed because it is outside the area of interest. Several studies have reported examples of misdiagnosis or delayed diagnosis in the maxillofacial region of a pathological⁶⁻⁸ or traumatic⁹⁻¹¹ nature occurring during or after dental treatment. Such misdiagnoses affect patient health and can cause medicolegal problems for dental professionals. A number of studies have also demonstrated that being able to visualize oral and maxillofacial pathologic entities in three dimensions assists in diagnosing and planning the appropriate treatment for the patient and minimizes misdiagnosis in the maxillofacial region.^{10,12,13}

For these reasons, it is important to prevent these delays or misdiagnosed cases by addressing the gap in knowledge. The need for good clinical and radiographic examinations should be emphasized, along with continuing education for any emerging medical and dental technologies used as diagnostic aids in this critical area.

We present two cases of delayed diagnosis in the maxillofacial region that caused prolonged morbidity or affected the prognosis of the patients.

Case 1

A 49-year-old woman with no significant past medical history reported to the Emergency Department in King Saud Medical City (KSMC) with a large swelling on the left side of her face that involved the entire cheek and obliterated the nasolabial fold (Figure 1). The swelling was soft to firm ("rubbery") in consistency with no obvious puffy oedema. The intra-oral vestibule was obliterated, with involvement of the left maxillary alveolar ridge.

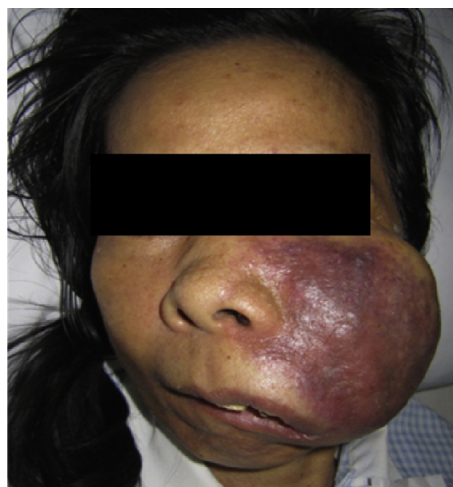

Figure 1: When the patient arrived at the Emergency Department, reddish-blue swelling occupied the left side of her face.

The swelling was present one month before the patient was admitted to the Emergency Department. She had visited four private dental clinics, but, according to the patient, none of them enquired about her medical history. The first three dentists prescribed oral and IV antibiotics, and the fourth dentist performed an incision and drainage and prescribed antibiotics. Thus, no medical history was obtained with regard to signs or symptoms of cancer (such as weight loss, night sweats, fever) that would promote further investigations. Though abscesses are usually soft, red, swollen areas that contain purulent discharge and are tender to touch, in this case, the swelling had a rubbery consistency. Because of this discrepancy, the patient should have been referred to a maxillofacial surgeon earlier for fine needle aspiration or to a physician for blood testing, peripheral lymph node examination and advanced imaging. The panoramic radiograph that was obtained previously had not been carefully interpreted. As shown in Figure 2, the shadow of soft tissue swelling with diffuse alveolar bone destruction in the radiograph was not associated with carious tooth or a periodontal pocket and should have indicated non-odontogenic disease.

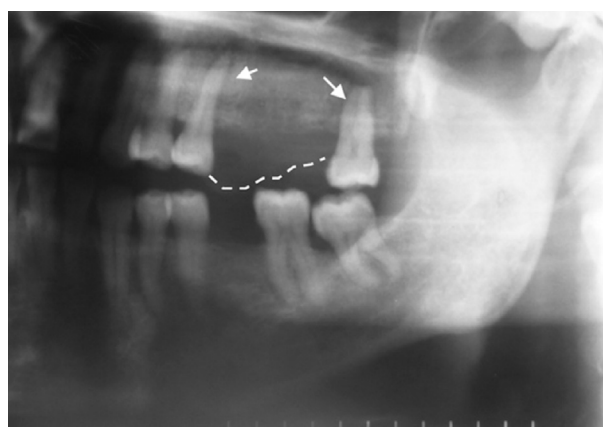


Figure 2: Panoramic view shows the shadow of soft tissue swelling (dashed line) with diffuse alveolar bone destruction (arrows) that are not related to a carious tooth or periodontal pocket.

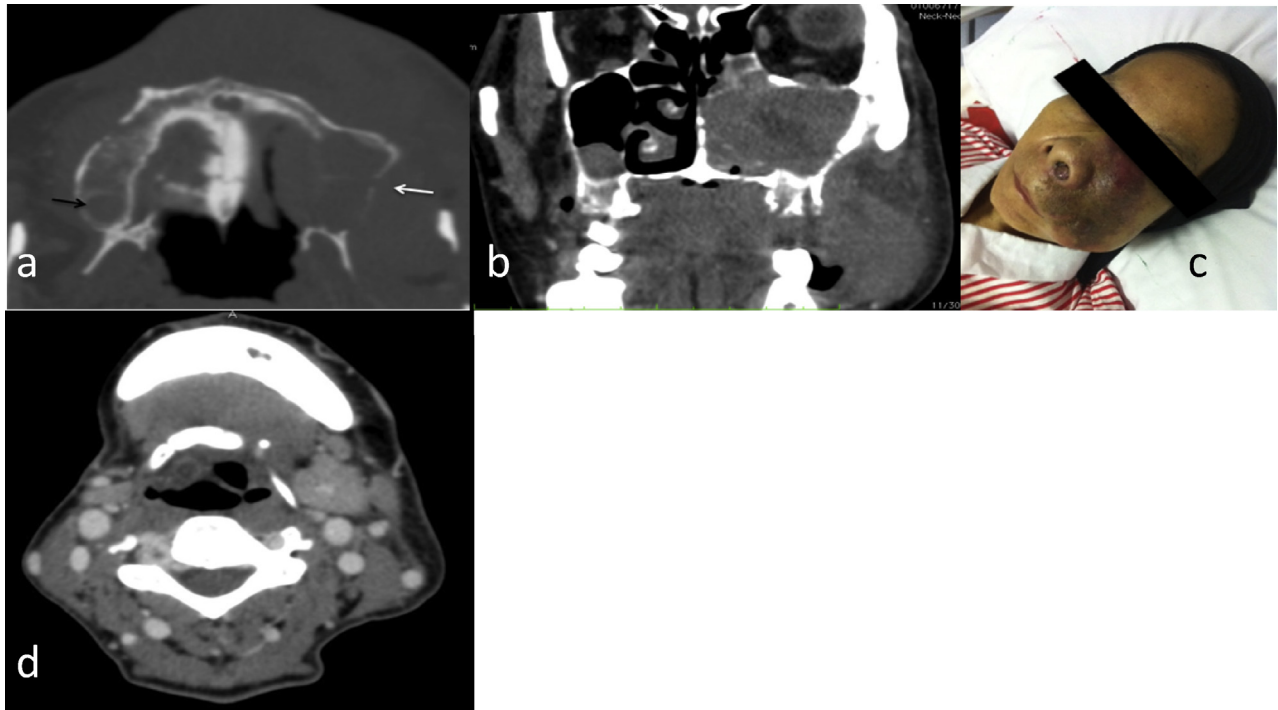


Figure 3: (a) Axial computed tomography (CT) bone window shows ill-defined alveolar bone destruction (white arrow) with a similar lesion starting on the right side (black arrow). (b) Coronal CT soft tissue window shows a large subcutaneous homogenous mass involving the left side of the face, including the left side of the nose, cheek and mandible, complete opacification of the left maxillary sinus, and mucosal thickening of the contralateral maxillary sinus. The left intra-maxillary soft tissue is enlarged, expanding the boundaries of the left maxillary sinus and involving the anterior inferior portion of the left orbit abutting the inferior surface of the left eye globe, as seen clinically in (c). (d) Axial CT with contrast shows the largest volume at the left submandibular and left jugulodigastric lymph nodes (level II LN).

When fine needle aspiration was performed in KSMC, it revealed that the patient had non-Hodgkin's lymphoma (NHL) involving the maxilla. Radiographic CT images of the case are presented in [Figure 3](#).

Discussion

This case is similar to other reported cases in which patients presented to a dental clinic complaining of pain in the upper jaw and were initially treated for an odontogenic infection before more extensive exploration established a diagnosis of lymphoma.^{14,15} Other unusual presentations of NHL of the maxilla and palate were diagnosed by dentists when they combined radiographic features with clinical examination.^{6,16} Buchanan et al. reported a similar case with radiographic signs consistent with a malignant process. These included loss of cortical density in the floor of the maxillary sinus, widening of the periodontal ligament (PDL) space around otherwise intact teeth, spread into the adjacent soft tissues without cortical expansion, and radiographically normal teeth.⁶ In our patient, two of these signs were present as shown in [Figure 2](#), namely, widening of the PDL space around intact teeth and spread into soft tissues without cortical expansion.

In another study of 15 cases of oral lymphoma, the hard palate and alveolus were the most common sites (five cases each). The median age at presentation was 42.6 years. The vast majority (12 of 15 cases) were diagnosed with NHL. Most patients (70%) reported having painless progressive

swelling without systemic signs such as fever, weight loss, and so on.¹⁷ In our patient, had these systemic signs been present, they could have alerted the dentist to undertake further investigation.

The most common affected oral location of NHL is the upper jaw (maxilla or palatal bone) in 28% of cases, followed by the mandible (20%), palatal soft tissue (20%) and vestibule and gingivae (17%). The most frequent presenting signs are swelling, ulceration and radiographic destruction of bone.¹⁸

Oral NHL is relatively rarely encountered in everyday practice and is difficult to diagnose in a clinical setting because it presents as local swelling, pain and discomfort and mimics a number of other conditions such as pyogenic granuloma, periodontal disease, osteomyelitis and other malignancies.¹⁹ Sometimes, an oral lesion may present as secondary widespread involvement throughout the body or as early disease (primary site).

Despite its rare occurrence, dentists must consider lymphoma in the differential diagnosis of pain, swelling, ulceration and non-healing periapical inflammation. In general, dentists should undertake a thorough medical history of the patient and perform clinical and radiographic examinations, with a high index of suspicion for lesions that do not respond to conventional therapy or appear unusual in other ways. Thus, dentists should play a role in the early diagnosis and prompt referral of patients to specialists for secondary care so that the patients will receive treatment at an early stage and improve their chances of having a better prognosis.

Case 2

A 9-year-old patient presented to the clinic with her mother. The mother offered a detailed history, claiming that her daughter had fallen when she was 1 year and 4 months old and had sustained an upper limb fracture, with no other fractures detected. She reported that, subsequently, her daughter had several illnesses, contracted herpes simplex virus, developed eye problems requiring eye surgery. During that time, because the patient was bottle and spoon fed, the limited mouth opening went unnoticed until she turned 3 years old. When she had a flu-like illness, the physician noticed the limited mouth opening during an examination of her tonsils and referred her to a general practitioner dentist who in turn referred her to an oral surgeon. The oral surgeon made a diagnosis of muscle spasm and prescribed exercises to improve her mouth opening. The patient performed the exercises for 2 years with minimal improvement: only a 2–3 mm increase in opening with continued relapses (Figure 4). When the patient turned 7 years old, an MRI was requested for further evaluation (Figure 5) as part of the standard evaluation when an internal structural joint abnormality is suspected.²⁰ A CT scan was also performed, which, according to the mother, showed no abnormality.

A maxillofacial radiologist at KSMC requested a second CT scan after the patient arrived at the clinic, with the justification that, according to the literature, children as young as 3 years old can have a CT scan of the head if a head injury is suspected.²¹ Because the patient was 9 years old and suffered from poor nutrition because of her limited mouth opening, the only thing that could be done at that stage was to perform another CT scan to rule out any problems due to the original trauma. The radiograph revealed two problems: 1) osteoarthritic changes of the TMJ (Figure 6a) with the superior surface of the mandibular condylar heads on both sides showing a loss of cortical outline, suggestive of degenerative joint disease, and 2) elongation of the lateral pterygoid plate, which explained the limited mouth opening as shown in Figure 6b–d. Which of these problems came first is unknown, though both could have been either sequelae to the trauma or related to one another. The limited mouth opening was caused by an uncommon elongation of the right lateral pterygoid plate, which functionally resulted in a defect in the lingual aspect

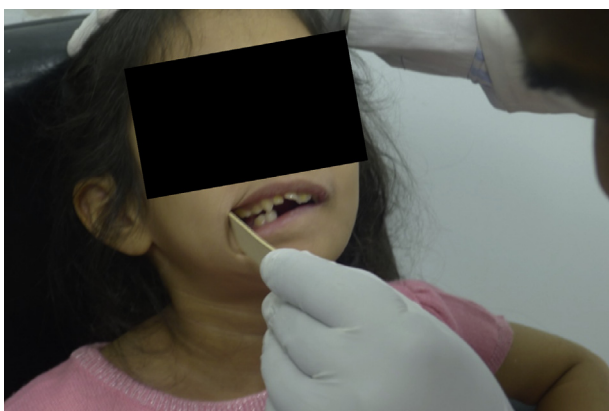

Figure 4: The patient with maximum mouth opening of approximately 2–3 mm.

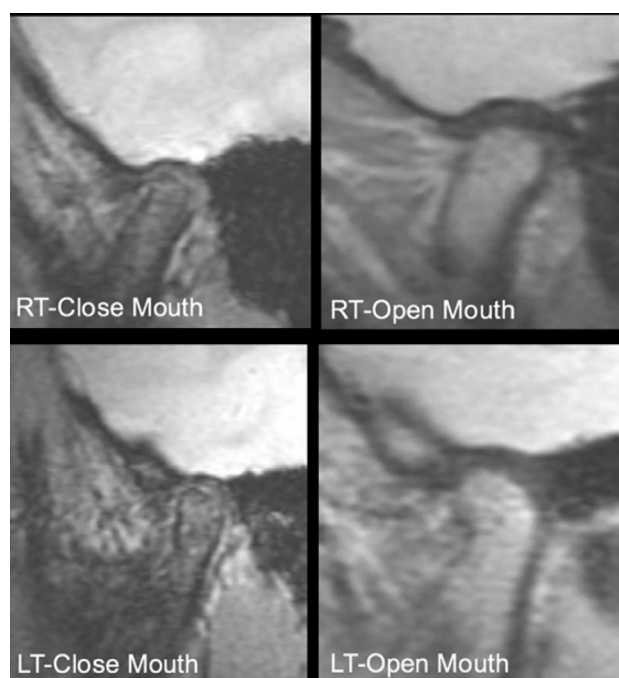


Figure 5: Proton density MR images of temporomandibular joints show the articular disks displayed anteriorly in the closed mouth position bilaterally. They appear thin and flat, mostly due to degenerative joint disease. Proton density MR images of an open mouth show minimal rotational and translational movement, with the disks continuing to be in an anterior position.

of the right mandibular body. This elongation was involved in the undercut of the defect, causing pseudoankylosis of the TMJ and resulting in limited mouth opening.

Discussion

Pseudoankylosis of the TMJ is a rare, extra-articular form of ankylosis of the jaw. It is characterized by mandibular hypomobility caused by an extrinsic condition of the joint that results in fusion between the coronoid process and the temporal,²² zygomatic^{23,24} or maxillary bone.²⁵

Pseudoankylosis is less frequent than the intracapsular form. Exact figures for the incidence of ankyloses and pseudoankyloses of the TMJ in the general population are not available in the literature. Pseudoankylosis can be congenital or acquired and complicates up to 0.6% of undiagnosed zygomatic fractures. Approximately 88% of cases of pseudoankylosis are associated with a history of trauma.²⁶ Traumas, with or without fracture, including surgery, can induce the formation of fibrous or scar tissue adhesion in the temporal and masseter muscles.²⁷ The diagnosis is based on clinical and radiological evaluations. A CT scan is usually requested to confirm the diagnosis because it can detect bony fusion, thus differentiating pseudoankylosis from true ankylosis. Because CT scans do not provide sufficient information about soft tissue disorders, an MRI may be indicated when fibrous tissue formation is suspected.²⁸ Once symptomatic bone ankylosis is diagnosed, surgery with postoperative physiotherapy is the recommended treatment.²⁶

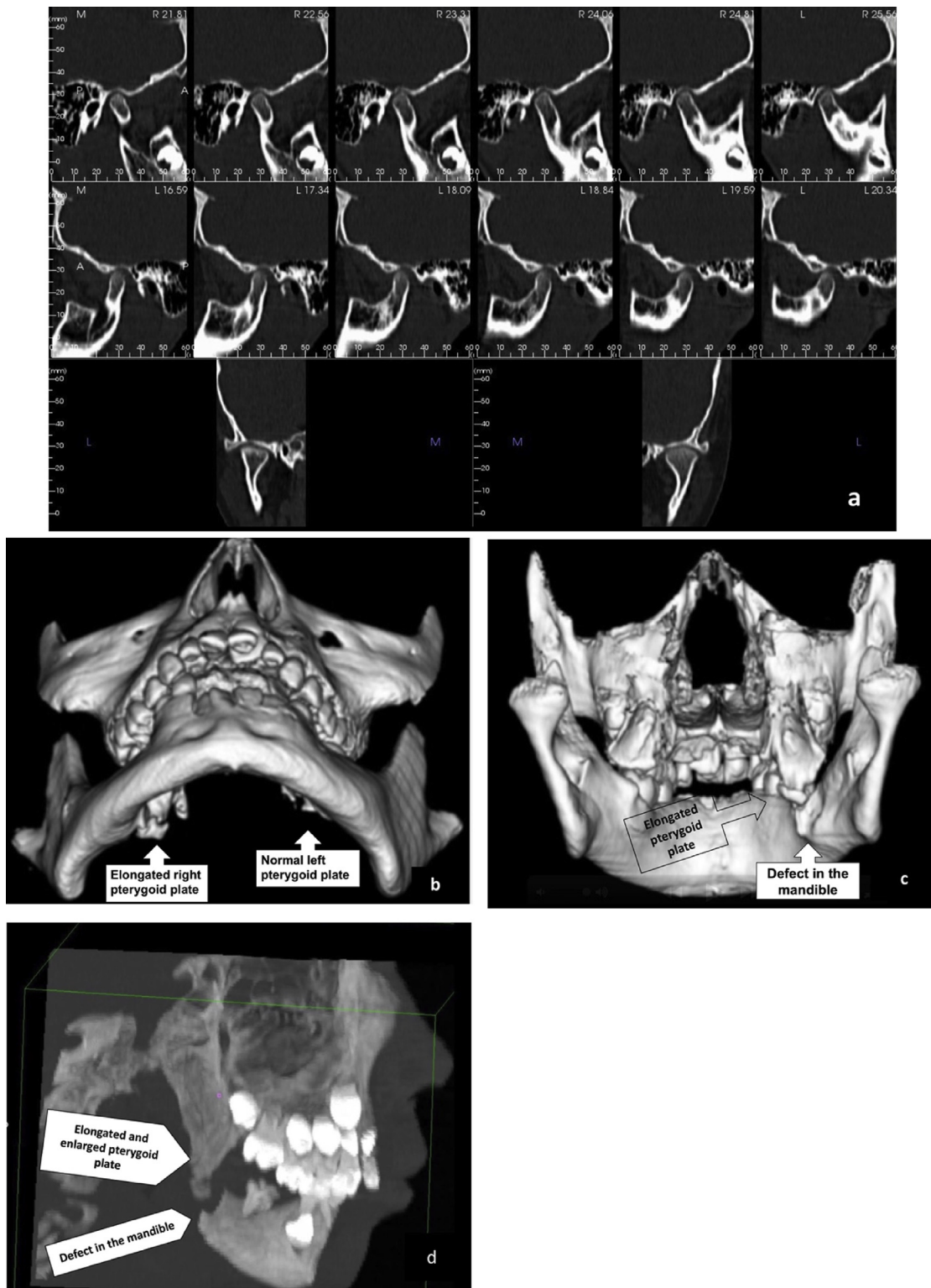


Figure 6: (a) Top row: sagittal views show a flattened left condyle, reduced articular eminence and joint space, and forward position of the condyle within the glenoid fossa. Middle row: sagittal views show erosion and discontinuity in the right glenoid fossa of the temporal bone, reduced articular eminence and reduced joint space. Bottom row: coronal section shows flattening of the superior surface of the left condyle, erosion of the superior surface of the right condyles and erosion of the right glenoid fossa. (b) Three-dimensional view shows elongated right pterygoid plate approaching the lower border of the mandible. (c) Three-dimensional posterior view of the enlarged lateral pterygoid that is causing a defect in the lingual aspect of the right mandibular body (arrow). (d) Reformatted oblique sagittal view shows how this elongation can be engaged in the undercut of the defect, causing limited mouth opening.

Osteoarthritis of the TMJ is thought to be an age-related disorder that is more frequently found in older people. However, one study reported evidence of degenerative arthritis in 37% of cases in a paediatric age group with TMJ pain and dysfunction.²⁹ This percentage is higher if one takes into account osteoarthritic changes caused by trauma in children,³⁰ because facial trauma in the paediatric population represents between 1.4% and 15% of all maxillofacial traumas. Such traumas go mostly undiagnosed and are consequently untreated, causing growth disturbances that show up years later. Clinicians must focus on these types of trauma carefully, not only because they cause direct damage to osseous structures but also because they lead to future disturbances in dentofacial development.³¹

In the present case, limited mouth opening was caused by an uncommon elongation of the right lateral pterygoid plate, functionally resulting in a defect in the lingual aspect of the right mandibular body. Only one case of limited mouth opening due to pseudoankylosis between the pterygoid plate and mandible has been previously reported.³² However, studies have reported pseudoankylosis of the TMJ caused by zygomatic malformation,²⁸ coronoid process hyperplasia³³ or fusion between the coronoid process and the temporal,²² zygomatic^{23,24} or maxillary bone.²⁵

TMJ ankylosis is one of the most overlooked and undermanaged problems in children. The TMJ forms the very cornerstone of cranio-facial integrity. As a result, ankylosis in growing children adversely affects growth and development of the jaws and leads to occlusion disturbance, speech impairment, difficulty in mastication, poor oral hygiene and rampant caries.³⁴

General practitioners and paediatric dentists are often the first clinicians to recognize late complications of facial trauma years after the injury has occurred by undertaking a proper history and performing a clinical and radiographic examination. The use of advanced imaging modalities consequently allows dentists and maxillofacial radiologists to diagnose these difficult problems.³⁵

Conclusion

These two cases of delayed diagnosis, along with the cases reported in the literature, emphasize that some problems are difficult to diagnose, either because they mimic other common diseases as in the first case, or because the problem is outside the area of interest as in the second case. A thorough clinical examination and radiographic interpretation along with procuring a complete medical history can minimize the delay in diagnosis. If the dentist cannot reach a diagnosis, the patient should be referred immediately to a specialist who can manage the specific medical problem.

Funding

There was no funding for this case report study.

Authors' contribution

EHZ collected the two cases, wrote literature review for both cases, discussions and conclusions. RIA wrote for case report 2 the description and radiographic interpretations.

FSA wrote the medical history and examination for case 2. KMA wrote the examinations and investigations for case 1. All authors have critically reviewed and approved the final draft and are responsible for the content and similarity index for the manuscript.

Conflict of interest

The authors have no conflict of interest to declare.

References

1. Kantor ML, Beideman RW, Benn DK, Geist JR, Hollender LG, Ludlow JB, et al. Characteristics of an oral and maxillofacial radiology department. Report of the ad hoc Department Characteristics Committee of the American Academy of Oral and Maxillofacial Radiology. *Oral Surg Oral Med Oral Pathol Oral Radiol Endod* 1997; 84(6): 708–712.
2. Ouyang T, Branstetter B. Advances in head and neck imaging. *Oral Maxillofac Surg Clin North Am* 2010; 22(1): 107–115.
3. Boeddinghaus R, Whyte A. Current concepts in maxillofacial imaging. *Eur J Radiol* 2008; 66(3): 396–418.
4. Matteson SR, Deahl ST, Alder ME, Nummikoski PV. Advanced imaging methods. *Crit Rev Oral Biol Med* 1996; 7(4): 346–395.
5. Shah N, Bansal N, Logani A. Recent advances in imaging technologies in dentistry. *World J Radiol* 2014; 6(10): 794–807.
6. Buchanan A, Kalathingal S, Capes J, Kurago Z. Unusual presentation of extranodal diffuse large B-cell lymphoma in the head and neck: description of a case with emphasis on radiographic features and review of the literature. *Dentomaxillofac Radiol* 2015; 44(3): 20140288.
7. Singh T, Schenberg M. Delayed diagnosis of oral squamous cell carcinoma following dental treatment. *Ann R Coll Surg Engl* 2013; 95(5): 369–373.
8. Fang Z, Jin S, Zhang C, Wang L, He Y. Misdiagnosis of osteosarcoma as cementoblastoma from an atypical mandibular swelling: a case report. *Oncol Lett* 2016; 11(6): 3761–3765.
9. Yilmaz SY, Misirlioglu M, Adisen MZ. A diagnosis of maxillary sinus fracture with cone-beam CT: case report and literature review. *Cranio-maxillofac Trauma Reconstr* 2014; 7(2): 85–91.
10. Dolekoglu S, Fisekcioglu E, Ilguy D, Ilguy M, Bayirli G. Diagnosis of jaw and dentoalveolar fractures in a traumatized patient with cone beam computed tomography. *Dent Traumatol* 2010; 26(2): 200–203.
11. DeFabianis P. TMJ fractures in children: clinical management and follow-up. *J Clin Pediatr Dent* 2001; 25(3): 203–208.
12. Guttenberg SA. Oral and maxillofacial pathology in three dimensions. *Dent Clin North Am* 2008; 52(4): 843–873, viii.
13. Closmann JJ, Schmidt BL. The use of cone beam computed tomography as an aid in evaluating and treatment planning for mandibular cancer. *J Oral Maxillofac Surg* 2007; 65(4): 766–771.
14. Saund D, Kotecha S, Rout J, Dietrich T. Non-resolving periapical inflammation: a malignant deception. *Int Endod J* 2010; 43(1): 84–90.
15. Martinelli-Klay CP, Martinelli CR, Martinelli C, Dias JB, Cheade TC, Lombardi T. Primary extranodal non-Hodgkin lymphoma of the gingiva initially misdiagnosed as dental abscess. *Quintessence Int* 2009; 40(10): 805–808.
16. Nadendla LK, Meduri V, Paramkusam G. Imaging characteristics of diffuse large cell extra nodal non-Hodgkin's lymphoma involving the palate and maxillary sinus: a case report. *Imaging Sci Dent* 2012; 42(2): 111–114.

17. Shah GH, Panwar SK, Chaturvedi PP, Kane SN. Isolated primary extranodal lymphoma of the oral cavity: a series of 15 cases and review of literature from a tertiary care cancer centre in India. **Indian J Med Paediatr Oncol** 2011; 32(2): 76–81.
18. Kemp S, Gallagher G, Kabani S, Noonan V, O'Hara C. Oral non-Hodgkin's lymphoma: review of the literature and World Health Organization classification with reference to 40 cases. **Oral Surg Oral Med Oral Pathol Oral Radiol Endod** 2008; 105(2): 194–201.
19. Shaikh AB, Waghmare S, Koshti-Khude S, Koshy AV. Unusual presentation of non-Hodgkin's lymphoma: case report and review of literature. **J Oral Maxillofac Pathol** 2016; 20(3): 510–517.
20. Bag AK, Gaddikeri S, Singhal A, Hardin S, Tran BD, Medina JA, et al. Imaging of the temporomandibular joint: an update. **World J Radiol** 2014; 6(8): 567–582.
21. Zaman S, Logan PH, Landes C, Harave S. Soft-tissue evidence of head injury in infants and young children: is CT head examination justified? **Clin Radiol** 2017; 72(4): 316–322.
22. Kamata S, Satoh K, Uemura T, Onizuka T. Congenital bilateral zygomatico-mandibular fusion with mandibular hypoplasia. **Br J Plast Surg** 1996; 49(4): 251–253.
23. Agarwal M, Gupta DK, Tiwari AD, Jakhhar SK. Extra-articular ankylosis after zygoma fracture; a case report & review of literature. **J Oral Biol Craniofac Res** 2013; 3(2): 105–107.
24. Akhlaghi F, Esmaeelinejad M. Limitation of mandibular movement: a rare case report of unilateral zygomatico-coronoid interference. **Trauma Mon** 2016; 21(1): e26225.
25. Super S, Cotten Jr JS. Bilateral pseudoankylosis of the temporomandibular joint due to synostoses between the mandible and maxilla. **J Oral Maxillofac Surg** 1982; 40(9): 590–592.
26. Allevi F, Battista V, Moneghini L, Biglioli F. Two typical cases of pseudoankylosis of the jaw: same treatment, different outcome. **BMJ Case Rep** 2015; 2015.
27. Gundlach KK. Ankylosis of the temporomandibular joint. **J Craniomaxillofac Surg** 2010; 38(2): 122–130.
28. Baraldi CE, Martins GL, Puricelli E. Pseudoankylosis of the temporomandibular joint caused by zygomatic malformation. **Int J Oral Maxillofac Surg** 2010; 39(7): 729–732.
29. Ishibashi H, Takenoshita Y, Ishibashi K, Oka M. Age-related changes in the human mandibular condyle: a morphologic, radiologic, and histologic study. **J Oral Maxillofac Surg** 1995; 53(9): 1016–1023. discussion 23–4.
30. Giannakopoulos HE, Quinn PD, Granquist E, Chou JC. Posttraumatic temporomandibular joint disorders. **Craniomaxillofac Trauma Reconstr** 2009; 2(2): 91–101.
31. Defabianis P. TMJ fractures in children: importance of functional activation of muscles in preventing mandibular asymmetries and facial maldevelopment. **Funct Orthod** 2002; 19(2): 34–42.
32. Super S, Cotton JS. A case of pseudoankylosis between the pterygoid plate and mandible. **J Oral Maxillofac Surg** 1986; 44(6): 467–468.
33. Costa YM, Porporatti AL, Stuginski-Barbosa J, Cassano DS, Bonjardim LR, Conti PC. Coronoid process hyperplasia: an unusual cause of mandibular hypomobility. **Braz Dent J** 2012; 23(3): 252–255.
34. Shashikiran ND, Reddy SV, Patil R, Yavagal C. Management of temporo-mandibular joint ankylosis in growing children. **J Indian Soc Pedod Prev Dent** 2005; 23(1): 35–37.
35. Mulroy MH, Loyd AM, Frush DP, Verla TG, Myers BS, Bass CR. Evaluation of pediatric skull fracture imaging techniques. **Forensic Sci Int** 2012; 214(1–3): 167–172.

How to cite this article: Zain-Alabdeen EH, Al-Sadhan RI, AlSuhaim FS, AlMutairi KM. Delayed diagnosis in the maxillofacial region: Two case reports. *J Taibah Univ Med Sc* 2017;12(6):548–554.