

# Early Experience With Laparoscopic Pyloromyotomy in a Teaching Institution

Richard J. Hendrickson, MD, Sherman Yu, MD, Jennifer L. Bruny, MD, David A. Partrick, MD, John K. Petty, MD, Denis D. Bensard, MD

## ABSTRACT

**Objective:** Hypertrophic pyloric stenosis is a common pediatric surgical condition. A Ramstedt pyloromyotomy is performed either via laparotomy or laparoscopy. We report our first 25 cases of laparoscopic pyloromyotomy at an academic children's hospital.

**Methods:** From January 2002 through February 2003, we retrospectively reviewed our first 25 laparoscopic pyloromyotomies. All patients had documented hypertrophic pyloric stenosis by ultrasound criteria. Three incisions were made, one 5-mm umbilical port, one 3-mm right upper quadrant port, and a third left upper quadrant working stab incision. A 4-mm, 30° scope was used in all cases. A longitudinal pyloromyotomy was performed using an arthrotomy scalpel. The pylorus was further separated with a laparoscopic Benson spreader. At the completion of the pyloromyotomy, the stomach was insufflated with air to identify any mucosal injury.

**Results:** Age range was 2.3 weeks to 8.4 weeks. Operating time has decreased from 70 minutes to 15 minutes. Two conversions to an open procedure were necessary, both during the first 10 cases. No mucosal perforations or incomplete pyloromyotomies have occurred. Feeds were started within 4 hours and advanced to goal. Time to discharge ranged from 12 hours to 30 hours. One patient developed umbilical cellulitis that was successfully treated with antibiotics.

**Conclusions:** Laparoscopic pyloromyotomy is a safe, effective procedure for hypertrophic pyloric stenosis in a resident teaching environment. Laparoscopy permits excellent visualization, has comparable postoperative recovery, and superior cosmesis.

**Key Words:** Laparoscopy, Pyloromyotomy.

## INTRODUCTION

Hypertrophic pyloric stenosis (HPS) is a common pediatric surgical condition. Open pyloromyotomy as described by Ramstedt in 1911 has remained the definitive treatment for this condition with excellent results.<sup>1</sup> In 1991, Alain<sup>2</sup> described a laparoscopic approach for performing a pyloromyotomy. Since then, several studies have shown comparative safety and efficacy of the laparoscopic approach compared with the open technique, although there have been concerns of increased mucosal perforations or incomplete myotomies.<sup>3-6</sup> Due to the increased interest in minimally invasive pediatric surgery by parents and pediatricians, more pediatric surgeons are performing laparoscopic pyloromyotomies. The aim of this report is to describe our initial experience with this minimally invasive technique in a resident teaching environment. Herein, we report our first 25 cases of laparoscopic pyloromyotomy performed at an academic children's hospital.

## METHODS

From January 2002 through February 2003, the medical records of our first 25 laparoscopic pyloromyotomies were retrospectively reviewed. Age, operative time, intraoperative complications (duodenal injury or mucosal perforation), postoperative complications (incomplete pyloromyotomy, incisional hernia, wound infection, or readmission), and time to discharge were all evaluated. A pediatric surgery fellow performed 20 of the 25 procedures. All patients had documented HPS by ultrasound criteria (thickness > 4 mm and length > 14 mm). Intravenous fluid resuscitation was performed to correct metabolic alkalosis to allow safe anesthesia administration.

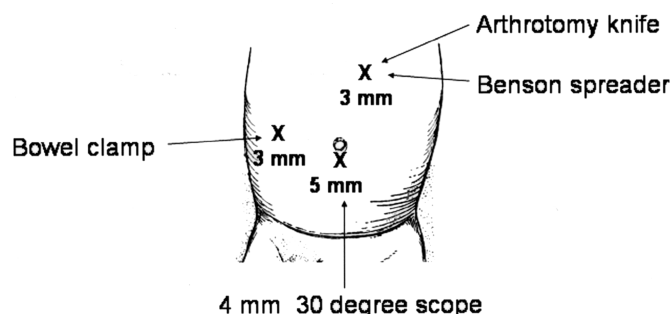
With the patient under general anesthesia, a 5-mm umbilical port is placed using an open technique. This port allows introduction of the 4-mm, 30° scope. Under direct vision, a 3-mm right upper quadrant port is placed, and a left epigastric working stab incision is made (**Figure 1**). The duodenum is stabilized using an atraumatic grasper

Department of Pediatric Surgery, The Children's Hospital/The University of Colorado Health Science Center, Denver, Colorado, USA (all authors).

Presented at the 12th International Congress and Endo Expo 2003, SLS Annual Meeting, Las Vegas, Nevada, USA, September 22-25, 2003.

Address reprint requests to: Richard J. Hendrickson, MD, The Children's Hospital, Department of Pediatric Surgery, 1056 East 19th Ave, B323, Denver, CO 80218, USA. Telephone: 303 861 6530, Fax: 303 764 8077, E-mail: Hendrickson.richard@tchden.org

© 2005 by JSLS, *Journal of the Society of Laparoendoscopic Surgeons*. Published by the Society of Laparoendoscopic Surgeons, Inc.



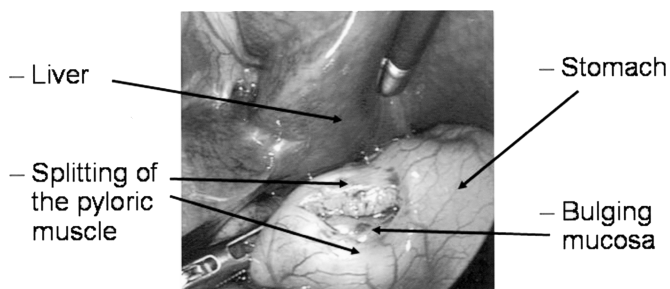
**Figure 1.** Diagram illustrating location of incisions and instruments used.

placed into the right upper quadrant port. A disposable, retractable arthrotomy scalpel is inserted via the left epigastric site and utilized for the seromuscular longitudinal incision in the hypertrophied pylorus. This incision is made in an avascular plane from the vein of Mayo distally to the thinned antral muscle proximally. With the blade retracted, the knife sheath is used to widen the incision and break apart the muscle fibers. This then allows adequate purchase for the pyloric spreader to complete the pyloromyotomy, evident by ballooning of the underlying mucosa and independent movement of the 2 edges of the myotomy (**Figure 2**). Upon completion of the pyloromyotomy, the stomach is insufflated with air via a nasogastric tube to confirm mucosal integrity. Feeds are started 4 hours postoperatively and advanced to goal as tolerated. Patients are discharged home when tolerating goal feeds.

This study was reviewed and approved by the Colorado Multiple Institutional Review Board (COMIRB #04-0503).

## RESULTS

The age of patients ranged from 2.3 weeks to 8.4 weeks with a mean of 5.3 weeks. Operating times decreased from 70 minutes early in the series to 15 minutes as experience was gained. The average operative time dur-



**Figure 2.** Laparoscopic view of a completed pyloromyotomy with bulging mucosa.

ing these first 25 cases was 30.9 minutes. The operating time was defined as from the “cut” time until the “close” time, when the dressings have been applied. A pediatric surgery fellow or general surgery resident was involved in all cases. Twenty of the 25 cases were performed entirely by the pediatric surgery fellow. Three of the cases had a senior resident perform most of the procedure, with the attending completing the pyloromyotomy to ensure a satisfactory result.

Two early cases had to be converted to an open procedure by the same surgeon. During that surgeon’s second case, conversion to an open procedure occurred because of a serosal injury to the duodenum during positioning of the grasper. No underlying mucosal injury was identified, and the serosa was reapproximated after opening. The second case involved diagnosis of an early pyloric stenosis with a thickness of only 3 mm noted after opening. The reason for open conversion was due to an inability to gain adequate purchase with the pyloric spreader and subsequent concern for mucosal injury. This was the surgeon’s fourth case, with an operative time of 70 minutes. Eliminating the 2 converted cases, the operative time averaged 28.7 minutes.

No mucosal perforations or incomplete pyloromyotomies occurred during this series. One patient did develop umbilical cellulitis that was successfully treated with antibiotics. No other postoperative complications occurred. Time to discharge ranged from 12 hours to 30 hours.

## DISCUSSION

In a resident teaching environment, we were able to introduce a novel technique into our practice safely and effectively. Two of the first 10 cases were converted to an open procedure, but no conversions were necessary in the following 15 cases resulting in an overall conversion rate of 8%. The first converted case involved a serosal injury to the duodenum (second case overall), and the second converted case involved a hypertrophic muscle of only 3 mm that could not be safely divided via the laparoscopic approach. The other complication in this series was a superficial umbilical wound infection, for a wound infection rate of 4%. Mucosal perforation, duodenal perforation, and incomplete pyloromyotomies were avoided during our early experience. Additionally, we have not had any incisional hernias or readmissions. The reported results from another academic children’s hospital were 8% mucosal perforation, 2% duodenal perforation, 2% incomplete pyloromyotomy, 5% wound infection, and 8% con-

version to open.<sup>5</sup> Our initial experience with this procedure has shown comparable outcomes.

Initially, the laparoscopic approach is challenging to learn and has a significant learning curve as evident by the longer operative times. However, the operative times quickly decreased as this technique was more frequently performed. As the attending surgeons became more familiar with this approach, the fellows and residents became more involved with the procedure. The pediatric surgery fellow performed 20 of the 25 procedures completely, and senior residents performed a majority of the procedure in 3 cases. As with learning any new laparoscopic procedure, complications and conversions to open cases are more evident at the beginning of the learning curve. After 2 early laparoscopic pyloromyotomies were converted to open, no further conversions were necessary.

Two key points are important for this operation. The first is an accurate seromuscular incision over the hypertrophied pylorus that is straight and with enough depth to allow for the Benson spreader to have a good purchase of pyloric tissue. Repeat incisions with the arthrotomy scalpel into this area can then lead to increased complications, and railroading or skiving of the pyloric muscle, increasing the difficulty to perform the myotomy.

The second involves knowing the strength and depth to spread with the pyloric spreader. The edges must be spread widely with thinning of the fibers seen at the proximal and distal end to assure a complete myotomy. Overly aggressive spreading can lead to mucosal perforation, especially near the duodenal end where the mucosa becomes more superficial. Passive spreading and a short pyloromyotomy can result in an incomplete pyloromyotomy.

Laparoscopy permits excellent visualization of the mucosa underlying the pyloric muscle. With air insufflation of the stomach at the end of the procedure, we can accurately determine the presence or absence of a mucosal perforation, although none were identified in this study. If a mucosal injury were present, this would allow immediate repair of the injury and prevent the morbidity of a delayed presentation of a mucosal perforation.

Moreover, laparoscopy provides superior cosmesis when compared with the standard transverse incision. In addition, laparoscopy allows diagnostic evaluation of the peritoneum. The internal inguinal ring can be assessed for a patent processus vaginalis and surgery recommended if

needed. Also, hemostasis of the pyloromyotomy is confirmed laparoscopically, before completion of the procedure.

Due to the increased interest in minimally invasive pediatric surgery by parents and pediatricians, more pediatric surgeons are performing laparoscopic pyloromyotomies. Although not all pediatric surgeons perform the laparoscopic approach, we feel it is as safe and effective as the standard right upper quadrant operation. We have no experience with the supraumbilical approach, although a report has demonstrated an “intraabdominal pyloromyotomy” through a supraumbilical approach when there was difficulty delivering a large pyloric tumor through the supraumbilical incision.<sup>7</sup> When laparoscopy is utilized, the pyloromyotomy is performed intraabdominally, thus avoiding the potential difficult delivery of a large pyloric tumor through a supraumbilical incision.

## CONCLUSION

Based on our early experience, laparoscopic pyloromyotomy can be safely and effectively introduced into an academic children’s hospital for the treatment of hypertrophic pyloric stenosis.

## References:

1. Ramstedt C. Zur operation der angelborenen pylorus-stenose. *Med Klin.* 1912;8:1702–1705.
2. Alain JL, Grousseau D, Terrier G. Extramucosal pyloromyotomy by laparoscopy. *Surg Endosc.* 1991;5(4):174–175.
3. Fujimoto T, Lane GJ, Segawa O, Esaki S, Miyano T. Laparoscopic extramucosal pyloromyotomy versus open pyloromyotomy for infantile hypertrophic pyloric stenosis: which is better? *J Pediatr Surg.* 1999;34(2):370–372.
4. Scorpio RJ, Tan HL, Hutson JM. Pyloromyotomy: comparison between laparoscopic and open surgical techniques. *J Laparoendosc Surg.* 1995;5(2):81–84.
5. Campbell BT, McLean K, Barnhart DC, Drongowski RA, Hirschl RB. A comparison of laparoscopic and open pyloromyotomy at a teaching hospital. *J Pediatr Surg.* 2002;37(7):1068–1071.
6. Hulka F, Harrison MW, Campbell TJ, Campbell RJ. Complications of pyloromyotomy for infantile hypertrophic pyloric stenosis. *Am J Surg.* 1997;173(5):450–452.
7. De Caluwe D, Reding R, de Ville de Goyet J, Otte JB. Intraabdominal pyloromyotomy through the umbilical route: A technical improvement. *J Pediatr Surg.* 1998;33(12):1806–1807.