



Inflammation and infection

Successfully treated bilateral renal fungal balls with continuous Anidulafungin irrigation

N.A.M. van Merode^{a,*}, J.J. Pat^{a,1}, M.J.H.M. Wolfhagen^b, G.A. Dijkstra^a^a Department of Urology, Isala klinieken, Zwolle, the Netherlands^b Laboratory of Clinical Microbiology and Infectious Diseases, Isala klinieken, Zwolle, the Netherlands

ARTICLE INFO

Keywords:

Candida glabrata
 Percutaneous nephrostomy
 Anidulafungin
 Invasive candidiasis
 Candidemia

ABSTRACT

A 73-year-old man with a history of type 2 diabetes mellitus, nephrolithiasis, and recurrent urinary tract infections caused by *Candida glabrata* was admitted to our hospital. Urosepsis was diagnosed and *C. glabrata* was isolated from urine and blood cultures. Computed tomography intravenous pyelography (CT-IVP) revealed bilateral filling defects caused by renal fungal balls. Treatment initially comprised intravenous anidulafungin coupled with continuous local anidulafungin irrigation via bilateral nephrostomy tubes, which was followed by high-dose oral fluconazole. This regimen successfully eradicated the *C. glabrata* in follow-up cultures.

Introduction

The incidence of urinary tract infections caused by *Candida spp.* is increasing as antibiotic and immunosuppressive use increases.¹ *Candida* can enter the upper urinary tract from the bloodstream (antegrade) or by ascending from the lower urinary tract (retrograde), with renal fungal balls as a rare presentation. To date, reports have focused on infections of the bladder or a single ureter, *Candida albicans* as the causative pathogen, and treatment with fluconazole or amphotericin B irrigation via nephrostomy tubes. We present a case of sepsis and bilateral renal fungal balls caused by *Candida glabrata*, treated by irrigation with anidulafungin (an echinocandin) via nephrostomy tubes.

Case presentation

The patient was a 73-year-old man with a history of type 2 diabetes mellitus, psoriasis, nephrolithiasis, and recurrent urinary tract infection caused by *C. glabrata*. Renal tract examination by cystoscopy and ultrasound had previously failed to reveal the underlying cause of his candiduria. At least six courses of oral fluconazole (doses of 200–400 mg/day for 10–28 days) had failed to achieve cure.

He presented to our emergency room with fever, reduced dietary intake and dysuria one month after his last course of fluconazole. Laboratory findings showed elevated inflammatory markers (leukocyte count, $13.1 \times 10^9/L$; C-reactive protein, 141 mg/L) and acute-on-

chronic renal impairment (estimated glomerular filtration rate [eGFR], 24 mL/min/1.73m²). Diagnostic testing for SARS-CoV-2 was negative and ultrasound revealed left-sided hydronephrosis.

Based on previous urine cultures growing *C. glabrata*, intravenous treatment was started with meropenem and anidulafungin, and we placed a transurethral catheter on the day of admission. His fever subsided the day after starting intravenous treatment, and given that blood and urine cultures subsequently confirmed *C. glabrata* in isolation, meropenem was discontinued. CT-IVP showed bilateral hydronephrosis with filling defects in the renal pelvises and calices caused by renal fungal balls (Fig. 1-A). Renography confirmed that drainage was impaired on both sides, so we placed bilateral percutaneous nephrostomies 7 days after hospital admission. Because of a national shortage of amphotericin B due to SARS-CoV-2 at the time of treatment, we opted to treat by continuous irrigation with anidulafungin via both nephrostomy tubes at a dosage of 5 mg/L (500 mL/24h/tube). During hospitalization, the patient's renal function gradually improved (eGFR 63 mL/min/1.73m²). Although a CT-IVP (contrast via nephrostomy) performed after 1 week of anidulafungin irrigation showed improvement, the fungal balls had not completely dissolved, so the anidulafungin irrigation and intravenous therapy were continued (Fig. 1-B).

A transurethral resection of the prostate was performed 12 days after starting the irrigation because of persistent lower urinary tract symptoms, obstructive flow and ureteral obstruction due to bladder wall hypertrophy. Prior to surgery, the patient received prophylactic

* Corresponding author. Dokter van Heesweg 2, 8025AB, Zwolle, the Netherlands.

E-mail address: vanmerode.nadine@gmail.com (N.A.M. van Merode).¹ shared first authorship.

cefazolin (1 g, single dose). We discontinued anidulafungin on post-operative day 2, but the patient developed a fever the following day, for which we started intravenous ceftriaxone. However, blood and urine cultures again showed *C. glabrata*, so the intravenous ceftriaxone was stopped and intravenous anidulafungin was started. The surgical pathology report showed benign prostatic hyperplasia with no signs of yeast infection.

Another CT-IVP, performed 14 days after starting the irrigation therapy, showed no further evidence of either the fungal balls or the ureteric obstructions. Therefore, we stopped the irrigation, removed the nephrostomy tubes and transurethral catheter, and stopped intravenous anidulafungin. The patient was discharged on high-dose oral fluconazole (800 mg/day). A follow-up CT-IVP 2 weeks later confirmed that the fungal balls had not recurred (Fig. 1-C). Six weeks after discharge the patient was re-admitted with malaise and elevated liver enzymes, which we diagnosed as a side effect of the fluconazole. Given that urine and blood cultures showed no signs of candidiasis, we discontinued the fluconazole and arranged follow-up CT-IVP 8 weeks after the previous scan, and this showed no recurrence (Fig. 1-D).

Discussion

Candiduria is a common problem that is only rarely complicated by the formation of renal fungal balls. Moreover, when candidemia is present, the mortality rate can reach 47% irrespective of this pathology.² Renal fungal balls are typically formed when *C. albicans* causes an invasive infection and forms (pseudo)hyphae that cluster, and if sufficiently large, can lead to urinary obstruction and hydronephrosis.³ Although *C. glabrata* cannot produce (pseudo)hyphae, it is capable of causing renal abscesses and fungal balls.³

C. albicans previously accounted for 70%–80% of all isolates from candida-infected patients. More recently, non-*albicans* species like *C. glabrata* and *C. tropicalis* have started to emerge. The widespread and

increased use of immunosuppressives and broad-spectrum antimycotics are thought to play a part in this mycological shift.¹ Infections of the urinary tract caused by *C. albicans* tend to be relatively easy to treat because of susceptibility to fluconazole, which can achieve high urinary concentrations. By contrast, species such as *C. glabrata*, which develop resistance to fluconazole, can be more difficult to treat.^{1,4}

In cases of fluconazole-resistant *C. glabrata*, the Infectious Diseases Society of America recommends amphotericin B. However, when renal fungal balls are present, the guideline further recommends surgical removal or irrigation with amphotericin B via nephrostomy tubes. The guideline does not recommend treatment with systemic echinocandins (i.e. anidulafungin) because of poor urinary excretion (<1%).² Anidulafungin (Ecalta®) is available in the European Union and 63 other countries (Table 1).

Previous case reports have indicated that successful treatment can be achieved with guidewire fragmentation, surgical removal, intravenous fluconazole plus saline irrigation, and fluconazole and amphotericin B irrigation. We did not find any case reports of successful irrigation with an echinocandin, this is probably due to the known efficacy and cost-effectiveness of amphotericin B.^{4,5}

Finally, risk factors for candiduria include diabetes mellitus, urinary tract abnormality or obstruction, prolonged antibiotic therapy, and renal failure.^{1,4} Our patient was predisposed to candiduria by his history of diabetes mellitus and urinary obstruction.

Conclusion

Renal fungal balls are a rare entity, especially those caused by *C. glabrata*. Current management strategies consist of therapy with intravenous antifungals plus irrigation via nephrostomy tubes. In the present case, we found that irrigation with anidulafungin may be a good alternative to fluconazole or amphotericin B, particularly where those may be contraindicated or unsuitable.

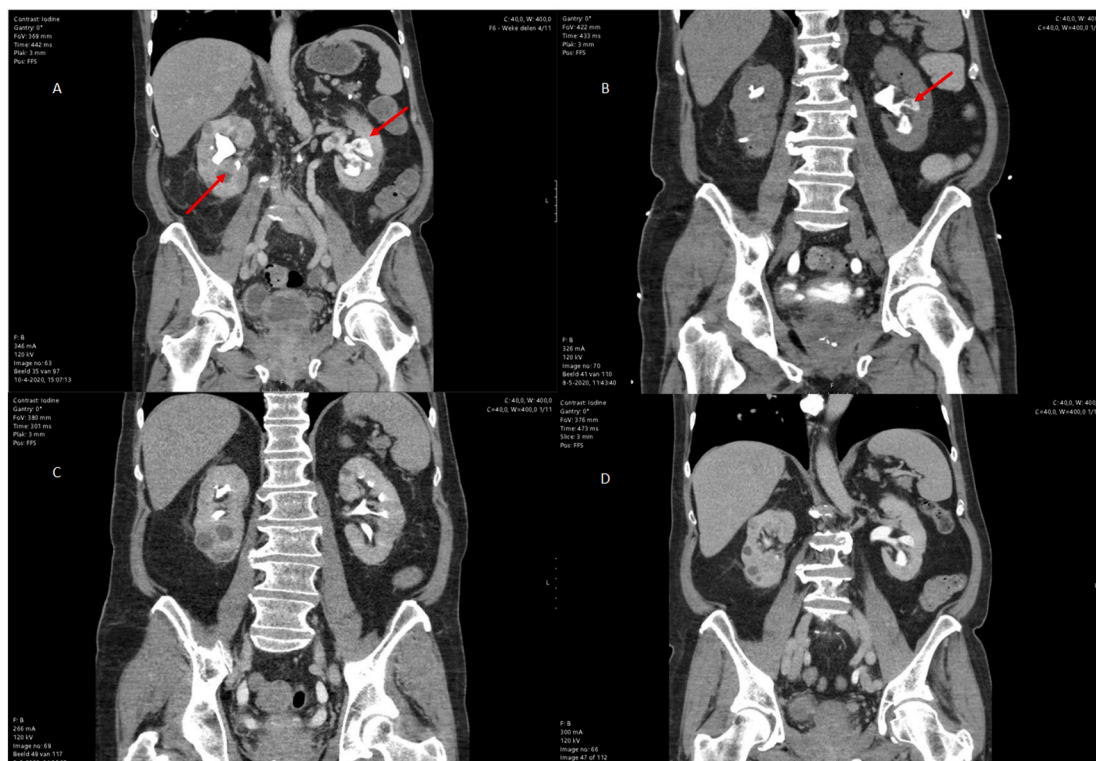


Fig. 1. Follow-up of CT-IVP throughout treatment course showing gradual decrease of renal fungal balls. A: Upon presentation showing bilateral hydronephrosis with filling defects in renal pelvises and calices. B: One week after starting anidulafungin irrigation showing improvement but some fungal balls remaining. C: Seven weeks after initial irrigation treatment no fungal balls were remaining. D: Eight weeks after last CT-IVP no recurrence was seen.

Table 1

List of countries where Anidulafungin (Ecalta®) is available.

Argentina	El Salvador	United Kingdom
Australia	European Union	Oman
Azerbaijan	Philippines	Panama
Bahama's	Ghana	Paraguay
Bahrain	Guatemala	Peru
Bangladesh	Honduras	Qatar
Barbados	Hong Kong	Russia
Belarus	India	Saudi-Arabia
Bermuda	Indonesia	Serbia
Bolivia	Israel	Singapore
Bosnia and Herzegovina	Jamaica	South Africa
Brasil	Jordan	Sri Lanka
Brunei Darussalam	Kazakhstan	Swiss
Canada	Kuwait	Thailand
Cayman Islands	Korea	Trinidad and Tobago
Chili	Lebanon	Tunisia
Colombia	Macau	Turkey
Costa Rica	Malaysia	Venezuela
Curacao	Mexico	United Arab Emirates
Dominican Republic	Nicaragua	United States of America
Ecuador	Norway	
Egypt	Ukraine	

Funding

This research did not receive any specific grant from funding agencies in the public, commercial, or not-for-profit sectors.

Author contributions

NvM and JP contributed equally and wrote the manuscript. MW and GD critically revised the manuscript.

Declaration of competing interest

None.

Acknowledgments

We thank Dr Robert Sykes (www.doctored.org.uk) for providing editorial services.

References

1. Fidel Jr PL, Vazquez JA, Sobel JD. *Candida glabrata*: review of epidemiology, pathogenesis, and clinical disease with comparison to *C. albicans*. *Clin Microbiol Rev*. 1999;12(1):80–96.
2. Pappas PG, Kauffman CA, Andes DR, et al. Executive summary: clinical practice guideline for the management of candidiasis: 2016 update by the Infectious Diseases Society of America. *Clin Infect Dis*. 2016;62(4):409–417.
3. Fisher JF, Kavanagh K, Sobel JD, Kauffman CA, Newman CA. *Candida* urinary tract infection: Pathogenesis. *Clin Infect Dis*. 2011;52(Suppl 6):S437–S451.
4. Praz V, Burruni R, Meid F, Wisard M, Jichlinski P, Tawadros T. Fungus ball in the urinary tract: a rare entity. *Can Urol Assoc J*. 2014;8(1-2):E118–E120.
5. Abdeljaleel OA, Alnadhari I, Mahmoud S, et al. Treatment of renal fungal ball with fluconazole instillation through a nephrostomy tube: CASE report and literature review. *Am J Case Rep*. 2018;19:1179–1183.