

A Rare Case of Cholecystoduodenal Fistula Complicated With Gallstone Ileus and Upper Gastrointestinal Bleeding

Review began 04/29/2022
Review ended 05/07/2022
Published 05/09/2022

© Copyright 2022

Chen et al. This is an open access article distributed under the terms of the Creative Commons Attribution License CC-BY 4.0., which permits unrestricted use, distribution, and reproduction in any medium, provided the original author and source are credited.

Ching-Ching Chen¹, Sheng-Chun Wang¹, Tzu-Hung Chen¹, Shao-Jiun Chou¹, Hsiang-Chun Lan¹

¹. General Surgery, Cardinal Tien Hospital, Taipei, TWN

Corresponding author: Sheng-Chun Wang, wsc110045@hotmail.com

Abstract

Gallstone ileus is a rare presentation of cholelithiasis, which usually impacts the narrowest part of the bowel, the ileocecal valve. This occurs as a result of a bilioenteric fistula where a gallstone passed through and entered the gastrointestinal tract. It is most commonly encountered in elder patients and predominantly in females. Abdominal computed tomography is the investigation of choice for diagnosis in the majority of cases. Here, we present a 68-year-old female patient with a choledochoduodenal fistula complicated by upper gastrointestinal bleeding and gallstone ileus.

Categories: General Surgery

Keywords: gastrointestinal tract, fistula, gallstone, ileus, pneumobilia

Introduction

Gallstone ileus is a rare complication of gallstone disease. It occurs mostly after the formation of a biliary-enteric fistula, especially with the duodenum, which allows the passage of gallstones into the intestinal lumen, causing small bowel obstruction [1]. Bleeding from biliary-enteric fistula can also be found due to irritation by bile or gallstone passage. Surgical treatments may be in one stage or two stages. Many studies indicate that clinicians prefer deferred definitive treatment according to their own experiences [2].

Here, we present a rare case of choledochoduodenal fistula complicated by upper gastrointestinal tract bleeding and gallstone ileus.

Case Presentation

The patient was a 68-year-old female patient without any prior history of systemic disease. The patient was brought to the emergency department due to changes in consciousness. The patient was ambulatory and able to self-care prior to this presentation. However, poor appetite and poor intake were noted as associated with vomiting and constipation for five days prior. There was no history of tarry stool or bloody stool passage before. Physical examination showed a distended abdomen with hypoactive bowel sounds. Other physical examinations cannot be performed due to hypovolemic shock with poor consciousness. Lab work revealed leukocytosis, severe anemia with a hemoglobin level of 4.9 gm/dl, and acute kidney injury. Computed tomography (CT) of the abdomen without contrast reported gallstone ileus and cholecystoduodenal fistula (Figures 1-4).

How to cite this article

Chen C, Wang S, Chen T, et al. (May 09, 2022) A Rare Case of Cholecystoduodenal Fistula Complicated With Gallstone Ileus and Upper Gastrointestinal Bleeding. Cureus 14(5): e24846. DOI 10.7759/cureus.24846

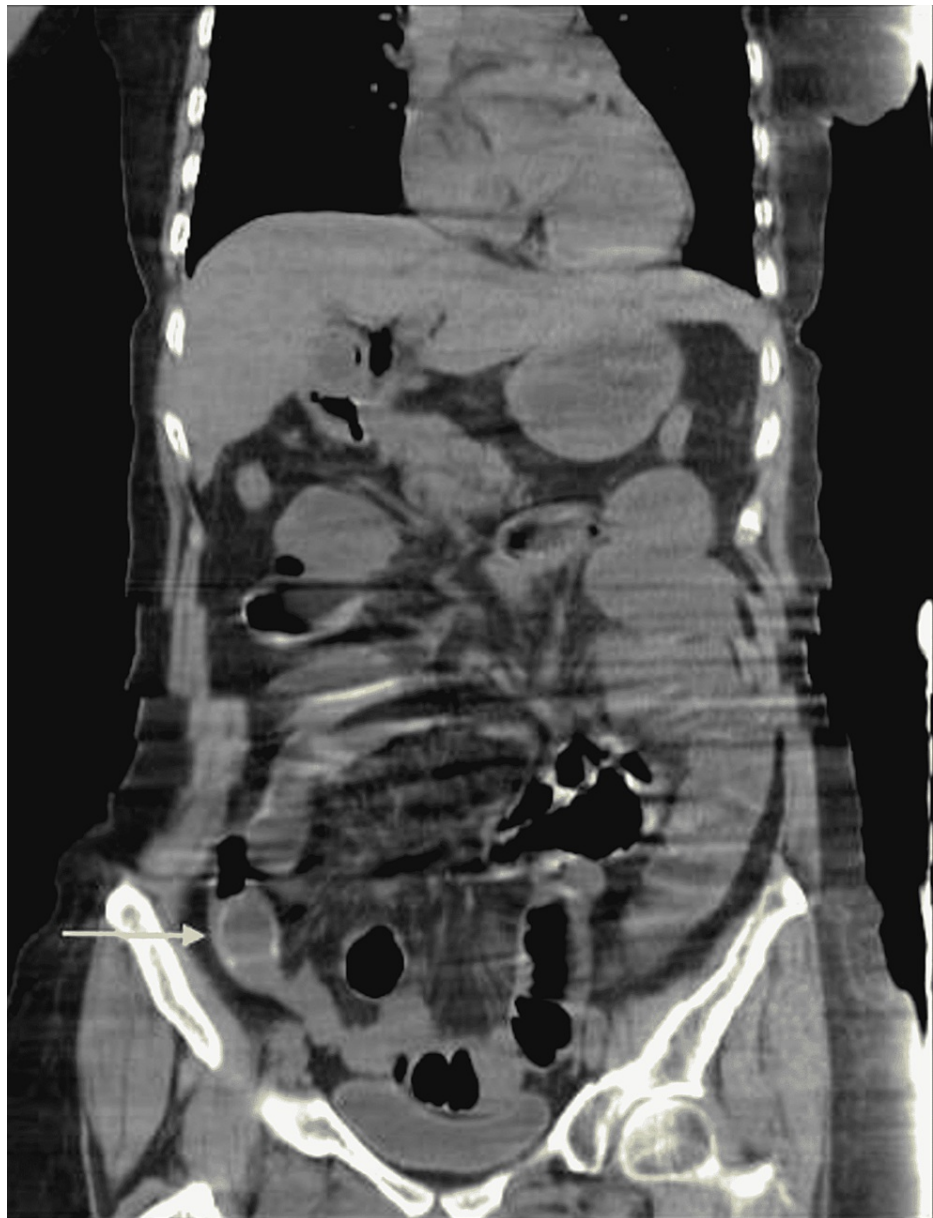

FIGURE 1: Coronal view of abdominal computed tomography

Gallstone in the distal ileum.

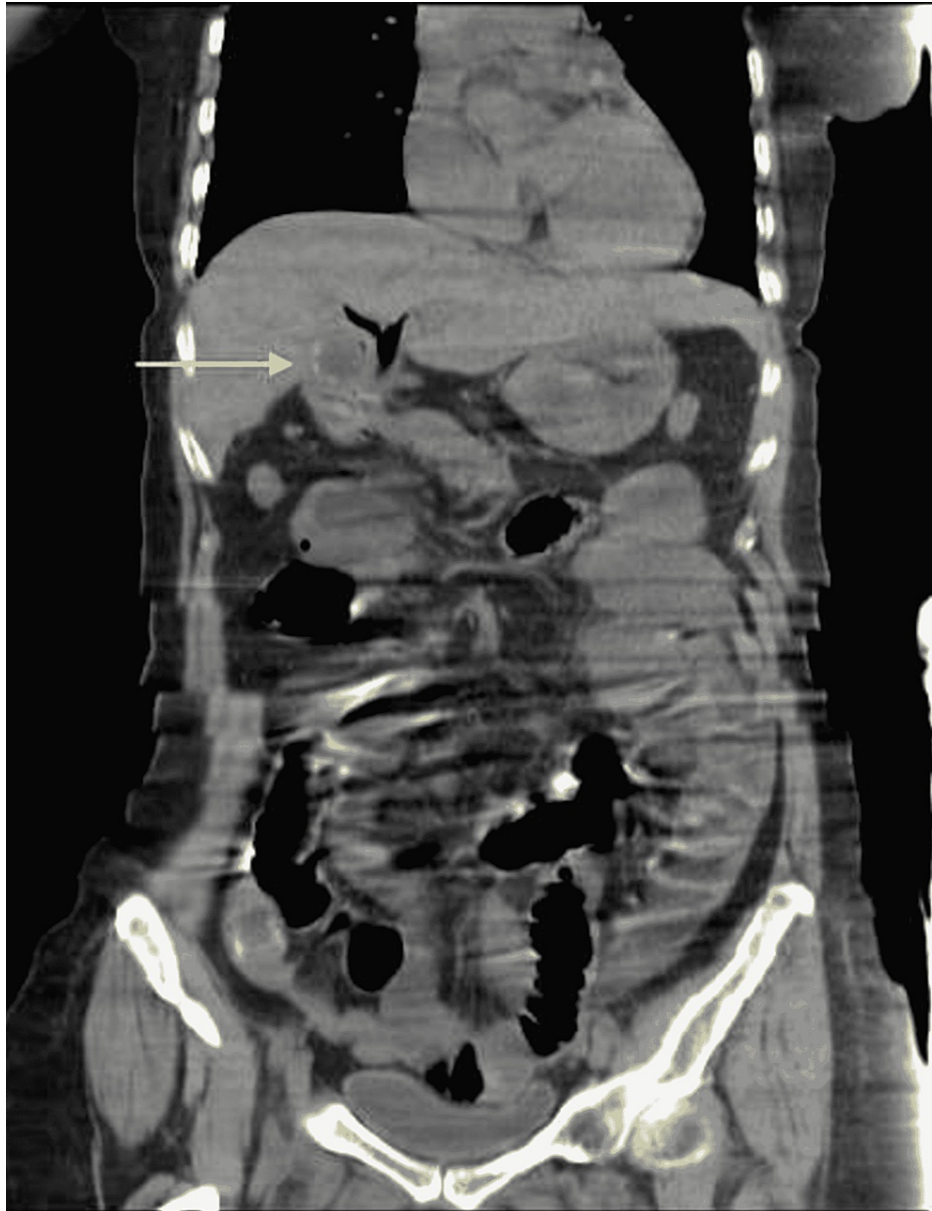

FIGURE 2: Coronal view of abdominal computed tomography

Residual gallstone in the gall bladder with pneumobilia.

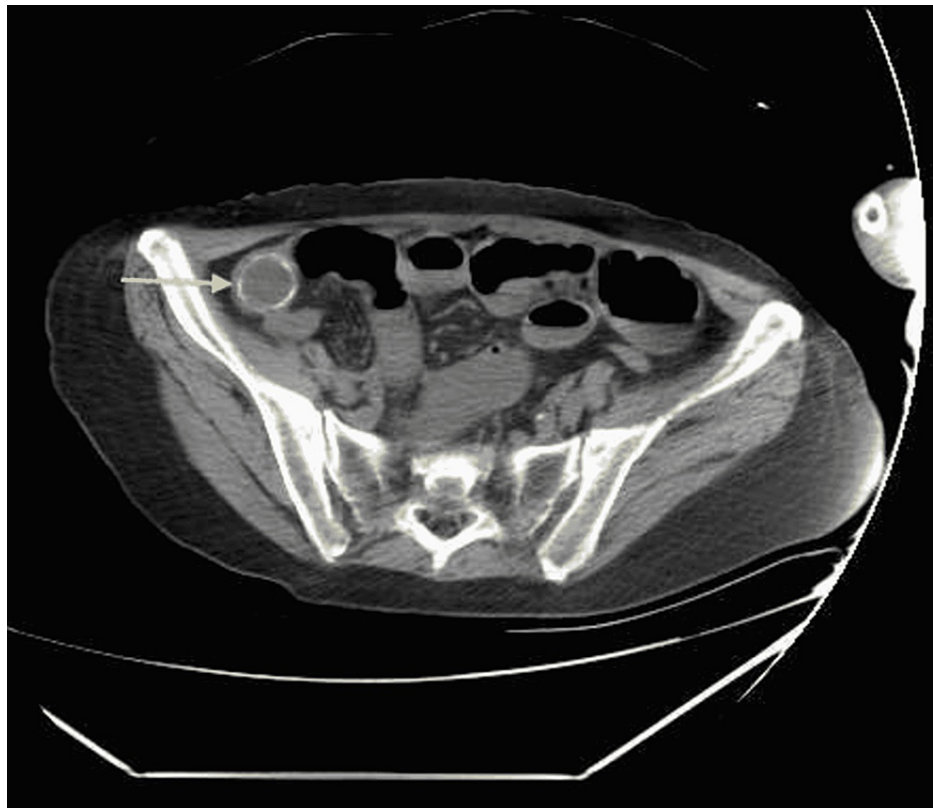


FIGURE 3: Axial view of abdominal computed tomography

Gallstone in the distal ileum.

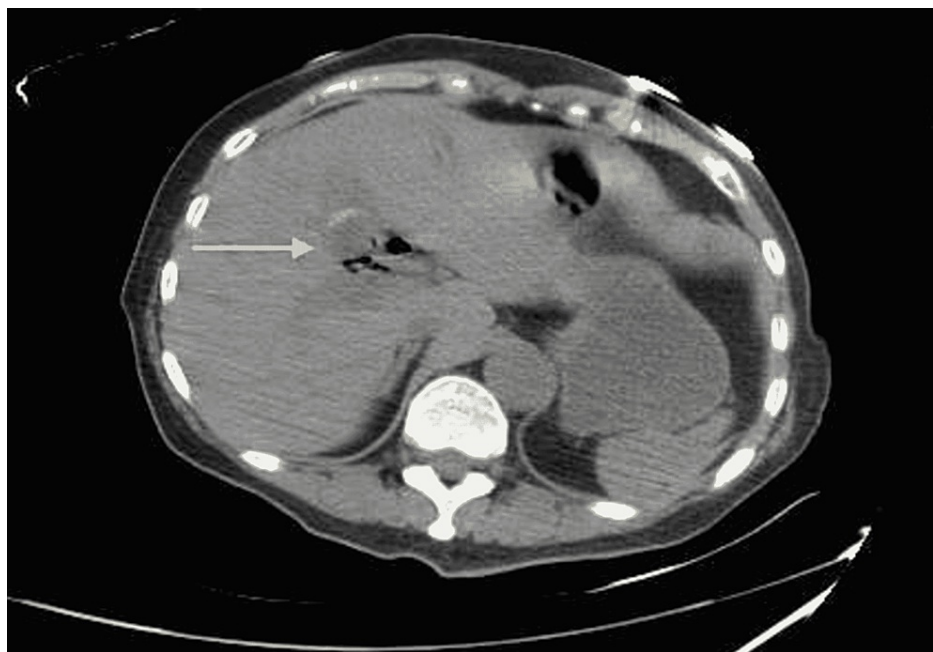


FIGURE 4: Axial view of abdominal computed tomography

Residual gallstone in the gallbladder with pneumobilia.

After resuscitation including blood transfusion, an emergent exploratory laparotomy was performed. A large gallstone located in the distal ileum was found to have caused an intestinal obstruction (Figures 5, 6). Enterotomy and removal of the gallstone were performed.

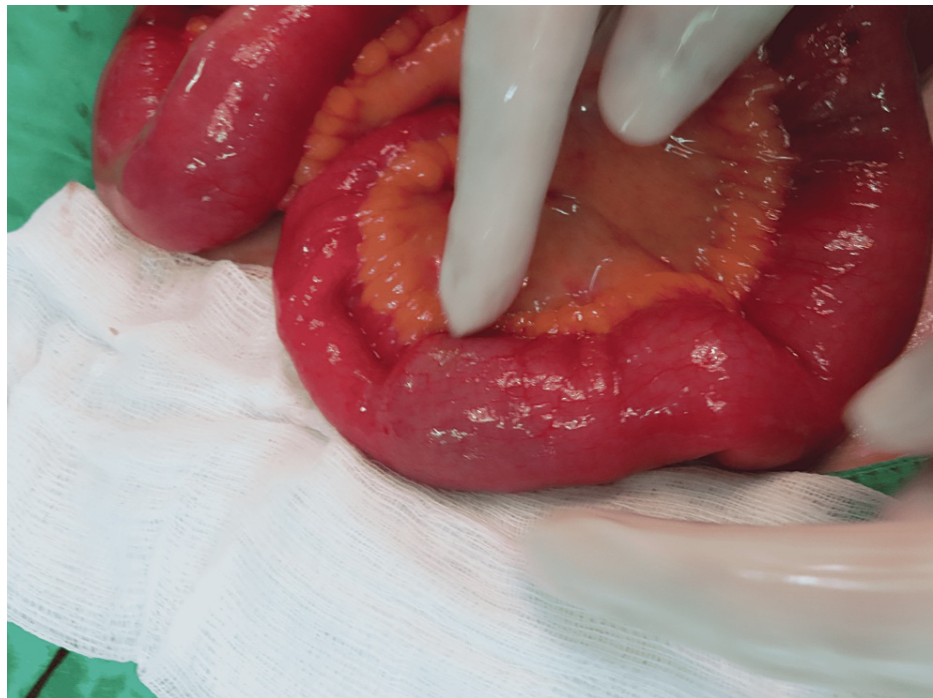

FIGURE 5: Operative finding

Gallstone impaction in the distal ileum with proximal dilatation.

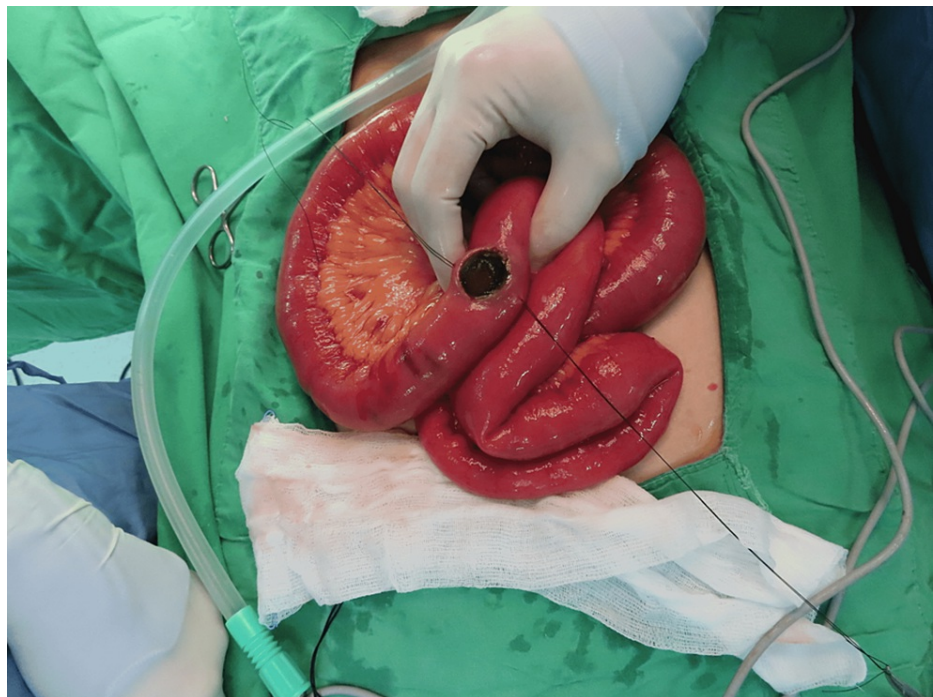


FIGURE 6: Operative finding

Gallstone in the distal ileum (post-enterotomy).

The patient's condition stabilized after the intestinal obstruction was improved. Upper gastrointestinal tract bleeding was confirmed by a bleeding scan, which reported increased tracer activity in the region of the upper abdomen with curvilinear movement through the small bowel. Interval operation of laparoscopic fistulectomy, cholecystectomy, and partial gastrectomy with Billroth II anastomosis for cholecystoduodenal fistula was performed one month after the first time operation (Figures 7, 8). Anemia due to upper

gastrointestinal tract bleeding was also improved after the fistulectomy was performed.

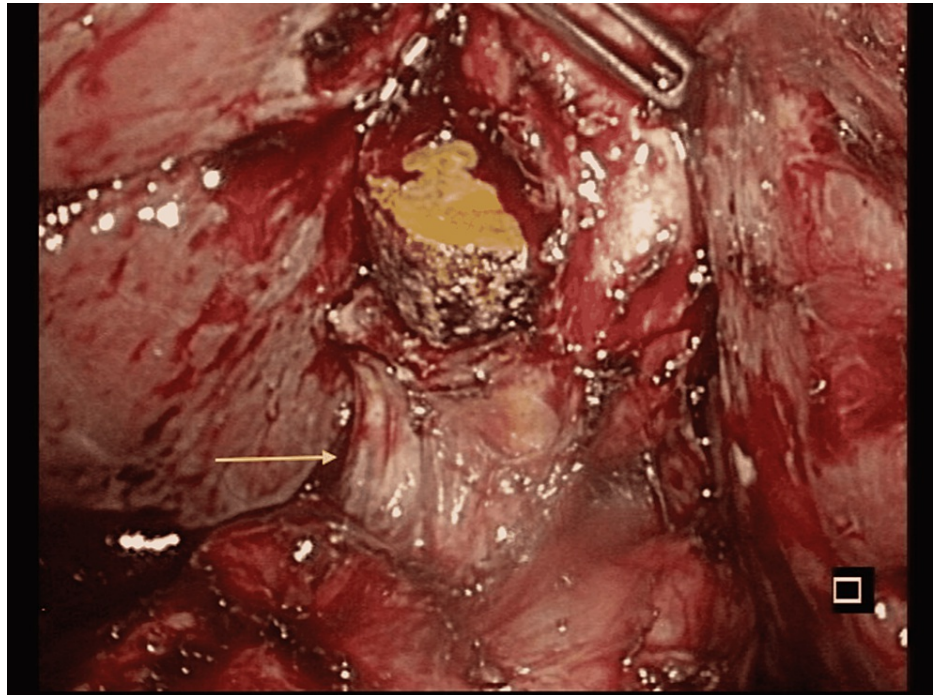


FIGURE 7: Laparoscopic finding

Cholecystoduodenal fistula (arrow) with a residual gallstone in the gallbladder.

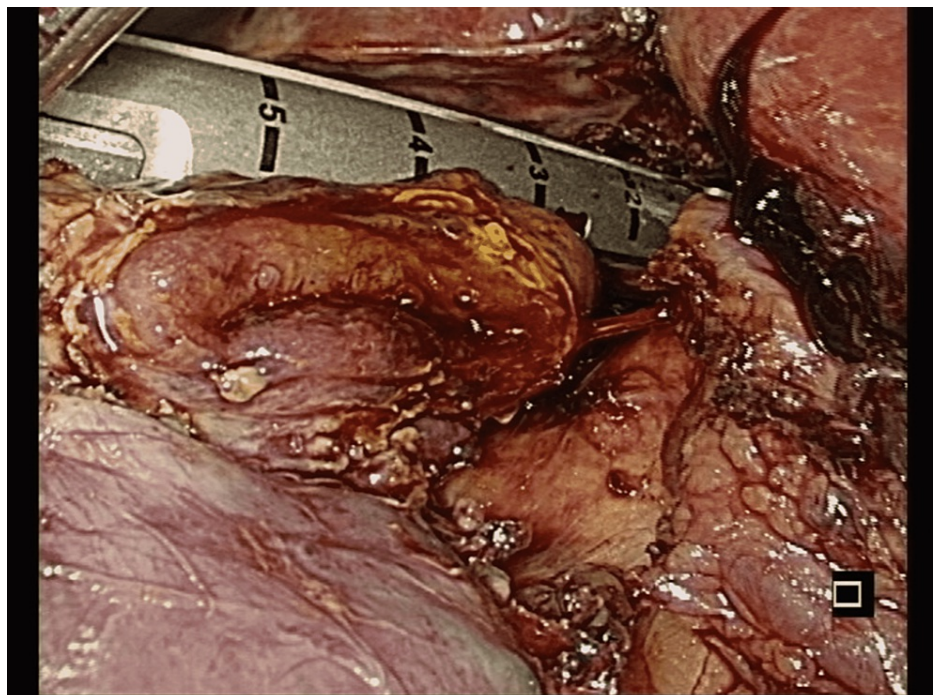


FIGURE 8: Laparoscopic finding

Fistulectomy and resection of the duodenal stump with Endo GIA (Medtronic, Minneapolis, MN).

Discussion

Recurrent episodes of gallstone cholecystitis may result in larger gallstone formation and biliary-enteric

fistula, complicated by gallstone ileus. The most common fistulas are cholecystoduodenal, and other types of biliary-enteric fistulas including cholecystocolic and cholecystogastric fistulas have also been reported. The most common site of obstruction is at the ileocecal valve, especially when the stone size is > 2.5 cm, suggesting a possible role of nasogastric decompression and fluid resuscitation in the management of gallstone ileus [3]. Prophylactic cholecystectomy is usually recommended in cases of large stones (>2.5 cm). However, this increases the unnecessary operative risks and costs for patients with asymptomatic gallstones. Although these patients are at risk of developing biliary-enteric fistula and gallstone ileus, the actual incidence of this progression is not known [4].

Gallstone ileus mostly presents in the form of small bowel obstruction, which is characterized as abdominal distension, colicky abdominal pain, nausea, vomiting, constipation, and features of dehydration such as feeling thirsty, dry eyes, dry mouth, deep color urine, and electrolyte imbalances. Although a history of previous biliary complaints is common in gallstone ileus, it is not a prerequisite. Only roughly 50% of gallstone ileus were noted with a history of previous biliary symptoms [5]. In some cases, gallstone impaction may cause pressure against the bowel wall and proximal bowel distension, resulting in necrosis of the bowel wall followed by perforation and peritonitis, which increase the mortality rate [6].

The typical radiographic features of gallstone ileus include small bowel obstruction, pneumobilia, and gallstone in the gastrointestinal tract that changes location on the serial film [7].

CT scanning is widely used as the investigation of choice in any other cause of acute abdomen, especially in intestinal obstruction with high sensitivity (90-93%) and specificity (100%) for gallstone ileus. In addition, CT scanning can also provide an accurate level of bowel obstruction that can be helpful in operative management and can further define the size and structure of the ectopic stone [8].

Upper gastrointestinal tract series using an oral contrast agent can also allow detecting the fistulous path extending between the gallbladder and the gastrointestinal tract, visualized as contrast accumulation within the gallbladder [9].

Cholecystoduodenal fistula rarely causes gastrointestinal bleeding, which occurs mostly due to invasion of the cystic artery by a duodenal ulcer or erosion by a gallstone. Bleeding associated with cholecystoduodenal fistula usually requires surgery because significant bleeding from the cystic artery is unlikely to be resolved by conservative management or endoscopic homeostasis [10].

The best management of gallstone ileus remains controversial. Enterotomy and stone extraction can resolve intestinal obstruction. Residual stones within the gall bladder may increase the risk of a recurrent attack of gallstone ileus, and even the risk of gallbladder cancer if recurrent cholecystitis has occurred.

For these reasons, two alternative methods of operation are introduced, which include a one-stage procedure as enterolithotomy, cholecystectomy, and fistula repair at the same time of operation and a two-stage procedure as enterolithotomy and interval cholecystectomy with fistula repair when the patient has recovered from the acute episode [11].

Reisner and Cohen compared mortality in patients who underwent enterolithotomy alone with those who underwent enterolithotomy, cholecystectomy, and fistula repair, which are one-stage surgery. The results showed that patients who underwent enterolithotomy alone had a mortality rate of 11.7% and patients who underwent one-stage surgery had a mortality rate of 16.9%. Although the recurrence rate for gallstone ileus is approximately 5%, enterolithotomy alone is the treatment of choice in gallstone ileus, especially in patients with hemodynamically unstable or significant comorbidities [12].

Conclusions

Gallstone ileus and gastrointestinal bleeding are rare but important complications of cholecystolithiasis with cholecystoduodenal fistula. Good judgment in selecting the surgical procedure is required, especially in elderly patients with a high incidence of comorbidities. Two-stage procedures are the procedure of choice in unstable patients.

Additional Information

Disclosures

Human subjects: Consent was obtained or waived by all participants in this study. Cardinal Tien Hospital issued approval CTH-111-3-7-002. Case Report Protocol: Version 1 (March 14, 2022). The committee is organized and operates according to ICH-GCP and the applicable laws and regulations. The study project is approved by the Institutional Review Board of the Cardinal Tien Hospital on March 26, 2022. This approval is valid till March 25, 2023. If the research is completed, the final report is required to submit before the expiration date. The principal investigator is required to report Serious Adverse Events and Unanticipated Problems according to the governmental laws and regulations and CTH requirements. **Conflicts of interest:** In compliance with the ICMJE uniform disclosure form, all authors declare the following: **Payment/services**

info: All authors have declared that no financial support was received from any organization for the submitted work. **Financial relationships:** All authors have declared that they have no financial relationships at present or within the previous three years with any organizations that might have an interest in the submitted work. **Other relationships:** All authors have declared that there are no other relationships or activities that could appear to have influenced the submitted work.

References

1. Jakubauskas M, Luksaite R, Sileikis A, Strupas K, Poskus T: Gallstone ileus: management and clinical outcomes. *Medicina (Kaunas)*. 2019, 55:598. [10.5390/medicina55090598](https://doi.org/10.5390/medicina55090598)
2. Stagnitti F, Tudisco A, Ceci F, et al.: Biliodigestive fistulae and gallstone ileus: diagnostic and therapeutic considerations. Our experience. *G Chir*. 2014, 35:235-8.
3. Fatimah N, Ahmed AS, Warraich MU, Butt UI, Ahmad QA, Ayyaz M: Stone in the distal jejunum presenting as small bowel obstruction: a case report. *Int J Surg Case Rep*. 2018, 52:20-2. [10.1016/j.ijscr.2018.09.045](https://doi.org/10.1016/j.ijscr.2018.09.045)
4. Freeman MH, Mullen MG, Friel CM: The progression of cholelithiasis to gallstone ileus: do large gallstones warrant surgery?. *J Gastrointest Surg*. 2016, 20:1278-80. [10.1007/s11605-016-3096-0](https://doi.org/10.1007/s11605-016-3096-0)
5. Hussain J, Alrashed AM, Alkhadher T, Wood S, Behbehani AD, Termos S: Gall stone ileus: unfamiliar cause of bowel obstruction. Case report and literature review. *Int J Surg Case Rep*. 2018, 49:44-50. [10.1016/j.ijscr.2018.06.010](https://doi.org/10.1016/j.ijscr.2018.06.010)
6. Nuño-Guzmán CM, Marín-Contreras ME, Figueroa-Sánchez M, Corona JL: Gallstone ileus, clinical presentation, diagnostic and treatment approach. *World J Gastrointest Surg*. 2016, 8:65-76. [10.4240/wjgs.v8.i1.65](https://doi.org/10.4240/wjgs.v8.i1.65)
7. Rigler LG, Borman CN, Noble JF: Gallstone obstruction: pathogenesis and roentgen manifestations. *JAMA*. 1941, 117:1753-9. [10.1001/JAMA.1941.02820470001001](https://doi.org/10.1001/JAMA.1941.02820470001001)
8. Chang L, Chang M, Chang HM, Chang AI, Chang F: Clinical and radiological diagnosis of gallstone ileus: a mini review. *Emerg Radiol*. 2017, 25:189-96. [10.1007/s10140-017-1568-5](https://doi.org/10.1007/s10140-017-1568-5)
9. Aldo C, Lorenzo M, Olgerta L, Alberto C, Licia U, Melchiorre G: Rolling in the deep: imaging findings and diagnostic pearls in gallstone ileus. *Surg Res Pract*. 2020, 2020:1421753. [10.1155/2020/1421753](https://doi.org/10.1155/2020/1421753)
10. Park JM, Kang CD, Kim JH, et al.: Cholecystoduodenal fistula presenting with upper gastrointestinal bleeding: a case report. *World J Clin Cases*. 2021, 9:410-5. [10.12998/wjcc.v9.i2.410](https://doi.org/10.12998/wjcc.v9.i2.410)
11. Ravikumar R, Williams JG: The operative management of gallstone ileus. *Ann R Coll Surg Engl*. 2010, 92:279-81. [10.1308/003588410X12664192076377](https://doi.org/10.1308/003588410X12664192076377)
12. Reisner RM, Cohen JR: Gallstone ileus: a review of 1001 reported cases. *Am Surg*. 1994, 60:441-6.