

Management of Malignant Obstructive Jaundice: Defining the Relevance of Various Palliative Surgical Options in Resource-Challenged Settings: A Review Article

Abstract

Malignant obstructive jaundice (MOJ) constitutes an important surgical problem with high morbidity and mortality worldwide. Presentation is usually delayed with a majority of patients benefitting only from palliative treatment. Surgeons practicing in developing countries face herculean task in managing MOJ due to lack of minimally invasive endoscopic procedures. Palliative surgical procedures are associated with high morbidity and sometimes mortality. Abdominal pain, generalized pruritus, and gastric outlet obstruction are some of the symptoms of MOJ requiring palliation. Successful surgical palliation may improve the overall quality of life in patients with MOJ considered fit for surgery. Bypass procedures and regional nerve blocks constitute the most effective surgical palliation available to surgeons practicing in resource-limited settings. This review article discusses the indications, the role, and types of surgical bypass procedures in the management of MOJ in contemporary surgical practice. This is important for surgeons in countries where expertise and resources for the less morbid endoscopic and radiologic approaches are not available. Relevant articles up to January 2021 published in PubMed, Google Scholar, and Hinari on the surgical management of obstructive jaundice were reviewed for inclusion. We also reviewed some modern surgical textbook topics on obstructive jaundice.

Keywords: Biliary, bypass, jaundice, low resource, malignant, obstruction, palliation

Introduction

Obstructing malignant lesions of the hepatobiliary tracts pose specific management challenge to the general surgeons in resource-limited countries.^[1] This may be attributed to the delayed manifestation of clinical symptoms and signs of hepatobiliary malignancies causing obstructive jaundice. Late-stage lesions of malignant obstructive jaundice (MOJ) preclude curative resection due to organ spread, lympho-vascular and perineural invasion, peritoneal deposits, and ascites.^[2,3] Generalized pruritus referable to malignant biliary obstruction is troublesome and may impact on the overall quality of life (QOL) of patients.^[4,5]

MOJ results from partial or total blockage of ante-grade flow of bile from the liver and gallbladder to the duodenum.^[6] This leads to accumulation of bile salts and products in the blood with a wide range of clinical manifestations.^[7] Pancreatic head cancer

and extrahepatic biliary malignancies are common causes of obstructive jaundice in general surgical practice.

Obstructive jaundice is also termed 'surgical jaundice' as surgery was traditionally required for its treatment or reversal of symptoms.^[8,9] Consequences of biliary obstruction include pruritus, malabsorption, cholangitis nutritional disturbances, bleeding disorders, and renal and progressive liver failure. Surgical resection for cure or long-term survival is not usually feasible in many patients with late-stage MOJ. However, palliative surgery remains a valuable option when endoscopic services are not available and life expectancy is more than 6 months.^[10]

Surgical palliation of malignancies is carried out with a primary intention to relieve symptoms and to improve QOL, despite having a negligible impact on patient's survival.^[11]

The current management of MOJ lesions is multidisciplinary^[12-14] and involves

How to cite this article: Balogun OS, Atoyebi OA. Management of malignant obstructive jaundice: Defining the relevance of various palliative surgical options in resource-challenged settings: A review article. *J West Afr Coll Surg* 2022;12:111-9.

Olanrewaju Samuel Balogun, Oluwole Ayoola Atoyebi

Department of Surgery, Lagos University Teaching Hospital, Idi-Araba, Lagos, Nigeria

Received: 25-Jan--2022

Accepted: 31-May-2022

Published: 06-Oct-2022

Address for correspondence:

Dr. Olanrewaju Samuel Balogun, Department of Surgery, Lagos University Teaching Hospital, Idi-Araba, Lagos, Nigeria. E-mail: drlanrebalogun@gmail.com

Access this article online

Website:

www.jwacs-jcoac.com

DOI: 10.4103/jwas.jwas_22_22

Quick Response Code:



This is an open access journal, and articles are distributed under the terms of the Creative Commons Attribution-NonCommercial-ShareAlike 4.0 License, which allows others to remix, tweak, and build upon the work non-commercially, as long as appropriate credit is given and the new creations are licensed under the identical terms.

For reprints contact: reprints@medknow.com

the Surgeon, the Interventional Radiologist, Medical Gastroenterologist, and an Oncologist.

Recently, there has been an increasing trend for the use of endoscopic and interventional radiologic procedures in MOJ. These procedures are associated with lesser morbidity and avoid the risk of major surgery. Endoscopic retrograde cholangiopancreatography (ERCP), endoscopic ultrasonography, and interventional radiologic procedures are currently the mainstay in the diagnosis and therapeutic management of malignant biliary obstruction.^[13,14] However, a major advantage of surgical bypass over the well-popularized endoscopic procedures is the long-term anastomotic patency rate. The overall cost of surgery is also less when compared with the endoscopic approach that requires repeated hospitalizations to manage stent-related problems.^[15]

In Nigeria, obstructive lesions of the biliary tract are fairly common to the General Surgeons. Most patients present late presentation and have poor prognosis. Few reports from developing countries have attested to the safety and feasibility of endoscopic management of obstructive jaundice.^[16,17] High cost of setting up and running this service is prohibitive and is not widely available. Hence, palliative surgery seems to be the most realistic way of achieving symptomatic relief in many of these frail, poor-body reserve patients.

This review aims to bring to the fore the various surgical palliation options for advanced MOJ. This is important for surgeons practicing in settings in which the less morbid endoscopic and radiologic approaches and expertise are not available. We explored the aetiology, pathophysiology, and clinical features of MOJ and discussed various surgical palliative options for unresectable malignant biliary lesions. Although there are other palliative measures such as chemotherapy and radiotherapy for these patients, our attention in this review will be focused on the surgical palliation of extra-hepatic biliary obstruction caused by malignancies.

Materials and Methods

A search through PubMed, Google Scholar, and Hinari online databases was conducted using the following search terms: malignant obstructive jaundice, surgical jaundice, surgical palliative bypass for obstructive jaundice in Nigeria, double biliary bypass, triple biliary bypass, biliary bypass in resource-challenged settings, and unresectable carcinoma head of pancreas. Relevant chapters and discussions on obstructive jaundice, cholangiocarcinoma, and pancreatic cancer from contemporary surgical textbooks were also reviewed.

Relevant articles published up to 2021 were retrieved from the aforementioned databases. Information on epidemiology, biliary anatomy, aetiopathogenesis of

obstructive jaundice, and surgical palliation for obstructive jaundice and outcome was reviewed. We excluded journal articles on bypass procedures for benign diseases, single case reports, summary of the meetings, and article published in non-refereed journals.

Epidemiology of Obstructive Jaundice in Nigeria

Obstructive jaundice occurs due to a variety of causes and hence is not a specific diagnosis. For this reason, epidemiology of MOJ depends on the prevailing aetiology. There are few published series on obstructive jaundice in Nigeria. In the majority of these papers, carcinoma head of pancreas was reported as the most common cause of obstructive jaundice.^[18–21] About 75% of pancreatic tumours occur in the head and neck region.^[22] According to the 2020 GLOBOCAN Statistics on Nigeria, released by the International Agency for Research on Cancer, cancer of the pancreas ranked 13th in causes of cancer-related deaths with a prevalence of 1.8 and a cumulative risk of 0.19.^[23] This implies that carcinoma of the pancreas is probably responsible for the minority of cancer-related deaths in Nigeria. There appears to be a preponderance of bile duct cancers among males as reported in most local series on obstructive jaundice in Nigeria. Immunosuppressive states, chronic alcohol ingestion, and smoking are also well-documented risk factors for biliary tract malignancies.^[24] A recent diagnosis of diabetes mellitus in a middle-aged or an elderly may herald the onset of symptoms due to pancreatic cancer.^[25]

Basic Biliary Anatomy

For management considerations, the biliary system in adults has two components: the intrahepatic and extrahepatic bile ducts. In the intrahepatic component, bile is secreted by the hepatocytes into the bile ductules which coalesce to form intrahepatic ducts. Further union of intrahepatic ducts downstream leads to the formation of right and left hepatic ducts. The extrahepatic system commences with the union of intrahepatic ducts, which emerge from the liver as right and left hepatic ducts [Figure 1]. These two ducts unite to form the common hepatic duct. Hepatic duct is further joined distally by the cystic duct to form the common bile duct which courses distally posterior to the first part of the duodenum and the head of pancreas. At this point, it is joined by the pancreatic duct in 80–90% of the cases to form a common channel which enters the medial wall of the second part of the duodenum and to form the ampulla of Vater.^[26] The common bile duct runs for 1–2 cm within the medial wall of the duodenum before ending up as ampulla of Vater. This intraduodenal part is encircled by a rim of smooth muscles which constitute the sphincter of Oddi.^[22]

Aetiology of Obstructive Jaundice

MOJ has primary or secondary causes. Primary biliary tract malignancy arises from either the intra- or extrahepatic

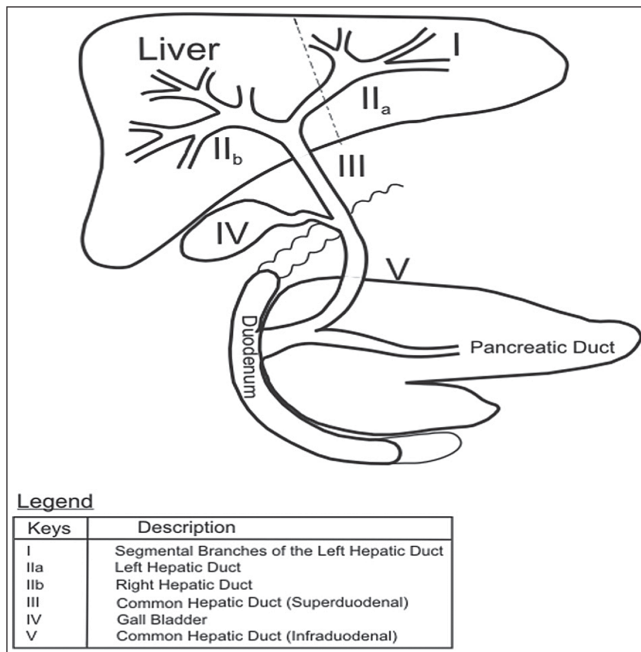


Figure 1: Basic anatomy of the hepato-pancreato-biliary system

bile duct. Secondary biliary tract malignancy occurs as a result of infiltration or spread from a regional mitotic lesion. For instance, malignant biliary strictures may arise from mural spread from cancers of the pancreas and cholangiocarcinoma.^[27,28]

Aetiologically, obstructive jaundice may develop from intrahepatic and extrahepatic causes. Intrahepatic causes are more complex and involve pathologies affecting the parenchyma and the intrahepatic ducts. Examples include viral hepatitis and biliary cirrhosis. Extrahepatic lesions cause progressive stricture or stenosis of the biliary tract. These lesions may occur at different levels from the right and left hepatic ducts to the ampulla of Vater. Examples include gallbladder carcinomas, cholangiocarcinomas, ampullary and periampullary carcinomas, and Klatskin's tumours.

Pathophysiology and Clinical Features of Obstructive Jaundice

Bile is secreted by the hepatocytes and channelled via the biliary canaliculi, hepatic, and common bile ducts into the second part of the duodenum [Figure 1]. About 95% of the secreted bile is reabsorbed in the gut and transported via the portal vein to the liver. This is called enterohepatic circulation.^[29] Bile is a mixture of water with bile salts, bile acids, cholesterol, electrolytes, and bilirubin. It plays a major role in digestion and absorption of fats and fat soluble vitamins. Bile also provides a channel for excretion of waste products of metabolism, drugs, and toxins. In obstructive jaundice, partial or total mechanical blockage of bile flow from the liver to the duodenum results in a spectrum of biochemical changes in the blood and structural changes in the liver. These may result in

deleterious consequences. Clinical and pathophysiological sequelae of biliary obstruction are as follows.

Abdominal pain: Traditionally, jaundice due to malignant biliary obstruction especially due to carcinoma of the pancreas has been regarded as 'painless'. It is now known that abdominal pain can be present in some patients.^[30] Abdominal pain due to malignant biliary obstruction may be secondary to local tumour infiltration, obstruction, and involvement of regional celiac plexus and nerves.^[22,30]

Jaundice: Jaundice connotes yellowish discolouration of elastin-containing tissues in the body such as sclera and mucosal surfaces. Persistent or remittent jaundice rather than intermittent jaundice tends to suggest malignant biliary obstruction. In biliary obstruction, total and conjugated bilirubin levels are raised with bilirubinuria (conjugated water-soluble bilirubin in urine).

Pruritus: The aetiology of pruritus in obstructive jaundice is not clear.^[5,9] This has been related to accumulation of bile salts in the skin and release of endogenous opioids.

Cholangitis: This is due to stasis of bile and secondary bacterial infection.

Clotting abnormalities: This results from the poor absorption of fats and fat-soluble vitamins like vitamin K, which is needed for the synthesis of clotting factors.

Nutritional disturbances: These are consequences of fat malabsorption and reduced intake due to anorexia of malignancy.

Progressive liver dysfunction: This arises from accumulation of toxic end products of metabolism and encephalopathy.

Oliguria renal failure: This is believed to be due to deposition of bile salts and pigments and other endotoxins in the glomerulus, leading to acute oliguric renal failure. Oliguric renal failure complicating obstructive jaundice occurs in 8–10% requiring surgery for biliary obstruction with mortality as high as 70–80%.^[31]

Laboratory Investigations

Regardless of the aetiology of MOJ, laboratory investigations in these patients are geared towards establishing the diagnosis and determine the degree and severity of obstruction. Laboratory investigations are also used to prepare the patient for surgery and predict the outcome of treatment. Conjugated hyperbilirubinaemia, elevated levels of alkaline phosphatase, gamma-glutamyl transferase, and 5' nucleotidase with bilirubinuria are hallmarks of biliary obstruction. Alanine transaminase (ALT) and aspartate transaminase (AST) are also deranged to a variable extent. Other relevant investigations will include full blood count, electrolytes urea and creatinine, coagulation profile, serum proteins and albumin, serum, and fasting blood sugar. Tumour markers assay, notably Ca19-9, may be useful in the diagnosis of pancreatic cancer,

prediction of its resectability, and prognosis after surgical resection.^[32] Ca 19-9 is also known to be elevated to a lesser extent in cholangiocarcinomas.

Radiological Investigations

Radiological investigations are helpful in establishing the diagnosis of MOJ, disease staging, and in selection of patients who will benefit from either curative or palliative procedures.

Abdominal ultrasound is the initial imaging of choice in most hepatobiliary disorders.^[33] Ultrasound findings suggestive of obstructive jaundice include: dilated extrahepatic and intrahepatic ducts. Ultrasound is however limited in the determination of the aetiology and the exact point of obstruction. Abdominal computed tomography (CT) scan can detect dilated intrahepatic and extrahepatic ducts and identify specific cause and point of obstruction on contrast-enhanced images. Magnetic resonance cholangiopancreatography (MRCP) is a non-invasive and sensitive method for evaluating the hepatobiliary tree. No contrast is required. MRCP can detect dilated bile ducts and determine the cause and level of obstruction.

ERCP is an invasive method of visualizing the biliary tree with the aid of contrast injected through a working channel of a side-viewing duodenoscope. Findings are similar to that of MRCP but in addition, ERCP offers therapeutic advantages of biliary drainage with insertion of endoprosthesis.

Indications for Surgical Palliation in MOJ

Diagnosis and staging of the disease: The gold standard for diagnosing malignant lesions causing obstructive jaundice is via the biopsy of the primary lesion. This can be achieved through image-guided percutaneous sampling, laparoscopic or open surgery. Fine needle aspiration cytology, core needle biopsy, and incisional biopsy are used in tissue sampling of MOJ lesions.^[24,34] In many cases, tissue samples from regional lymph node or metastatic deposits may be obtained for tissue diagnosis and immunochemical characterization. Tissue biopsied in this case will depend on the underlying lesion causing obstruction and the level of safety associated with the execution of the procedure. For instance, excision of peripancreatic nodes or biopsy of liver metastasis may be preferred to primary pancreatic tissue biopsy, which risks more bleeding, propensity to develop acute pancreatitis, abscesses, and fistulas.^[34] Same consideration applies to cancers arising from luminal structures such as bile ducts. Diagnostic laparoscopy provides a more accurate staging of the malignant lesion than computed tomography scan or magnetic resonance imaging.

Therapeutic treatment: Benefits of surgical palliation include symptomatic relief from jaundice, troublesome pruritus, gastric outlet obstruction, ascites, and abdominal pain. The presence of jaundice without other symptoms is generally not considered as indication for palliation. Surgical bypass or endoscopic decompression of the obstructed biliary tract

improves QOL and may be a reasonable option for effective metabolism and excretion of chemotherapeutic agents in patients with gallbladder and biliary tract cancers.^[35] Relief of jaundice requires drainage of more than 30% of functional liver parenchyma.^[36]

Pre-operative Considerations

In MOJ, efforts are made to determine the severity of the disease and optimize patients' clinical conditions in preparation for surgery. Pre-operative preparation of the patients involves: correction of anaemia, hypoproteinaemia, coagulopathy, adequate hydration, and treatment of infections. Any associated co-morbid condition should be given proper attention. Patients with MOJ may tolerate anaesthesia and major surgical procedures poorly, hence, it is recommended that surgery should be carried out as soon as is feasible to do so.

Surgical Palliative Procedures for Relieve of Jaundice and Pruritus

Surgical bypass to relieve jaundice and pruritus in MOJ involves creation of an enterobiliary anastomosis proximal to the obstruction so as to divert the flow of bile into the gastrointestinal tract. Roux-en-Y or a simple loop (Braun) jejunal conduit may be used^[37-39] [Figures 2(a) and (b)]. Both hand-sewn and stapled anastomoses are described in the literature.

Roux-en-Y or a simple loop conduit can be constructed in a retrocolic or antecolic fashion. The latter approach is technically easier to execute. Antecolic jejunal conduit is the preferred choice in patients with MOJ. The simple loop (Braun) technique is quicker to perform and is suitable for patients with intraperitoneal carcinomatosis, secondaries in the liver, ascites, and poor clinical state.^[38] However, simple loop bypass utilizes more bowel length [Figure 2(b)]. The afferent bilioenteric limb distal to the entero-enteric anastomosis may also be redundant. The Roux loop has advantage of increased mobility to the subhepatic space, less tension on the bilioenteric anastomosis, and less incidence of cholangitis [Figure 2(a)]. In addition, Roux loop also makes an easier treatment of potential anastomotic bile leaks.^[37] However, compared with simple loop enterobiliary bypass, the Roux loop bypass takes longer time to perform.^[32,34] Both Braun and Roux intestinal conduits require an entero-enterostomy which is usually placed between 40 and 60 cm from the bilioenteric anastomosis to prevent ascending cholangitis.^[33] Considerations for bypass procedures should take account of the location of obstruction, the extent of local disease, and surgeon's expertise.

Procedures for proximal biliary duct obstruction

Intrahepatic segmental bilioenteric bypass (cholangiojejunostomy)

Intrahepatic cholangiojejunostomy is used to bypass unresectable hilar cholangiocarcinomas (Klatskin's tumours) and obstructing gallbladder carcinoma.^[40] In

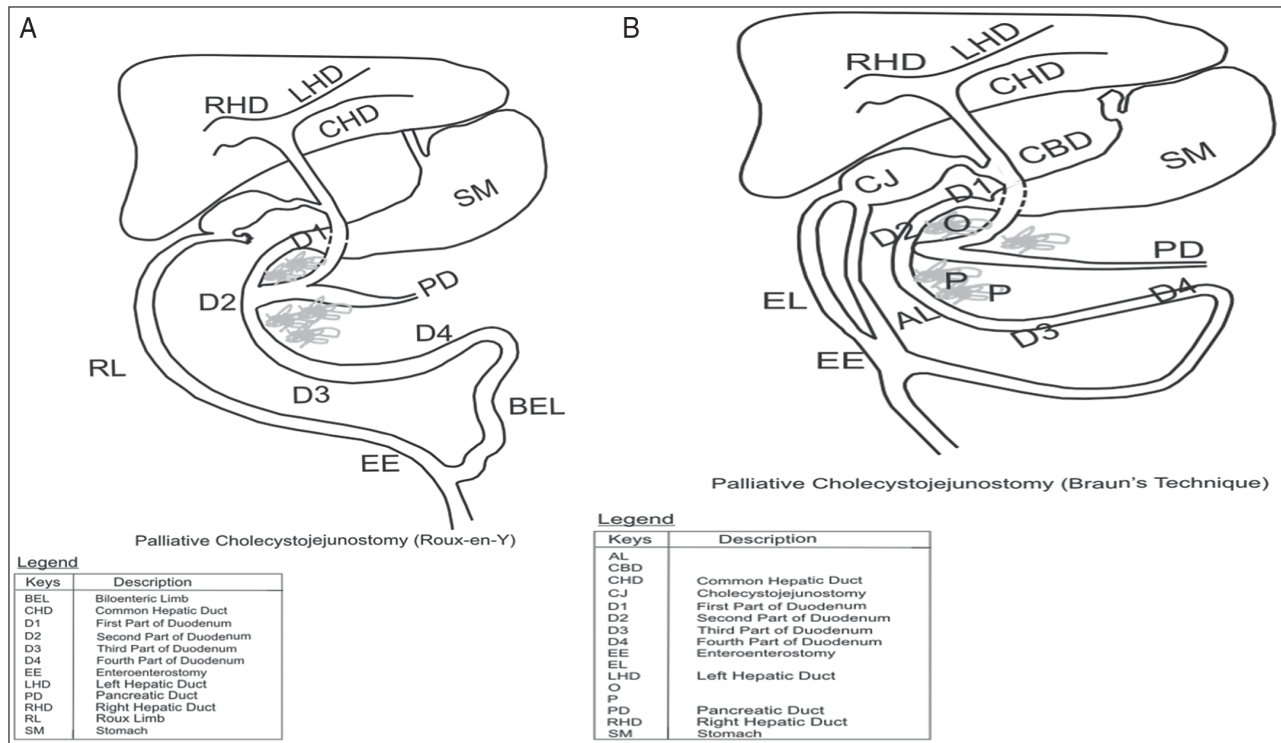


Figure 2: (a) Roux-en-Y single bypass cholecystojejunostomy; (b) loop single bypass cholecystojejunostomy (Braun technique)

fit patients, this procedure may offer a good palliation with improved QOL and prevention of cholangitis.^[40] Anastomosis is constructed well away from the proximal border of the tumour to minimize anastomotic infiltration and occlusion. Elective intrahepatic cholangiojejunostomy is contraindicated in extensive liver disease, multiple liver secondaries, and portal vein obstruction.^[41] Biliary decompression through cholangiojejunostomy can be achieved in three principal methods.

1. Resection of the left lateral segment (segment III) of the liver with end-to-side cholangiojejunal anastomosis (Longmire's procedure).^[42,43] Longmire's procedure is old, technically challenging, and has been superseded by segment III and V bilioenteric bypass procedures.
2. Exposure of left lateral (segment III) duct beneath the round ligament with side-to-side cholangiojejunostomy.^[44] This operation is popular among many hepatobiliary surgeons because of its efficacy in biliary decompression.^[45,46] Segment III cholangiojejunostomy is made feasible because the left hepatic duct is longer than the right, with a little extrahepatic course.^[47] The left hepatic duct also has more tendency to dilate in distal obstruction, making it easier to assess for anastomosis.^[40,41,45]
3. Exposure of the right hepatic duct (segment V) through the base of the gallbladder with cholangiojejunostomy.^[40,48] Access to segment V duct is more challenging as it requires more extensive dissection and there is no surface marker to the duct. Access to the right hepatic duct is aided by intra-operative ultrasound.^[45] Segment V cholangiojejunostomy has also been found to be

associated with more morbidity and is less effective than segment III cholangiojejunostomy with regard to long-term patency rate.^[49-51]

Intrahepatic enterobiliary bypass should be avoided in atrophic liver as is often not effective.^[15,45] It is also contraindicated if the undrained liver remnant is infected.^[51]

Procedures for distal biliary obstruction (extrahepatic bypass)

Surgical options for extrahepatic bypass include hepaticojejunostomy, choledochojejunostomy, and cholecystojejunostomy.

Hepaticojejunostomy: This is an anastomosis between the common hepatic duct and a Roux or Braun loop of jejunum. When present, gallbladder is usually removed to facilitate this procedure.^[52] Hepaticojejunostomy is favoured over choledochojejunostomy or cholecystojejunostomy in distal malignant biliary obstruction because of its long-term patency rate.^[15] The anastomosis is at a considerable distance from the tumour. An end-to-side hepaticojejunostomy is recommended, but a side-to-end or a side-to side hepaticojejunostomy works as well. Contraindication to hepaticojejunostomy is a large tumour disease of the hepatic tract. In this instance, large tumour bulk often makes dissection of the hepatic duct technically difficult.

Choledochooduodenostomy: Side-to-side anastomosis between the common bile duct and the duodenum has a very limited role in palliation of distal common bile duct and pancreatic head tumours. This is because of the proximity of the anastomosis to the tumour bed with the risk of early tumour invasion and

recurrent jaundice.^[52] Complications arising from anastomotic dehiscence in choledochoduodenostomy are associated with high morbidity as a result of leakage of bile and gastrointestinal secretions.

Cholecystojejunostomy [Figure 2(a) and (b)]: this is the most commonly performed bilioenteric anastomoses for MOJ. Easy access, safety, and simplicity of performing the procedure within a short period of time make cholecystojejunostomy a favourite among surgeons. Efficacy of cholecystojejunostomy relies on the patency of the cystic duct and when cystic/common bile duct junction is well away from the tumour. A distended gallbladder does not necessarily indicate a patent cystic duct as it may be due to cystic duct obstruction.^[52] Cystic duct patency is determined pre- or intra-operatively by cholangiography.^[52] In situations in which facilities for cholangiography are not available, failure to decompress the dilated common bile and hepatic ducts when the gallbladder content is suctioned at surgery may suggest an obstructed cystic duct.^[53] A major drawback of cholecystojejunostomy is the easy occlusion of the cystic/hepatic duct junction by bile sludge debris, tumour in-growth.^[51,52] For this reason, cholecystojejunostomy is a less effective palliation when compared with hepaticojejunostomy. An author has attributed the high failure rate of bilioenteric anastomosis seen in some published series to the use of gallbladder for bypass.^[52] Cholecystojejunostomy is contraindicated in fibrotic gall bladder and previous cholecystectomy.^[52]

Hepaticocholecystojejunostomy (HCJ): This procedure was described by Weintraub *et al.*^[54] as an alternative when hepaticojejunostomy is contraindicated or when there are concerns about long-term efficacy of cholecystojejunostomy due to patency of the cystic duct. HCJ uses the gallbladder as a bilioenteric conduit with two segmental anastomoses: (i) between the infundibulum of the gallbladder and the hepatic duct and (ii) between the fundus of the gallbladder and usually the Roux loop of the jejunum. HCJ is considered safe and simpler option than end-to-side HJ that requires some dissection after cholecystectomy.^[54,55] The dissection around the biliary tract is that which allows a tension-free anastomosis between the gallbladder infundibulum and the hepatic duct.

Relieve of Gastric Outlet Obstruction(GOO)

GOO from advanced gastrointestinal and hepatobiliary malignancies is associated with reduced length of survival. GOO can follow an insidious course because of an inherent capacity of the stomach to grossly dilate before a high grade obstruction occurs.^[56]

Possible mechanisms for GOO in advanced pancreatic cancer include (i) alteration of gastric dysmotility due to celiac plexus infiltration by the tumour and mesenteric artery involvement^[57] and (ii) less commonly (5%), obstruction of the duodenum due to tumour infiltration.^[58]

Gastroparaesis and persistent vomiting which occur in some patients after palliative gastrojejunostomy can be attributed to gastric dysmotility from tumour infiltration of the coeliac plexus. Palliative gastrojejunostomy is more likely to be beneficial when the aetiology is secondary to mechanical obstruction and is offered in addition to the biliary bypass surgery in patients with MOJ complicated by GOO. These two procedures constitute a double-bypass surgery [Figure 3].

The role of prophylactic gastrojejunostomy for GOO in advanced pancreatic cancer has been a subject of controversy among surgeons. Prophylactic gastrojejunostomy is believed by some experts to add to the duration of surgery and morbidity of bypass procedures. However, a prospective multi-centre study has shown that prophylactic gastrojejunostomy can reduce the incidence of GOO without increasing the complication rate of surgery.^[59] Another study and a systematic Cochrane review are also in favour of this practice.^[60,61] Antecolic gastrojejunostomy is a preferred option in advanced pancreatic cancers to mitigate the possibility of tumour obstructing the anastomosis.

Triple Bypass Vs. Double Biliary Bypass: An Often Confused Terminology

A procedure involving bypass of biliary obstruction (cholecysto/choledocho/hepatico-jejunostomy) and gastric outlet obstruction (gastrojejunostomy) is regarded as a double bypass surgery. Occasionally, an additional procedure (pancreaticojejunostomy) may be performed if pancreatic duct is also obstructed as in periampullary cancers. Cholecysto/choledocho/hepatico-jejunostomy with gastrojejunostomy and pancreaticojejunostomy constitute a triple bypass surgery.^[62]

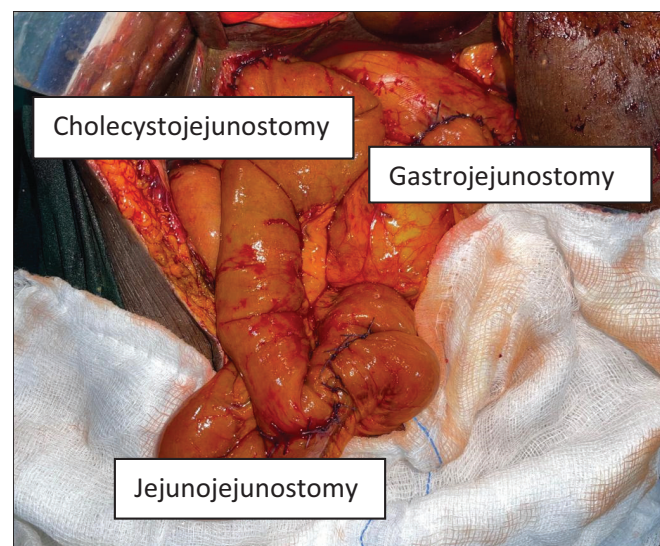


Figure 3: Intra-operative view of the abdomen in a patient after Roux-en-Y double bypass surgery by the author

Relieve of Abdominal Pain (Coeliac Plexus Block)

Intra-operative chemical splanchnectomy via coeliac ganglion block is considered to be the most effect method of invasive pain palliation from pancreatic tumour infiltration.^[63] Short-term (weeks to months) efficacy of coeliac plexus block has been reported to be as high as 80%.^[64] Although reports of short-term efficacy of coeliac block is very encouraging, its long-term benefit is debatable.^[52,65]

In the coeliac plexus block, phenol or 50% alcohol is used to block afferent nerve impulses from the bed infiltrated by the tumour. About 50% alcohol is prepared by diluting absolute alcohol with sterile water in a ratio of 1:1. The coeliac plexus block is carried out by injecting 20 mL of 50% alcohol on either side of the aorta at the level of coeliac trunk. Intra-operative palpation of the coeliac trunk bruits can aid in correct placement of the block.

Relieve of Ascites

Aetio-pathogenic mechanisms for malignant ascites include increased vascular permeability, venous obstruction, and reduced lymphatic drainage due to obstruction by tumour emboli.^[2] Malignant ascites occur in about 20% of pancreatic cancers.^[66] Abdominal paracentesis for malignant ascites has diagnostic and therapeutic roles. A positive cytology or a negative cytology plus low ascitic blood glucose and low serum ascites albumin gradient (SAAG) of <1.1 indicates malignant ascites.^[67] Paracentesis for therapeutic drainage of ascites can be effective but relief from this procedure is only temporary. Repeated paracentesis predisposes patients to iatrogenic gut perforation and ascitic fluid infection and peritonitis.^[68] Peritovenous shunts have also been reported but there is currently not enough evidence to support its routine use.^[68] Permanent in-dwelling catheters are also used for intermittent ascitic fluid drainage in daily aliquots. These are not readily available in our settings.

Other Supportive Care

Anorexia is almost universal in most patients with obstructive jaundice and contributes in part to weight loss found in most of these patients. While palliation may be effective in relief of pain, gastric outlet obstruction, and pruritus, anorexia tends to persist after surgery for MOJ although there is a report of patients with improved caloric intake after internal drainage for biliary obstruction.^[69]

Conclusion

Surgical palliation in obstructing MOJ is desirable in settings in which minimally invasive and endoscopic approaches are not available. Surgical bypass is associated with morbidity and mortality but may offer significant and long-lasting relief from abdominal pain, pruritus, and gastric outlet obstruction. Relief from these symptoms can lead to improvement in patients' overall QOL. Adequate pre-operative optimization of the

patients' clinical status plays a major role in the success of these complex procedures. The choice of appropriate palliative procedure should be on a case-by-case basis, depending on the overall fitness and life expectancy of the patient. Newer pieces of evidence are in support of prophylactic gastrojejunostomy in patients with locally advanced pancreatic cancer. Intra-operative coeliac plexus block offers effective pain palliation in the short term. Paracentesis for ascites may be indicated in the minority of patients.

Declaration of patient consent

The authors certify that they have obtained all appropriate patient consent forms. In the form the patient(s) has/have given his/her/their consent for his/her/their images and other clinical information to be reported in the journal. The patients understand that their names and initials will not be published and due efforts will be made to conceal their identity, but anonymity cannot be guaranteed.

Financial support and sponsorship

Nil.

Conflicts of interest

There are no conflicts of interest.

REFERENCES

1. Chalya PL, Kanumba ES, McHembe M. Etiological spectrum and treatment outcome of obstructive jaundice at a university teaching hospital in northwestern Tanzania: A diagnostic and therapeutic challenges. *BMC Res Notes* 2011;4:147.
2. Sangisetty SL, Miner TJ. Malignant ascites: A review of prognostic factors, pathophysiology and therapeutic measures. *World J Gastrointest Surg* 2012;4:87-95.
3. Malik NK, May KS, Chandrasekhar R, Wee W, Flaherty L, Iyer R, *et al.* Treatment of locally advanced unresectable pancreatic cancer: A 10-year experience. *J Gastrointest Oncol* 2012;3:326-34.
4. Erturk IE, Arican O, Omurlu IK, Sut N. Effect of the pruritus on the quality of life: A preliminary study. *Ann Dermatol* 2012;24:406-12.
5. Huesmann M, Huesmann T, Osada N, Phan NQ, Kremer AE, Ständer S. Cholestatic pruritus: A retrospective analysis on clinical characteristics and treatment response. *J Dtsch Dermatol Ges* 2013;11:158-68.
6. Bonheur JL. Biliary Obstruction: Background, Pathophysiology, Etiology [Internet]. Available from: <https://emedicine.medscape.com/article/187001-overview#a5>. [Last accessed on 2022 Jun 16].
7. Assy N, Jacob G, Spira G, Edoute Y. Diagnostic approach to patients with cholestatic jaundice. *World J Gastroenterol* 1999;5:252-62.
8. Kumar A, Rai A, Jha NK. Observation of renal function in patients with surgical jaundice. *Hong Kong J Nephrol* 2014;16:12-8.
9. Greig JD, Krukowski ZH, Matheson NA. Surgical morbidity and mortality in one hundred and twenty-nine patients with obstructive jaundice. *Br J Surg* 1988;75:216-9.
10. Boulay BR, Birg A. Malignant biliary obstruction: From palliation to treatment. *World J Gastrointest Oncol* 2016;8:498-508.

11. Miner TJ, Jaques DP, Karpeh MS, Brennan MF. Defining palliative surgery in patients receiving noncurative resections for gastric cancer. *J Am Coll Surg* 2004;198:1013-21.
12. Lorenz JM. Management of malignant biliary obstruction. *Semin Intervent Radiol* 2016;33:259-67.
13. L  uffer JM, Mai G, Berchtold D, Curti CG, Triller J, Baer HU. Multidisciplinary approach to palliation of obstructive jaundice caused by a central hepatocellular carcinoma. *Dig Surg* 1999;16:531-6.
14. Fernandez Y, Viesca M, Arvanitakis M. Early diagnosis and management of malignant distal biliary obstruction: A review on current recommendations and guidelines. *Clin Exp Gastroenterol* 2019;12:415-32.
15. Gouma DJ, Busch ORC, Van Gulik TM. Pancreatic carcinoma: Palliative surgical and endoscopic treatment part of this article will be published in Blumgart, *Surgery of the Liver, Biliary Tract and Pancreas*. HPB 2006;8:369-76.
16. Michael O, Gerald T, Viola N, Steven B, Ponsiano O. Pioneering endoscopic retrograde cholangiopancreatography in a Sub Saharan African hospital: A case series. *Int J Surg Open* 2018;15:14-7.
17. Alatise OI, Owojuyigbe MO, Omisore AC, Ndububa DA, Aburime E, Dua KS AA, *et al.* Endoscopic management and clinical outcomes of obstructive jaundice. *Niger Postgrad Med J* 2020;27:302-10.
18. Agbo SP, Oboirien M. Obstructive jaundice : A review of clinical experience in resource limited setting. *Merit Res J Med Med Sci* 2017;5:349-53.
19. Lawal D, Oluwole S, Makanjuola D, Adekunle M. Diagnosis, management and prognosis of obstructive jaundice in Ile-Ife, Nigeria. *West Afr J Med* 1998;17:255-60.
20. Rahman GA, Yusuf IF, Faniyi AO, Etonyeaku AC. Management of patients with obstructive jaundice: Experience in a developing country. *Nig Q J Hosp Med* 2011;21:75-9.
21. Olatoke SA, Agodirin SO, Adenuga AT, Adeyeye AA, Rahman GA. Management of obstructive jaundice: Experience in a north central Nigerian hospital. *Trop J Heal Sci* 2018;25:21-5.
22. Kabashi S, Dedushi K, Ramadani N, Mucaj S, Hoxhaj A, Jerliu N. Pancreatic carcinoma: The disease that kills. *World J Oncol* 2016;7:13-6.
23. IARC. Nigeria. 2020. IARC Sci Publ 2021;2020-1.
24. Journals O. JNCI journal of the National Cancer Institute way to better DNA. *Ann Intern Med* 2008;37:1-9.
25. Pannala R, Basu A, Petersen GM, Chari ST. New-onset diabetes: A potential clue to the early diagnosis of pancreatic cancer. *Lancet Oncol* 2009;10:88-95.
26. Biliary Tract | Current Diagnosis and Treatment: Surgery, 14e | AccessSurgery | McGraw-Hill Medical [Internet]. Available from: <https://accesssurgery.mhmedical.com/content.aspx?sectionid=71521210&bookid=1202>. [Last accessed on 2022 Jun].
27. Lee HJ, Cho KB. Diagnosis of malignant biliary stricture: More is better. *Clin Endosc* 2018;51:115-7.
28. Singh A, Gelrud A, Agarwal B. Biliary strictures: Diagnostic considerations and approach. *Gastroenterol Rep (Oxf)* 2015;3:22-31.
29. Gonzalez FJ. Nuclear receptor control of enterohepatic circulation. In: *Comprehensive Physiology*. Bethesda, MD: John Wiley & Sons, Inc.; 2012. p. 2811.
30. Fazal S, Saif MW. Supportive and palliative care of pancreatic cancer. *JOP* 2007;8:240-53.
31. Green J, Better OS. Systemic hypotension and renal failure in obstructive jaundice—Mechanistic and therapeutic aspects. *J Am Soc Nephrol* 1995;5:1853-71.
32. Ballehaninna UK, Chamberlain RS. The clinical utility of serum CA 19-9 in the diagnosis, prognosis and management of pancreatic adenocarcinoma: An evidence based appraisal. *J Gastrointest Oncol* 2012;3:105-19.
33. Levy AD. Noninvasive imaging approach to patients with suspected hepatobiliary disease. *Tech Vasc Interv Radiol* 2001;4:132-40.
34. Ihse I, Axelson J, Dawiskiba S, Hansson L. Pancreatic biopsy: Why? When? How? *World J Surg* 1999;23:896-900.
35. Rajagopalan V, Daines WP, Grossbard ML, Kozuch P. Gallbladder and biliary tract carcinoma: A comprehensive update, part 1. *Oncology (Williston Park)* 2004;18:889-96.
36. Gold JS, Zinner MJ, Whang EE. Cancer of the gallbladder and bile ducts. In: Zinner MJ, Ashley SW, editors. *Maingot's Abdominal Operations*. 13th ed. New York: McGraw-Hill; 2019. p. 2989-3045.
37. Lombardo KMR, Barton JSM. Operative palliation of pancreatic cancer. In: Fischer JE, editor. *Hepatobiliary and Pancreatic Surgery*. Philadelphia: Lippincott Williams and Wilkins; 2013. p. 59-76.
38. Cameron JL. Society ACC. Surgical Palliation of Pancreatic Cancer. In: Cameron J, editor. *Pancreatic Cancer*. PMPH-USA: BC Decker; 2001. p. 274.
39. Altaf Hussain Talpur K, Malik AM, Memon AI, Qureshi JN, Sangrasi AK, Laghari AA. Biliary bypass surgery—Analysis of indications and outcome of different procedures. *Pakistan J Med Sci* 2013;29:799-802.
40. Connor S, Wigmore SJ, Madhavan KK, Parks RW, Garden OJ. Surgical palliation for unresectable hilar cholangiocarcinoma. *HPB (Oxford)* 2005;7:273-7.
41. Kester JE. Liver. *Encyclopedia of Toxicology*. 3rd ed. London: Academic Press; 2014. p. 591.
42. Lippman HN, Longmire WP. Intrahepatic cholangiojejunostomy: An operation for biliary obstruction. *Surg Clin North Am* 1956;36:849-63.
43. Goh HS, Rauff A, Fong WC, Tan L. Modified Longmire operation for proximal extrahepatic biliary obstruction. *Singapore Med J* 1984;25:92-6.
44. Singh VP, Mukhopadhyay HG, Kaushik R, Kannan N. Intrahepatic cholangiojejunostomy for malignant hilar biliary obstruction: Approach to the left hepatic duct. *Med J Armed Forces India* 1998;54:21-2.
45. Suzuki S, Kurachi K, Yokoi Y, Tsuchiya Y, Okamoto K, Okumura T, *et al.* Intrahepatic cholangiojejunostomy for unresectable malignant biliary tumors with obstructive jaundice. *J Hepatobiliary Pancreat Surg* 2001;8:124-9.
46. Traynor O, Castaing D, Bismuth H. Left intrahepatic cholangio-enteric anastomosis (round ligament approach): An effective palliative treatment for hilar cancers. *Br J Surg* 1987;74: 952-4.
47. Kapoor V, Haribhakti R, Singh PSP, Sikora V, Saxena S, Kaushik SR. Surgical management of benign biliary stricture: Hepatico-jejunostomy, post-cholecystectomy bile duct injury. *BJS Soc* 1996;83:1709-11.
48. Lesurtel MCP. Pancreatic surgery. In: Mathew W, Guy M, editors. *Palliative Surgery*. London: Springer-Heidelberg; 2014. p. 154-6.
49. Criostoir B, O'Suilleabhain MD, Krishnak K, Madhavan MS, A modification of segment III intrahepatic cholangiojejunostomy. *Am J Surg* 2004;187:131-133.
50. Cho CS, D'Angelica MI. Bile duct exploration and biliary-enteric anastomosis. In: Blumgart's *Surgery of the Liver, Biliary Tract, and Pancreas*. London: Elsevier Inc.; 2012. p. 470-80.

51. Jarnagin WR, Burke E, Powers C, Fong Y, Blumgart LH. Intrahepatic biliary enteric bypass provides effective palliation in selected patients with malignant obstruction at the hepatic duct confluence. *Am J Surg* 1998;175:453-60.
52. Bornman PCKJ. Rob and Smith operative surgery. In: David Rusell R, Pitt CG, Henry Bismuth H, editors. *Hepatobiliary and Pancreatic Surgery*. Fifth Carter. New York: Chapman and Hall Medical; 1996. p. 674.
53. Wolff RA, Abbruzzese J, Evans DB. Neoplasms of the exocrine pancreas. In: Kufe DW, Pollock RE, Weichselbaum RR, *et al.*, editors. *Holland-Frei Cancer Medicine*. 6th ed. Hamilton: BC Decker; 2003. Available from: <https://www.ncbi.nlm.nih.gov/books/NBK13053>.
54. Weintraub S, Grünspan M, Singer D. Hepaticocholecystostomy and cholecystojejunostomy for bile drainage. A palliative procedure. *Am J Surg* 1980;139:441-2.
55. Gani J, Lewis K. Hepaticocholecystoenterostomy as an alternative to hepaticojejunostomy for biliary bypass. *Ann R Coll Surg Engl* 2012;94:472-5.
56. Potz BA, Miner TJ. Surgical palliation of gastric outlet obstruction in advanced malignancy. *World J Gastrointest Surg* 2016;8:545-55.
57. Thor PJ, Popiela T, Sobocki J, Herman RM, Matyja A, Huszno B. Pancreatic carcinoma-induced changes in gastric myoelectric activity and emptying. *Hepatogastroenterology* 2002;49:268-70.
58. Gouma DJ. Blumgart's *Surgery of the Liver, Biliary Tract, and Pancreas*. 5th ed. London: Elsevier Inc.; 2012. p. 979-88.
59. Van Heek NT, De Castro SMM, Van Eijck CH, Van Geenen RCI, Tran TCK, Kazemier G, *et al.* The need for a prophylactic gastrojejunostomy for unresectable periampullary cancer. *Ann Surg* 2003;238:894-905.
60. Khan IM, Aurangzeb M, Mujeeb-Ur-Rahman, Tayyab M. Palliative surgery for pancreatic carcinoma. *J Coll Physicians Surg Pak* 2010;20:719-22.
61. Gurusamy K, Kumar S, Davidson B. Prophylactic gastrojejunostomy for unresectable periampullary carcinoma. *Cochrane Database Syst Rev* (Online) 2010;2:CD008533.
62. Kudo Y, Sato N, Tamura T, Hirata K. Triple bypass for advanced pancreatic head cancer associated with biliary stricture, duodenal stenosis, and recurrent obstructive pancreatitis. *Surg Case Rep* 2016;2:79.
63. Arcidiacono PG, Rossi M. Celiac plexus neurolysis. *JOP* 2004;5:315-21.
64. Gao L, Yang YJ, Xu HY, Zhou J, Hong H, Wang YL, *et al.* A randomized clinical trial of nerve block to manage end-stage pancreatic cancerous pain. *Tumour Biol* 2014;35:2297-301.
65. Camern JL, Sandone C. *Atlas of Gastrointestinal Surgery*. 2nd ed. Ontario: BC Decker; 2007. p. 561.
66. Adam RA, Adam YG. Malignant ascites: Past, present, and future. *J Am Coll Surg* 2004;198:999-1011.
67. Huang L, Xia HH, Zhu S. Review article ascitic fluid analysis in the differential diagnosis of ascites: Focus on cirrhotic ascites. *J Clin Transl Hepatol* 2014;2:58-64.
68. Reilly EMO. Adjuvant and neoadjuvant systemic therapy for pancreas adenocarcinoma. *Semin Oncol* 2015;42:134-43.
69. Padillo FJ, Andicoberry B, Naranjo A, *et al.* Anorexia and the effect of internal biliary drainage on food intake in patients with obstructive jaundice. *J Am Coll Surg* 2001;192:584-90.