

## Research

# Severe reperfusion lung injury after double lung transplantation

Giorgio Della Rocca<sup>1</sup>, Federico Pierconti<sup>2</sup>, Maria Gabriella Costa<sup>2</sup>, Cecilia Coccia<sup>2</sup>, Livia Pompei<sup>2</sup>, Monica Rocco<sup>1</sup>, Federico Venuta<sup>3</sup> and Paolo Pietropaoli<sup>4</sup>

<sup>1</sup>Associate Professor, Istituto di Anestesiologia e Rianimazione, University of Rome 'La Sapienza', Rome, Italy

<sup>2</sup>Assistant, Istituto di Anestesiologia e Rianimazione, University of Rome 'La Sapienza', Rome, Italy

<sup>3</sup>Associate Professor, Cattedra di Chirurgia Toracica, University of Rome 'La Sapienza', Rome, Italy

<sup>4</sup>Director of Department, Istituto di Anestesiologia e Rianimazione, University of Rome 'La Sapienza', Rome, Italy

Correspondence: Giorgio Della Rocca, giorgio.dellarocca@uniroma1.it

Received: 15 November 2001

*Critical Care* 2002, **6**:240-244

Revisions requested: 14 January 2002

Revisions received: 21 February 2002

Accepted: 7 March 2002

Published: 1 May 2002

© 2002 Della Rocca *et al.*, licensee BioMed Central Ltd  
(Print ISSN 1364-8535; Online ISSN 1466-609X)

## Abstract

**Aim:** To demonstrate the effects of combined inhaled nitric oxide and surfactant replacement as treatment for acute respiratory distress syndrome. This treatment has not previously been documented for reperfusion injury after double lung transplantation.

**Method:** A 24-year-old female with cystic fibrosis underwent double lung transplantation. During implantation of the second lung a marked increase in pulmonary artery pressure associated with systemic hypotension, hypoxemia and low cardiac output were observed. Notwithstanding the patient received support from cardiovascular drugs and pulmonary vasodilators cardiopulmonary by-pass was necessary. In the intensive care unit the patient received the same drug support, inhaled nitric oxide and two bronchoscopic applications of bovine surfactant.

**Results:** A rapid improvement in PaO<sub>2</sub>/FiO<sub>2</sub> within 2–3 hours of administration of surfactant was seen. The patient is well at follow-up 1 year post-transplant.

**Conclusion:** There is a potential role for a combined therapy with inhaled nitric oxide and surfactant replacement in reperfusion injury after lung transplantation.

**Keywords:** inhaled nitric oxide, lung transplantation, reperfusion injury, surfactant.

## Introduction

Reperfusion injury is one of the major causes of early morbidity and mortality after lung transplantation [1]. In animal experiments the role of surfactant in the reduction of early reperfusion injury during lung transplantation has been widely investigated, but only recently have data become available for humans [2]. Ischemia reperfusion injury is characterized by pulmonary edema caused by endothelial dysfunction, platelet aggregation, and neutrophil activation and sequestration. Particularly at the time of reperfusion, free radicals are produced in the endothelial cell membranes and in neutrophils causing an increase in cell membrane permeability [1]. Lipid peroxida-

tion can also occur during ischemia reperfusion injury [3]. In addition, sludging of red blood cells, together with the obstruction by white blood cells, vasospasm and the narrowing of the vessel lumen as a result of the edema of the vascular endothelium, can cause blood flow from the arterioles into the capillaries to be markedly diminished (i.e. the no-reflow phenomenon). Moreover, inadequate surfactant function was found in all patients after lung transplantation [4].

During respiratory distress syndrome of premature infants, surfactant replacement therapy plays a fundamental role. These benefits have provoked interest in the use of surfactant

**Table 1****Hemodynamic and oxygenation data from the preoperative period to the application of surfactant**

	Baseline	Clamping 1	Reperfusion 1	Clamping 2	Reperfusion 2	Final	Pre-surfactant	Post-surfactant
pH	7.43	7.21	7.02	7.29	7.15	7.30	7.53	7.50
SvO <sub>2</sub> (%)	67.1	69.6	68	28	30	38.4	50.3	63.9
PaCO <sub>2</sub> (mmHg)	57	91.6	65	114	95	80.1	50	52
PaO <sub>2</sub> /FiO <sub>2</sub> (mmHg)	353	218	240	50	45	39	46	250
MAP (mmHg)	95	83	87	38	50	45	103	80
MPAP (mmHg)	32	43	41	65	37	31	29	23
CI (l/min/m <sup>2</sup> )	3.3	2.6	4.9	1.1	2.4	2.4	3.3	3.7
CVP (mmHg)	10	8	9	12	16	8	8	9
EVLWI (ml/kg)	9.7	7.3	6.9	32.4	45.2	37.1	21	19
ITBVI (ml/m <sup>2</sup> )	615	483	684	691	672	704	853	900

↑ CPB

Baseline, with both lungs mechanically ventilated; 1,2, 1st and 2nd lung; MPAP, mean pulmonary arterial pressure; CI, cardiac index; EVLWI, extravascular lung water index; ITBVI, intrathoracic blood volume; pre-surfactant, before surfactant administration; post-surfactant, after surfactant replacement (3 days after end of surgical procedure); CPB, cardiopulmonary bypass; CVP, central venous pressure.

in the treatment of acute respiratory distress syndrome (ARDS). The surfactant alterations in ARDS are thought to contribute significantly to lung dysfunction. In several case reports, successful surfactant replacement has been demonstrated [5]. Exogenous surfactant therapy has been shown to be effective in severe animal models of acute lung injury. In this case report, we describe the effects of combined inhaled nitric oxide (INO) and surfactant replacement therapy in a patient with severe reperfusion injury during and after double lung transplantation for cystic fibrosis.

## Methods

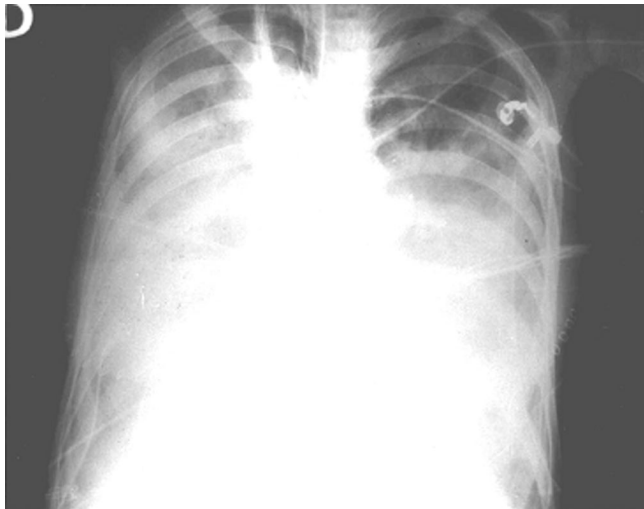
A young woman (24 years old, weight 40 kg, height 150 cm), with end-stage lung disease from cystic fibrosis was admitted for double lung transplantation. A pulmonary artery catheter facilitating continuous cardiac output and mixed venous oxygen saturation (SvO<sub>2</sub>) (Vigilance Intelicath Baxter, Irvine, CA, USA), was placed in the left or right subclavian or internal jugular vein. A 4 FR catheter was inserted into the femoral artery and connected to the PiCCO monitor (pulse contour continuous cardiac output; Pulsion Medical System, Munich, Germany); this allowed evaluation of continuous cardiac output, intrathoracic blood volume and extra lung water index through the single indicator technique. Transesophageal echocardiography (Sonos 2500 HP, Mc Minville, Oregon, USA) and routine monitors were also attached. Preoperative hemodynamic and oxygenation data are reported in Table 1 (baseline). The lungs were stored in hypothermic preserving solution until implantation. The solution used was EuroCollins modified (S.A.L.F. Bergamo, Italy) (used in most lung transplant centers). Double lung transplantation was performed

using the bilateral sequential single lung technique. The first lung transplantation (left) was successfully performed without cardiopulmonary bypass (Table 1, Reperfusion 1) with 6 hours of ischemia time. The surgical procedure was complicated when the right pulmonary artery was clamped (Table 1, Clamping 2). The transesophageal echocardiography showed evidence of right ventricular failure and of an increase in right ventricular chamber dysfunction with a MPAP of 65 mmHg and a severe wall motion abnormality; at this time a marked increase in pulmonary artery pressure was observed, in association with systemic hypotension and oxygen desaturation (SpO<sub>2</sub> and SvO<sub>2</sub>) and a decrease in cardiac output. At this time prostaglandin E<sub>1</sub> (40 µg/kg/min) by continuous infusion and INO (40 ppm) were administered. Therefore, cardiovascular drugs such as dobutamine (10 µg/kg/min), dopamine (7 µg/kg/min), enoximone, norepinephrine (0.7 µg/kg/min) and ephedrine (25 mg) were required to support the systemic pressure. Cardiopulmonary bypass was used to facilitate pneumonectomy of the right lung. The second lung (right) was reperfused after 35 min of cardiopulmonary bypass. Soon after the reperfusion of the second lung, a severe lung injury developed.

Oxygenation could be maintained using FiO<sub>2</sub> = 1 and high positive end-expiratory pressure (PEEP = 10 cmH<sub>2</sub>O and inspiration:expiration [I:E] ratio = 1:1). Continuous main bronchial suction was performed to reduce fluids in the airways (a total of 2000 ml).

After 7 hours the surgical procedure finished. The patient received a bronchial lavage through a fiberoptic broncho-

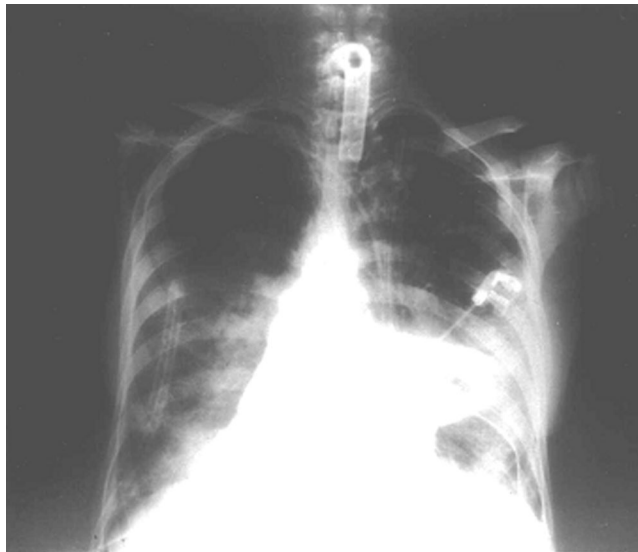
Figure 1



Chest X-ray film 2 hours after double lung transplantation before surfactant replacement therapy, revealing edema of transplanted lungs.

scope and was then transferred to the intensive care unit (Fig. 1) supported by the same regimen of cardiovascular drugs and pulmonary vasodilators. In the intensive care unit the patient was ventilated in control mode ventilation by a Servo 900C Ventilator (Siemens Elema, Solna, Sweden) with pressure support ventilation of 20 cmH<sub>2</sub>O, a tidal volume of 8 ml/kg, FiO<sub>2</sub> = 1, I:E = 1:1, and PEEP of 10 cmH<sub>2</sub>O in the supine position. The clinical condition did not change after 2 days (Fig. 1). Then 400 mg/kg of porcine surfactant (Curosurf®; Chiesi Farmaceutici, Parma, Italy) was delivered via the fiberoptic bronchoscope directly into the right and the left main bronchi. The instillation of surfactant was approved by the local ethics committee. During this application, the position of the patient (supine) and the ventilator settings were not changed. After 2.5 hours, in response to the surfactant application, we observed modifications of hemodynamic and oxygenation data (Table 1, Pre-surfactant and Post-surfactant). An increase of PaO<sub>2</sub>/FiO<sub>2</sub> from 46 to 250 mmHg was observed. In addition, an amelioration of mean pulmonary arterial pressure and SvO<sub>2</sub> was noted. The surfactant therapy was repeated after 12 hours. The edema of the transplanted lungs on chest X-ray film was remarkably reduced the day after the surfactant replacement therapy still associated with INO administration. The patient was planned to be extubated when clinically indicated by the following criteria for discontinuation of mechanical ventilation: PaO<sub>2</sub> >120 mmHg, where the FiO<sub>2</sub> was 0.4 and the pH >7.37, SvO<sub>2</sub> >65%, hemodynamic stability and presence of spontaneous breathing. A tracheotomy was performed 7 days after the surgical procedure (5 days after surfactant replacement), and 2 days later the patient was extubated (Fig. 2). The total length of stay in the intensive care unit was 20 days. The patient was discharged from the hospital 45 days after double lung transplantation, and 1 year later she is still enjoying good health.

Figure 2



Chest X-ray film 5 days after double lung transplantation following surfactant replacement therapy.

## Results

Lung reperfusion injury remains one of the major complications during the early postoperative course, with respiratory distress usually occurring 6–12 hours after lung transplantation [1]. Although the pathogenesis of reperfusion injury after lung transplantation is not completely understood, it is generally accepted that an inflammatory response as a result of activation of leukocytes and platelets may play an important role. Additional signs are capillary leakage of the graft with an infiltrate on chest X-ray, pleural effusions and lung edema [1]. One of the main symptoms is a steadily increasing oxygen demand on the ventilator, but the complete failure of the graft may also occur.

In 1967, Ashbaugh and colleagues [6] first described ARDS and suggested that abnormalities of pulmonary surfactant could be involved in the pathophysiology of the lung injury. Generally, the administration of surfactant after lung transplantation is based on experimental findings that indicate an alteration in surfactant composition and function after transplantation [1]. In our case report the improvement of gas exchange and the amelioration of pulmonary edema that followed the administration of surfactant associated with INO, reversed a life-threatening situation. These effects may be attributed to a typical response to surfactant therapy.

The use and the method of delivery of pulmonary surfactant has prompted considerable debate. Several studies described various strategies for surfactant administration and preparation, for the timing of the treatment, for the dosage and the frequency of administration, and for ventilator settings [2,7]. Among the strategies proposed in the literature for

surfactant administration, we preferred the bronchoscopic instillation to aerosolized surfactant, based on recent findings showing the superiority of instilled surfactant [8]. In addition, no significant effects have been found after the continuous administration of aerosolized surfactant [7].

With respect to the ventilator strategies, it has been demonstrated in different animal models that for the same peak or mean airway pressure, ventilation with PEEP at lower tidal volumes results in less edema than would occur with ventilation using zero PEEP and ventilation with higher tidal volumes. The use of PEEP prevents alveolar flooding and reduces endothelial and epithelial injury [9]. In our case, the use of PEEP of 10 cmH<sub>2</sub>O did not prevent pulmonary edema.

Different studies have examined the beneficial effects of PEEP on the surfactant system. In 1975, Wyszogrodski *et al.* showed that PEEP prevents a decrease in lung compliance and surface activity of lung extract, indicating a preventive loss of alveolar surfactant function during lung overinflation [10]. In addition, because PEEP prevents alveolar collapse, it maintains the end-expiratory volume of alveoli at a higher level, and prevents excessive loss of surfactant in the small airways by surfactant being 'squeezed out' of the alveoli during expiration. More recent studies have shown that the rate of conversion of large surfactant into small aggregates is dependent on tidal volume and time [11], while respiratory rate or PEEP level did not affect surfactant conversion [11]. These studies suggest that the preservation of the surfactant system by PEEP is a result of the reduction of cyclic changes in the surface areas of the alveoli. In our case, after the amelioration of gas exchange, PEEP was decreased from 10 to 5 cmH<sub>2</sub>O and then to zero before complete withdrawal of treatment.

Episodes of lung injury after extracorporeal membrane oxygenation have been reported in the literature [2]. The frequency increases with increased duration of extracorporeal membrane oxygenation. The lung injury is mainly initiated by shear forces and from contact of the venous blood with non-physiological surfaces of the extracorporeal circuit, resulting in activated platelets and polymorphonuclear granulocytes, mediator release and activation of the complement and kallikrein-kinin system. Griese *et al.* found impaired surfactant function as indicated by deterioration in surface activity from day 0 to day 3 after bypass [2].

## Conclusion

In conclusion, our results show an amelioration of the lung injury as a result of surfactant replacement. The beneficial effect may be because of the replacement of surfactant when production is impaired after hypoxia. In an experimental lung transplantation model, normal surfactant function in the reperfusion period was found only after exogenous substitution [12]. In the setting of continued use of INO shortly after transplant, the addition of surfactant replacement led to a rapid

improvement in oxygenation. It should be noted that the INO therapy itself did not produce any amelioration of the lung injury in the early period after transplantation. Lung function improvement occurred only after surfactant replacement, which was used in combination with INO therapy. We cannot hypothesize what would have happened without the use of INO. The combination of INO and surfactant has been used by Struber *et al.* in one case of injury of the lung with an episode of ischemia and reperfusion, which can be considered similar to the reperfusion injury occurring after lung transplantation [13]. During the continuous administration of INO, they applied synthetic surfactant through a bronchoscope into the left and right main bronchi, to improve gas exchange and lung compliance. They hypothesized that INO improves perfusion of well-ventilated alveoli, increasing the number of alveoli available for ventilation. These additional alveoli are recruited by the additional surfactant [13].

To our knowledge, surfactant replacement therapy has not been used for lung injury reperfusion occurring in the early post-transplantation period. Our data suggest a potential role for a combined therapy with INO and surfactant replacement in reperfusion injury after lung transplantation. This combined approach has to be confirmed by a systematic randomized, controlled study.

### Key messages

- Combined therapy with inhaled nitric oxide, intravenous prostaglandin E<sub>1</sub> plus surfactant replacement may play a role in the treatment of the reperfusion injury after lung transplantation.
- The effect of the surfactant therapy without inhaled nitric oxide needs further investigation.

## Competing interests

None declared.

## References

1. Struber M, Hirt SW, Cremer J, Harringer W, Haverich A: **Surfactant replacement injury after clinical lung transplantation.** *Intensive Care Med* 1999, **25**:862-864.
2. Griese M: **Pulmonary surfactant in health and human lung diseases: state of the art.** *Eur Respir J* 1999, **13**:1455-1476.
3. Yamagishi H, Yamashita C, Okada M: **Preventive influence of inhaled nitric oxide on lung ischemia-reperfusion injury.** *Jpn J Surg* 1999, **29**:897-901.
4. Hohlfeld JM, Tiryaki E, Hamm H, Hoymann HG, Krug N, Haverich A, Fabel H: **Pulmonary surfactant activity is impaired in lung transplant recipients.** *Am J Respir Crit Care Med* 1998, **158**:706-712.
5. Richman PS, Spragg RG, Robertson B, Merritt TA, Curstedt T: **The adult respiratory distress syndrome: first trials with surfactant replacement.** *Eur Respir J* 1989, **2**:109-111.
6. Ashbaugh DG, Bigelow DB, Petty TL, Levine BE: **Acute respiratory distress syndrome in adults.** *Lancet* 1967, **2**:319-323.
7. Anzueto A, Baughmann RP, Guntupalli KK, Weg JG, Wiedemann HP, Raventos AA, Lemaire F, Long W, Zaccardelli DS, Pattishall EN: **Aerosolized surfactant in adults with sepsis-induced acute respiratory distress syndrome.** *N Engl J Med* 1996, **334**:1417-1421.

8. Lewis JF, Tabor B, Ikegami M, Jobe AH, Joseph M, Absolom D: **Lung function and surfactant distribution in saline lavaged sheep given instilled vs. nebulized surfactant.** *J Appl Physiol* 1993, **74(3)**:1256-1264.
9. Dreyfuss D, Saumon G: **Ventilator-induced lung injury. Lesson from experimental studies.** *Am J Respir Crit Care Med* 1998, **157**:294-323.
10. Wyszogrodski I, Kyei-Aboagye K, Taeusch HW Jr, Avery ME: **Surfactant inactivation by hyperinflation: conservation by end-expiratory pressure.** *J Appl Physiol* 1975, **38**:461-466.
11. Veldhuizen RA, Marcou J, Yao LJ, McCaig L, Ito Y, Lewis JF: **Alveolar surfactant aggregate conversion in ventilated normal and injured rabbits.** *Am J Physiol* 1996, **270**:152-158.
12. Friedrich I, Splittgerber FH, Gunther A: **Influence of trans-bronchial surfactant administration on lung function and surfactant attributes after single lung transplantation.** *J Heart Lung Transplant* 1997, **16**:113.
13. Struber M, Brandt M, Cremer J, Harringer W, Hirt SW, Haverich A: **Therapy for lung failure using nitric oxide inhalation and surfactant replacement.** *Ann Thorac Surg* 1996, **61**:1543-1545.