


Conflicts of interest

None declared.

References

1. Calonje E. Tumours of the skin appendages. In: Burns T, Breathnach S, Cox N, Griffiths C, editors. *Rook's Textbook of Dermatology*. 8th ed. Oxford: Blackwell Publishing Ltd; 2010. p. 53.11–2.
2. Gumaste P, Ortiz A, Patel A, Baron J, Harris R, Barr R. Generalized basaloid follicular hamartoma syndrome: a case report and review of the literature. *Am J Dermatopathol*. 2015;37:37–40.
3. Mills O, Thomas B. Basaloid follicular hamartoma. *Arch Pathol Lab Med*. 2010;134:1215–9.
4. Kouzak SS, Mendes MS, Costa IM. Cutaneous mosaicism: concepts, patterns and classifications. *An Bras Dermatol*. 2013;88:507–17.

Gabriela Martins de Queiroz *, Tayla Cristina Lopes ,
 Maria Clara Dantas Valle Soares ,
 Carlos Bruno Fernandes Lima 

Universidade Potiguar, Natal, RN, Brazil

* Corresponding author.

E-mail: gabrielamartins96@yahoo.com.br (G.M. Queiroz).

Received 28 August 2020; accepted 23 October 2020

Available online 21 September 2022

<https://doi.org/10.1016/j.abd.2020.10.027>
 0365-0596/ © 2022 Published by Elsevier España, S.L.U. on behalf of Sociedade Brasileira de Dermatologia. This is an open access article under the CC BY license (<http://creativecommons.org/licenses/by/4.0/>).

Congenital infantile fibrosarcoma: a rare tumor dermatologists should know about[☆]



Dear Editor,

A seven-month-old female patient presented with a history of a congenital, violaceous, fast-growing lesion located on the right plantar surface. Dermatological examination disclosed the presence of a firm spherical tumor, with dilated vessels on the surface, and central ulceration with friable, bleeding tissue, and hematic crusts (Fig. 1A). The child developed severe anemia (hemoglobin of 4.4 g/dL), requiring a blood transfusion. The platelet count was normal. Histopathology was suggestive of kaposiform hemangioendothelioma. Treatment with oral prednisolone (2 mg/kg/day) was started but was interrupted after one month, due to lack of a response (Fig. 1B).

Magnetic resonance imaging (MRI) and magnetic resonance angiography (MRA) disclosed a well-vascularized solid mass, with the involvement of the underlying muscles and extending to the anterior aspect of the foot. Diffuse contrast enhancement was observed throughout the lesion, with no signs of arteriovenous shunts or a cluster of tortuous vessels (nidus), thus ruling out the diagnosis of a vascular tumor, including kaposiform hemangioendothelioma (Figs. 2A and 2B). A second biopsy was performed, revealing a hypercellular fusiform tumor. Immunohistochemistry was positive for vimentin and negative for CD31, CD34, factor VIII, desmin, MyoD1, myogenin, CD99 and EMA, indicating the diagnosis of congenital infantile fibrosarcoma (CIF).

The patient was submitted to neoadjuvant chemotherapy (vincristine, actinomycin-D and cyclophosphamide) to reduce tumor size (Fig. 1C), followed by amputation of the foot. There are no signs of recurrence or metastasis at five years of follow-up.

CIF is a rare malignant tumor of childhood; however, it is the most common soft tissue sarcoma in children under one year of age.¹ This highly vascularized congenital tumor is difficult to clinically differentiate from vascular tumors or malformations. It may be present at birth or develop during the first five years, with approximately 80% of cases diagnosed during the first year of life.²

Fibrosarcomas are malignant neoplasias composed of mesenchymal fibroblasts. The infantile variant shares histopathological characteristics with adult fibrosarcoma but has a better prognosis. Although local recurrences are common, the rate of CIF metastasis is less than 10% and the ten-year survival rate is up to 90%.³ The extremities are more commonly affected and lesions located on the trunk, head and neck are less frequent, although they are more aggressive.^{1,4} Due to the risk of local recurrence, extensive surgical resection is recommended. Surgery alone shows recurrence rates of 17% to 40%. Neoadjuvant chemotherapy reduces the risk of local recurrence and metastases.^{2,3,5}

The histopathological findings of CIF include the proliferation of dense fusiform cells and vascularized areas. Immunohistochemistry is positive for vimentin and, in some cases, for desmin, smooth muscle actin, and cytokeratin.⁴ CIF is characterized in up to 85% of cases by a specific t(12;15) (p13;q25) chromosomal translocation encoding an ETV6-NTRK3 gene fusion.^{1,3–5}

The diagnosis of CIF should always be considered in the presence of a congenital, spherical, bleeding extremity tumor in children, aiming to avoid treatment delays.

Financial support

None declared.

Authors' contributions

Luciana Baptista Pereira: Design and planning of the study; drafting and editing of the manuscript; collection, analysis, and interpretation of data; critical review of the manuscript; approval of the final version of the manuscript.

[☆] Study conducted at the Hospital das Clínicas, Universidade Federal de Minas Gerais, Belo Horizonte, MG, Brazil.

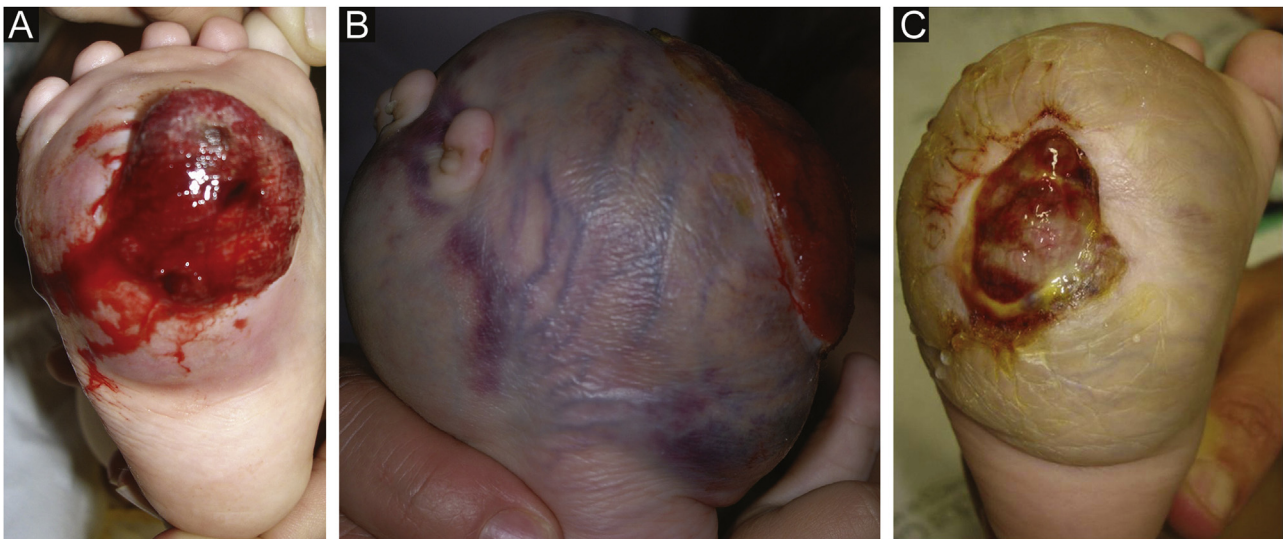


Figure 1 (A) Ulcerated and bleeding tumor mass. (B) After 13 weeks, significant increase in size (before the chemotherapy). (C) Tumor and ulcer reduction after adjuvant chemotherapy and before amputation.

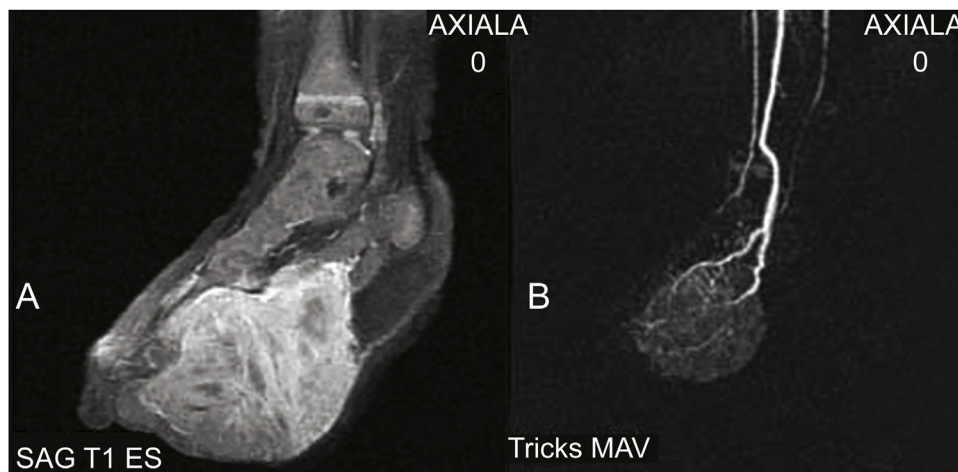

Figure 2 (A) MRI identifying an expansive mass with diffuse contrast enhancement. (B) MRA showing an expansive lesion supported by vascular structures. There is no evidence of arteriovenous fistulas or nidus.

João Renato Vianna Gontijo: Critical review of the manuscript; drafting and editing of the manuscript; approval of the final version of the manuscript.

Marcelo de Mattos Garcia: Critical review of the manuscript; drafting and editing of the manuscript; approval of the final version of the manuscript.

Karine Corrêa Fonseca: Critical review of the manuscript; drafting and editing of the manuscript; approval of the final version of the manuscript.

Conflicts of interest

None declared.

References

1. Nicholas RG, Brennan TE. Congenital infantile fibrosarcoma of the glabella: nuances of achieving surgical cure without cosmetic or functional deformity. *Int J Pediatr Otorhinolaryngol.* 2019;117:110–4.
2. Parida L, Fernandez-Pineda I, Uffman JK, Davidoff AM, Krasin MJ, Pappo A, et al. Clinical management of infantile fibrosarcoma: a retrospective single-institution review. *Pediatr Surg Int.* 2013;29:703–8.
3. Orbach D, Rey A, Cecchetto G, Oberlin O, Casanova M, Thebaud E, et al. Infantile fibrosarcoma: management based on the European experience. *J Clin Oncol.* 2010;28:318–23.
4. Farmakis SG, Herman TE, Siegel MJ. Congenital infantile fibrosarcoma. *J Perinatol.* 2014;34:329–30.

5. Tarik E, Lamiae R, Abdelouahed A, Tarik M, Hassan G, Anouar DM. Unusual case of congenital/infantile fibrosarcoma in a newborn. *Afr J Paediatr Surg.* 2013;10:185–7.

Luciana Baptista Pereira  a,b,*

^a *Dermatology Service, Hospital das Clínicas, Faculty of Medicine, Universidade Federal de Minas Gerais, Belo Horizonte, MG, Brazil*

^b *Department of Dermatology, Faculty of Medicine, Universidade Federal de Minas Gerais, Belo Horizonte, MG, Brazil*

João Renato Vianna Gontijo  a,b

^a *Dermatology Service, Hospital das Clínicas, Faculty of Medicine, Universidade Federal de Minas Gerais, Belo Horizonte, MG, Brazil*

^b *Dermatology Service, Hospital Mater Dei, Belo Horizonte, MG, Brazil*

Marcelo de Mattos Garcia  a,b

^a *Axial Medicina Diagnóstica, Belo Horizonte, MG, Brazil*

^b *Hospital UNIMED, Belo Horizonte, MG, Brazil*

Karine Corrêa Fonseca 

Hospital das Clínicas, Faculty of Medicine, Universidade Federal de Minas Gerais, Belo Horizonte, MG, Brazil

* Corresponding author.

E-mail: lucianabaptistapereira@gmail.com (L.B. Pereira).

Received 29 October 2020; accepted 26 December 2020

Available online 6 September 2022

<https://doi.org/10.1016/j.abd.2020.12.020>

0365-0596/ © 2022 Sociedade Brasileira de Dermatologia.

Published by Elsevier España, S.L.U. This is an open access article under the CC BY license

(<http://creativecommons.org/licenses/by/4.0/>).

Dermoscopic findings in a case of plasma cell cheilitis[☆]



Dear Editor,

Plasma Cell Cheilitis (PCC) is a rare inflammatory disorder of unknown origin within the spectrum of plasma cell mucositis. Clinically, it manifests as a circumscribed, flat to slightly raised, eroded erythematous plaque or patch involving the lower lip of elderly male patients.¹ Histopathologically, dense band-like plasma cell infiltration in the upper dermis is seen.² Dermoscopic features of this entity have been described in only one report.³ Here we report a case of refractory PCC and its dermoscopic features.

An otherwise healthy 52-year-old man, an agricultural worker, was referred to our hospital with a ten-year history of painful erythematous erosion on the lower lip. Physical examination revealed an erythematous plaque with diffuse desquamation along with erosions and crusts (Fig. 1A). Dermoscopy showed a well-defined lesion with the milky-red structureless area, small erosions, and multiple enlarged linear vessels on the periphery with a radial distribution. Scales although present on a small focus of the lesion was not a predominant feature (Fig. 2). Laboratory tests, including complete blood counts and tests for liver and renal function, showed normal findings, and hepatitis B and C and HIV infection was negative; PPD; chest X-Ray; thyroid

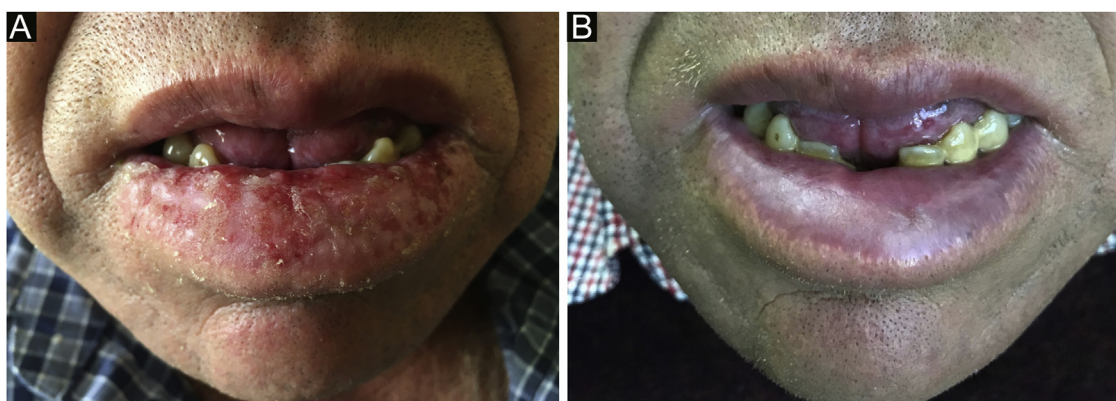

Figure 1 (A) The lower lip shows a diffuse xerotic erythematous plaque with erosions and hemorrhagic crusts. (B) Clinical improvement after 7-days of treatment with oral prednisone.

[☆] Study conducted at the Hospital Regional Libertador Bernardo O'Higgins, Rancagua, Chile.