



## Bladder and urethral duplication and a bladder exstrophy plate with omphalocele in a female child<sup>☆</sup>

Luiz G. Freitas Filho<sup>a,\*</sup>, Ana Carolina Carvalho Fonseca<sup>b</sup>, Taynara Roberta Guerreiro Paiva<sup>b</sup>,  
Bárbara Stephane de Medeiros Jerônimo<sup>b</sup>, Raphael Miranda Magalhães<sup>b</sup>,  
Maria Cristina Gomes Abreu<sup>c</sup>, Luiz J. Budib<sup>d</sup>

<sup>a</sup> Professor of Urology Universidade Federal de São Paulo, Visiting Professor, Hospital Santa Marcelina, Brazil

<sup>b</sup> Resident in Pediatric Surgery, Hospital Santa Marcelina, Brazil

<sup>c</sup> Department of Pediatric Surgery, Hospital Santa Marcelina, Brazil

<sup>d</sup> Department of Urology, Hospital Santa Marcelina, Brazil

### ARTICLE INFO

#### Keywords:

Bladder exstrophy  
Exstrophy variants  
Bladder duplication  
Urethra duplication

### ABSTRACT

The Exstrophy – Epispadias Complex (EEC) is a spectrum of rare congenital malformations involving the urinary, genital and musculoskeletal systems. We present an atypical or variant case of EEC in which a bladder plate is found involving a small omphalocele, separated pubic bones and bladder and urethral duplication. The treatment had a favorable outcome, with bladder control and the child voiding normally. Perhaps the best accepted embryonic theory to explain exstrophy and its variants should be reviewed as it fails to satisfactorily explain the alterations we found.

### Introduction

The Exstrophy – Epispadias Complex (EEC) is a spectrum of rare congenital malformations involving the urinary, genital and musculoskeletal systems. Exstrophy variants or “split symphysis variants” are even rarer, observed in approximately 1 in every 400.000 live newborns or in 1 in every 500.000 ones, most commonly found among girls as compared to boys, unlike what is perceived in regular exstrophy cases.<sup>1,2</sup> The etiology of EEC is quite unknown yet and different theories have been suggested to explain the abnormal development of the cloacal membrane.<sup>3</sup> We report on the case of a female child who was born with a bladder exstrophy variant and an omphalocele in the middle of the plate, besides a bladder and urethral duplication.

### Case report

A seven-day-old girl was referred to our department diagnosed with omphalocele and ambiguous genitalia. She was born after a normal pregnancy, Cesarean section, diabetic and hypertensive mother, in week

thirty-seven of pregnancy. Nothing abnormal appeared in the ultrasounds performed during pregnancy. After birth she underwent an abdominal ultrasonography that revealed nothing unusual, a transfontanelar ultrasound equally normal and an echocardiogram that detected an interatrial communication and an interventricular communication with no hemodynamic repercussions. When she was first examined an omphalocele involved by a bladder plate was found, apparently with no ureteral ostia. She had bifid clitoris and clearly female genitals (Fig. 1). An abdominal radiography showed that her pubic bones were separated, as usually occurs in cases of exstrophy-epispadias complex. On day eight she underwent posterior osteotomy of the iliac bones and a median laparotomy. Besides the bladder plate involving the omphalocele, two well characterized bladders were noticed, each one with its ureteral ostium and respective urethra (Fig. 2a). Both bladders were opened and united with Vycril 4-0 stitches (Fig. 2b). Two urethral catheters were left in place for 48 hours. The abdominal wall was sutured with Vycril 2-0 separated stitches and the pubic bones were quite easily approximated by three Vycril 1 stitches (Fig. 3). The child remained with her lower limbs immobilized for three weeks. She had an

<sup>☆</sup> We acknowledge Dr LJ Budib for his contribution to this manuscript.

\* Corresponding author. Rua Batista Cepelos 87 – ap 61, 04109, São Paulo, Brazil.

E-mail addresses: [luiz.freitas@unifesp.br](mailto:luiz.freitas@unifesp.br) (L.G. Freitas Filho), [carolfonseccarvalho@gmail.com](mailto:carolfonseccarvalho@gmail.com) (A.C. Carvalho Fonseca), [taynarapaiva@gmail.com](mailto:taynarapaiva@gmail.com) (T.R. Guerreiro Paiva), [babii.stephane@gmail.com](mailto:babii.stephane@gmail.com) (B. Stephane de Medeiros Jerônimo), [raphaelmmster@gmail.com](mailto:raphaelmmster@gmail.com) (R.M. Magalhães), [cristinaabreu@uol.com.br](mailto:cristinaabreu@uol.com.br) (M.C. Gomes Abreu).

<https://doi.org/10.1016/j.eucr.2021.101769>

Received 14 June 2021; Received in revised form 30 June 2021; Accepted 5 July 2021

Available online 6 July 2021

2214-4420/© 2021 Published by Elsevier Inc. This is an open access article under the CC BY-NC-ND license (<http://creativecommons.org/licenses/by-nc-nd/4.0/>).

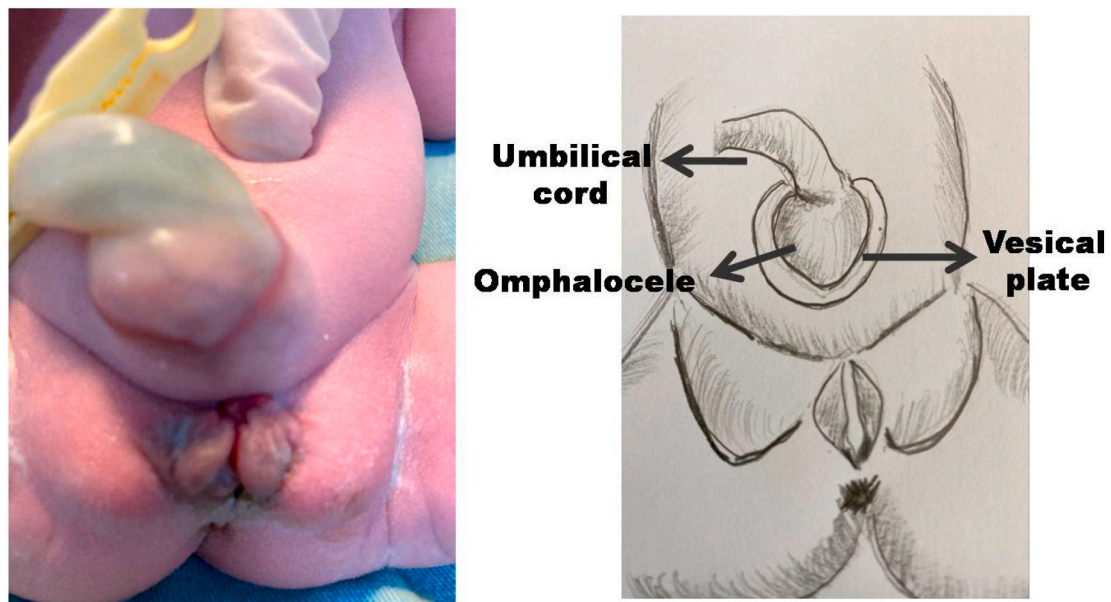


Fig. 1. Vesical plate and omphalocele on the day of birth.

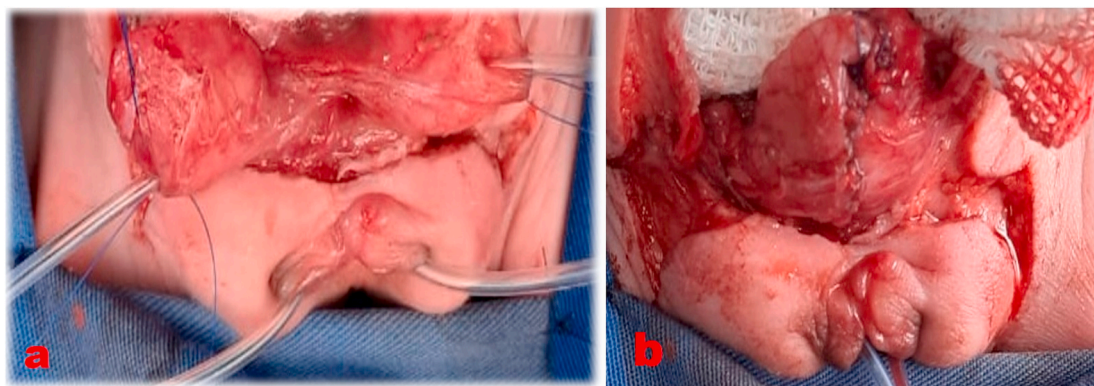


Fig. 2. a: Two bladders and two urethras with catheters inside. b The two bladder are unified.

uneventful postoperative and was released with no complication. She is currently six months old and voids normally.

#### Comment

According to Turner et al. exstrophy variants are found in 8% of all patients with exstrophy.<sup>4</sup> Such variants were classified into 5 sub-groups<sup>1,5</sup>:

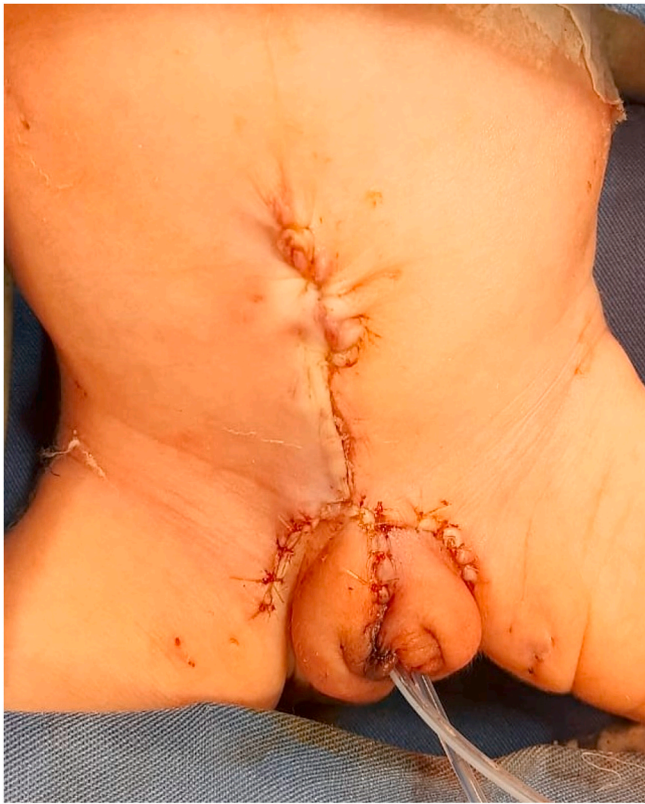1. Superior vesical fissure: A musculoskeletal defect is present, however with minimal bladder eventration and limited to the apex.
2. Pseudo-exstrophy: There are characteristic musculoskeletal defects with no major defect except for subcutaneous location of the bladder.
3. Duplicate exstrophy: Only a patch of the bladder exstrophy mucosa in the infraumbilical region is present but the urinary tract is intact.
4. Superior vesical fistula: A tiny communication between the bladder and the exterior is present in addition to the musculoskeletal defect.
5. Covered exstrophy: there is a visceral sequestration where, in addition to the musculoskeletal defect, an isolated bowel segment is present on the anterior abdominal wall close to the genital area.

In our case urethral and bladder duplication was found, with normal ureters and kidneys, besides the presence of a bladder exstrophy plate

with an omphalocele in the middle, i.e., a combination of duplicate exstrophy and pseudo-exstrophy (Fig. 1).

In the embryonic phase, a misleading fact in the development of an exstrophy and its variants is that at no stage in the human or animal embryonic development anything similar to an exstrophy occurs. So, most likely, exstrophy is not caused by a discontinuity in the development process. The most accepted theory for the development of an exstrophy and its variants was described by Marshall et Muecke who suggest an abnormal development of the cloacal membrane, in which there is no development of the mesenchyme between the ectoderm and the endoderm of the infraumbilical region, leading to a perforation that can be either early, leading to a cloacal exstrophy, or late, leading to an bladder exstrophy, or even later which in turn leads to the development of epispatias.<sup>5</sup>

Exstrophy variants have been suggested as being a manifestation of a circumscribed perforation of the cloacal membrane, predominantly in its cranial or more caudal position. Our patient, in addition to presenting an exstrophy plate with an omphalocele in the middle had bladder and urethral duplication, which may suggest that Marshall et Muecke's theory should be reconsidered for further evaluation.



**Fig. 3.** Final aspect.

### Conclusion

The bladder-exstrophy complex is a spectrum of challenging

congenital malformations ranging from classical or typical forms to variant or atypical ones. Perhaps the best accepted embryonic theory to explain all cases should be reviewed when considering variant or atypical forms.

### References

1. Gupta DK, Charles AR, Srinivas M. Exstrophy variants: should they be considered malformation complexes separate from classic exstrophy? *Eur J Pediatr Surg.* 2003;13: 377–382.
2. Valioulis I, Levard G, Lottmann H, Hameury F, Cendron J – a rare complex bladder exstrophy variant. *BJU Int.* 2000;86:398–400.
3. Mollard P, Mouriquand P, Joubert P. *L'exstrophie vésicale et ses variants.* second ed. Paris, France: Editions Techniques; 1988:1–14. Encyclopédie Médico-Chirurgicale.
4. Turner Jr WR, Ranasley PG, Bloom DA, Williams DI. Variants of the exstrophic complex. *Urol Clin.* 1980;7:493–501.
5. Marshall VF, Mueck EC. Variations in exstrophy of the bladder. *J Urol.* 1962;88: 766–796.