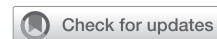

Right atrium blood cyst: Minimally invasive surgical approach



Nestor Manuel Clusa, MD,^a Guillermo Gutierrez, MD,^a Santiago Florit, MD,^b Sergio Baratta, MD,^c and Guillermo Vaccarino, MD,^a Buenos Aires, Argentina

From the ^aCardiovascular Surgery Department, and ^cCardiology Department, Hospital Universitario Austral, Buenos Aires, Argentina; and ^bDepartment of Cardiovascular Surgery, Sanatorio Las Lomas, Buenos Aires, Argentina.

Disclosures: The authors reported no conflicts of interest.

The *Journal* policy requires editors and reviewers to disclose conflicts of interest and to decline handling or reviewing manuscripts for which they may have a conflict of interest. The editors and reviewers of this article have no conflicts of interest.

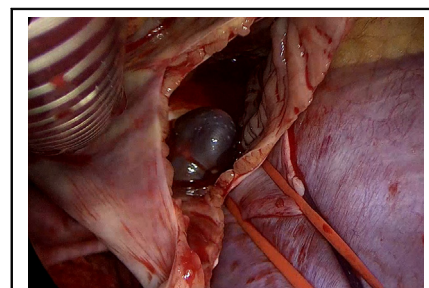
Received for publication Sept 27, 2022; accepted for publication Sept 27, 2022; available ahead of print Sept 30, 2022.

Address for reprints: Nestor Manuel Clusa, MD, Av. Libertador 7548 8F, Ciudad Autonoma de Buenos Aires, Buenos Aires, Argentina (E-mail: nestormanuelclusa@gmail.com).

JTCVS Techniques 2022;16:128-31
2666-2507

Copyright © 2022 The Author(s). Published by Elsevier Inc. on behalf of The American Association for Thoracic Surgery. This is an open access article under the CC BY-NC-ND license (<http://creativecommons.org/licenses/by-nc-nd/4.0/>).

<https://doi.org/10.1016/j.jtc.2022.09.015>



Right atrium blood cyst: minimally invasive surgical approach.

CENTRAL MESSAGE

We report on the surgical resolution of a blood cyst in the right atrium with a minimally invasive approach through a mini video-assisted right anterolateral thoracotomy.

▶ Video clip is available online.

Blood cardiac cyst is rare entity usually found within the first 6 months of life, usually located in the atrioventricular valves, more frequently on the left side.¹ The diagnosis in adult patients and on the right side of the heart is infrequent. These cysts are aberrant embryologic remnants of the Chiari network that lead to the formation of a diverticulum adhered to the interatrial septum at the level of the inlet of the sinus venosus and the inferior vena cava. They are generally asymptomatic in adults but can cause valvular valve dysfunction, embolic stroke, and pulmonary embolism.²

CASE PRESENTATION

We present the case of a 48-year-old male patient with no medical history or cardiovascular risk factors who was under study for nonspecific chest pain. As part of the complementary studies, an echocardiogram was requested, which showed preserved ventricular function without valvular heart disease and a nonspecific thickening of the interatrial septum (Figure 1, A). The study was complemented with a multislice computed tomography angiography, which confirmed no evidence of coronary disease but revealed a round, solid, heterogeneous formation of 16 × 15 × 20 mm, with soft-tissue density with calcifications inside, that contacted the interatrial septum, the ostium

of the sinus venosus, and the medial wall of the inferior vena cava (Figure 1, B). The study was extended with a cardiac magnetic resonance imaging, which showed, between the inlet of the inferior vena cava and the coronary sinus, a rounded 13 × 12-mm mass with clear edges, no pedicle, and nonmobile, hyperintense in T2, heterogeneous in T1. It was not canceled in sequence with fat saturation, hypointense in early enhancement sequence, and hypointense in late enhancement sequence (Figure 1, C). With the diagnosis of right atrial mass, surgical resolution was decided through a minimally invasive approach through a mini video-assisted right anterolateral thoracotomy with femoral venous and arterial cannulation (Figure 1, D).

The tumor was approached through a right atriotomy, where we encountered a violaceous cystic mass adhered to the sinus venosus (Figure 2, A). During the resection, the wall of the cyst was opened, revealing its blood content and 3 calcified structures inside it with the appearance of phleboliths (Figure 2, B, and Video 1). Extracorporeal circulation and clamping times were 64 and 27 minutes, respectively. The patient had an uneventful postoperative course and was discharged from the hospital on the sixth postoperative day. He returned to his regular activities at

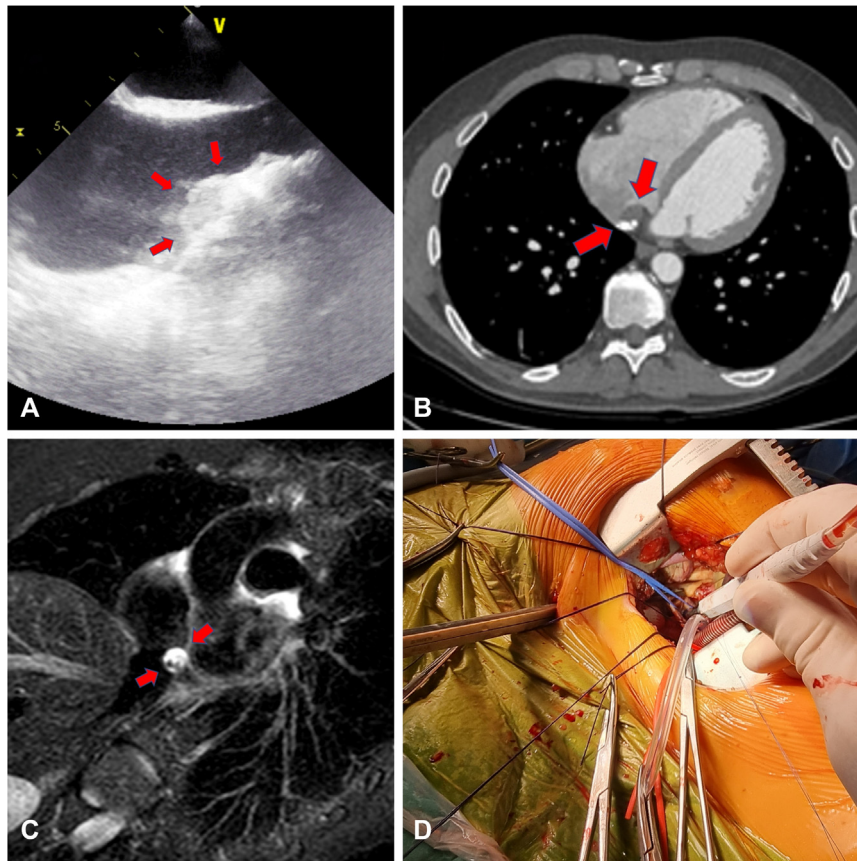


FIGURE 1. A, Echocardiographic image of nonspecific thickening of the interatrial septum. B, Cystic lesion with calcium densities inside adhered to the interatrial septum by computed tomography. C, Nuclear magnetic resonance image in T2 STIR (short inversion time inversion recovery) sequence. D, Minimally invasive approach by right anterolateral mini-thoracotomy.

14 days after discharge, with a cosmetic and functional result superior to conventional sternotomy (Figure 2, C).

The pathologic study of the extracted piece describes a cystic-like formation with thickened walls made up of collagen tissue and surrounded by CD31+ endothelial cells. In its interior, hematic fibrin material and calcium deposits were observed. Findings were compatible with the diagnosis of hematic cyst (Figure 2, D).

DISCUSSION

Cardiac blood cysts are a rare entity usually seen in infants, and their most frequent location is along the closure lines of the atrioventricular valves in 96% of the cases, less frequently in the aortic and pulmonary valves. These cysts can disappear spontaneously during childhood, so it is uncommon to find them in adult patients.³

The origin of these heart cysts has not yet been elucidated, and several hypotheses have been proposed. Kantelip and colleagues postulated that blood cysts arise from heteroplastic changes in tissues originating from the primitive pericardial mesothelium, which is involved in the formation of the fibrous skeleton of the heart.⁴ Boyd suggests that

cysts form during valve development from blood that has been retained in crevices that later coalesce into a cystic structure.⁵ Hematic cysts usually contain calcified structures with the appearance of phleboliths.^{5,6}

Diagnosis is usually through a finding in a routine study, and they are usually asymptomatic but may cause symptoms due to valvular valve dysfunction, embolic stroke, and pulmonary embolism. The minimally invasive approach by minithoracotomy offers an alternative to the conventional approach by sternotomy, avoiding all the complications related to it. Analogous to mitral surgery approaches, minimally invasive surgery reduces the rate of postoperative bleeding, the need for blood transfusions, and reduces the number of days of hospitalization both in the critical care unit and in total days of hospitalization.⁷

Luo and colleagues⁸ published their series of 50 patients with cardiac masses comparing conventional sternotomy versus minimally invasive approach through a right mini-thoracotomy and found no significant differences between the 2 groups in terms of cardiopulmonary bypass time, aortic crossclamp time, postoperative intubation time, intensive care unit days, and length of the hospital stay.

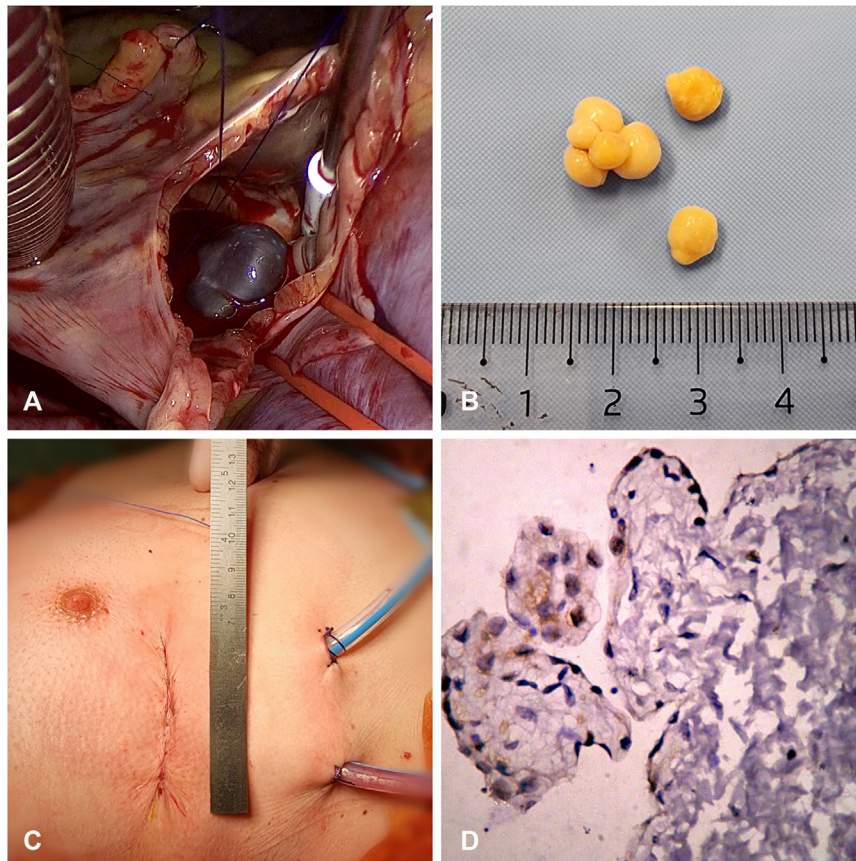


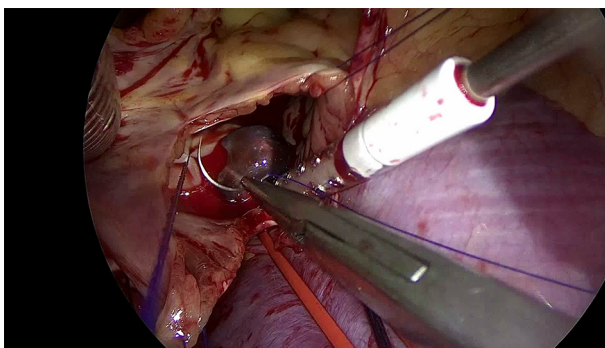
FIGURE 2. A, Intraoperative finding: purple cyst between the inferior vena cava and the sinus venosus. B, Phlebolith-like formations found inside the cyst. C, Scar from the minimally invasive approach by anterolateral minithoracotomy D, Microscopic analysis.

Patients with right anterolateral minithoracotomy had less postoperative chest drainage (536 ± 159 vs 773 ± 255 mL, $P < .01$) and transfusion rate (5.9% vs 33.3%, $P = .033$) than those who had sternotomy.

Russo and colleagues⁹ also compared both approaches for cardiac masses in 34 consecutive patients and concluded

in their experience that minimally invasive atrial mass excisions can be accomplished reliably without compromising complete tumor resection and without significant increases in operative times or serious adverse events.

This article was reviewed and approved by Hospital Austral Scientific Board (Approval date: March 1, 2022). The patient provided written informed consent for the publication of the study data.



VIDEO 1. Video shows minimally invasive surgical resection of right atrium blood cyst. Video available at: [https://www.jtcvs.org/article/S2666-2507\(22\)00517-X/fulltext](https://www.jtcvs.org/article/S2666-2507(22)00517-X/fulltext).

References

1. Imai A, Enomoto Y, Shigeta O, Suzuki Y. Right atrial blood cyst in elderly patient: the timing of surgery. *Asian Cardiovasc Thorac Ann.* 2020;28:500-3. <https://doi.org/10.1177/0218492320949406>
2. Sabzi F, Heydari A, Asadmobini A, Heidari MB. Right atrial blood cyst with stones suspended from the coronary sinus. *Sultan Qaboos Univ Med J.* 2019;19:e161-3. <https://doi.org/10.18295/squmj.2019.19.02.014>
3. Elsässer C. Bericht über die Ereignisse in der Gebärenstalt des Catherinen. *Hospitals im Jahre 1844. Med Correspondenzblatt.* 1844;14:297.
4. Kantelip B, Satge D, Camilleri L, Chenard MP, De Riberolles C. Valvular cyst and atrioventricular canal in a child with trisomy. *Proc (Bayl Univ Med Cent).* 1994; <https://doi.org/10.1080/08998280.2015.11929275>
5. Boyd WC, Hartman GS, Reilly DM, Kreiger KH. An adult atrial blood cyst. *J Cardiothorac Vasc Anesth.* 1999; [https://doi.org/10.1016/s1053-0770\(99\)90014-9](https://doi.org/10.1016/s1053-0770(99)90014-9)

6. Otsuka K, Terasaki F, Iimori A, Tonari S, Shimomura H, Ito T, et al. Right atrial blood cyst with total occlusion of the right coronary artery. *Heart Vessels*. 2007;22:208-10. <https://doi.org/10.1007/s00380-006-0972-7>
7. Sündermann SH, Sromicki J, Rodriguez Cetina Bieffer H, Seifert B, Holubec T, Falk V, et al. Mitral valve surgery: right lateral minithoracotomy or sternotomy? A systematic review and meta-analysis. *J Thorac Cardiovasc Surg*. 2014;148:1989-95.e4. <https://doi.org/10.1016/j.jtcvs.2014.01.046>
8. Luo C, Zhu J, Bao C, Ding F, Mei J. Minimally invasive and conventional surgical treatment of primary benign cardiac tumors. *J Cardiothorac Surg*. 2019;14:76. <https://doi.org/10.1186/s13019-019-0890-2>
9. Russo MJ, Martens TP, Hong KN, Colman DL, Voleti VB, Smith CR Jr, et al. Minimally invasive versus standard approach for excision of atrial masses. *Heart Surg Forum*. 2007;10:E50-4. <https://doi.org/10.1532/HSF98.20061132>