



Case report

Orthopnea and pulmonary hypertension. Treat the underlying disease

M. Meysman^{a,*}, S. Droogmans^b^a Respiratory Division, Universitair Ziekenhuis Brussel, University Hospital VUB, Brussels, Belgium^b Department of Medicine, Centrum Hart- en Vaataziekten (CHVZ), Universitair Ziekenhuis Brussel, University Hospital VUB, Brussels, Belgium

ARTICLE INFO

Keywords:

Diaphragm dysfunction
Right heart failure

ABSTRACT

We report the case of a patient with longstanding dyspnea upon reclining, who presented with severe right heart failure due to chronic alveolar hypoventilation. Bilateral diaphragmatic paresis was discovered. She recovered from her right ventricular failure with non-invasive mechanical ventilatory support.

1. Introduction

The diaphragm is the principle muscle of respiration. Bilateral dysfunction of this important muscle can, among other symptoms, lead to sleep-disordered breathing and alveolar hypoventilation, since the accessory inspiratory muscles, who compensate for this dysfunction, are suppressed during rapid-eye-movement sleep [1]. Long standing serious sleep-disordered breathing is associated with cardiovascular disease and even pulmonary hypertension and right heart failure [2]. Awareness of this treatable cause of pulmonary hypertension is necessary as is demonstrated by this case.

2. Case history

A 56 year old female with a body mass index of 28 was referred by her cardiologist for additional work-up of severe dyspnea (New York Heart Association Class IV) and pulmonary hypertension.

She complained of dyspnea and orthopnea for more than 20 years. She slept in a recliner. In the past she consulted different specialists (neurologists, psychologists, pulmonologists) and was considered overweight and with a burn-out syndrome and prescribed antidepressants.

When she presented to the cardiologist, she had edema of the legs up to the groin, and was not able to lay down on the examination table due to breathlessness. Blood pressure 130/80 mmHg, pulse regular 72/min. sPO₂ 90% breathing room air standing, declining till 88% in recumbence with paradoxically inward abdominal movement during inspiration. Turgescient jugular veins and bilateral crackles over the lung bases.

An electrocardiogram (see Fig. 1) showed sinus rhythm with bi-atrial enlargement and right axis deviation.

Echocardiography performed in sit confirmed severe pulmonary

hypertension, with a systolic pulmonary artery pressure estimated at 80 mmHg and normal left ventricular function.

Right heart catheterization was performed, confirming severe pre-capillary pulmonary hypertension with a right atrial pressure of 17 mmHg, a mean pulmonary artery pressure of 65 mmHg, a pulmonary artery wedge pressure of 10 mmHg and a cardiac output of 5.4L/min. The pulmonary vascular resistance was calculated at 10.2 Wood units. Central venous oxygen saturation was 66%.

Chest X-ray showed vascular congestion, with a left hemi diaphragm at the same height of the right hemi diaphragm (Fig. 2). Pulmonary embolism was ruled out on chest angio-CT. She was put on diuretics and further work-up was scheduled.

Arterial bloodgas analysis, breathing room air, confirmed respiratory insufficiency type II with hypoxemia and hypercapnia (pH 7.37, P_aO₂ 63 mmHg (8.38 kPa), P_aCO₂ 57 mmHg (7.58 kPa), Oxygen saturation 90%), but with a normal A-a gradient of 15.5 mmHg (2.1kPa).

The biomarker NT-proBNP was markedly elevated 1730 ng/L (normal < 125), a six-minute walking test could not be performed by the patient.

A fluoroscopy of the diaphragm with 'sniff' test (assessing the motion of the diaphragm during a short, sharp inspiratory effort through the nostrils) showed the use of accessory respiratory muscles, with bilateral diminished diaphragmatic excursion (video 1).

Supplementary video related to this article can be found at <http://dx.doi.org/10.1016/j.rmcr.2018.05.004>.

Pulmonary function test showed extra pulmonary restrictive lung disease with a total lung capacity of 55% predicted value in sit. Measurements in supine posture could not be performed. Maximal inspiratory mouth pressures showed markedly reduced inspiratory muscle power with a value of 44 cm H₂O. Maximal static expiratory pressure was preserved.

* Corresponding author. Respiratory Division, Universitair Ziekenhuis Brussel, Laarbeeklaan 101, 1090 Brussels, Belgium.
E-mail address: marc.meysman@uzbrussel.be (M. Meysman).

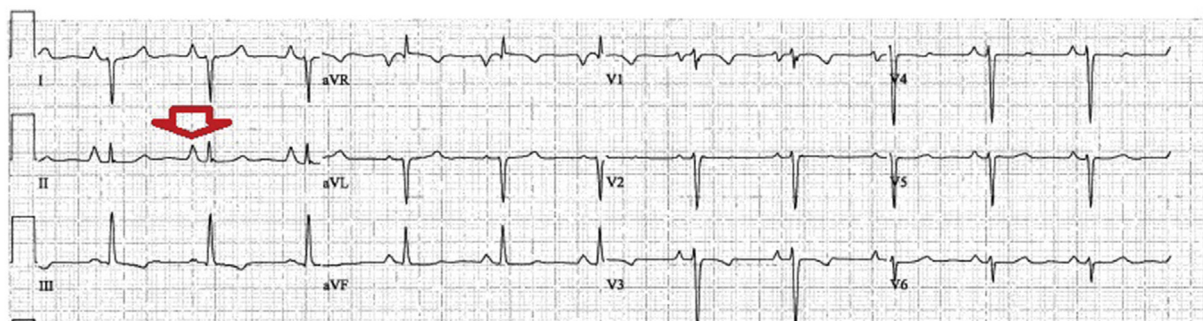


Fig. 1. ECG of the patient showing bi-atrial enlargement (arrow) and a right axis deviation.

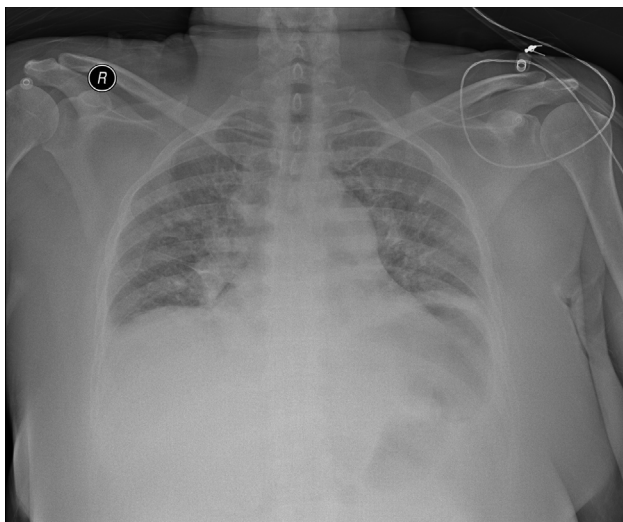


Fig. 2. Anteroposterior Chest X-ray with elevated left hemidiaphragm and turgescient vascular hili.

Autoimmune pathology, Lyme disease and cervical spinal pathology was ruled out. A polysomnography showed no sleep-disordered breathing other than alveolar hypoventilation.

Electromyography of the phrenic nerves confirmed little motoric response on stimulation.

Intermittent (night time and when recumbent) non-invasive bi-level mechanical ventilatory support (NIV), was started with almost immediate normalization of the arterial blood gas values and improvement of her daytime somnolence. After one month of treatment she was able to restart her professional activities as a teacher. Four years after the start of her NIV treatment right heart function has completely normalized. A final diagnosis of idiopathic bilateral diaphragm dysfunction with secondary right heart failure was made.

3. Discussion

Diaphragmatic dysfunction is an unusual cause of orthopnea and right heart failure.

The causes of diaphragmatic dysfunction must be classified according to the level of impairment. Cerebral causes (multiple sclerosis, stroke, Arnold-chiari malformation), disorders at the level of the cervical spine (quadriplegia, amyotrophic lateral sclerosis, poliomyositis, spinal muscular atrophy, syringomyelia), phrenic nerve pathology (Guillain-Barré syndrome, tumor compression, neuralgic myopathy, critical-illness polyneuropathy, chronic inflammatory demyelinating polyneuropathy, Charcot-Marie-Tooth disease, idiopathic), pulmonary disease with marked hyperinflation (COPD, asthma), disordered synaptic transmission at the neuromuscular junction of the diaphragm (myasthenia gravis, Lambert-Eaton syndrome, botulism,

organophosphate intoxication, drugs), various inherited and acquired myopathies (muscular dystrophies, myositis, acid maltase deficiency, glucocorticoid induced, disuse atrophy) [3]. According to the clinical presentation, work-up at those different levels must be done.

Dyspnea and orthopnea, in the presence of thoraco-abdominal paradoxical breathing in supine posture are important clinical signs leading to the suspicion of bilateral diaphragmatic dysfunction [3].

The function of the phrenic nerve responsible for the control of the ipsilateral diaphragm can best be evaluated with nerve conduction analysis by means of bipolar stimulating electrodes usually placed in the supraclavicular fossa, just above the ipsilateral clavicle, recording electrodes of which one is placed 5 cm above the xiphoid process and the second one 16 cm from the first one on the chest margin ipsilateral to the stimulated phrenic nerve [4], and an electromyography (EMG) system. The latter must also be used to evaluate diaphragm function. In case of a conduction problem in the phrenic nerve, denervation activity or severe reduction of the motor unit potential morphology can be seen, as was the case in our patient [5]. Ultrasonography is more and more used for diagnosing both unilateral and bilateral diaphragmatic dysfunction. Dynamic MRI of the diaphragm might become even more valuable [6].

Imaging such as CT or MRI of the cervical spine and chest CT is used to rule out pathologies along the trajectory of the phrenic nerve from its origin at C3-C5 up to the neuro-muscular junction of the diaphragm. In bilateral diaphragmatic paralysis, bilateral, smooth elevation of the hemidiaphragms and small lung volumes are usually seen on plain chest X-ray, and the costophrenic and costovertebral sulci are deep and narrow. The lateral view confirms a smooth contour and elevated diaphragmatic position. Plate-like atelectasis may also be present, usually at the lung base [7]. Although fluoroscopy and sniff test are useful for unilateral diaphragm dysfunction, its value in bilateral disease is very limited. Paradoxical movement of the chest due to accessory muscle activity must not be misinterpreted as diaphragmatic activity (see our patient) [8].

Transdiaphragmatic pressure recording, during maximal voluntary inspiration with the use of an esophageal balloon is considered the golden standard to diagnose bilateral diaphragm paralysis, but usually regarded as to invasive [3].

Pulmonary function tests help in the evaluation of the diaphragmatic weakness and manifest as an extrinsic restrictive pulmonary disorder (low total lung capacity with normal diffusion capacity of carbon monoxide corrected for alveolar volume (DLCO/VA). Restriction usually can worsen in the supine posture. Forced vital capacity (FVC), decreasing more than 20% in recumbency, is suggestive of diaphragmatic weakness. Reductions in maximal inspiratory pressure (MIP) do confirm the muscle weakness. Pulmonary function tests can also be used in the follow-up of the disease [9].

In our patient no identifiable causes for diaphragmatic dysfunction could be found.

Idiopathic phrenic neuropathy is an entity with unknown epidemiology and unknown etiology, often leading to delayed diagnosis as

the dyspnea and orthopnea are attributed to other causes. No well controlled trials of treatment for idiopathic phrenic neuropathy have been published. Although spontaneous improvement can occur, most bilateral phrenic neuropathies do not recover. Although an immune mechanism is suspected no antibody involved has been isolated so far. So results of sporadic patients treated with immunosuppressive agents, antiviral agents or intravenous immunoglobulins must be interpreted with caution [10]. Phrenic nerve pacing is no option as it requires intact phrenic nerve function [11].

In our patient the longstanding alveolar hypoventilation induced the pulmonary hypertension.

The mechanisms responsible for the development of pulmonary hypertension in alveolar hypoventilation syndromes have not been fully elucidated, but the reversibility of the pulmonary hypertension by treatment with NIV suggest a major pathologic role for hypoxic and hypercapnic vasoconstriction [12]. As with other hypoventilation syndromes, accompanied by pulmonary hypertension, such as obesity hypoventilation and Ondine's curse, and as endorsed by the leading experts in the field, treatment of the underlying disease is the goal, as this pulmonary hypertension is refractory to drugs targeting the pulmonary circulation [2,12]. In the case of hypoventilation syndrome this is ventilatory support.

Financial/non-financial disclosures

No significant conflicts of interest exist with any companies/organizations whose products or services may be discussed in this paper.

References

- [1] J. Steier, C.J. Jolley, J. Seymour, et al., Sleep-disordered breathing in unilateral diaphragm paralysis or severe weakness, *Eur. Respir. J.* 32 (6) (2008) 1479–1487.
- [2] N. Galiè, M. Humbert, J.L. Vachiery, et al., 2015 ESC/ERS guidelines for the diagnosis and treatment of pulmonary hypertension: the joint task force for the diagnosis and treatment of pulmonary hypertension of the European Society of Cardiology (ESC) and the European Respiratory Society (ERS): endorsed by: association for European Paediatric and Congenital Cardiology (AEPC), International Society for heart and lung transplantation (ISHLT), *Eur. Heart J.* 37 (1) (2016) 67–119.
- [3] F.D. McCool, G.E. Tzelepis, Dysfunction of the diaphragm, *N. Engl. J. Med.* 366 (10) (2012) 932–942.
- [4] R. Chen, S. Collins, H. Remtulla, et al., Phrenic nerve conduction study in normal subjects, *Muscle Nerve* 18 (1995) 330–335.
- [5] S. Podnar, Idiopathic phrenic neuropathies: a case series and review of the literature, *Muscle Nerve* 52 (2015) 986–992.
- [6] K. Nadir, Dysfunction of the diaphragm: imaging as a diagnostic tool, *Curr. Opin. Pulm. Med.* 19 (2013) 394–398.
- [7] G.J. Gibson, Diaphragmatic paresis: pathophysiology, clinical features, and investigation, *Thorax* 44 (1989) 960–970.
- [8] J. Davis, Diaphragm function and alveolar hypoventilation, *Q. J. Med.* 45 (1976) 87–100.
- [9] G. Gayan-Ramirez, N. Gosselin, T. Troosters, et al., Functional recovery of diaphragm paralysis: a long-term follow-up study, *Respir. Med.* 102 (2008) 690–698.
- [10] S. Podnar, Nosology of idiopathic phrenic neuropathies, *J. Neurol.* 262 (3) (2015) 558–562.
- [11] J. Gonzalez-Bermejo, C. LLontop, et al., Respiratory neuromodulation in patients with neurological pathologies: for whom and how? *Ann Phys Rehabil Med* 58 (2015) 238–244.
- [12] R. Naeije, Pulmonary hypertension in hypoventilation syndromes, *Eur. Respir. J.* 43 (1) (2014) 12–15.