



Case report

Pneumatic retinopexy for displaced macular laceration from intraocular foreign body



Patrick A. Coady*, Nauman Chaudhry, Ron A. Adelman

Department of Ophthalmology and Visual Science, Yale University School of Medicine, New Haven, CT, USA

ARTICLE INFO

Article history:

Received 13 April 2016

Received in revised form

27 June 2016

Accepted 14 July 2016

Available online 18 July 2016

Keywords:

Intraocular foreign body

Penetrating ocular injury

Macular injury

Pneumatic retinopexy

ABSTRACT

Purpose: To report a case of macular laceration from intraocular foreign body (IOFB) treated with pneumatic retinopexy.

Observations: A 74 year old man sustained penetrating injury to his left globe with retained metallic intraocular foreign body (IOFB). The patient underwent prompt pars plana vitrectomy, intravitreal antibiotics and removal of IOFB. The posterior point of impact left a displaced foveo-macular laceration which was recognized postoperatively and treated with pneumatic retinopexy for re-approximation of the foveal tissue. Optical coherence tomography confirmed acute traumatic laceration and edema, closure of the tissue and subsequent healing and adjacent retinal and retinal pigment epithelial atrophy. He regained visual acuity of 20/30.

Conclusions and importance: Traumatic macular lacerations can be treated with pneumatic retinopexy, after pars plana vitrectomy, with potentially good visual result.

© 2016 The Authors. Published by Elsevier Inc. This is an open access article under the CC BY-NC-ND license (<http://creativecommons.org/licenses/by-nc-nd/4.0/>).

Introduction

Penetrating ocular injuries represent a potentially devastating threat to vision that require prompt surgical intervention. Retained intraocular foreign body (IOFB) injuries are an important subset of these injuries, with the majority ending up in the vitreous cavity or retina/choroid.^{1,2} In spite of the complexity and severity of these injuries, improved surgical techniques have improved the number of eyes salvaged and have resulted in 60–71% of these patients' eyes achieving greater than 20/40 visual acuity.^{1,2} In eyes with final visual acuity worse than 20/40 visual acuity, macular injury resulting in scarring represents a significant cause.²

Case report

A 74 year old man presented to the emergency department several hours after experiencing immediate pain and central blurry vision in his left eye while hammering a metal screwdriver. His initial visual acuity was 20/400 with eccentric fixation in the left eye. His right eye had a history of 20/200 vision after blunt trauma

approximately 60 years prior. On exam, he had a nasal subconjunctival hemorrhage and 2.0 mm scleral laceration, approximately 0.5 mm from the limbus at the 8 o'clock meridian with no uveal prolapse. He had a mild nuclear sclerosis cataract with no focal opacity. A linear area of retinal hemorrhage and whitening was noted slightly temporally to the fovea, presumed to be point of impact, but obscured by vitreous hemorrhage. A flat metallic IOFB was seen in the temporal anterior peripheral vitreous at the 3 o'clock meridian and confirmed on CT scan (Fig. 1).

The patient was brought to the operating room within 12 hours of initial injury for repair of scleral laceration, pars plana vitrectomy, intravitreal antibiotics and removal of IOFB. A 2.5 by 2.0 mm metal foreign body was recovered approximately 3.0 mm from the temporal limbus through a scleral incision directly over the foreign body, using forceps. A posterior vitreous detachment was pre-existing. A linear macular laceration with surrounding hemorrhage and whitening was also seen, but the view was limited and not recognized to be displaced.

On day two, the patient had count fingers vision at six feet vision, mild vitreous hemorrhage and displaced macular laceration with retinal edema and no vitreo-macular adhesions (Fig. 2 A,B). On day 6, his exam was unchanged and he underwent pneumatic retinopexy with 0.6 ml of 100% sulfur hexafluoride gas. He positioned face down for four days. The optical coherence tomogram (OCT) showed re-opposed macular laceration (Fig. 2 C,D). On day

* Corresponding author. Yale Eye Center, 40 Temple Street, 3rd floor, New Haven, CT 06510, USA.

E-mail address: Patrick.coady@yale.edu (P.A. Coady).

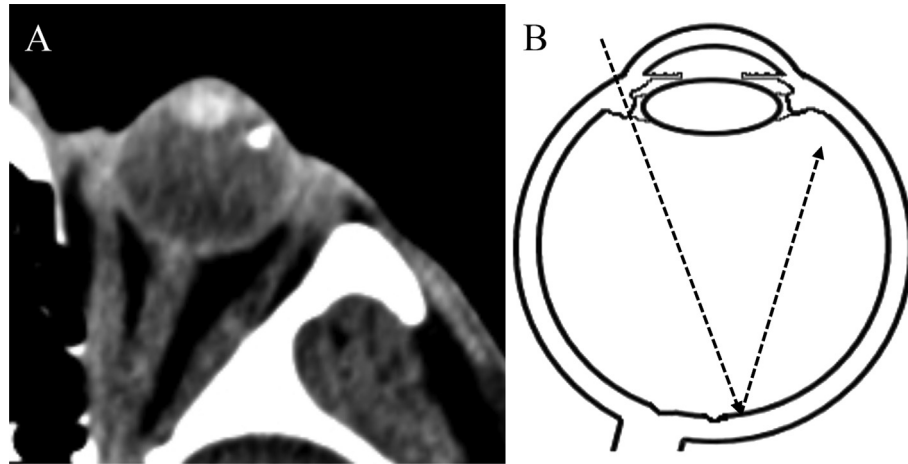


Fig. 1. A. Axial computed tomography (CT) scan of left eye shows metal foreign body in the antero-lateral vitreous cavity. B. Schematic trajectory (axial CT orientation) of metal foreign body entering left eye shows entry wound nasally, impact just temporal to the fovea and resting in the temporal vitreous cavity.

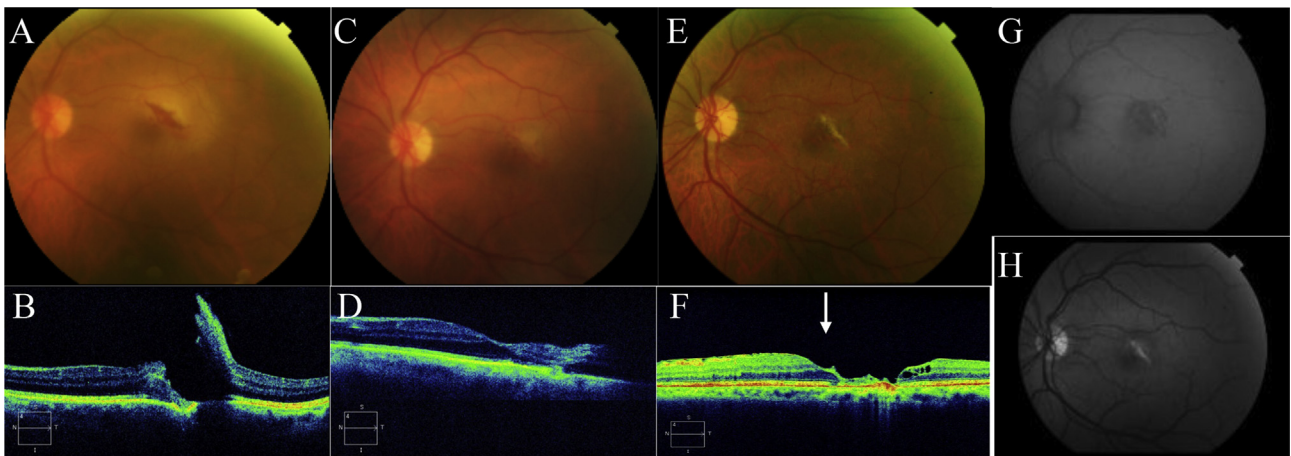


Fig. 2. A. Day two - fundus photo of the left eye shows macular laceration, retinal hemorrhages and surrounding edema. B. Day two - spectral domain optical coherence tomogram (SDOCT) horizontal line scan adjacent to the fovea shows full thickness laceration, hyper-reflectivity and displacement of the retina as well as injury into retinal pigment epithelium (RPE) and bruch's membrane. No vitreo-macular adhesions or traction were noted. C. Day nine (three days after pneumatic retinopexy) - fundus photo of the left eye shows closed laceration, improving edema and retinal hemorrhage. D. Day nine - SDOCT horizontal line scan shows re-apposed retina with full-thickness hyper-reflectivity of temporal retina. E. Day 72 - fundus photo of the left eye shows linear scar, resolved edema and hemorrhage and epiretinal membrane. F. Day 72 - SDOCT horizontal line scan shows atrophy of previously displaced and hyper-reflective retinal tissue, adjacent cystic spaces, preservation of ellipsoid zone in the umbo (white arrow) with adjacent atrophy and epiretinal membrane. G. Day 72 - Fundus autofluorescence of the left eye shows RPE loss and stippled appearance at impact site. H. Day 72 - Red-free image highlights area of scarring and impact. (For interpretation of the references to colour in this figure legend, the reader is referred to the web version of this article.)

72, his visual acuity returned to 20/30 with preserved ellipsoid zone in the umbo, mild epiretinal membrane and adjacent atrophy (Fig. 2 E,F,G,H).

Discussion

The patient in this case had a penetrating injury with retained IOFB. He underwent pars plana vitrectomy, intravitreal antibiotics and removal of IOFB and fortunately avoided retinal detachment or endophthalmitis. However, the projectile's point of impact left a full thickness, displaced retinal laceration near the fovea with Bruch's membrane and retinal pigment epithelium involvement apparent on OCT. Five days after initial IOFB removal, he underwent intravitreal gas injection to re-oppose the macular laceration. To our knowledge, we are unaware of a similar case reported in the literature.

In a recent series of patients with IOFB, macular scar was the second most common cause of visual acuity below 20/40 (29% of

cases) after retinal detachment.² The pneumatic retinopexy in this case was an attempt to minimize this damage in a patient with pre-existing poor vision in the contralateral eye. It is difficult to prove that this intervention improved this patient's visual outcome compared to no intervention, as this is a single case.

In addition, even though a macular point of impact was noted prior to surgery, a fluid-air exchange was not performed at the time of pars plana vitrectomy and IOFB removal. This was not performed as a displaced laceration was not recognized due to poor visualization and therefore not felt to be necessary at the time. It is possible that intravitreal gas with positioning at the time of original IOFB removal would have resulted in an even better anatomical outcome. However, if a displaced macular laceration is unrecognized and fluid air exchange is not performed at the time of vitrectomy, it is possible to treat these patients with macular tamponade in the early post-operative period (first with pars plana vitrectomy and IOFB removal and then subsequent pneumatic retinopexy if needed). Despite the treatment, this patient's OCT still

showed significant atrophy of the original avulsed and hyper-reflective retinal tissue.

Posterior IOFB injuries can also result in the foreign body resting in an intraretinal location. Even though this patient's IOFB location rested in the vitreous cavity, it passed through an intraretinal location on its trajectory and therefore exhibited some characteristics of an intraretinal IOFB injury. This patient developed epiretinal membrane, which is reported in 60% of intraretinal IOFBs in one series.³

Despite the macular point of impact, this patient's injury had several characteristics that have been previously correlated with favorable visual outcome.^{1,2} For example, this IOFB was relatively small, from a sharp metal (rather than blunt), and not associated with uveal prolapse, loss of lens material or retinal detachment.^{1,2} Macular point of impact was recognized before vitrectomy for IOFB removal and although the piece of metal was not seen to fall posteriorly during the time of surgery, injury at the time of surgery cannot be ruled out as a possibility.

Conclusion

We recommend placement of intraocular air or gas at the end of IOFB removal (fluid-air exchange at the time of pars plana vitrectomy) if macular impact is suspected. However, if this is not initially recognized or unable to be performed at the time of initial IOFB

removal, our case suggest that a subsequent pneumatic retinopexy in the early post-operative period can be considered.

Consent to publish

Informed consent was obtained in writing from the patient for publication of personal information including medical record details and photographs.

Acknowledgements

This manuscript is partially supported by Leir Foundation, Newman's Own Foundation and Research to Prevent Blindness. Special thanks to Robert Yerrington and Gregory McNamara.

References

1. Williams DF, Mieler WF, Abrams GW, Lewis H. Results and prognostic factors in penetrating ocular injuries with retained intraocular foreign bodies. *Ophthalmology*. 1988;95:911–916.
2. Greven CM, Engelbrecht NE, Slusher MM, Nagy SS. Intraocular foreign bodies: management, prognostic factors, and visual outcomes. *Ophthalmology*. 2000;107:608–612.
3. Slusher MM. Intraretinal foreign bodies: management and observations. *Retina*. 1990;10(suppl 1):S50–S54.