



Periostitis Ossificans: Largest Case Series with Review of Literature

Ahmed Saad¹ Karthikeyan P. Iyengar² Vineet John Kurisunkal¹ Neha Nischal³ A.M. Davies³
Rajesh Botchu³

¹Department of Orthopedic Oncology, Royal Orthopaedic Hospital NHS Foundation Trust, Birmingham, United Kingdom

²Department of Orthopedics, Southport and Ormskirk Hospital NHS Trust, Southport, United Kingdom

³Department of Musculoskeletal Radiology, Royal Orthopaedic Hospital NHS Foundation Trust, Birmingham, United Kingdom

Address for correspondence Rajesh Botchu, MRCS, FRCR, Department of Musculoskeletal Radiology, Royal Orthopaedic Hospital, Bristol Road South B21 3AP, Northfield, Birmingham, United Kingdom (e-mail: drbrajesh@yahoo.com).

Indian J Radiol Imaging 2024;34:32–36.

Abstract

Background Periostitis ossificans (PO) are rare, benign ossifying surface lesions characterized by the centripetal ossification with osseous and soft-tissue edema. Their clinicoradiological appearances can easily mimic those of more sinister or infective surface lesion.

Objective This study aimed to explore the various anatomical locations and muscle attachment at the site of PO, and evaluate the role of complementary image findings in patients presenting at our tertiary orthopaedic referral center.

Patients and Methods A retrospective review of our oncology and radiology databases was undertaken to identify patients with PO reported on radiographs, magnetic resonance imaging (MRI) and computed tomography (CT) over the past 13 years (2007–2020).

Patient demographics, sites of PO, muscle attachment at the site of PO, findings on complementary imaging, and clinical management outcome were documented.

Results We identified 38 patients with PO with a mean age of 24 years (range: 4–66 years). Muscle attachment was seen at the site of PO in the majority of cases (89%). The majority of PO were in the lower limb and commonly seen around the attachment of quadriceps. Deltoid attachment was commonly involved in the upper limb.

Conclusion Muscle attachment is commonly seen at the site of PO, which results in stripping of the periosteum resulting in soft-tissue and osseous edema and centripetal ossification.

Keywords

- ▶ orthopedics
- ▶ periosteum
- ▶ lower extremity
- ▶ upper extremity
- ▶ computed tomography
- ▶ magnetic resonance imaging

Introduction

Periostitis ossificans (PO) is akin to myositis ossificans. This is defined as surface lesion with centripetal ossification, soft tissue and osseous edema, and stripping of

the periosteum. The imaging features can mimic a sinister surface lesion, and appropriate diagnosis is key to decrease morbidity. We present the largest series of PO. We hypothesize that muscle attachment at the site of

article published online
July 14, 2023

DOI <https://doi.org/10.1055/s-0043-1770723>.
ISSN 0971-3026.

© 2023. Indian Radiological Association. All rights reserved.
This is an open access article published by Thieme under the terms of the Creative Commons Attribution-NonDerivative-NonCommercial-License, permitting copying and reproduction so long as the original work is given appropriate credit. Contents may not be used for commercial purposes, or adapted, remixed, transformed or built upon. (<https://creativecommons.org/licenses/by-nc-nd/4.0/>)
Thieme Medical and Scientific Publishers Pvt. Ltd., A-12, 2nd Floor, Sector 2, Noida-201301 UP, India

PO causes periosteum stripping and elevation resulting in PO.

Patient and Methods

Study Design and Patients

Following local hospital committee approval, a retrospective review of our oncology database, Radiology Information System (RIS), and computerized radiology information system (CRIS) was undertaken to identify patients with PO reported on plain radiographs, magnetic resonance imaging (MRI), and computed tomography (CT) over the past 13 years (2007–2020). Most patients had radiographs, MRI, and CT. Patient demographics, clinical characteristics, and the data were categorized according to the site of the lesions and anatomical structure. The diagnosis was made on imaging alone as it is a “do not touch lesion.”

Image Analysis

The radiological images of all the patients were reviewed by a musculoskeletal radiologist with over 35 years of experience (AMD) and a fellowship-trained musculoskeletal radiologist with more than 10 years' experience (RB) for analysis. Radiographs, MRI, and CT were reviewed in all cases. MRI protocol involved a combination of T1 and fluid sensitive sequence (T2 fat suppressed or short tau inversion recovery [STIR]) images in axial and coronal or sagittal view. Radiographs and CT were analyzed for pattern of soft-tissue ossification and if this was in continuity with the adjacent bones. MR images were assessed for the presence of soft-tissue edema, osseous edema, periosteal stripping/elevation, and soft-tissue ossification. The presence of centripetal pattern of soft-tissue ossification continuous with adjacent bone was diagnostic of PO. The images were analyzed to ascertain the muscle group at the site of PO.

Data Analysis

Demographic data, clinical characteristics, and imaging features were collected from radiology and our oncology database for evaluation. Information was collated and analyzed using a Microsoft Excel data sheet for analysis.

Results

Our review identified a total of 38 patients with PO. The average age of our cohort was 24 years (range: 4–66 years). There was a male predominance with a ratio of 1.4 males to 1 female (22 males and 16 females). Muscle attachment at the site of PO was noted in the majority of cases (89% of cases [$n = 34$]). PO was more commonly seen in the lower limb, with quadriceps muscle (vastus intermedius) attachment frequently involved (**Table 1**). Forty-one percent cases ($n = 14$) were in the upper limb (UL). Of these, the majority involved the deltoid muscle attachment (12% of cases [$n = 4$]; **Figs. 1–5**).

Table 1 Various site of periostitis ossificans (muscle or tendon attachment) and number of patients with the condition within our study cohort

Muscle or tendon at the site of periostitis ossificans	Number of patients with the condition
Brachialis	3
Brachioradialis	1
Deltoid	4
Extensor carpi ulnaris	2
Extensor digitorum longus	1
Flexor digitorum profundus	1
Interossei muscle hand	3
Peroneus brevis	2
Soleus	2
Tibialis anterior	1
Trapezius	1
Vastus intermedius	11
Vastus lateralis	1
Vastus medialis	1
Total	34

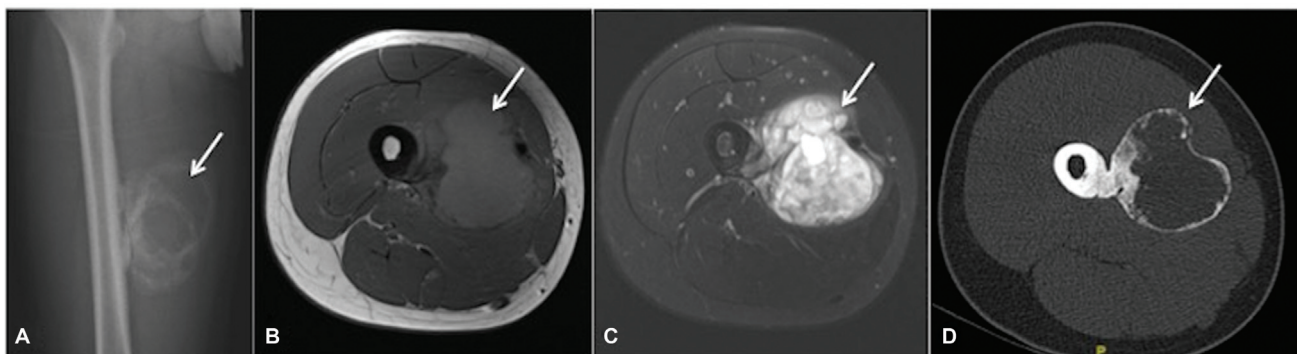


Fig. 1 Anteroposterior (AP) radiographs of the (A) right femur, (B) axial T1, (C) short tau inversion recovery (STIR), and (D) computed tomography (CT) showing periostitis ossificans in relation to the medial aspect of the femur corresponding to attachment of the vastus intermedius and vastus lateralis.

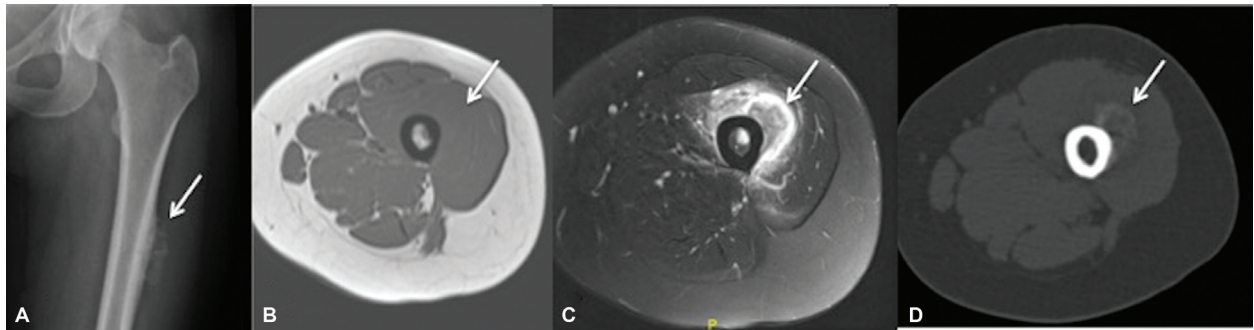


Fig. 2 AL radiographs of the (A) left femur, (B) axial T1, (C) short tau inversion recovery (STIR), and (D) computed tomography (CT) showing periostitis ossificans in relation to the anterior aspect of the medial aspect of the femur corresponding to the attachment of the vastus intermedius.

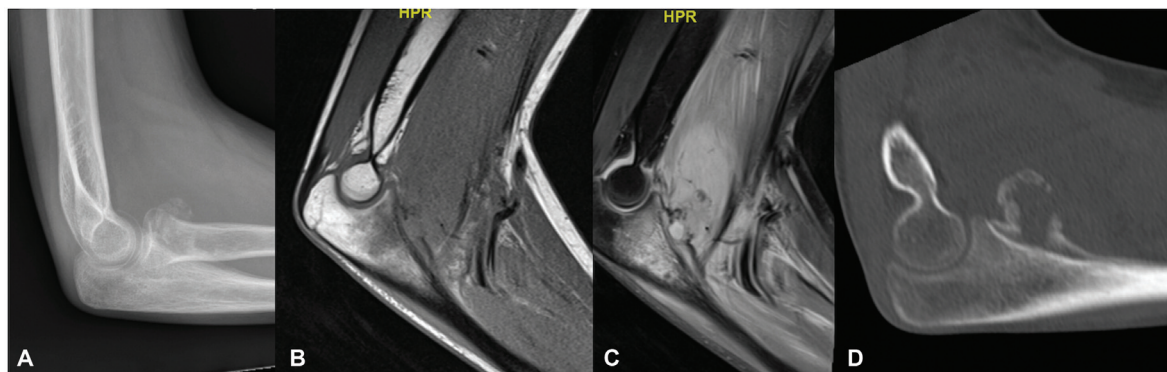


Fig. 3 Lateral radiographs of the (A) elbow, (B) sagittal T1, (C) short tau inversion recovery (STIR), and (D) computed tomography (CT) showing periostitis ossificans in relation to the anterior aspect of the proximal ulna corresponding to the attachment of the brachialis.

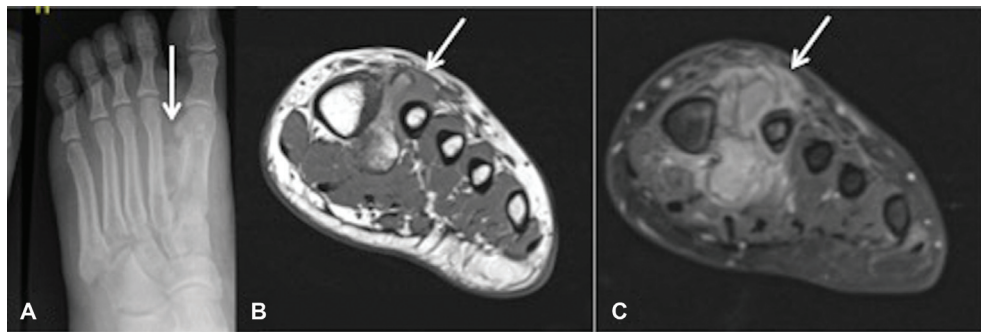


Fig. 4 Radiographs of the (A) dorsoplantar, (B) coronal T1, and (C) T2 fat suppressed of the foot showing focus of the periostitis ossificans (PO) in between the first and second metatarsal and communication with the lateral cortex of the first metatarsal.

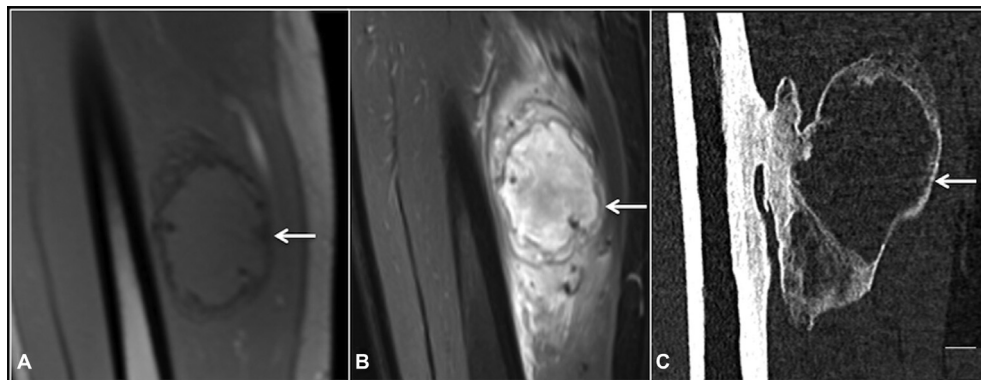


Fig. 5 Coronal (A) T1, (B) short tau inversion recovery (STIR), and (C) computed tomography (CT) showing periostitis ossificans in relation to the medial aspect of the femur. Note the communication between the femur and the focus of ossification.

In four cases, no muscle or tendon attachment could be found at the site of PO. These included a single case involving each of the radius, linea aspera, proximal phalanx, and little finger metacarpal.

Discussion

PO is a type of hypertrophic ossification. It represents a part of the spectrum of conditions with similar overlapping features such as bizarre parosteal osteochondromatous proliferation (BPOP), benign fibro-osseous pseudotumors, and turret exostosis.^{1–5}

We believe the pattern and direction of periosteal stripping play a role in the development of PO at the various anatomical regions. The periosteum plays a critical part in serving as an attachment for muscles, tendons, and ligaments in humans. The process of ripping and repairing the periosteum following traumatic injuries leads to periosteal elevation and the development of soft-tissue ossification.⁶ In our cohort, history of trauma could not be elicited in any patients. We hypothesize that it could have been due to a sequela of trauma that they did not remember or presumed the event to be not important. Due to the presence of pluripotential mesenchymal cells and growth factors, periosteal disruption stimulates ossification. This is supported by the identification of PO at the site of muscle attachment in most patients in our series.⁷

Clinically, patients with PO may present with nonspecific symptoms including pain, swelling, or skin erythema overlying the affected area.^{4,8,9} The imaging features of PO may overlap with other bone lesions such as BPOP, osteomyelitis, or myositis ossificans, and mimic highly sinister surface bone lesions, such as parosteal osteosarcomas (POS).^{4,10–14} This can represent a diagnostic dilemma to clinicians. Therefore, careful radiographic evaluation and diagnoses is required to ensure appropriate management is initiated. Traditionally, the first-line investigation for PO is radiography. This may depict a mixture of smooth and solid centripetal soft-tissue ossification associated with soft-tissue swelling. On CT imaging, the lesions can further be delineated to affect the external cortex, with preservation of the internal cortex.^{3,4,8,9} MRI is important to assess soft-tissue involvement, and often demonstrates osseous edema, soft-tissue edema, periosteal elevation, and low signal corresponding to the site of ossification.^{4,5,8} PO features can be like that of POS. The key differentiator between them is the absence of inflammatory oedema and dense consolidation in POS. POS are commonly seen in young adults (20–40 years) with a predilection to the posterior aspect of the distal femora. Unlike PO in myositis ossificans, there is no connection between focus of heterotopic ossification and the adjacent bone. The presence of penumbra sign (peripheral of T1 high signal), sequestrum, and cortical thickening in osteomyelitis helps differentiate it from PO.

The periosteum is formed of two distinct layers: an inner layer (cambium) with significant osteoblastic potential and an outer fibrous layer.^{6,15} There is a mixture of reactive osteoblastic and fibroblastic proliferation of both layers,

with accompanying new woven bone formation. Osteoblasts can have atypical features; however, irregular mitotic appearances and cellular pleomorphism are absent, which are key in differentiating osteoblasts from malignant lesions.

Management of PO can be quite challenging to orthopaedic surgeons, and often depends on the severity of symptoms and anatomical location. The symptoms include pain and restriction of movements. The lesion demonstrates progressive centripetal ossification with resolution of osseous and soft-tissue edema over time. The management of this condition may consist of conservative symptomatic treatment with nonsteroidal anti-inflammatory drugs (NSAIDs), limb rest, and physiotherapy.⁵ However, surgical resection is rarely performed and is reserved to those with severe symptoms.⁹

Our study has few limitations. The numbers are relatively small; however, we feel our cohort is large enough to draw conclusions, in particular, about the imaging findings. The case selection is slightly biased as all were referred to tertiary orthopaedic oncology hospital as suspected tumor.

Conclusion

We would like to highlight that PO are rare surface lesions. Appropriate diagnostic measures are crucial to distinguish these from sinister neoplastic lesions. We recommend radiological follow-up to assess the lesion and ensure progressive centripetal ossification.

Funding

None.

Conflict of Interest

None declared.

References

- Riaz M, McCluggage WG, Bharucha H, Small JO. Florid reactive periostitis of the thumb. *J Hand Surg [Br]* 1996;21(02):276–279
- Jambhekar NA, Desai SS, Puri A, Agarwal M. Florid reactive periostitis of the hands. *Skeletal Radiol* 2004;33(11):663–665
- Saad A, Azzopardi C, Patel A, Davies AM, Botchu R. Myositis ossificans revisited: the largest reported case series. *J Clin Orthop Trauma* 2021;17:123–127
- Sundaram M, Wang L, Rotman M, Howard R, Saboeiro AP. Florid reactive periostitis and bizarre parosteal osteochondromatous proliferation: pre-biopsy imaging evolution, treatment and outcome. *Skeletal Radiol* 2001;30(04):192–198
- Jamshidi K, Givehchian B, Mirzaei A. Florid reactive periostitis of the long bone: a case series of seven patients. *J Orthop Sci* 2017;22(03):560–565
- Dwek JR. The periosteum: what is it, where is it, and what mimics it in its absence? *Skeletal Radiol* 2010;39(04):319–323
- Malizos KN, Papatheodorou LK. The healing potential of the periosteum molecular aspects. *Injury* 2005;36(Suppl 3):S13–S19
- Levy JL, Louka KL, Cooper K, Weber KL, Dianat S. Focal reactive periostitis ossificans in a long bone: radiologic and pathologic findings. *Radiol Case Rep* 2021;16(12):3638–3642
- Spjut HJ, Dorfman HD. Florid reactive periostitis of the tubular bones of the hands and feet. A benign lesion which may simulate osteosarcoma. *Am J Surg Pathol* 1981;5(05):423–433

- 10 Byun BH, Koh JS, Yoo JY, Lim SM, Kong CB. (99m)Tc-MDP- and (18F)-FDG-avid florid reactive periostitis ossificans mimicking recurrent osteosarcoma. *Clin Nucl Med* 2013;38(06):482–483
- 11 Soni A, Weil A, Wei S, Jaffe KA, Siegal GP. Florid reactive periostitis ossificans of the humerus: case report and differential diagnosis of periosteal lesions of long bones. *World J Orthop* 2015;6(07):559–563
- 12 Ribeiro JNA, Cavalcante MLC, Farias DA, Bingana RD. Florid reactive periostitis of the proximal phalanx: case report and literature review. *Rev Bras Ortop* 2019;54(03):335–338
- 13 Azorín D, López-Pino MA, González-Mediero I, Epeldegui T, López-Barea F. Long bone florid reactive periostitis ossificans: a case in the distal femur mimicking osteosarcoma. *J Pediatr Orthop B* 2008;17(06):301–305
- 14 Brien EW, Mirra JM, Latanza L, Fedenko A, Luck J Jr. Giant bone island of femur. Case report, literature review, and its distinction from low grade osteosarcoma. *Skeletal Radiol* 1995;24(07):546–550
- 15 Squier CA, Ghoneim S, Kremenak CR. Ultrastructure of the periosteum from membrane bone. *J Anat* 1990;171:233–239