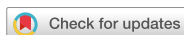

Images in  
Cardiovascular Medicine



# Cardiac Sarcoidosis Presenting as Complete Atrioventricular Block: Findings on PET/MRI

Chan-Hee Lee , MD, PhD<sup>1</sup>, Jang-Won Son , MD, PhD<sup>1</sup>, and Eun-Jung Kong , MD, PhD<sup>2</sup>

<sup>1</sup>Division of Cardiology, Department of Internal Medicine, Yeungnam University Medical Center, Daegu, Korea  
<sup>2</sup>Department of Nuclear Medicine, Yeungnam University Medical Center, Daegu, Korea

OPEN ACCESS

**Received:** Feb 4, 2018  
**Revised:** May 4, 2018  
**Accepted:** May 30, 2018

**Correspondence to**

Chan-Hee Lee, MD, PhD

Division of Cardiology, Department of Internal Medicine, Yeungnam University Medical Center, Yeungnam University College of Medicine, 170, Hyeonchung-ro, Nam-gu, Daegu 42415, Korea.  
E-mail: chanheebox@naver.com

Copyright © 2018. The Korean Society of Cardiology

This is an Open Access article distributed under the terms of the Creative Commons Attribution Non-Commercial License (<https://creativecommons.org/licenses/by-nc/4.0>) which permits unrestricted noncommercial use, distribution, and reproduction in any medium, provided the original work is properly cited.

**ORCID iDs**

Chan-Hee Lee   
<https://orcid.org/0000-0001-9338-0679>  
Jang-Won Son   
<https://orcid.org/0000-0002-8109-5018>  
Eun-Jung Kong   
<https://orcid.org/0000-0002-2300-4675>

**Conflict of Interest**

The authors have no financial conflicts of interest.

**Author Contributions**

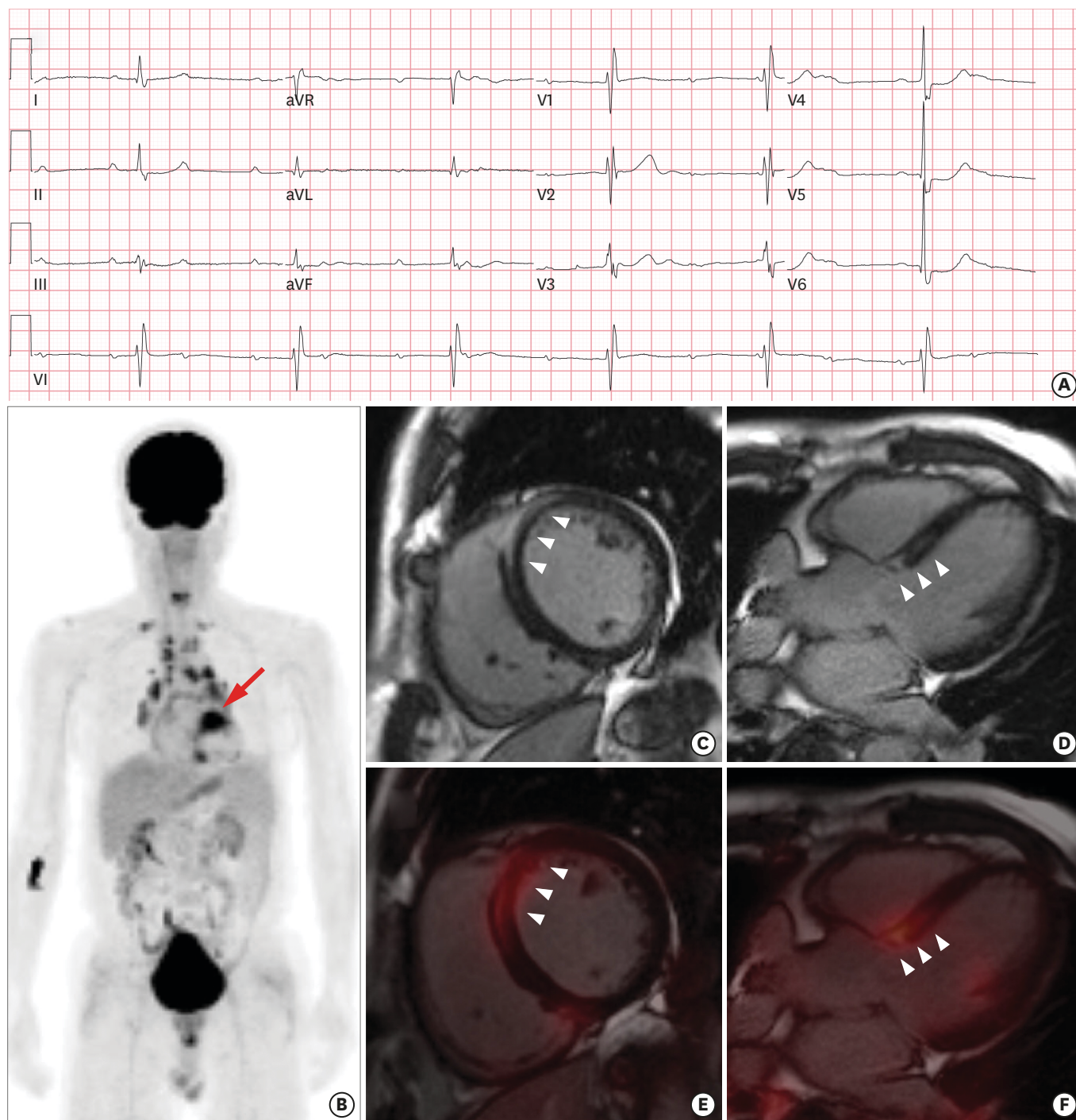
Data curation: Son JW; Methodology: Kong EJ; Software: Kong EJ; Writing - original draft: Lee CH; Writing - review & editing: Lee CH.

A 72-year-old male was transferred from a health promotion center with complete atrioventricular block (CAVB, **Figure 1A**). He complained of dyspnea, and had a 1-year history of hypertension and 50 pack-year history of smoking. A whole body fluorodeoxyglucose (FDG) positron emission tomography/magnetic resonance imaging (PET/MRI), taken during a medical check-up, revealed multiple supraclavicular and mediastinal lymphadenopathies, and a hot FDG uptake in the septal area of the heart (**Figure 1B**, arrow). An FDG cardiac PET/MRI was performed for a further evaluation 3 weeks later. The PET/MRI revealed a late gadolinium enhancement (LGE) in the mid-wall of the basal septum (**Figure 1C and 1D**, arrowheads) with a corresponding FDG uptake (**Figure 1E and 1F**, arrowheads). Bronchoscopy was performed for an endobronchial ultrasound guided lymph node (LN) biopsy, and an endobronchial mass was incidentally found in the right upper apical segment. The endobronchial mass was confirmed as a squamous cell carcinoma. A permanent pacemaker implantation was performed with steroid therapy under planning for an operation. A right upper lobectomy was performed with a mediastinal LN dissection (2R, 4R, 10R, 3A, 7, 8, and 9) by video-assisted thoracoscopic surgery. The LN biopsy revealed chronic granulomatous inflammation without a tumor metastasis. He had a final diagnosis of sarcoidosis involving the heart and mediastinal LN, concurrent with lung cancer.

In this case, the cardiac PET/MRI well-visualized the myocardial inflammation and fibrosis related to the CAVB. Comprehensive imaging with cardiac PET/MRI could be the gold standard for a clinical diagnosis<sup>(1,2)</sup> in cardiac sarcoidosis.

## REFERENCES

1. Dweck MR, Abgral R, Trivieri MG, et al. Hybrid magnetic resonance imaging and positron emission tomography with fluorodeoxyglucose to diagnose active cardiac sarcoidosis. *JACC Cardiovasc Imaging* 2018;11:94-107.  
[PUBMED](#) | [CROSSREF](#)
2. Terasaki F, Yoshinaga K. New guidelines for diagnosis of cardiac sarcoidosis in Japan. *Ann Nucl Cardiol* 2017;3:42-5.  
[CROSSREF](#)



**Figure 1.** (A) Electrocardiogram; PET/MRI. (B) A whole-body image of the FDG uptake. T1-weighted image; (C) short-axis and (D) long-axis, and cardiac PET/MRI image; (E) short-axis and (F) long-axis.

FDG = fluorodeoxyglucose; MRI = magnetic resonance imaging; PET = positron emission tomography.