



Case report

Drug-induced hepatitis after Sinopharm COVID-19 vaccination: A case study of a 62-year-old patient

Hossein Ghorbani^a, Tina Rouhi^{a,*}, Zeinab Vosough^a, Javad Shokri-shirvani^b^a Cancer Research Center, Department of Pathology, Babol University of Medical Science, Mazandaran, Iran^b Cancer Research Center, Department of Gastroenterology, Babol University of Medical Science, Mazandaran, Iran

ARTICLE INFO

Keywords:

Infectious diseases

Allergy and immunology

Gastroenterology and hepatology

Case report

ABSTRACT

Introduction: COVID-19 virus pandemic has begun since 2020 and became one of the most important causes of mortalities. Accordingly, vaccination has found a vital role in control of COVID-19 virus. Despite many advantages of vaccines in controlling the virus spread and reducing the mortal rate, these benefits came at the expense of side effects which have not been fully explored nor should be ignored. One of the most serious side effects of vaccination, which has been reported recently, is liver injury.

Case presentation: This study presents a case of hepatitis initiated by Sinopharm vaccine for COVID-19. A 62-year-old man presented with jaundice, weight loss and elevated liver enzymes three days after getting the second dose of COVID-19 vaccine. Microscopic sections showed hepatitis pattern of injury with both portal and lobular inflammation and marked eosinophils infiltration.

Discussion: Several cases of hepatitis have been reported after COVID-19 vaccines, but almost all of them were diagnosed as autoimmune hepatitis, triggered by COVID-19 mRNA or viral vector vaccines but the present case is one of the first reported cases of hepatitis after Sinopharm vaccine, an inactivated virus COVID-19 vaccine. Spontaneous decrease in liver enzyme levels, without corticosteroids therapy, is against to the diagnosis of autoimmune hepatitis in other reported cases.

Conclusion: Considering the microscopic findings, along with the negative serologic studies for viral and autoimmune hepatitis, and by ruling out of other causes of hepatitis like COVID-19 or other viral infections, a probable relation between liver injury and Sinopharm vaccine may be interpreted.

1. Introduction

Coronavirus disease (COVID-19) is an infectious disease caused by the SARS-CoV-2 virus. It has been spread worldwide since March 2020 and became one of the most serious causes of mortalities, specially, among elderly and immunocompromised people [1]. This virus is able to affect different organs such as kidney, lung and liver causing organ failure. Therefore, there is an urgent need for an effective way to control spread of COVID-19 virus, and vaccination can be a good choice for this achievement [2]. Nowadays, different types of vaccines have been developed by different pharmaceutical companies [3]. In addition to the benefits of vaccination, the side effects should be fully considered. Mild side effects, which are the most common, include swelling at injection site, fever and myalgia. However, more serious side effects such as seizure, life-threatening allergic reactions and thrombocytopenia have been reported as well [2,4]. Some trials also reported decreased

hemoglobin, increased bilirubin, elevated AST (aspartate aminotransferase) and ALT (alanine aminotransferase) [5]. Recently, in different reports, probable association between vaccination and onset of immune-mediated disorders such as autoimmune hepatitis has been observed [6]. Autoimmune hepatitis is an immune-mediated inflammatory liver disease which affects people in different ages. Diagnosis is based on combination of clinical, laboratory and histological features [7]. Autoimmune hepatitis has been reported after both COVID-19 infection and vaccination against it [8] but the presented case is one of the first reported cases of hepatitis after Sinopharm vaccine, an inactivated virus COVID-19 vaccine. Spontaneous decrease in liver enzyme levels during hospitalization in our patient, without corticosteroids therapy, is also against what should have been observed in autoimmune hepatitis which were reported in other vaccines, so it is important to be aware of side effects of Sinopharm vaccine in form of drug-induced hepatitis rather than autoimmune causes to avoid prescribing unnecessary drugs like

* Corresponding author at: Department of Pathology, School of Medicine, Babol University of Medical Science, Babol 4714636897, Iran.

E-mail address: Rouhitina0@gmail.com (T. Rouhi).<https://doi.org/10.1016/j.ijscr.2022.106926>

Received 19 February 2022; Received in revised form 4 March 2022; Accepted 6 March 2022

Available online 9 March 2022

2210-2612/© 2022 The Authors. Published by Elsevier Ltd on behalf of IJS Publishing Group Ltd. This is an open access article under the CC BY-NC-ND license (<http://creativecommons.org/licenses/by-nc-nd/4.0/>).

corticosteroids with lots of side effects.

2. Case history/examination

A 62-year-old man, without previous history of liver disease, referred to hospital with weakness and jaundice, just three days after getting the second dose of Sinopharm vaccine, an inactivated virus COVID19 vaccine. Other complaints were itching and weight loss, which were added to symptoms gradually. He had no problem and symptom after first dose of vaccine. There was no recent complaint of COVID19 infection symptoms such as fever, cough, sore throat, or breathing difficulties. Medical history included hypertension and diabetes mellitus, and he was on Metformin, Glibenclamide and Losartan tabs. There was no history of alcohol intake or immune deficiency disease. In physical examination the patient's mental status was intact. Yellow colored skin and scleral icterus were detected. Abdomen was soft with no tenderness. No lymphadenopathy, hepatomegaly or splenomegaly was identified. Liver span was normal (about 10 cm). Vital signs including RR: 30, HR: 85, BP: 140/90, T: 36.8 °C.

2.1. Differential diagnosis, investigations and treatment

Ultrasonography showed mild parenchymal coarseness and wall thickness of common bile duct, while other findings were normal. Endosonography and MRCP reports were normal. In the first lab Data, ALT: 722 U/L (normal range < 37), AST: 435 U/L (normal range < 41), ALP: 512 U/L (normal range: 80–306), total bilirubin: 8 mg/dl (normal range: 0.1–1.2), direct bilirubin: 3.2 mg/dl (normal range < 0.3), negative ANA (antinuclear antibody), negative ASMA (anti-smooth muscle antibody), negative anti-LKM-1 (liver/kidney microsome antibody) and negative viral markers were detected. Sonoguided core needle biopsy from liver was done. Specimen received in formalin. Sections were taken and stained by Hematoxylin and Eosin. Microscopic sections showed severe infiltration of lymphocytes, eosinophils, and neutrophils in portal tract (score: 3/4) and lobules (score: 4/4) accompanied by interface hepatitis (score: 4/4) and feathery change. Foci of ductular

reaction were seen too. No confluent necrosis was identified (score: 0/6), [Figs. 1, 2](#). Final grading and staging, according to Ishak modified hepatitis activity index, were 11/18 and 1/6, respectively. According to these findings, autoimmune and viral hepatitis were the main differential diagnosis. Spontaneous decrease in liver enzyme levels during hospitalization, without corticosteroid therapy, and negative specific markers were against what should have been observed in autoimmune hepatitis. Negative viral markers were against viral hepatitis too. Also, RUCAM score was 6 which meant probable relationship between vaccination and liver damage [9]. During admission, the patient was on ursodeoxycholic acid tab and liver enzymes began to decrease gradually, [Fig. 3](#). This work has been reported in line with the SCARE 2020 criteria [10].

2.2. Outcome and follow-up

The patient was on Ursodeoxycholic acid tab. Clinical signs began to disappear and liver enzymes decreased gradually. After three months follow up, detected lab data was ALT: 33 U/L (normal range < 37), AST: 30 U/L (normal range < 41), ALP: 275 U/L (normal range: 80–306), [Fig. 3](#).

3. Discussion

This study presents a 62-year-old man with hepatitis after getting the second dose of COVID-19 vaccine. Several cases of hepatitis have been reported after COVID-19 vaccines ([Table 1](#)). Almost all of them were diagnosed as autoimmune hepatitis, triggered by COVID-19 vaccine. Most of reported cases were related to mRNA COVID-19 vaccines except for three of them which were after Covishield vaccine (Oxford-AstraZeneca), a viral vector vaccine using a modified chimpanzee adenovirus ChAdOx1. The present case is the first reported case of hepatitis after Sinopharm vaccine, an inactivated virus COVID-19 vaccine [6,8,11–16]. In some cases, symptoms were manifested after the first dose of vaccination [8,12–15], but in others, symptoms began after the second dose, just like the presented case [6,11,13]. Most cases showed symptoms

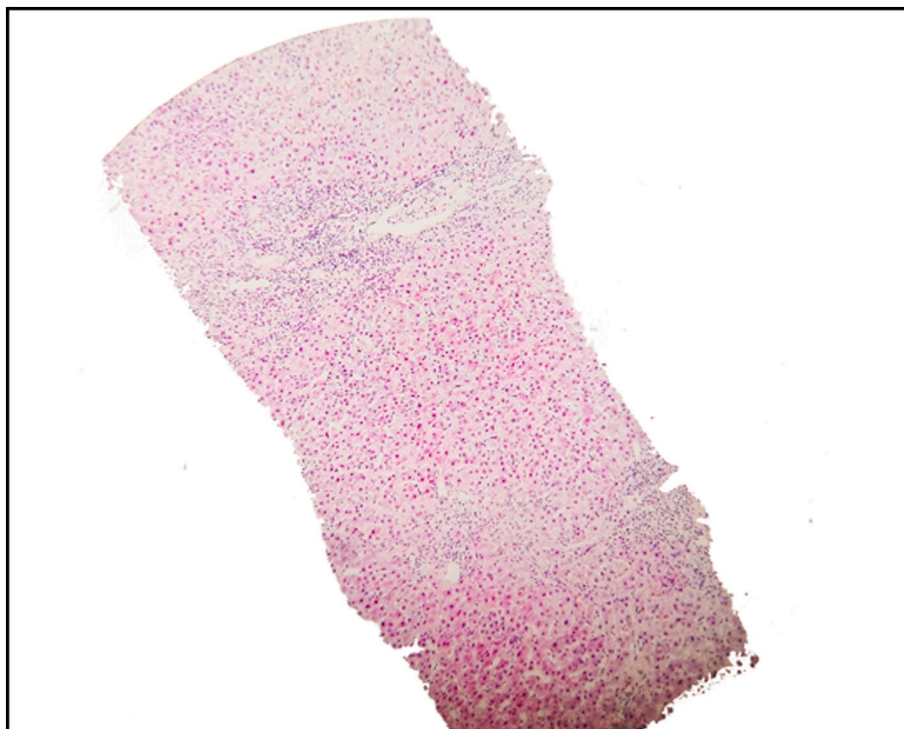


Fig. 1. Liver biopsy, portal and lobular inflammation.

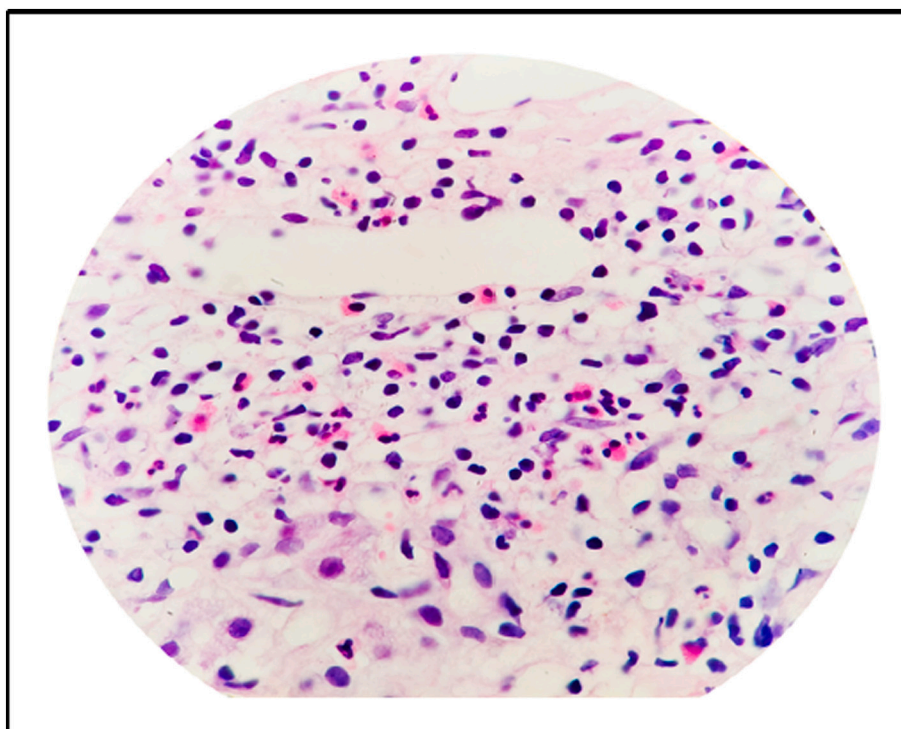


Fig. 2. Liver biopsy, marked eosinophilic infiltration.

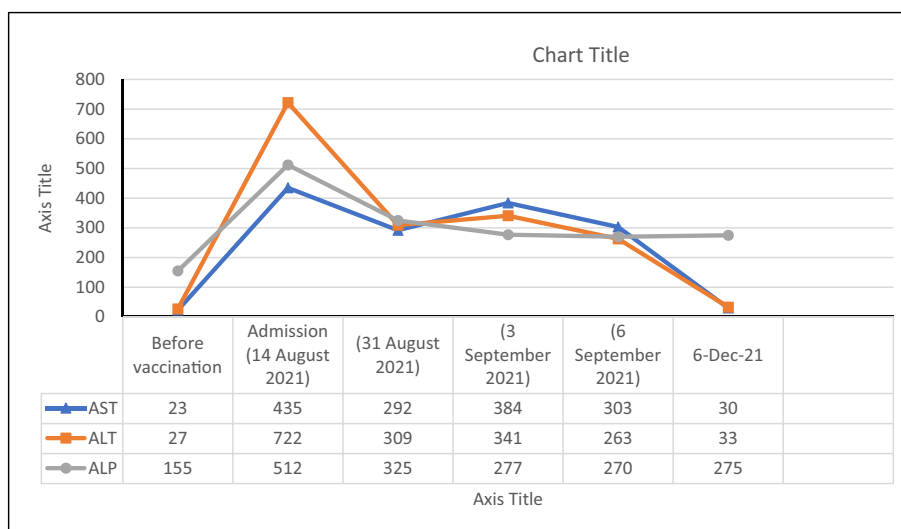


Fig. 3. Liver enzymes trend before and after vaccination.

after seven days or more of vaccination [6,8,11,13,15,16], but in the current case, symptoms started only three days after vaccination. There was only one case that reported symptoms in such short time, but it was observed after the first dose [14]. Similar to the other cases, the presented case showed elevated AST, ALT, Bilirubin, and ALP with negative viral markers, but any of specific and nonspecific markers of other types of hepatitis were positive. Microscopic sections showed portal and lobular inflammation with prominent eosinophilic infiltration. According to normal MRCP, EUS and US and based on findings in microscopic study, the other causes of hepatitis can be ruled out [6,8,11–16] (Fig. 4). Unlike most reported cases, the presented case developed liver injury symptoms shortly after receiving vaccination which makes autoimmune cause unlikely. Also, the patient didn't have symptoms when he received the first dose of Sinopharm vaccine contrary to what have been observed

in other reports. Spontaneous decrease in liver enzyme levels during hospitalization, without corticosteroids therapy, is also against what should have been observed in autoimmune hepatitis. Eosinophils were also abundant which is a clue to drug associated hepatitis, since the patient didn't receive any drugs other than the vaccine. Therefore, the main culprit could have been the vaccine itself. The best approach to solve this problem is a long course of patient follow-up. If patient's liver enzymes wouldn't decrease to normal level or it raises again, the autoimmune hepatitis probability is amplified, otherwise drug-induced liver injury stays in the top of differential diagnosis list. If the case proved to be autoimmune hepatitis, like other reported cases, cannot definitely link this observation to vaccination because it could be coincidental. The lack of epidemiologic studies is felt here but it's like other issues raised with covid because of limited knowledge in this field. With the extensive

Table 1
Reported cases of liver injury after COVID vaccines.

Study	Patient characteristic	Vaccine	Latency period	AST/ALT at presentation (U/l)	Total bilirubin at presentation (mg/dl)	Antibody	IgG	Biopsy
Ghielmetti M [8].	63-year-old male	mRNA vaccine	Seven days after the first dose	1127/1038	11.9	- ANA - Gastric parietal cells antibody - Atypical AMA	Slightly elevated	Acute autoimmune (AIH)-like hepatitis
Rocco A [6].	80-year-old female	mRNA vaccine (PfizerBioNTech)	1 week after completing the schedule	1401/1186	10.5	ANA	Increased	AIH
Bril F [12].	35-year-old female	mRNA vaccine (PfizerBioNTech)	Seven days after the first dose	754/2001	4.8	- ANA - ds DNA	Normal	AIH
Clayton-Chubb D [13].	36-year-old male	(Oxford-AstraZeneca) vaccine	26 days after the first dose	633/1774	9.9	ANA	Normal	AIH
Londoño M-C [11].	41-year-old female	mRNA vaccine (Moderna)	Seven days after the second dose	993/1312	2.3	- ANA - ASM - SLA - LC1	Increased	AIH
Rela M [16].	38-year-old female	Covishield (Oxford-AstraZeneca) vaccine	20 days following administration	1101/1025	14.9	ANA	Mildly increased	AIH
Rela M [16].	62-year-old male	Covishield (Oxford-AstraZeneca) vaccine	13 days after the second dose	1361/1094	19.2	-	-	AIH
Tan CK [15].	56-year-old female	mRNA vaccine (Moderna)	Five weeks after receiving the first dose	1124/1701	5.9	- ANA - ASMA	Increased	AIH
Vuille-Lessard É [14].	76-year-old female	mRNA vaccine (Moderna)	Two to three days after receiving the first dose	811/579	3.8	- ANA - ASMA	Significantly increased	AIH
McShane C [17].	71-year-old female	mRNA vaccine (Moderna)	Four days post vaccination	-/1067	15.7	ASMA	Increased	AIH

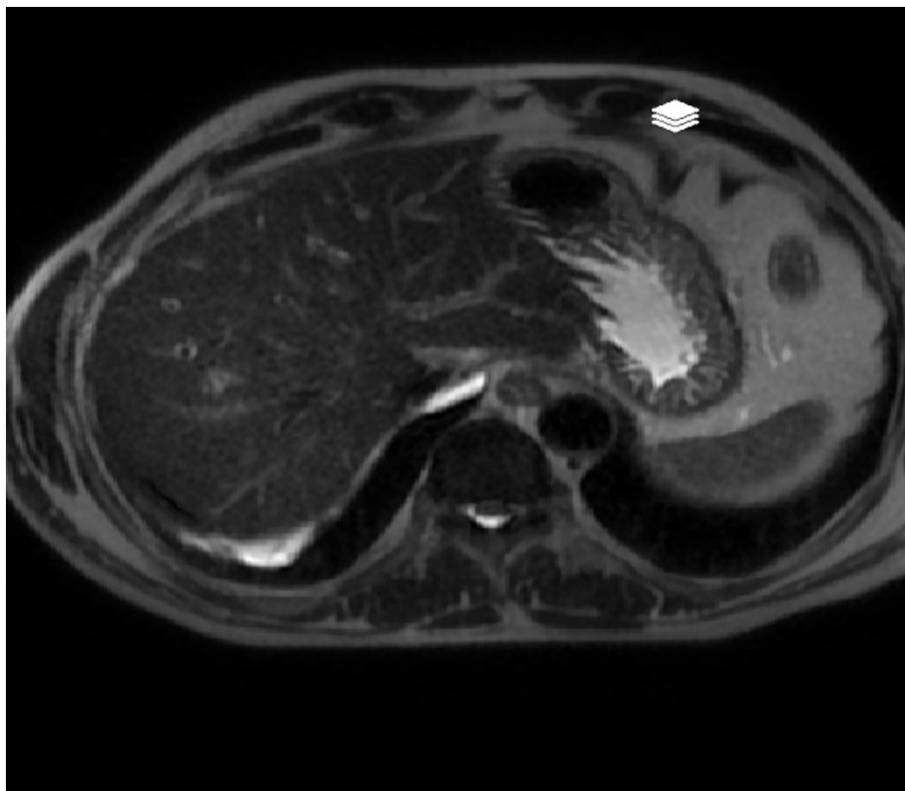


Fig. 4. MRCP of the patient.

vaccination, increased trend of this issue was observed, it may be inferred that COVID-19 vaccination triggers the autoimmune hepatitis.

4. Conclusion

According to the patient history, microscopic findings with marked eosinophilic infiltration, negative serologic studies for viral and autoimmune hepatitis and by ruling out of other causes of hepatitis like COVID-19 or other viral infections, there might be a close relation between liver injury and Sinopharm vaccine and Sinopharm vaccine would be the most probable cause of hepatitis in the presented case.

Patient consent statement

Written informed consent was obtained from the patient for publication of this case report and accompanying images. A copy of the written consent is available for review by the Editor-in-Chief of this journal on request.

Provenance and peer review

Not commissioned, externally peer-reviewed.

Ethical approval

This study was approved by the ethics committee of Babol University of Medical Sciences.

Funding

None.

Guarantor

Dr Tina Rouhi.

Research registration number

None.

CRediT authorship contribution statement

Hossein Ghorbani: Detected the case and lead the study.
Tina Rouhi: Analyzed the data and wrote the manuscript.
Zeinab Vosough: Reviewed and revised the manuscript.
Javad Shokri-shirvani: Detected the case and did the procedure of biopsy.

Declaration of competing interest

None.

References

- [1] J. Zhao, S. Zhao, J. Ou, et al., COVID-19: coronavirus vaccine development updates, *Front. Immunol.* 11 (2020), 602256, <https://doi.org/10.3389/fimmu.2020.602256>.
- [2] J.R. Teijaro, D.L. Farber, COVID-19 vaccines: modes of immune activation and future challenges, *Nat. Rev. Immunol.* 21 (4) (2021) 195–197, <https://doi.org/10.1038/s41577-021-00526-x>, 2021/04/01.
- [3] D. Freeman, B.S. Loe, L.-M. Yu, et al., Effects of different types of written vaccination information on COVID-19 vaccine hesitancy in the UK (OCEANS-III): a single-blind, parallel-group, randomised controlled trial, *Lancet Public Health* 6 (6) (2021) e416–e427, [https://doi.org/10.1016/S2468-2667\(21\)00096-7](https://doi.org/10.1016/S2468-2667(21)00096-7).
- [4] A. Hines, J.G. Shen, C. Olazagasti, S. Shams, Immune thrombocytopenic purpura and acute liver injury after COVID-19 vaccine, *BMJ Case Rep.* 14 (7) (Jul 30 2021), <https://doi.org/10.1136/bcr-2021-242678>.
- [5] R.J. Kaur, S. Dutta, P. Bhardwaj, Adverse events reported from COVID-19 vaccine trials: a systematic review, *Indian J. Clin. Biochem.* (2021) 1–13, <https://doi.org/10.1007/s12291-021-00968-z>.
- [6] A. Rocco, C. Sgamato, D. Compare, G. Nardone, Autoimmune hepatitis following SARS-CoV-2 vaccine: may not be a causality, *J. Hepatol.* 75 (3) (2021) 728–729, <https://doi.org/10.1016/j.jhep.2021.05.038>.
- [7] G. Mieli-Vergani, D. Vergani, A.J. Czaja, Autoimmune hepatitis, *Nat. Rev. Dis. Primers.* 4 (1) (2018) 18017, <https://doi.org/10.1038/nrdp.2018.17>, 2018/04/12.
- [8] M. Ghielmetti, H.D. Schaufelberger, G. Mieli-Vergani, Acute autoimmune-like hepatitis with atypical anti-mitochondrial antibody after mRNA COVID-19 vaccination: a novel clinical entity? *J. Autoimmun.* 123 (2021), 102706 <https://doi.org/10.1016/j.jaut.2021.102706>, 2021/09/01/.
- [9] G. Danan, R. Teschke, RUCAM in drug and herb induced liver injury: the update, *Int. J. Mol. Sci.* 17 (1) (2015) 14, <https://doi.org/10.3390/ijms17010014>.
- [10] R.A. Agha, T. Franchi, C. Sohrabi, G. Mathew, A. Kerwan, The SCARE 2020 guideline: updating consensus surgical CAse REport (SCARE) guidelines, *Int. J. Surg.* 84 (Dec 2020) 226–230, <https://doi.org/10.1016/j.ijsu.2020.10.034>.
- [11] M-C Londoño J Gratacós-Ginès J. Sáez-Peñataro Another case of autoimmune hepatitis after SARS-CoV-2 vaccination – still casualty? *J. Hepatol.* doi: 10.1016/j.jhep.2021.06.004.
- [12] F. Bril, S. Al Duffalha, M. Dean, D.M. Fetting, Autoimmune hepatitis developing after coronavirus disease 2019 (COVID-19) vaccine: causality or casualty? *J. Hepatol.* 75 (1) (2021) 222–224, <https://doi.org/10.1016/j.jhep.2021.04.003>.
- [13] D. Clayton-Chubb, D. Schneider, E. Freeman, W. Kemp, S.K. Roberts, Autoimmune hepatitis developing after the ChAdOx1 nCoV-19 (Oxford-AstraZeneca) vaccine, *J. Hepatol.* (2021), <https://doi.org/10.1016/j.jhep.2021.06.014>, 2021/06/22/.
- [14] É. Vuille-Lessard, M. Montani, J. Bosch, N. Semmo, Autoimmune hepatitis triggered by SARS-CoV-2 vaccination, *J. Autoimmun.* 123 (Sep 2021), 102710, <https://doi.org/10.1016/j.jaut.2021.102710>.
- [15] C.K. Tan, Y.J. Wong, L.M. Wang, T.L. Ang, R. Kumar, Autoimmune hepatitis following COVID-19 vaccination: true causality or mere association? *J. Hepatol.* (2021) <https://doi.org/10.1016/j.jhep.2021.06.009>. S0168-8278(21)00424-4.
- [16] M. Rela, D. Jothimani, M. Vij, A. Rajakumar, A. Rammohan, Auto-immune hepatitis following COVID vaccination, *J. Autoimmun.* 123 (2021), 102688, <https://doi.org/10.1016/j.jaut.2021.102688>, 2021/09/01/.
- [17] C. Kiat, J. Rigby, Ó. Crosbie, C. McShane, The mRNA COVID-19 vaccine - a rare trigger of autoimmune hepatitis? *J. Hepatol.* (2021) <https://doi.org/10.1016/j.jhep.2021.06.044>. S0168-8278(21)01896-1.