

# Outcomes following open reduction for late-presenting developmental dysplasia of the hip

P. Castañeda<sup>1</sup>  
K. Z. Masrouha<sup>2</sup>  
C. Vidal Ruiz<sup>1</sup>  
L. Moscona-Mishy<sup>1</sup>

## Abstract

**Purpose** Patients with late-presenting developmental dysplasia of the hip (DDH) are more likely to require an open reduction. Since many developing countries do not have mandated screening, there continues to be a relatively high incidence of late-presenting DDH. We report the clinical and radiographic outcomes of open reduction in a series of patients who presented late.

**Patients and methods** This was a retrospective review of 712 hips in 645 patients that underwent open reduction, alone or in combination with a pelvic osteotomy. In all, 91 hips had open reduction alone and 621 had open reduction and pelvic osteotomy. Femoral shortening was performed in 221 hips. The mean age at the time of surgery was 2.1 years (1 to 6.5) and the mean follow-up time was 9.3 years (6 to 14). We used the Children's Hospital Oakland Hip Evaluation Score (CHOHES) to determine functional outcomes and the Severin classification was used to evaluate radiographic outcomes. The rate of avascular necrosis (AVN) and the need for a reoperation were also recorded and analyzed.

**Results** In all 80% (570 hips) had good radiographic outcomes (Severin type I or II) and 87% had a CHOHES score of > 90 at final follow up. There was a 14% rate of AVN and only a 2% rate of redislocation. Better radiographic outcomes and lower reoperation rates were seen with patients who underwent both an open reduction and pelvic osteotomy. A trend was observed towards worse outcomes in older patients.

**Conclusions** There was a high rate of good clinical and radiographic outcomes at a minimum six-year follow-up in

patients with late-presenting DDH who underwent open reduction. Those who underwent open reduction in combination with a pelvic osteotomy had a higher rate of good radiographic outcomes and a lower rate of complications, particularly reoperation.

Cite this article: Castañeda P, Masrouha KZ, Vidal Ruiz C, Moscona-Mishy L. Outcomes following open reduction for late-presenting developmental dysplasia of the hip. *J Child Orthop* 2018;12:323-330. DOI: 10.1302/1863-2548.12.170078

**Keywords:** developmental dysplasia of the hip, open reduction, late presentation, outcomes

## Introduction

Early detection of developmental dysplasia of the hip (DDH) reduces the need for invasive surgical procedures.<sup>1,2</sup> This is due to the remarkable remodeling potential of the acetabulum in the first year of life as shown by the high rate of success with treatment in the Pavlik harness.<sup>3,4</sup> The increased success rate and decreased complication rate of early treatment options has led some countries to adopt early screening methods for detecting DDH.<sup>5</sup> There remains significant debate as to whether or not universal screening is effective; however, there is some data to suggest that indications for open reduction are due to a failure of screening rather than failure of initial treatment.<sup>6,7</sup>

Patients who undergo open reduction typically present later than those who successfully undergo splinting or closed reduction. There is no clear cutoff as to what constitutes a 'late-presenting' patient with DDH. A recent study from Australia considered any DDH discovered after three months of age a 'late diagnosis'.<sup>8</sup> However, data suggests that normalization of the acetabulum slows significantly when treatment with closed reduction is performed after age 12 to 14 months, although some studies have reported continued normalization of the acetabular index until eight years of age as long as the hip remained concentrically reduced.<sup>8-11</sup> Price et al<sup>7</sup> found that children presenting after ten months of age had a 12-fold increased chance of requiring an open reduction as compared to those diagnosed before six weeks of age.

In developing countries, where there are no mandated screening protocols, the incidence of late presentation, and thus the need for operative treatment, of patients with DDH is significantly higher. The objective of this

<sup>1</sup> Shriners Hospital for Children, Mexico City, Mexico

<sup>2</sup> Division of Pediatric Orthopedic Surgery, Department of Orthopedic Surgery, New York University Langone Orthopedic Hospital and Hassenfeld Children's Hospital, New York, New York, USA

Correspondence should be sent to P. Castañeda, Division of Pediatric Orthopedic Surgery, Department of Orthopedic Surgery, New York University Langone Orthopedic Hospital, 301 E 17th Street, New York, New York 10003, United States.  
E-mail: pablo.castaneda@nyumc.org

paper is to present the clinical and radiographic outcomes of a large series of such patients who underwent an open reduction and had a minimum follow-up of six years.

## Patients and methods

We retrospectively reviewed 712 hips in 645 patients, which comprise a single surgeon series. Patients who underwent open reduction at the Shriners Hospital for Children, Mexico City, Mexico, between 2000 and 2010 were included. A total of 561 patients were girls (87%) and 84 were boys; 444 patients were affected on one side only with 355 left, 89 right and 134 cases being bilateral. Over 50% of the patients presenting to the institution in the time of this cohort were treated were beyond walking age upon presentation, this series comprises only the cohort undergoing open reduction. All the hips were dislocated as determined by both the Tönnis<sup>12</sup> and International Hip Dysplasia Institute (IHDI) classifications,<sup>13</sup> with 360 being Tönnis and IHDI grade III and 352 being grade IV.

There were 91 hips that underwent an open reduction alone, while 621 hips underwent an open reduction in addition to a pelvic osteotomy. The mean age at the time of surgery was 2.1 years (1.0 to 6.5). There were 96 hips between the ages of 12 and 18 months, 418 between the ages of 18 months and three years, 157 between the ages of three and five years and 41 patients between five and six years of age at the time of treatment.

All the patients were followed up for a mean period of 9.3 years (6 to 14) and were independently evaluated by both an orthopaedic surgery fellow and a resident who documented the clinical findings. The radiographs were evaluated by two paediatric orthopaedic surgery fellows and one resident, using consensus to determine classifications.

## Surgical technique

All patients underwent an anterior open reduction of the hip, after performing a release of the adductor longus and adductor brevis through a 1-cm incision in the inguinal crease, and taking care to protect the obturator nerve, a modified Smith-Peterson approach was used through a 5-cm incision in line with the bikini crease. The approach was divided into three parts: first the iliac apophysis was split and a sponge was placed in the external iliac wing, second, the interval between the rectus femoris and tensor fascia lata was developed while protecting the lateral femoral cutaneous nerve, these two parts of the approach were then joined by sharply dividing up to the ilium. By retracting the rectus medially and the abductors laterally the hip capsule was exposed and cleaned and a T-shaped capsulotomy was performed with the horizontal part being in line

with the true acetabulum and the vertical part being perpendicular to the first. By placing tag sutures the joint was exposed and by externally rotating the hip the ligamentum teres was visualized and released from its insertion on the femoral head and then traced down to its origin in the acetabulum. The psoas tendon was also released from its insertion in the lesser trochanter. A right-angle clamp was then placed with the elbow of the clamp on the transverse acetabular ligament, allowing full exposure of the acetabulum and safe removal of the pulvinar and releasing the transverse acetabular ligament. Care was taken to protect the labrum and secondary ossification center of the acetabular rim. The hip was then reduced; the tension required to achieve reduction was variable. A useful rule was employed: it should take no more pressure than can be applied with two fingers, the quality of the reduction was determined by the contact between the hyaline cartilage of the femoral head and the acetabulum. If there was excessive pressure all of the structures released were revised and in case the pressure was still deemed to be excessive (as determined by the surgeon) then a femoral shortening procedure was performed. Femoral shortening had to be performed in 212 hips, all in patients who were older than four years at the time of surgery. We did not record the amount of shortening, this was calculated by performing an osteotomy, reducing the head into the acetabulum and shortening by the amount of overlap; varus was never intentionally produced. Derotation was achieved by externally rotating the distal femoral fragment until the patella was centred in the coronal plane. The capsule was then closed by removing the redundant superolateral portion and suturing the inferolateral portion to the medial portion and then supplementing by performing a capsulorrhaphy with a running absorbable suture. In the cases where a pelvic osteotomy was performed, attention was then returned to the pelvis where the medial iliac wing was exposed subperiosteally in the same way the lateral one had been in the beginning of the case. A Gigli saw was passed through the sciatic notch using retractors to protect the neurovascular bundle, completing the cut between the anterosuperior and inferior iliac spines. Displacement was then produced in a distal and lateral direction, and by placing a triangular wedge, taken from the iliac wing, which was fixed with two smooth 1.5 mm Kirschner-wires. Closure is achieved by repairing the iliac apophysis, since the direct head of the rectus was not released and the sartorius and rectus remained on the medial aspect of the iliac apophysis. The femorocutaneous nerve was protected when closing and all of the patients were then placed in a one-leg spica cast for six weeks. After which a gradual range of movement is recovered without any specific physical therapy being prescribed. In this series, we used a transarticular pin to stabilize the joint in 114 hips. This was performed at the discretion of the surgeon when the

hip was considered to be very unstable despite a quality open reduction, capsulorrhaphy and the osteotomy. When it was used it was a smooth 2.0-mm Kirschner-wire which was placed percutaneously, through the greater trochanter, along the inferior third of the neck and into the non-weight-bearing area of the inferomedial aspect of the acetabulum. The position was verified with fluoroscopic imaging with aftercare included placing a hip spica cast. The pin was then removed three weeks after the procedure without removing the cast and the cast was maintained for a total of six weeks.

Demographic data was collected including gender, laterality and treatment. Treatment data included age at the time of surgery, surgery performed, duration of follow-up, rate of complications (avascular necrosis (AVN), redislocation and reoperation). Clinical outcomes were determined by using the Children's Hospital of Oakland Hip Evaluation Score (CHOHES) which is an instrument that has been previously validated in a cohort of patients of a slightly older age.<sup>14</sup>

The CHOHES is a modification of the Harris Hip Score designed to be applicable in children. It consists of three domains: pain, function and physical exam. Pain can only be measured in increments of ten, rating of pain over the past four weeks for each hip as 'none' (40 points), 'mild' (30 points), 'moderate' (20 points), 'severe' (10 points) or 'incapacitating' (0 points). Function is determined by ambulatory status and ability to perform daily activities; and physical exam is determined by range of movement and strength testing. The sum of these gives a global score which has a maximum of 100.

The Severin classification was used to evaluate radiographic outcomes.<sup>15</sup> It considers the shape of the femoral head and its relationship with the acetabulum in addition to the centre edge angle. For simplicity, Severin grades I and II were grouped together and defined as a good radiographic outcome, grades III and IV were defined as a residual subluxation and grades V and VI were defined as a redislocation.

AVN is defined as the cellular death of bone components due to interruption of the blood supply, and although the definition, pathogenesis and cause are all debatable, we employ the term since it is so widespread within the literature relating to DDH. We do not actually believe all cases to be caused by vascular insult, rather by pressure placed on the femoral head and since no specimens have been retrieved for microscopic evaluation the term is used when changes in the proximal femoral epiphysis are observed on radiographs, perhaps the term 'proximal femoral growth disturbance' as described by previous authors<sup>16,17</sup> would be more appropriate, however, it is not widely used and thus, we used the Salter criteria for AVN<sup>18</sup> considering it to be present when any asymmetric radiolucency was observed in the proximal femoral epiphysis

or asymmetric broadening of the proximal metaphysis on two serial radiographs of the hip. The Salter-Thompson classification<sup>19</sup> was then used to determine the extent of involvement considering any radiolucency or fragmentation of the proximal epiphysis to represent AVN and subjectively determining what the percentage of involvement of the epiphysis was, with < 50% being considered type A and > 50% being considered type B.

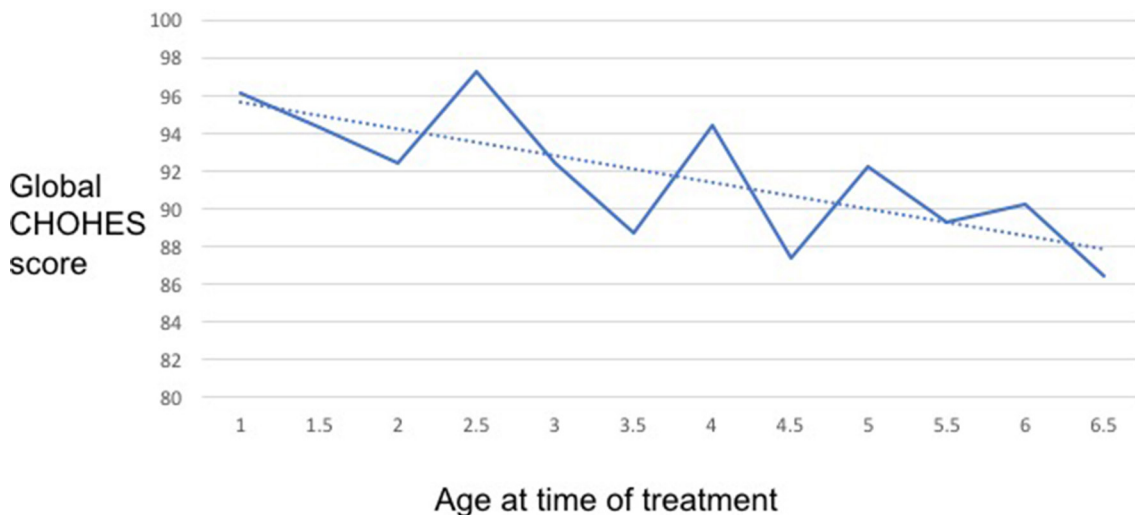
## Statistical analysis

An independent Student's *t*-test was applied to compare independent continuous variables, analysis of variance was used to test the difference between group means after any other variance in the outcome variables were accounted for. Pearson correlation was used to test for the strength of the association between two continuous variables, Spearman when they were ordinal variables and the distribution was not considered normal and the chi-squared test when examining categorical variables. Statistical significance was determined when the value of *p* was equal or less than the standardized 0.05. All data was analyzed utilizing SAS software, SAS® University Edition (SAS Institute, Cary, North Carolina).

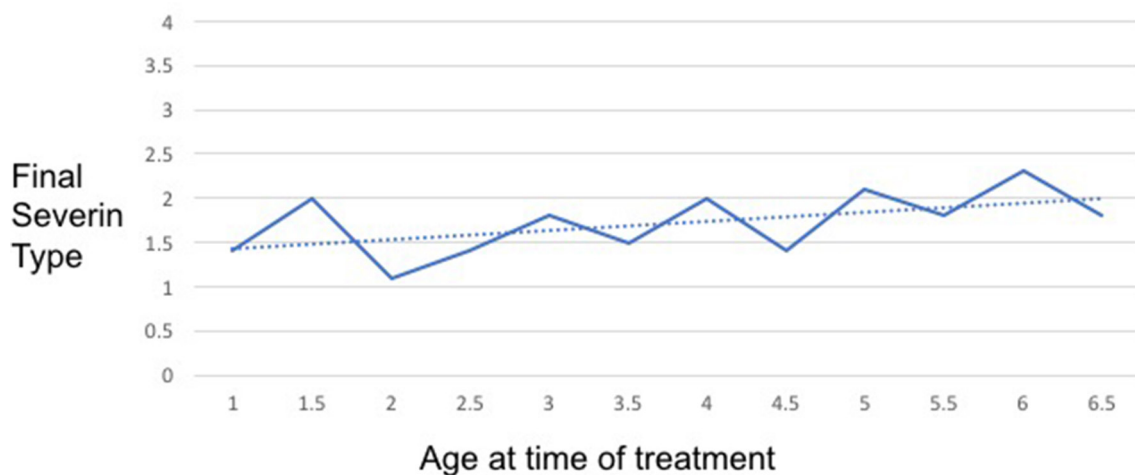
## Results

The mean global CHOHES score was 94.3 (48 to 100), with 87% of patients having a score > 90. When stratified by age, there was a trend toward lower scores with increasing age, however, mean global scores remained over 85 in all age groups (Fig. 1). We could not demonstrate a statistically significant correlation between age and clinical outcome with the Pearson or Spearman correlation, however, when age was considered as a categorical value being younger or older than four years at the time of surgery, there was a significant difference with the mean CHOHES score being 95.7 (84 to 100) for patients younger than four years at the time of surgery (*n* = 556) and 92.5 (82 to 100) for patients older than four years at the time of surgery (*n* = 89), *p* = 0.05.

The mean pain score for the entire cohort was 36.9 (range 10 to 40), with 546 patients reporting no pain whatsoever. Of the 32 patients who did have pain, the mean pain score was 25.9 (range 10 to 30). The mean functional score for the entire cohort was 31.4 (range 10 to 40), the maximum score obtainable is 32, showing an excellent function according to this scale, however, we believe this also highlights the fact that at this short-term evaluation the function can be expected to be good regardless of radiographic outcome. The mean physical exam score was 22.3 (10 to 28); the maximum score obtainable is 28 (Table 1).



**Fig. 1** Clinical outcome as determined by Children’s Hospital Oakland Hip Evaluation Score (CHOHES) versus age at the time of treatment.



**Fig. 2** Radiographic outcomes as determined by Severin classification versus age at the time of treatment.

**Table 1** Clinical outcome as determined by Children’s Hospital Oakland Hip Evaluation Score

Domain	Mean	Range
Pain	36.9	10 to 40
Function	31.4	26 to 32
Physical exam	22.3	12 to 28
Global score	94.3	48 to 100

**Table 2** Radiographic outcomes as determined by Severin classification

Severin type	n (%)
I or II (adequate acetabular development)	570 (80)
III or IVa (inadequate acetabular development)	128 (18)
IVb, V and VI	14 (2)

At final follow up, 570 hips (80%) had a good radiographic outcome, that is: Severin grade I or II, 128 hips (18%) were considered residual dysplasia or subluxation, that is: Severin type III and IVa and only 14 hips (2%) presented redislocation, that is: Severin IVb, V and VI (Table 2). The mean age for the group resulting as Severin type I or II was 2.4 years (1 to 6.4) compared with the mean age for all others which was 4.3 years (1.5 to 6.5), with this difference being statistically significant ( $p = 0.004$ ). There was

also a trend towards a worse radiographic outcome with increasing age at the time of surgery (Fig. 2), although Pearson and Spearman correlations did not prove statistical significance.

Again, when dividing patients into two categories (those less than four years of age and those older than four years of age at the time of treatment) there was a significant difference, with 478 of the 556 (86%) hips in patients younger than four at the time of surgery ending with a

Severin type I or II, 69 hips resulting in a Severin type III or IVa (12.4%) and nine patients presenting redislocation (1.6%). Of the 156 hips in patients older than four years of age at the time of treatment, 65 hips could be graded as Severin type I or II hips (41.6%), 79 hips as Severin type III and IVa hips (50.6%) and 12 presented a redislocation (7.8%). Using the chi-squared test a statistically significant difference was proven between patients younger and older than four years at the time of treatment, resulting in a Severin type I or II hip,  $p = 0.03$ .

This difference was even greater when dividing patients into those under the age of three years and those older than three years at the time of treatment. When comparing the 418 hips in patients between the ages of 18 months and three years to the 198 patients who were between the ages of three and six years when undergoing treatment, the results were striking. Of the patients

younger than three years (418 hips), 302 could be graded as a Severin type I hip (72.2%) and 81 as a Severin type II hip (19.4%), meaning that 383 of the 418 were Severin I or II hips (91.6%). For the group between the ages of three and six years (256 hips), only 67 could be graded as Severin type I hips (26.3%) and 94 as Severin type II hips (36.9%), meaning that only 63.2% hips of this cohort were Severin Type I or II and 95 hips (36.8%) Severin III or IV. This difference was found to be statistically significant ( $p = 0.003$ ). (Figs. 3-6)

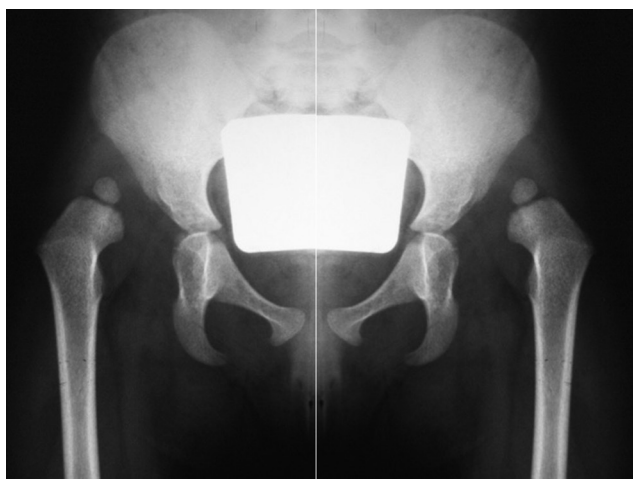The rate of AVN was 14%, or 100 of the overall cohort of 712 hips. The rate of AVN was different between hips originally classified as Tönnis/IHDI type III and IV, with 63 of the 352 type IV hips developing AVN, (rate = 18%), whereas only 37 of the 360 type III hips developed AVN (rate = 10.3%) this difference was found to be statistically significant ( $p = 0.004$ ) (Table 3).

The mean age of the patients who developed AVN was 3.1 years (1.2 to 6.5) compared with the mean age of the patients who did not develop AVN which was 3.3 years (1 to 6.4), however, this difference was not found to be statistically significant ( $p = 0.06$ ).

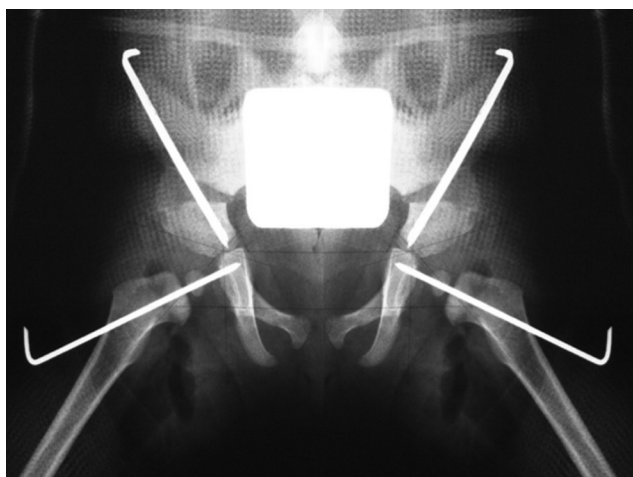
According to the Salter-Thompson Classification 69 hips were type A (< 50% involvement) and 31 hips were type B (> 50% involvement). None of the statistical tests for correlation showed an association with age or preoperative Tönnis/IHDI grade.

Thus, the rate of AVN was found to be directly related to the Tönnis/IHDI grade of dislocation but not to age at the time of surgery, however, the severity of the involvement was not found to be related to either independent variable.

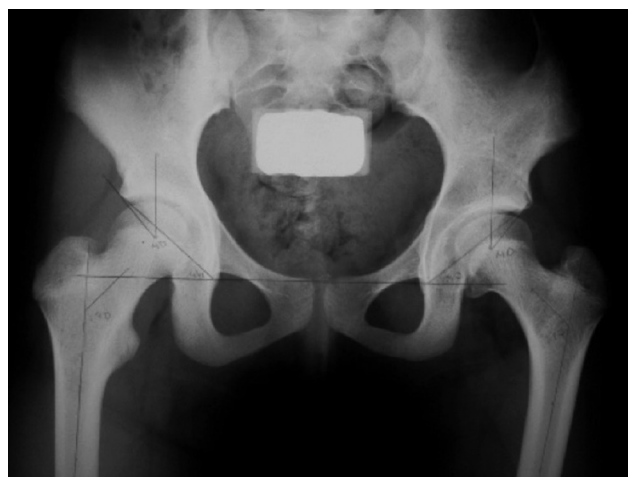There were significant differences in outcomes for the group undergoing isolated open reduction compared with the group undergoing concomitant open reduction



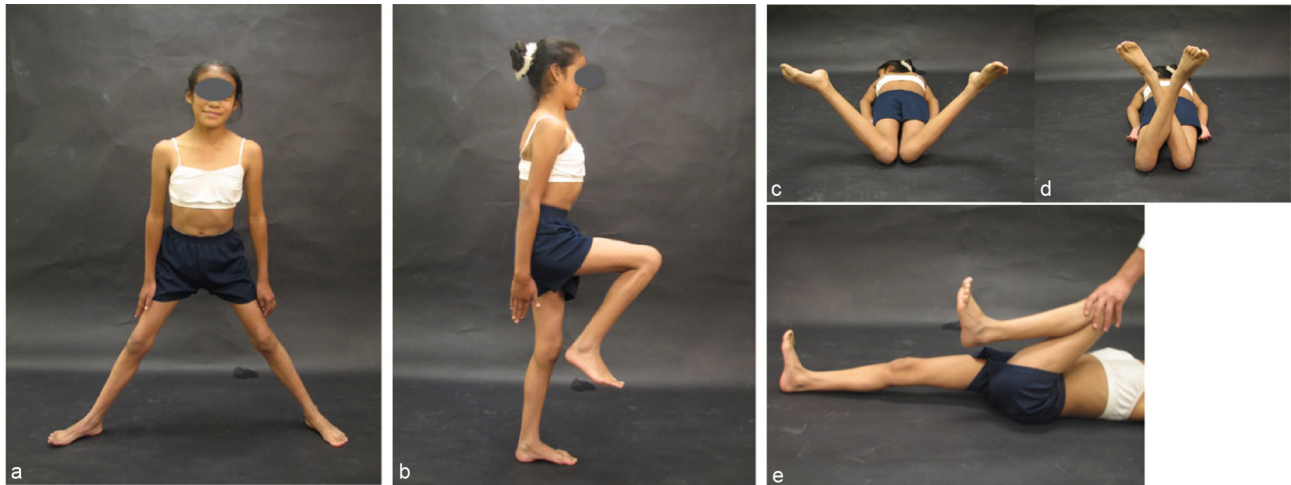**Fig. 3** Case example of a bilateral Tönnis/International Hip Dysplasia Institute (IHDI) Grade IV dislocation treated at the age of 2.1 years.



**Fig. 4** Immediate postoperative radiograph after staged procedures (two weeks apart), open reduction, pelvic osteotomy and temporary stabilization with a transarticular pin.



**Fig. 5** Final radiographic follow-up at age 12.2 (ten-year follow-up), shows bilateral spherically congruent hips with adequate acetabular development.



**Fig. 6 a-d** Clinical follow-up at age 12.2 (ten-year follow-up), the patient had excellent range of movement and no noticeable limp.

**Table 3** Complications

Complication	n (%)
Avascular necrosis	100 (14)
Redislocation	16 (2)

**Table 4** Rate of complications by treatment type

Treatment	Avascular necrosis, n (%)	Reoperation, n (%)
Open reduction (n = 91)	15 (16)	27 (30)
Open reduction and pelvic osteotomy (n = 621)	84 (14)	93 (15)

and pelvic osteotomy. At final follow-up, 55 of the 91 hips (60%) that underwent open reduction alone had a Severin grade of I or II with adequate acetabular development. Of the 621 hips that underwent open reduction and pelvic osteotomy, 515 (82.9%) could be graded as Severin type I or II hips or had adequate acetabular development. This difference was found to be statistically significant ( $p = 0.005$ ).

The rate of AVN for the group undergoing an isolated open reduction was 16.4% (15 of 91 hips), and it was 13.5% for the group undergoing open reduction and pelvic osteotomy (84 of 621 hips),  $p = 0.06$ . The rate of redislocation for the group undergoing an isolated open reduction was 5.5% (five of 91 hips) and it was 1.9% for the group undergoing open reduction and pelvic osteotomy (12 of 621 hips),  $p = 0.003$ .

The rate of reoperation for either redislocation or residual dysplasia was 29.7% for the group undergoing an isolated primary open reduction (27 of 91 hips), compared with 15% for the group undergoing open reduction and concomitant pelvic osteotomy (93 of 621 hips),  $p = 0.004$  (Table 4).

Of the patients that redislocated ( $n = 17$ ) only 11 had undergone revision open reduction with the other six patients either deciding not to undergo revision or still awaiting surgery. Thus, 103 of the reoperations were pelvic osteotomies to correct acetabular dysplasia and all of these were performed at a minimum of 12 months after the index procedure, with an acetabular index  $> 30^\circ$  was considered as an absolute indication. Of these 103 delayed pelvic osteotomies, 23 had been in the primary isolated open reduction group and 80 in the open reduction and pelvic osteotomy group. We attempted to determine radiographic variables associated with poor subsequent acetabular development and found a weak association between the change in acetabular index in the first year after the open reduction, however, variability in radiographic measurements and a lack of standardization of the radiographs precluded formal analysis.

## Discussion

With greater delay in the diagnosis of DDH, the likelihood of requiring an open reduction significantly increases.<sup>7</sup> Data suggest that good outcomes can be expected with a single stage procedure including open reduction, with or without femoral shortening and pelvic osteotomy.<sup>20-23</sup> The results of the present study show that 87% of patients will have an excellent clinical outcome and 80% will have a good to excellent radiographic outcome at a minimum six-year follow-up. These results are comparable with or slightly better than those found in the literature.

The oldest patient treated surgically in our cohort was 6.5 years of age. Studies have reported that patients above the age of seven years at the time of surgery had poorer outcomes.<sup>21,23</sup> The general trend in the literature is that

younger patients have better outcomes after open reduction for DDH.<sup>21,23-25</sup> However, the optimal age is unknown, as one study found that those operated on between 2.5 and eight years of age had better outcomes than those who had their surgery earlier.<sup>22</sup> The relatively young mean age at the time of surgery in our patient population may partially explain the high rate of good to excellent outcomes.

Redislocation is a commonly reported complication following the treatment of DDH. The incidence following open reduction is up to 8%, however, the rate is lower following open reduction combined with a pelvic osteotomy.<sup>22,26,27</sup> In the present cohort, the redislocation rate was 2%, however, the rate was 5.5% in the patients who underwent open reduction alone. The addition of a pelvic osteotomy in our cohort was based on the discretion of the senior surgeon, this was done routinely in patients over 18 months and only once in a patient younger than 18 months (16 months at the time of surgery). The improved outcomes in this group of patients as compared with those who underwent an open reduction alone may be due to the increased stability and maintenance of a concentrically reduced hip following a pelvic osteotomy during a time in which acetabular remodeling has slowed.<sup>11</sup>

Similarly, the rate of reoperation was higher in the group of patients that underwent open reduction alone. Studies have found that residual bony abnormalities may be responsible for the increased redislocation and reoperation rates in these patients.<sup>28,29</sup> The abnormal morphology commonly seen in these patients is an increase in combined anteversion of the femur and acetabulum.<sup>28</sup> Other risk factors for failure of open reduction include increased pelvic width and decreased hip abduction in the spica cast, however, these parameters were not explored in our patient cohort.<sup>28,30</sup>

This study is not without limitations. The authors acknowledge the limitations inherent in all retrospective reviews. There were no preoperative clinical scores obtained to compare with postoperative outcomes. Not all morphological parameters were obtained on the patients which would have enabled us to investigate potential causes for redislocation. Patients were treated with either open reduction alone or open reduction with a pelvic osteotomy rather than one single procedure, however, the numbers were sufficient to group patient outcomes. We believe the biggest inherent flaw to be a lack of follow-up; a longer follow-up may be needed to understand long-term outcomes in this patient population. To overcome this, we are relying on using the Severin classification as a proxy for ultimate outcome.

In conclusion, we reported on the outcomes of a large group of patients who underwent a single-stage surgical procedure for the treatment of late-presenting DDH. We found that this cohort of patients had a very high

rate of excellent clinical outcomes at a minimum six-year follow-up, with better outcomes in younger patients. In addition, we found that those who underwent open reduction in combination with a pelvic osteotomy had a higher rate of good radiographic outcomes and a lower rate of complications, particularly reoperation.

Received 17 May 2018; accepted 20 June 2018.

## COMPLIANCE WITH ETHICAL STANDARDS

### FUNDING STATEMENT

No benefits in any form have been received or will be received from a commercial party related directly or indirectly to the subject of this article.

### OA LICENCE TEXT

This article is distributed under the terms of the Creative Commons Attribution-Non Commercial 4.0 International (CC BY-NC 4.0) licence (<https://creativecommons.org/licenses/by-nc/4.0/>) which permits non-commercial use, reproduction and distribution of the work without further permission provided the original work is attributed.

### ETHICAL STATEMENT

**Ethical approval:** This research involves human participants but only as a retrospective review having undergone the standard of care for the condition. IRB approval was waived due to the retrospective nature of this work.

**Informed consent:** Informed consent for the collection of data was obtained in all cases.

### ICMJE CONFLICT OF INTEREST STATEMENT

None declared.

### REFERENCES

- Vane AG, Gwynne Jones DP, Dunbar JD, Theis JC.** The diagnosis and management of neonatal hip instability: results of a clinical and targeted ultrasound screening program. *J Pediatr Orthop* 2005;25:292–295.
- Paton RW, Hossain S, Eccles K.** Eight-year prospective targeted ultrasound screening program for instability and at-risk hip joints in developmental dysplasia of the hip. *J Pediatr Orthop* 2002;22:338–341.
- Pavlik A.** The functional method of treatment using a harness with stirrups as the primary method of conservative therapy for infants with congenital dislocation of the hip. 1957. *Clin Orthop Relat Res* 1992;281:4–10.
- Cashman JP, Round J, Taylor G, Clarke NM.** The natural history of developmental dysplasia of the hip after early supervised treatment in the Pavlik harness. A prospective, longitudinal follow-up. *J Bone Joint Surg [Br]* 2002;84-B:418–425.
- No authors listed.** Newborn and infant physical examination (NIPE) screening programme. [https://www.gov.uk/government/collections/newborn-and-infant-physical-examination-clinical-guidance\\_\(date last accessed 25 June 2018\)](https://www.gov.uk/government/collections/newborn-and-infant-physical-examination-clinical-guidance_(date%20last%20accessed%2025%20June%202018).).
- Sanghrajka AP, Murnaghan CF, Shekkeris A, Eastwood DM.** Open reduction for developmental dysplasia of the hip: failures of screening or failures of treatment? *Ann R Coll Surg Engl* 2013;95:113–117.
- Price KR, Dove R, Hunter JB.** Current screening recommendations for developmental dysplasia of the hip may lead to an increase in open reduction. *Bone Joint J* 2013;95-B:846–850.

8. **Studer K, Williams N, Antoniou G, et al.** Increase in late diagnosed developmental dysplasia of the hip in South Australia: risk factors, proposed solutions. *Med J Aust* 2016;204:240.
9. **Lindstrom JR, Ponseti IV, Wenger DR.** Acetabular development after reduction in congenital dislocation of the hip. *J Bone Joint Surg [Am]* 1979;61-A:112–118.
10. **Almby B, Grevsten S, Lönnerholm T.** Hip joint instability after the neonatal period. II. The acetabular growth potential. *Acta Radiol Diagn (Stockh)* 1979;20:213–222.
11. **Danielsson L.** Late-diagnosed DDH: a prospective 11-year follow-up of 71 consecutive patients (75 hips). *Acta Orthop Scand* 2000;71:232–242.
12. **Tönnis D.** *Congenital dysplasia and dislocation of the hip in children and adults.* Berlin, Germany: Springer-Verlag, 1987.
13. **Narayanan U, Mulpuri K, Sankar WN, et al.** Reliability of a new radiographic classification for developmental dysplasia of the hip. *J Pediatr Orthop* 2015;35:478–484.
14. **Aguilar CM, Neumayr LD, Eggleston BE, et al.** Clinical evaluation of avascular necrosis in patients with sickle cell disease: Children's Hospital Oakland Hip Evaluation Scale—a modification of the Harris Hip Score. *Arch Phys Med Rehabil* 2005;86:1369–1375.
15. **Severin E.** Contribution to the knowledge of congenital dislocation of the hip joint. *Acta Chir Scand* 1941;Suppl 63:1–142.
16. **O'Brien T, Millis MB, Griffin PP.** The early identification and classification of growth disturbances of the proximal end of the femur. *J Bone Joint Surg [Am]* 1986;68-A:970–980.
17. **Keret D, MacEwen GD.** Growth disturbance of the proximal part of the femur after treatment for congenital dislocation of the hip. *J Bone Joint Surg [Am]* 1991;73-A:410–423.
18. **Salter RB, Kostuik J, Dallas S.** Avascular necrosis of the femoral head as a complication of treatment for congenital dislocation of the hip in young children: a clinical and experimental investigation. *Can J Surg* 1969;12:44–61.
19. **Salter RB, Thompson GH.** Legg-Calve-Perthes disease. The prognostic significance of the subchondral fracture and a two-group classification of the femoral head involvement. *J Bone Joint Surg [Am]* 1984;66-A:479–489.
20. **Haidar RK, Jones RS, Vergroesen DA, Evans GA.** Simultaneous open reduction and Salter innominate osteotomy for developmental dysplasia of the hip. *J Bone Joint Surg [Br]* 1996;78-B:471–476.
21. **Forlin E, Munhoz da Cunha LA, Figueiredo DC.** Treatment of developmental dysplasia of the hip after walking age with open reduction, femoral shortening, and acetabular osteotomy. *Orthop Clin North Am* 2006;37:149–160. vi.
22. **Ning B, Yuan Y, Yao J, Zhang S, Sun J.** Analyses of outcomes of one-stage operation for treatment of late-diagnosed developmental dislocation of the hip: 864 hips followed for 3.2 to 8.9 years. *BMC Musculoskelet Disord* 2014;15:401.
23. **Dogan M, Bozkurt M, Sesen H, Yildirim H.** One-stage treatment of congenital severely dislocated hips in older children through various acetabuloplasty techniques: 22 children followed for 1–5 years. *Acta Orthop* 2005;76:212–219.
24. **Umer M, Nawaz H, Kasi PM, Ahmed M, Ali SS.** Outcome of triple procedure in older children with developmental dysplasia of hip (DDH). *J Pak Med Assoc* 2007;57:591–595.
25. **Ganger R, Radler C, Petje G, et al.** Treatment options for developmental dislocation of the hip after walking age. *J Pediatr Orthop B* 2005;14:139–150.
26. **Kershaw CJ, Ware HE, Pattinson R, Fixsen JA.** Revision of failed open reduction of congenital dislocation of the hip. *J Bone Joint Surg [Br]* 1993;75-B:744–749.
27. **Kamath SU, Bennet GC.** Re-dislocation following open reduction for developmental dysplasia of the hip. *Int Orthop* 2005;29:191–194.
28. **Tuhanoğlu Ü, Cicek H, Ogur HU, Seyfettinoglu F, Kapukaya A.** Evaluation of late redislocation in patients who underwent open reduction and pelvic osteotomy as treatment for developmental dysplasia of the hip. *Hip Int* 2017 October 16. (Epub ahead of print)
29. **Sankar WN, Neuburger CO, Moseley CF.** Femoral anteversion in developmental dysplasia of the hip. *J Pediatr Orthop* 2009;29:885–888.
30. **Sankar WN, Young CR, Lin AG, et al.** Risk factors for failure after open reduction for DDH: a matched cohort analysis. *J Pediatr Orthop* 2011;31:232–239.