

Case Report

# Ophthalmomyiasis externa: A case report from Alkharj, Saudi Arabia



Kanika Sharma

## Abstract

Ophthalmomyiasis is an infestation of mammalian eyes with larvae or maggots of certain flies. *Oestrus ovis* is the most common cause of human myiasis. This article reports a case of ophthalmomyiasis externa caused by *Oestrus ovis* (sheep nasal botfly) in a young healthy male, living in Al Kharj, Kingdom of Saudi Arabia. Patient presented with acute symptoms in left eye in April, mimicking as unilateral conjunctivitis/keratitis/external ocular foreign body/uveitis. Prompt diagnosis and mechanical removal of five live larvae from conjunctival fornices of the left eye under topical anaesthesia and cyclopentolate 1% eyedrops, not only relieved patient's severe symptoms in a single day but also prevented rare yet sight threatening complications.

**Keywords:** Ophthalmomyiasis, *O. ovis*, Sheep nasal botfly, KSA, Acute unilateral conjunctivitis

© 2017 The Author. Production and hosting by Elsevier B.V. on behalf of Saudi Ophthalmological Society, King Saud University. This is an open access article under the CC BY-NC-ND license (<http://creativecommons.org/licenses/by-nc-nd/4.0/>).  
<https://doi.org/10.1016/j.sjopt.2017.11.005>

## Introduction

*Oestrus ovis* (sheep nasal botfly), belonging to Class 'Insecta', order 'Diptera'; family 'Oestridae'; is the most common cause of human myiasis.<sup>1,2</sup> Although sheep and goats are its preferred hosts, humans handling the sheep and goat farms or living nearby such livestock with large fly population, become accidental hosts in its life cycle.<sup>3,4</sup> Myiasis is the infestation of live mammalian tissue by fly larvae or maggots with most cases of human myiasis being cutaneous infestations. Nose, eye, ear, genitourinary, abdomino-intestinal tracts have been infested less commonly.<sup>5–9</sup> It has been seen in the hospital settings/open wound cases and has been associated with extremes of age, poor hygienic conditions, alcoholics, diabetics, psychiatric patients, HIV cases, chronic malignancies. Ocular involvement is seen in less than 5% cases of myiasis.<sup>10</sup> The condition is more common in summer and spring seasons of tropical countries. Based on site of infestation, ophthalmomyiasis is classified as:

1. External ophthalmomyiasis: larval infestation of lids, lacrimal ducts, conjunctiva. It is often a self-limiting condition, as in humans the larvae cannot survive beyond the first stage and are believed to die within 10 days.<sup>11</sup>
2. Internal ophthalmomyiasis: when larvae penetrates eyeball and are seen in aqueous, iris, vitreous, sub-retinal space.<sup>12</sup> It is rare and can cause sight threatening endophthalmitis and optic atrophy.<sup>13</sup> Larval species identification is important because certain species such as Hypoderma (cattle grub)/reindeer fly/rodent botfly have tendency to penetrate coats of eyeball and orbit, adnexa, optic nerve.<sup>14–18</sup>
3. Orbital ophthalmomyiasis: fly larvae penetrate into orbit and affect ocular adnexa and optic nerve. Severe cases may need exenteration in its management.<sup>18,19</sup>

After extensive search of scientific literature, very few cases were found to be reported from K.S.A and none from this region of K.S.A.<sup>20–22</sup> Thus, the rarity of this condition makes it liable to be missed masquerading as routine cases of conjunctivitis or uveitis.

Received 29 July 2017; received in revised form 7 November 2017; accepted 19 November 2017; available online 24 November 2017.

Dept. of Ophthalmology, College of Medicine, Prince Sattam Bin Abdulaziz University, Alkharj, Saudi Arabia  
e-mail address: [drkanikamei@yahoo.com](mailto:drkanikamei@yahoo.com)



Peer review under responsibility of Saudi Ophthalmological Society, King Saud University



Production and hosting by Elsevier

Access this article online:  
[www.saudiophthaljournal.com](http://www.saudiophthaljournal.com)  
[www.sciencedirect.com](http://www.sciencedirect.com)

## Case report

A 32-year-old healthy male presented to out-patient department of Prince Sattam Bin Abdul Aziz University Hospital, Al- Kharj, KSA in April 2017 with less than a day history of severe redness, profuse watering, inability to open his left eye with foreign body sensation and left running nose after a dust storm a day back which the patient specifically interpreted as the cause of some foreign body falling in the left eye. He already had washed his left eye multiple times with water but symptoms persisted. On examination, unaided visual acuity was found to be 6/6 (Snellens chart) for both eyes. Left eye lids were swollen with reduced vertical palpebral aperture, and the patient had severe photophobia. Ocular motility was normal. Slit lamp examination revealed congested conjunctiva, upper and lower palpebral conjunctiva exhibited papillary hypertrophy in temporal sector. Palpebral conjunctiva revealed presence of five motile translucent white larvae approx. 1.0–1.5 mm long and 0.5 mm wide with dark cephalic ends (Fig. 1). The larvae were actively mobile and exhibited photoaversion with burrowing activity into conjunctiva to escape (Fig. 2). The left eye was topically anaesthetized with Benoxinate 0.4% eyedrops and cyclopentolate 1% eyedrops were instilled after testing pupillary reflexes which were normal. Five larvae were removed with sterile cotton swabsticks. On further examination, cornea, anterior chamber and iris were uninvolved and no abnormality was detected. Posterior segment was thoroughly examined with direct and indirect ophthalmoscopy to rule out any larval migration inside the eye and no abnormality was detected which was confirmed further with a normal B-scan ultrasonography. Right eye examination was normal. Left eye was irrigated with copious amounts of sterile normal saline solution. The diagnosis of "Ophthalmomyiasis Externa OS" was made and larval samples were subjected to microbiological examination for species identification. Patient was put on antibiotic and steroid eyedrops. Patient came for follow up the next day and was completely asymptomatic. Detailed slit lamp and posterior segment examination was repeated and found to be normal in the concerned eye. The microbiology larval report identified the larvae to be of *Oestrus ovis*.

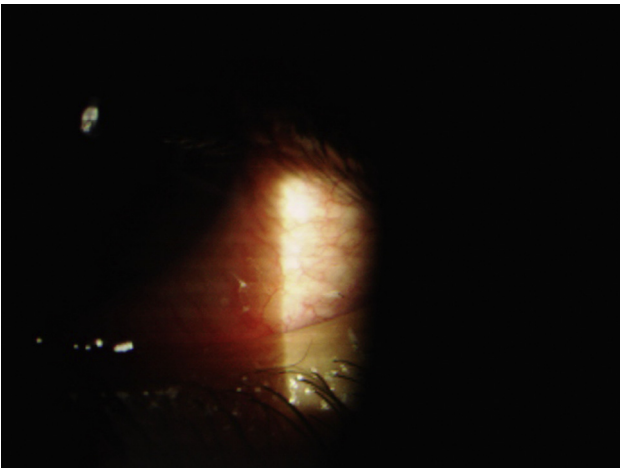


Fig. 1. Two white larvae are seen at temporal bulbar conjunctiva.

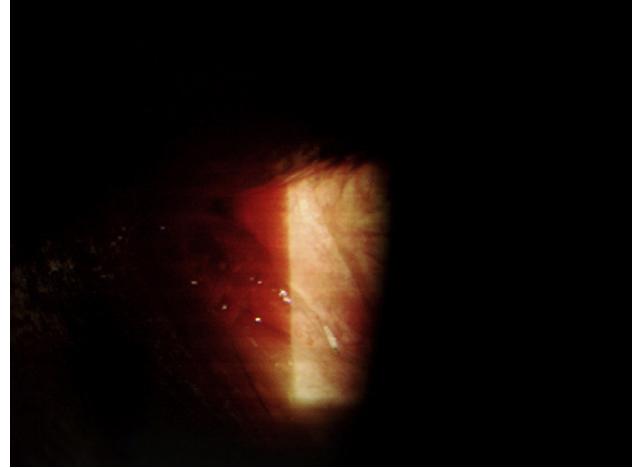


Fig. 2. Single slender white larva with black cephalic ends.

## Discussion

Human ocular myiasis has been reported worldwide. It was first reported by Keyt in 1900 and later by Elliot in 1910 from India.<sup>23</sup> It is caused by three main fly families: Calliphoridae (Blowflies), Oestridae (Botflies) and Sarcophagidae (Fleshflies).

The sheep nasal botfly, *O. ovis* are large dark grey flies with dark spots on the dorsum of thorax and abdomen, covered by light brown hair.<sup>3</sup> The fly deposits hatched larvae within fluid, while on wings and on striking moist surfaces such as nasal mucosa of sheep and cattle and accidentally human eyes. Man serves as an accidental host and hence the ocular myiasis in humans is a rare condition.<sup>3</sup> These larvae can penetrate intact skin and conjunctival mucus membrane. Their infestation occurs through contaminated hands of sheep rearers and handlers from infested sheep or by a fly itself.

Our patient lived near a sheep rearing farm in the summer month (April) of KSA, presented with unilateral acute conjunctivitis and pre septal edema. A review of scientific literature and case series highlighted summer and spring seasons as the seasons of ophthalmomyiasis caused by sheep botfly in the tropical and Mediterranean countries.

This case report again highlights the following features of ophthalmomyiasis:

1. Ophthalmologists should keep external ophthalmomyiasis as differential diagnosis in cases of acute unilateral conjunctivitis and preseptal cellulitis, especially in tropical summers and springs.
2. This disease should be considered as an occupational hazard among sheep, goat and cattle rearers and people living nearby such livestock, with flies and poor hygienic conditions. These people should be taught hygienic practices such as frequent hand washing and methods to control fly population.
3. Due to firm grasping of mucosal tissue by larval hooks, simple saline irrigation of affected eye alone does not help in their removal.

A review of available literature recommends the following methods to treat External ophthalmomyiasis:

1. By far the most common and simple method is mechanical removal of larvae under topical anaesthesia or an anticholinesterase agent or both.
2. Liquid paraffin has been used to cut off the oxygen supply of larvae thus killing it followed by mechanical removal.
3. Topical ivermectin 10 mg/ ml has been used in treating myiasis.<sup>24,25</sup>
4. Topical tobacco extract has been used to treat external ophthalmomyiasis.<sup>26</sup>

Although internal ophthalmomyiasis or orbital myiasis is rare to occur as a sequel to external ophthalmomyiasis, it is prudent to conduct a follow up examination by slit lamp biomicroscopy and dilated posterior segment examination in the following few days.

### Conflict of interest

The authors declared that there is no conflict of interest.

### References

1. Dunbar J, Cooper B, Hodgetts T, Yskandar H, van Thiel P, Whelan S, et al. An outbreak of human external ophthalmomyiasis due to *Oestrus ovis* in Southern Afghanistan. *Clin Infect Dis* 2008;**46**:e124–6.
2. Reingold WJ, Robin JB, Leipa D, Kondra L, Schanzlin DJ, Smith RE. *Oestrus ovis* ophthalmomyiasis externa. *Am J Ophthalmol* 1984;**97**:7.
3. Beaver PC, Jung RC, Cupp EW. *Clinical parasitology*. 9th ed. Philadelphia, USA: Lea & Febiger; 1984. p. 680–95.
4. Hira PR, Hajj B, Al-Ali F, Hall MJ. Ophthalmomyiasis in Kuwait: first report of infections due to the larvae of *Oestrus ovis* before and after the Gulf conflict. *J Trop Med Hyg* 1993;**96**(4):241–4.
5. Mohsen M, Keramatalab H. External ophthalmomyiasis caused by sheep botfly (*Oestrus ovis*) larvae: a report of 8 cases. *Arch Iranian Med* 2004;**7**:136–9.
6. Amr ZS, Amr BA, Abo-Shehada MN. Ophthalmomyiasis externa caused by *Oestrus ovis* L. in the Ajloun area of northern Jordan. *Ann Trop Med Parasitol* 1993;**87**:259–62.
7. Keller AP, Paul Iii AK. Myiasis of the middle ear. *The Laryngoscope* 1970;**80**:646–50.
8. Thompson Jr JH, Knutson LV, Culp OS. Larva of *Scenopinus* sp. (diptera: scenopinidae) causing human urogenital myiasis? *Mayo Clin Proc* 1970;**45**(8):597–601.
9. Zumpt F. *Myiasis in Man and Animals in the old world*. London: Butterworths; 1965.
10. Ziemianski MC, Lee KY, Sabates FN. Ophthalmomyiasis interna. *Arch Ophthalmol* 1980;**98**:1588–9.
11. Lane RP, Crosskey RW. *Medical insects and arachnids*. London: Chapman and Hall; 1993.
12. Hunt Jr EW. Unusual case of ophthalmomyiasis interna posterior. *Am J Ophthalmol* 1970;**70**:978–80.
13. Jakobs EM, Adelberg DA, Lewis JM, Trpis M, Green WR. Ophthalmomyiasis interna posterior. Report of a case with optic atrophy. *Retina* 1997;**17**:310–4.
14. Chiang Homer H et al. A case of ophthalmomyiasis interna in the Pacific Northwest. *Am J Ophthalmol Case Reports* 2017;**6**:11–4.
15. Syrdalen P, Nitter T, Mehl R. Ophthalmomyiasis interna posterior: report of case caused by the reindeer warble fly larva and review of previous reported cases. *Br J Ophthalmol* 1982;**66**(9):589–93.
16. Phelan MJ, Johnson MW. Acute posterior ophthalmomyiasis interna treated with photocoagulation. *Am J Ophthalmol* 1995;**119**:106–7.
17. Buettner H. Ophthalmomyiasis Interna. *Arch Ophthalmol* 2002;**120**(11):1598–9.
18. Çaça I, Ünlü K, Çakmak SS, Bilek K, Şakalar YB, Ünlü G. Orbital myiasis: case report. *Jpn J Ophthalmol* 2003;**47**(4):412–4.
19. Baliga MJ, Davis P, Rai P, Rajasekhar V. Orbital myiasis: a case report. *Int J Oral Maxillofac Surg* 2001;**30**(1):83–4.
20. Al-Amry Mohammad, Al-Saikhan Fahad I, Al-Dahmash Saad. External ophthalmomyiasis: a case report. *Saudi J Ophthalmol* 2014;**28**(4):322–4.
21. Omar MS, Das AB, Osman NI. External ophthalmomyiasis due to the sheep nostril botfly larva *Oestrus ovis* in Saudi Arabia. *Ann Trop Med Parasitol* 1988;**82**(2):221–3.
22. Cameron JA, Shoukrey NM, Al-Garni AA. Conjunctival ophthalmomyiasis caused by the sheep nasal botfly (*Oestrus ovis*). *Am J Ophthalmol* 1991;**112**(3):331–4.
23. Sivaramasubramanyam P, Sadanand AV. Ophthalmomyiasis. *Br J Ophthalmol* 1968;**52**(1):64–5.
24. Victoria J, Trujillo R, Barreto M, Msph. Myiasis: a successful treatment with topical ivermectin. *Int J Dermatol* 1999;**38**(2):142–4.
25. Denion E, Dalens PH, Couppié P, Aznar C, Sainte-Marie D, et al. Case series external ophthalmomyiasis caused by *Dermatobia hominis*. A retrospective study of nine cases and a review of the literature. *Acta Ophthalmol Scand* 2004;**82**:576–84.
26. Garcia-Guerrero J, Garza-Quinones J, Reza-Caballero J, Gonzalez-Trevino JL. External ophthalmomyiasis by *Oestrus ovis* treated with tobacco: clinical case report and medical literature review. *Medicina Universitaria* 2014;**16**:181–3.