



## Case report

## Endobronchial metastases 20 years after prostate cancer excision

Yukihisa Hatakeyama<sup>a,\*</sup>, Sho Yoshimura<sup>a</sup>, Taira Ninomaru<sup>a</sup>, Shodai Fujimoto<sup>a</sup>, Rei Takamiya<sup>a</sup>, Kayoko Okamura<sup>a</sup>, Nobuya Sano<sup>b</sup>, Hisashi Ohnishi<sup>a</sup>

<sup>a</sup> Department of Respiratory Medicine, Akashi Medical Center, 743-33 Okubocho Yagi, Akashi, Hyogo, 674-0063, Japan

<sup>b</sup> Department of Pathology, Akashi Medical Center, 743-33 Okubocho Yagi, Akashi, Hyogo, 674-0063, Japan

## ARTICLE INFO

## Keywords:

Bronchoscopy  
Prostate cancer  
Endobronchial metastases  
Metastatic lung cancer  
PSA

## ABSTRACT

A 78-year-old Japanese man who had undergone total prostatectomy for prostate cancer (pT3cN1M0, Gleason score 3 + 3) 20 years previously was referred to the Respiratory Medicine Department of our institution because of a 1-week history of chest pain and cough. Computed tomography showed multiple small nodules and mediastinal lymph node enlargement. Bronchoscopy revealed multiple soft polypoid masses and obstruction of the lingular segment. Prostate-specific antigen (PSA) concentrations had increased markedly from 0.48 ng/mL in 2014 to 741 ng/mL in 2018. The diagnosis of prostatic cancer metastases was confirmed by revealing the presence of PSA via immunohistological staining of a bronchoscopically obtained biopsy of one of the masses. The patient had not been attending scheduled follow-up visits for the past 4 years. Treatment with degarelix (a gonadotropin-releasing hormone) was started, and the PSA concentration decreased dramatically (29 ng/mL). Metastases from prostate cancer are rarely first diagnosed two decades after radical prostatectomy. This patient illustrates the importance of obtaining a complete medical history.

## 1. Introduction

Prostate cancer is reported to metastasize to any organ, but especially to bone [1]. Although pulmonary metastasis is often observed at necropsy, it is rarely observed clinically [2]. Endobronchial metastasis from prostate carcinoma is unique in that only 12 such cases have been confirmed [3]. The survival rate is high compared with other carcinomas, and many patients receive long-term follow-up [4]. However, recurrence two decades after initial treatment, is unique. We report a rare case of intrabronchial metastasis of prostate cancer that was found 20 years after the original diagnosis during a diagnostic work-up in a patient who had been coughing for 1 week.

## 2. Case report

A 78-year-old Japanese man presented with a 1-week history of coughing and chest pain associated with weight loss. Chest radiographic examination showed multiple nodular shadows and slightly reticular opacities. Computed tomography showed mediastinal lymph node enlargement and obstruction of the lingular lung segment (Fig. 1). Bronchoscopy revealed the presence of multiple whitish soft masses on

the bronchial surface (Fig. 2), and biopsy involved easy and extensive detachment of tissue around the tumor, with slight bleeding.

Histopathological evaluation by direct-vision biopsy showed sheet-like proliferation, a small glandular cavity, and an intracytoplasmic ductal and sieve-like structure. Immunohistological staining revealed positive prostate-specific antigen (PSA) and negative thyroid transcription factor-1 (Fig. 3). The patient was diagnosed with endobronchial metastases of prostatic cancer. After questioning the patient, we learned that he had been diagnosed with prostate cancer 20 years prior based on a high PSA level. He had undergone retropubic prostatectomy (pT3cN1M0, Gleason score 3 + 3) and was clinically followed since surgery without requiring additional treatment. Fourteen years after the successful retropubic prostatectomy, his PSA level had increased slightly from 0.03 ng/mL to 0.06 ng/mL. Two years later, his PSA level had increased further to 0.48 ng/mL. He then discontinued his follow-up visits without explanation for more than 4 years. Although his medical history for the most recent 4 years was unknown, his PSA at the time of the current visit was markedly elevated level (714 ng/mL). He was referred to the urology department for treatment of the recurrence. Administration of a gonadotropin-releasing hormone-receptor antagonist was initiated, and his blood PSA level

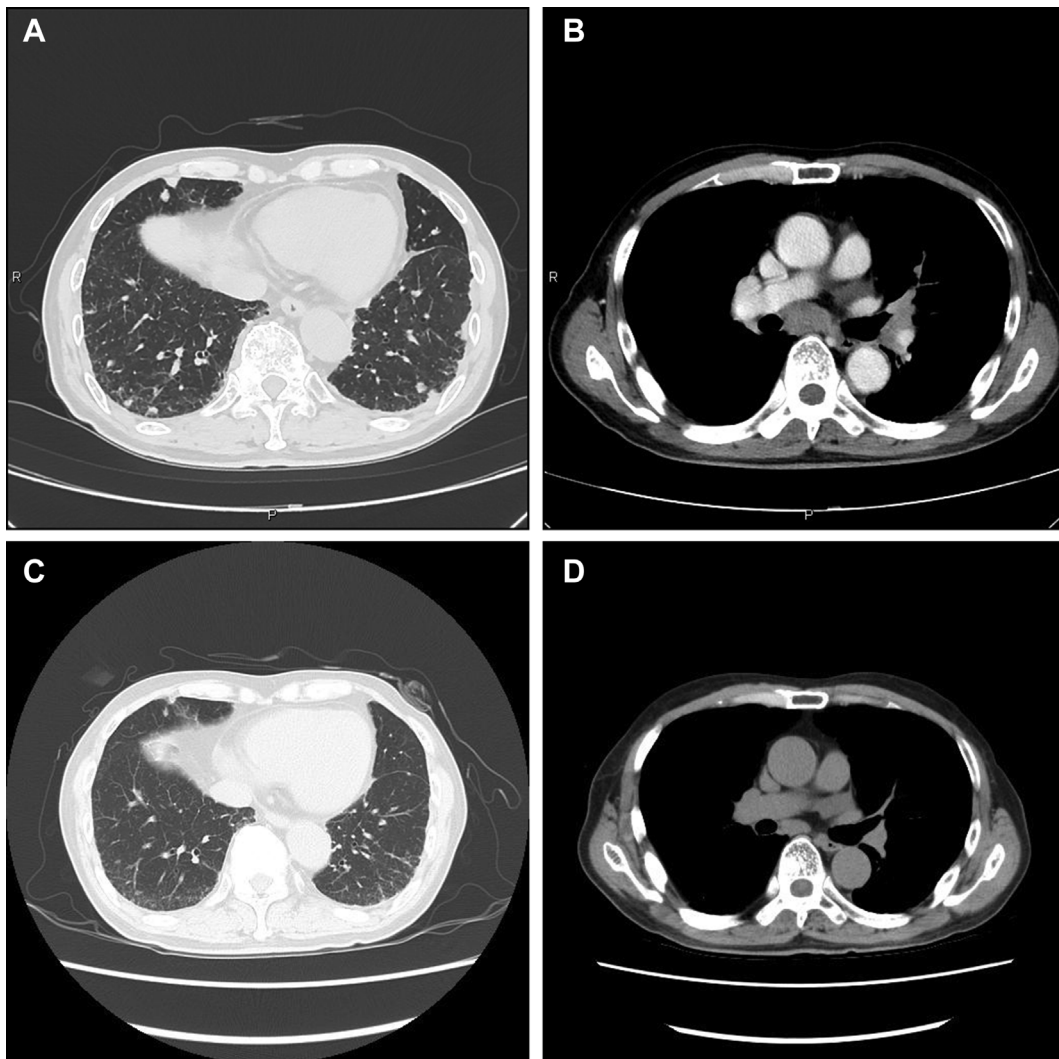
\* Corresponding author.

E-mail addresses: [yukkyu1@yahoo.co.jp](mailto:yukkyu1@yahoo.co.jp) (Y. Hatakeyama), [sho@amc1.jp](mailto:sho@amc1.jp) (S. Yoshimura), [ninomarutaira@hotmail.co.jp](mailto:ninomarutaira@hotmail.co.jp) (T. Ninomaru), [shodai0715@yahoo.co.jp](mailto:shodai0715@yahoo.co.jp) (S. Fujimoto), [takamiya0101@amc1.jp](mailto:takamiya0101@amc1.jp) (R. Takamiya), [k.okamura@amc1.jp](mailto:k.okamura@amc1.jp) (K. Okamura), [nobuya-akashi@amc1.jp](mailto:nobuya-akashi@amc1.jp) (N. Sano), [ohnishi@amc1.jp](mailto:ohnishi@amc1.jp) (H. Ohnishi).

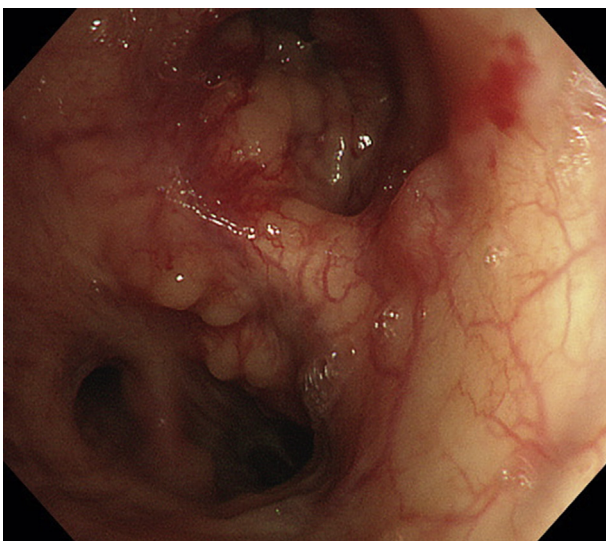
<https://doi.org/10.1016/j.rmcr.2019.100858>

Received 16 January 2019; Received in revised form 9 May 2019; Accepted 13 May 2019

2213-0071/ © 2019 The Authors. Published by Elsevier Ltd. This is an open access article under the CC BY-NC-ND license (<http://creativecommons.org/licenses/by-nc-nd/4.0/>).



**Fig. 1.** (A) Plain computed tomography (lung window) showing multiple nodules. (B) Obstructive atelectasis of the lingular segment secondary to tumor pressure. (C) (D) Post-hormone therapy changes (6 months after treatment).

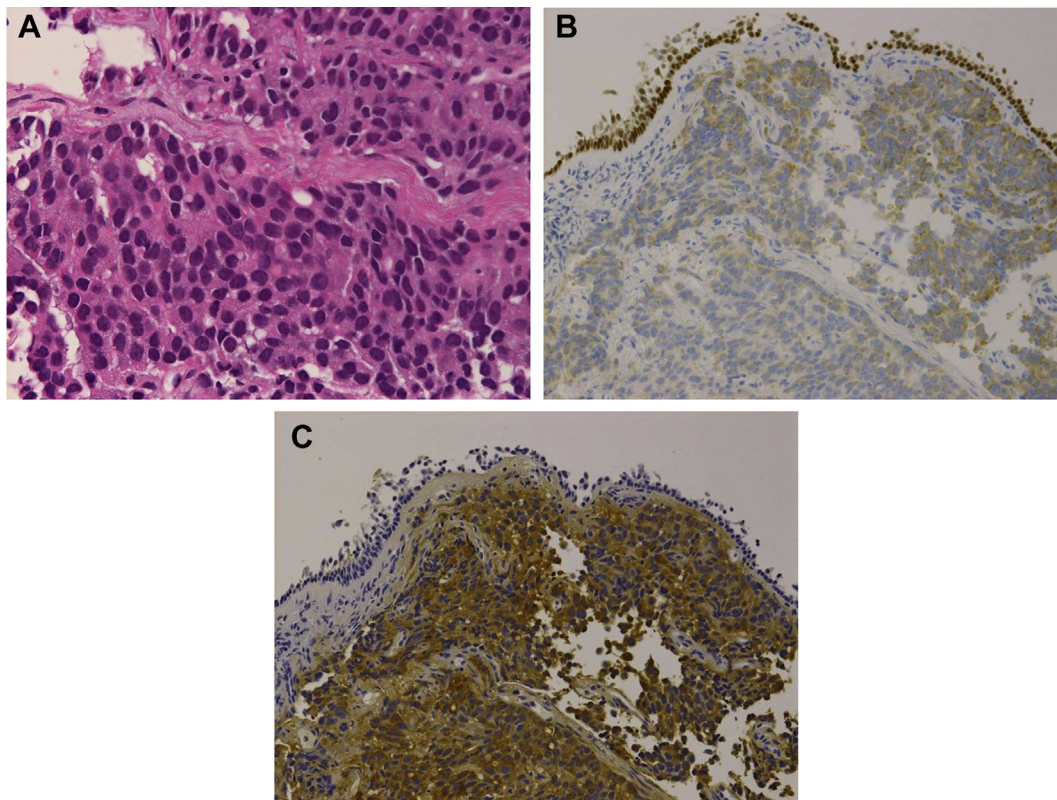


**Fig. 2.** Routine bronchoscopy showing the diffuse bronchial area with multiple soft polypoid lesions.

decreased from 714 ng/mL to 29 ng/mL. His cough improved with treatment, and we saw rapid regression of the multiple lung nodules, enlarged lymph node, and obstruction of the lingular segment (Fig. 1).

### 3. Discussion

Bronchial metastasis from an extrathoracic primary tumor is not uncommon and has a reported rate of 14% [5]. Bronchial metastasis is most commonly secondary to known breast, colon, and renal cancers [6,7], but with prostate cancer metastasis to the lung, nodules are usually identified by computed tomography. Bronchial metastasis with obvious tumor invasion to the lobar bronchi, main bronchus, or trachea is rare; to date, only 12 endobronchial metastases cases have been reported [3]. Respiratory symptoms are often the earliest sign of bronchial metastasis, and expected diagnoses differ according to the metastatic location. Metastatic lesions are most often discovered by the urology department at the time of a prostate cancer diagnosis. However, lung cancer that has metastasized from the prostate has been reported rarely (only 2.0% of such cases are diagnosed during the initial detection of the prostatic lesions) [8]. In addition, bronchial metastases are rarely found during post-treatment follow-up. Four cases of bronchial metastasis recurrence have been reported after a long interval of observation following treatment [9–12]. However, a search of the literature identified no other diagnosed recurrences after a 20-year



**Fig. 3.** Immunohistochemistry of the biopsied lung tissue. (A) Adenocarcinoma with a medullary tubular appearance (hematoxylin and eosin stain). (B) Negative labeling with thyroid transcription factor-1 ( $\times 40$ ). (C) Note the strong reaction with prostate-specific antigen ( $\times 40$ , polyclonal).

follow-up, as in our patient.

Hormone therapy is the treatment modality of choice for advanced prostate cancer. Metastatic prostate cancer is classified radiographically into two types: nodular and lymphangitic [13]; the nodular type responds more readily to drug treatment. Our patient received hormonal therapy and showed a good response, with alleviated symptoms. A meta-analysis of Phase III trials reported that lung metastases had a median overall survival of 19.4 months compared with nonvisceral bone metastases, with an overall survival of 21.3 months [14]. These results suggest that patients with lung metastases represent a second poor-risk group (lymph node only: 31.6 months, liver metastasis: 13.5 months), and that the metastatic region is an important predictor of overall survival.

Early identification of factors leading to a poor prognosis in certain metastatic categories, such as lung metastasis, is needed. In addition to being able to diagnose multiple metastatic cancers of the lung as adenocarcinoma, histopathologically, a detailed questionnaire that could lead to a correct diagnosis is also needed.

#### Conflicts of interest

None to declare.

#### Funding

The author(s) received no financial support for the research, authorship, and/or publication of this article.

#### Acknowledgement

We thank Nancy Schatken BS, MT(ASCP), and Jane Charbonneau, DVM, from Liwen Bianji, Edanz Group China ([www.liwenbianji.cn/ac](http://www.liwenbianji.cn/ac)), for editing the English text of a draft of this manuscript.

#### Appendix A. Supplementary data

Supplementary data to this article can be found online at <https://doi.org/10.1016/j.rmcr.2019.100858>.

#### References

- [1] L. Bubendorf, A. Schöpfer, U. Wagner, G. Sauter, H. Moch, N. Willi, et al., Metastatic patterns of prostate cancer: an autopsy study of 1,589 patients, *Hum. Pathol.* 31 (2000) 578–583.
- [2] B.H. Bolton, Pulmonary metastases from carcinoma of the prostate: incidence and case report of a long remission, *J. Urol.* 94 (1965) 73–77.
- [3] T. Hotta, Y. Tsubata, A. Kodama, Y. Mori, M. Nakao, Y. Amano, et al., A case of multiple endobronchial metastasis from prostate cancer showing good response to chemotherapy, *Journal of the Japan Society for Respiratory Endoscopy (JJSRE)* 39 (2017) 262–267.
- [4] C.R. Pound, A.W. Partin, M.A. Eisenberger, D.W. Chan, J.D. Pearson, P.C. Walsh, Natural history of progression after PSA elevation following radical prostatectomy, *J. Am. Med. Assoc.* 281 (1999) 1591–1597.
- [5] H. Kreisman, N. Wolkove, H.S. Finkelstein, C. Cohen, R. Margolese, H. Frank, Breast cancer and thoracic metastases: review of 119 patients, *Thorax* 38 (1983) 175–179.
- [6] M.P. Shepherd, Endobronchial metastatic disease, *Thorax* 37 (1982) 362–365.
- [7] J.B. Sørensen, Endobronchial metastases from extrapulmonary solid tumors, *Acta Oncol.* 43 (2004) 73–79.
- [8] S.J. Fabozzi, P.F. Schellhammer, A.M. el-Mahdi, Pulmonary metastases from prostate cancer, *Cancer* 75 (1995) 2706–2709.
- [9] W.G. Scoggins, J.A. Witten Jr., J.H. Texter Jr., T.A. Hazra, Endobronchial metastasis from prostatic cancer in patient with renal cell carcinoma, *Urology* 12 (1978) 207–209.
- [10] H. Scherz, J.D. Schmidt, Endobronchial metastasis from prostate carcinoma, *Prostate* 8 (1986) 319–324.
- [11] D.W. Lee, J.Y. Ro, A.A. Sahin, A.G. Lee JS Ayala, Mucinous adenocarcinoma of the prostate with endobronchial metastasis, *Am. J. Clin. Pathol.* 94 (1990) 641–645.
- [12] I. Gerogianni, S. Gravas, D. Papadopoulos, A. Terzis, M. Nakou, V. Tzortzis, et al., Endobronchial metastasis from prostate cancer, *Int. Urol. Nephrol.* 40 (2008) 961–964.
- [13] M. Tokumitsu, F. Inada, K. Kitahara, N. Kawakami, N. Masui, H. Ishida, et al., Successful complete androgen blockade (CAB) therapy for prostatic cancer detected from multiple lung metastases: a case report, *Hinyokika Kyo* 47 (2001) 59–62 (in Japanese).
- [14] S. Halabi, W.K. Kelly, H. Ma, H. Zhou, N.C. Solomon, K. Fizazi, et al., Meta-analysis evaluating the impact of site of metastasis on overall survival in men with castration-resistant prostate cancer, *J. Clin. Oncol.* 34 (2016) 1652–1659.