

Long-term Outcome Following Three-Level Stand-Alone Anterior Cervical Discectomy and Fusion: Is Plating Necessary?

Abstract

Background: Anterior cervical discectomy with fusion (ACDF) is a proven method for the treatment of selected patients. The necessity of use of an anterior plate is controversial. The article aims to assess the fusion rates (FRs) and long-term outcomes following three-level ACDF. **Materials and Methods:** Data were collected from the medical records of patients operated on due to degenerative cervical disease. All patients were treated with three-level ACDF employing polyether ether-ketone cages without anterior plating. Visual analog scale (VAS), neck disability index (NDI), and plain radiographs were used in the clinical and radiological postsurgery assessment. Fusion evaluation was performed according to the <1 mm motion between spinous processes rule. Subsidence was defined as a more than 2 mm decrease in the interbody height. **Results:** A total of 234 treated levels on 78 patients were assessed. The mean presurgery NDI score was 23.07 ± 4.86 , with a mean disability of $46.03\% \pm 9.64$. The mean presurgery VAS score of the neck was 7.58 ± 0.85 , while VAS score of the arm was 7.75 ± 1.008 . Post surgery, NDI stated no disability, while VAS score of the neck and arm showed no presence of pain. The mean FR was 19.50 ± 21.71 levels per month, with a peak from 3rd to 6th month. Presurgery evaluation showed 12 (15.38%) patients with a high T2 sequence signal. Magnetic resonance imaging screening detected 31 (39.24%) patients with coexisting cervical and lumbar findings. Post surgery, transient dysphagia was reported by 1 patient (1.28%), while subsidence was registered in 15 (6.41%) levels, situated in 12 patients (15.38%), most often at C₆₋₇ (66.6%). Clinical and radiological follow-up extended to 69.47 ± 11.45 months. **Conclusion:** Multilevel stand-alone ACDF is a safe, cost-effective procedure providing favorable clinical and radiological results with minimal complications. The incidence of subsidence is usually clinically insignificant and can be decreased with a careful surgical technique.

Keywords: Anterior cervical discectomy, fusion, outcome, stand alone

Introduction

Since its introduction in the 1950s, anterior cervical discectomy with fusion (ACDF) has been established as the gold standard technique for the treatment of symptomatic degenerative cervical disease (DCD), providing excellent results in most patients.^[1] The use of anterior plating is typically suggested in multilevel discectomies to provide better stability. The necessity, however, of this technique has been questioned over the years since similar results can be achieved employing the stand-alone technique, especially in one- or two-level surgery.^[2,3] The article aims to assess the fusion rates (FRs) and long-term outcomes following three-level ACDF without the use of an anterior plate.

This is an open access journal, and articles are distributed under the terms of the Creative Commons Attribution-NonCommercial-ShareAlike 4.0 License, which allows others to remix, tweak, and build upon the work non-commercially, as long as appropriate credit is given and the new creations are licensed under the identical terms.

For reprints contact: WKHLRPMedknow_reprints@wolterskluwer.com

Materials and Methods

Patients

Data were retrospectively collected from the medical records of 78 patients primary operated on for symptomatic DCD at three-cervical spine levels due to electromyographic and radiographic magnetic resonance imaging (MRI) evidence of compressed cervical nerve roots or spinal cord by ossified bony elements or herniated disc, with concordant radiculopathy and/or myelopathy symptoms. No trauma patients were included in this study. Due to lack of set norms in the literature, regarding the time of eligibility of these patients for a surgical procedure, our department's protocol was followed, offering surgery to patients with persistent

Marios Theologou^{1,2},
Theologos
Theologou³,
Nikolaos
Skoulios¹, Maria
Mitka², Nikolaos
Karanikolas¹,
Antriana
Theologou⁴,
Eleftheria
Georgiou⁵, Slavisa
Matejic⁶, Christos
Tsonidis¹

¹Second Departments of Neurosurgery, Aristotle University of Thessaloniki, Hippokraton General Hospital of Thessaloniki, ²Fifth Department of Surgery, Aristotle University of Thessaloniki, Hippokraton General Hospital of Thessaloniki, ³Department of Spine Surgery, Lefkos Stavros the Athens Clinic, Athens, ⁴Pediatric Surgery Department, Hippokraton General Hospital of Thessaloniki, Greece, ⁵School of Medicine, University of Belgrade, Belgrade, ⁶Department of Neurosurgery, School of Medicine, University of Pristina Temporarily Settled in Kosovska Mitrovica, Kosovo, Serbia

Address for correspondence:

Dr. Marios Theologou,
Konstantinoupoleos 49,
Thessaloniki 54642, Greece.
E-mail: theologou_marios@dr.com

Access this article online

Website: www.asianjns.org

DOI: 10.4103/ajns.AJNS_196_19

Quick Response Code:



How to cite this article: Theologou M, Theologou T, Skoulios N, Mitka M, Karanikolas N, Theologou A, et al. Long-term outcome following three-level stand-alone anterior cervical discectomy and fusion: Is plating necessary? Asian J Neurosurg 2020;15:554-9.

Submitted: 25-Jun-2019 Revised: 21-Dec-2019

Accepted: 08-Apr-2020 Published: 28-Aug-2020

neck and/or upper extremity pain and/or neurological deficits, without previous physical therapy treatment.

Surgical technique

All patients were treated with three-level ACDF, by a single surgical team, employing the standard Smith–Robinson approach.^[4] The cartilaginous disc end plate was removed, while excessive care was taken to avoid any damage of the bony end plate, followed by osteophyctomy and foraminotomy in the vast majority of cases. Radiographic-guided trials were employed in the size selection process of the polyether ether ketone (PEEK) cages. Autologous local decompression bone as well as synthesized hydroxyapatite–collagen artificial bone was used to fill the cages thus promoting fusion.

Outcome assessment

Clinical assessment (visual analog scale [VAS] of the neck and arm,^[5] and neck disability index [NDI]^[6]) and radiological assessment (plain radiograph) were performed once per month until fusion was accomplished as a part of the surgical team's follow-up protocol. Postsurgery MRI was conducted in patients that presented with radiographic signs of myelopathy (high signal on T2 sequence) on the preoperative imaging. FR was evaluated employing the <1 mm motion between the spinous processes system.^[7] Subsidence was defined as a more than 2 mm decrease of the interbody height.^[8] Plain radiograph measurements were compared to MRI to define magnification by an experienced independent radiologist. Patient follow-up was 69.47 ± 11.45 months. All data management and analysis were performed using the IBM SPSS v. 21 software (SPSS Inc., Chicago, IL, USA). Normality was assessed employing the Shapiro–Wilk test. Descriptive data were presented as Mean and Standard Deviation. Qualitative data were tested employing chi-squared test, while quantitative were assessed by a t-test. A statistically significant difference between comparative groups was considered at the 95% confidence interval ($P \leq 0.05$).

Results

Clinical and radiological characteristics

A total of 234 treated levels on 78 patients, 43 (55.2%) male and 35 (44.8%) female, with a mean age of 50.73 ± 8.88 (minimum: 30; maximum: 71) years were assessed after treated with three-level ACDF. The mean presurgery NDI score was 23.07 ± 4.86 (minimum: 13; maximum: 34), with a mean disability of $46.03\% \pm 9.64$ [Table 1]. The mean presurgery VAS score of the neck was 7.58 ± 0.85 (minimum: 6; maximum: 9), while VAS of the arm was 7.75 ± 1.008 (minimum: 6; maximum: 9) [Tables 2 and 3].

During the presurgery evaluation, 12 (15.38%) patients manifested a high T2 sequence signal. MRI screening

Table 1: Neck Disability Index patient scores

NDI				
Valid	Frequency	Percent	Valid percent	Cumulative percent
13.00	2	2.6	2.6	2.6
14.00	2	2.6	2.6	5.1
15.00	5	6.4	6.4	11.5
16.00	1	1.3	1.3	12.8
18.00	4	5.1	5.1	17.9
20.00	7	9.0	9.0	26.9
21.00	1	1.3	1.3	28.2
22.00	8	10.3	10.3	38.5
23.00	11	14.1	14.1	52.6
24.00	10	12.8	12.8	65.4
25.00	9	11.5	11.5	76.9
26.00	3	3.8	3.8	80.8
27.00	4	5.1	5.1	85.9
28.00	3	3.8	3.8	89.7
29.00	1	1.3	1.3	91.0
31.00	2	2.6	2.6	93.6
33.00	3	3.8	3.8	97.4
34.00	2	2.6	2.6	100.0
Total	78	100.0	100.0	

NDI – Neck Disability Index

Table 2: Self-reported usual analog scale - neck pain level

VAS neck				
Valid	Frequency	Percent	Valid percent	Cumulative percent
6.00	9	11.5	11.5	11.5
7.00	24	30.8	30.8	42.3
8.00	35	44.9	44.9	87.2
9.00	10	12.8	12.8	100.0
Total	78	100.0	100.0	

VAS – Visual Analog Scale

Table 3: Self-reported Visual analog scale - arm pain level

VAS arm				
Valid	Frequency	Percent	Valid percent	Cumulative percent
6.00	11	14.1	14.1	14.1
7.00	20	25.6	25.6	39.7
8.00	26	33.3	33.3	73.1
9.00	19	24.4	24.4	97.4
10.00	2	2.6	2.6	100.0
Total	78	100.0	100.0	

VAS – Visual Analog Scale

detected 31 (39.24%) patients with coexisting cervical and lumbar radiographical findings.

Surgical data

The surgical time was approximately. $3.16 \text{ h} \pm 0.29$. Hospitalization extended for 2.22 ± 0.42 days.

Complications

Post surgery, transient dysphagia was reported by 1 patient (1.28%), while from the total number of operated levels subsidence was registered in 15 (6.41%)

situated in 12 patients (15.38%), most often at C₆₋₇ level (66.6%) [Table 4].

Outcome

Post surgery, NDI stated no disability (1.93 ± 0.87; minimum: 1 and maximum: 3), as shown in Table 5, while VAS score of the neck and arm showed no presence of pain (neck: 0.10 ± 0.30; minimum: 0 and maximum: 1, arm: 0.19 ± 0.53; minimum: 0 and maximum: 3) as manifested in Tables 6 and 7. The mean FR was 19.50 ± 21.71 levels per month (minimum:

0; maximum: 51), with a maximum peak from 3rd to 6th month [Figure 2]. Post surgery, high signal resolved in 8 (66.6%) at 12-month follow-up.

Discussion

To our knowledge, there are scarce mentions of three or more level ACDF without anterior plating in the literature. Anterior cervical plating was popularized in the early 1980s and remains a widely used technique, especially in the treatment of three and more levels, as it is believed to positively influence alignment and outcome.^[9] However, the necessity of plating is controversial if Wolff’s law of biomechanics is taken into consideration, according to which bone formation is stimulated by mechanical loading, a law on which the superior results of dynamic plating were attributed.^[10] Based on the aforementioned results, we could conclude that taking the plate out of the occasion would result in even higher FRs in a shorter period of time as supported further, by the results of this study. Literature also shows good postsurgery results in patients who were treated with only interbody spacers for up to four levels, with one case report advocating the safety of employing this technique for up to five levels.^[11,12] Bagby advocate the use of stand-alone cages in ACDF based on the distraction–compression principle.^[13] The results of this study support the aforementioned theory.

The assessment was performed employing NDI and VAS scoring systems, as well as clinical neurological evaluation. Most of the patients presented with moderate disability (46.03% ± 9.64%; NDI 23.07 ± 4.86) and reported VAS pain of the neck: 7.58 ± 0.85/arm: 7.75 ± 1.008. Post surgery, none of the patients reported any disability or pain (NDI: 0–3; VAS neck: 0–1; VAS arm: 0–3) (*P* < 0.001 – NDI; *P* = 0.004 – VAS neck; *P* = 0.002 – VAS arm). Our good results support the literature, showing up a 90% likelihood of relief of radicular pain and stabilization.^[14]

Some researchers advocate the use of a low focal T1 and/or high T2 signal as a negative prognostic factor regarding posttreatment outcome, while others defy this.^[15-21] Our results support the last as during presurgery evaluation, 12 (15.38%) of the patients manifested a high intense T2 signal, without compromising the results. The aforementioned results, however, could be associated with a higher NDI score (ranging from 27 to 34). No association with VAS was observed. We support the use of diffusion tensor imaging, a relatively new promising technique which detects the random motion of water molecules, providing information about cellular integrity/pathology, thus detecting white matter damage before a high T2 signal appears, presenting a great tool in the presurgery evaluation. Our patients were also MRI screened for degenerative lumbar syndrome (DLS) resulting in 31 (39.24%) patients, having coexisting cervical and lumbar manifestations, some of who were operated on for both in one act. Literature

Table 4: Subsidence incidence per level employing the more than 2 mm decrease of the interbody height

Subsidence				
Valid	Frequency	Percent	Valid percent	Cumulative percent
C ₄₋₅	2	13.4	13.4	13.4
C ₅₋₆	3	20	20	33.4
C ₆₋₇	10	66.6	66.6	100
Total	15	100.0	100.0	

Evaluation performed employing the 2mm decrease of the interbody height rule

Table 5: Neck Disability Index scores on first post-surgery follow-up

NDI postsurgery				
Valid	Frequency	Percent	Valid percent	Cumulative percent
1.00	32	41.0	41.0	41.0
2.00	19	24.4	24.4	65.4
3.00	27	34.6	34.6	100.0
Total	78	100.0	100.0	

NDI – Neck Disability Index

Table 6: Self-reported Visual Analog Scale grade for neck pain on first post-surgery follow-up

VAS neck postsurgery				
Valid	Frequency	Percent	Valid percent	Cumulative percent
0.00	70	89.7	89.7	89.7
1.00	8	10.3	10.3	100.0
Total	78	100.0	100.0	

VAS – Visual Analog Scale

Table 7: Self-reported Visual Analog Scale grade for arm pain on first post-surgery follow-up

VAS arm postsurgery				
Valid	Frequency	Percent	Valid percent	Cumulative percent
0.00	66	84.6	85.7	85.7
1.00	8	10.3	10.4	96.1
2.00	2	2.6	2.6	98.7
3.00	1	1.3	1.3	100.0
Total	77	98.7	100.0	
Missing system	1	1.3		
Total	78	100.0		

VAS – Visual Analog Scale

suggests that coexisting lumbar stenosis is a fairly common (up to 28%) finding in these patients and one may mask the symptoms of the other; therefore, patients with lumbar stenosis should also be evaluated for DCD and vice versa.^[22-24]

The goal of operative treatment is the decompression of the spinal cord without compromising alignment and stability. All of our patients received stand-alone PEEK interbody spacers embedded with local decompression bone and/or hydroxyapatite–collagen artificial bone, a widely used technique providing superior FRs, while avoiding the donor site morbidity associated with iliac crest harvesting.^[25,26]

Recent literature suggests numerous available methods to assess fusion and thus diagnose pseudoarthrosis, resulting often in a disagreement between surgeons and reviewers. Oshina *et al.* in their extensive review found 10 fusion criteria and concluded that the presence of trabecular bone between the end plates was the most commonly used definition. However, the authors found the particular classification highly subjective and recommended the use of the <1 mm of motion between spinous processes on the extension and flexion system to confirm fusion^[7] [Figure 1]. Furthermore, FRs were reported as 90.2% at 1 year and 94.7% at 2 years.^[7] Based on the aforementioned results, the second criteria system was employed in the evaluation process. The 1st year FR was 100%, with a significant peak registered between months 3 and 6, as shown in Figure 2. Moreover, there is a common belief that fusion is not possible during the 1st month postsurgery; however, 7.70% of the treated levels fulfilled the criteria for being classified as fused, thus manifesting that early fusion is possible.

Adjacent segment disease (ASD) is a broad term describing new postsurgery findings, such as intervertebral disc herniation, hypertrophic facet arthritis, listhesis, instability, scoliosis, and vertebral compression fracture in patients treated with fusion techniques, especially in those with single-level arthrodesis involving the C₅₋₆ vertebrae and preexisting radiographic evidence of adjacent level degeneration.^[27] The

leading opinion is that altered biomechanical status of the cervical spine due to arthrodesis as well as the disruption of anatomical structures including even soft-tissue damage results in an increase of intradiscal pressure, leading to the degeneration of the adjacent segment intervertebral discs (evidence level III).^[28-30] Literature advocates that in case the surgeon uses the cervical plating technique, the plate-to-disc distance can contribute at a great extent in the progression of ASD if the plate is positioned <3 mm from the adjacent disc and as a result, a gap of at least 5 mm should be used.^[31,32] The avoidance of plating should diminish the incidence of ASD, as shown in this study, as none of the patients presented with the same in the long term.

Dysphagia and dysphonia are the most common complications, with rates 1%–79%.^[33,34] Dysphagia presents a controversial entity associated with soft-tissue swelling, recurrent laryngeal nerve (RLN) palsy, pharyngeal plexus denervation, direct injury, and regional esophageal ischemia. Likewise, dysphonia is associated with RLN palsy, while it can also present due to the direct trauma of the vocal cords during intubation. One patient presented with self-reported dysphagia (1.28%) subsiding a month postsurgery. None of our patients presented with dysphonia. The aforementioned results may be associated with the absence of an anterior plate, application of retraction with periodic pressure release, and fine soft-tissue handling.

Subsidence presents an important radiographic finding, resulting in a long-term foraminal reduction. The literature reports an incidence of 8.1%–44.77%.^[25,29] We registered 15 (6.41%) subsidence in 234 operated interbody spaces, without compromising clinical outcome. Subsidence is a multifactorial radiographic finding and it does not depend solely on the presence or absence of a plate. The literature suggests that greater distance between anterior cage rim and vertebral body and less contact surface between cage and end plate are significant risk factors due to increased stress applied on the surface of the end plate.^[35] Low bone mineral density, excessive distraction during interbody-spacer application, and intraoperative end-plate damage can also increase the incidence. The good results

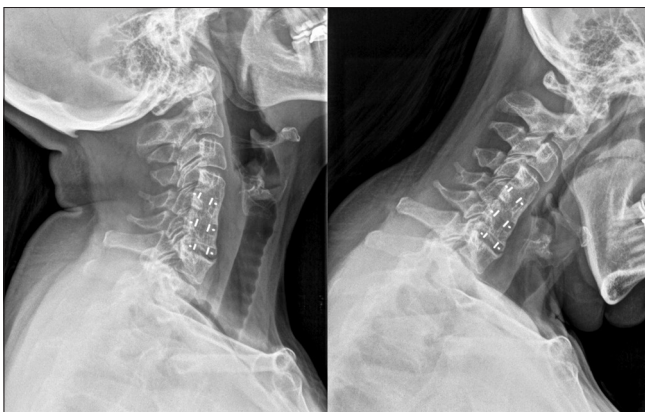


Figure 1: Postsurgery plain radiograph in hyperextension and hyperflexion, used in fusion rate evaluation employing the <1 mm movement between the spinal processes system

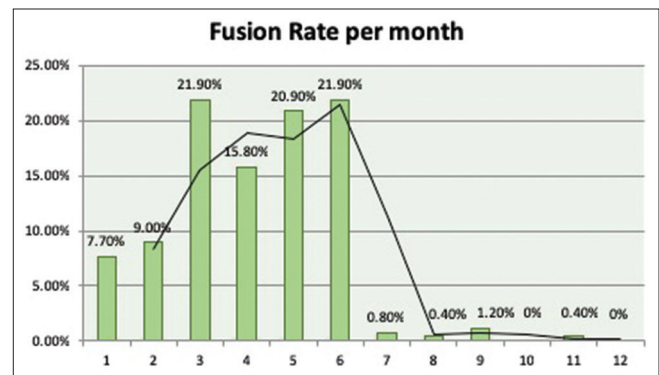


Figure 2: Fusion Rate per month assessed employing the <1 mm of motion between the spinous processes criteria

demonstrated in this study may be associated with proper preparation of patients and fine manipulation, thus reduction of bone damage and selection of proper cage height and AP diameter. A very interesting finding was that the most common level of subsidence was the C₆₋₇, registered in as many as 66.6% of the cases, a finding in accordance with the literature.^[36] However, none of the patients' outcome or FR was affected despite negative radiological measurements in our study or in recently published papers.

Last but not least, we have to take into consideration the surgical time which is shorter in the employment of our technique (our mean surgical time was approximately 3 h 16 m), as well as the socioeconomical gain as less materials are introduced (Greece's lowest price found according to the National Health System Observatory for anterior plate 536€), thus decreasing surgical team fee due to less procedures performed (National Insurance Program per ICD for ACDF with plating 6000€ including 7 hospitalization days).^[37,38] As a result, a sum of 41,808€ was saved from the National Insurance System, Private Sector Insurance System, and Personal Funds of the Health Services Users, without introducing into the equation the fee difference of the surgical team.

Conclusion

ACDF without the use of an anterior plate in three levels is a safe, cost-effective technique providing good short, intermediate, and long-term clinical results with a minimal incidence of complications. The use of stand-alone cages can provide similar or better FRs compared to plating. Subsidence can occur, but it is clinically insignificant. Correct cage size selection and positioning may lower its incidence. Patients presenting with DCD should be also screened for DLS as a significant incidence of coexistence can be detected, thus providing the opportunity of dual treatment in one act that could result in even better outcomes.

Financial support and sponsorship

Nil.

Conflicts of interest

There are no conflicts of interest.

References

- Buttermann GR. Anterior cervical discectomy and fusion outcomes over 10 years: A prospective study. *Spine (Phila Pa 1976)* 2018;43:207-14.
- Cheung ZB, Gidumal S, White S, Shin J, Phan K, Osman N, *et al.* Comparison of anterior cervical discectomy and fusion with a stand-alone interbody cage versus a conventional cage-plate technique: A systematic review and meta-analysis. *Global Spine J* 2019;9:446-55.
- Kim SY, Yoon SH, Kim D, Oh CH, Oh S. A prospective study with cage-only or cage-with-plate fixation in anterior cervical discectomy and interbody fusion of one and two levels. *J Korean Neurosurg Soc* 2017;60:691-700.
- Smith GW, Robinson RA. The treatment of certain cervical-spine disorders by anterior removal of the intervertebral disc and interbody fusion. *J Bone Joint Surg Am* 1958;40:607-24.
- Downie WW, Leatham PA, Rhind VM, Wright V, Branco JA, Anderson JA. Studies with pain rating scales. *Ann Rheum Dis* 1978;37:378-81.
- Vernon H, Mior S. The neck disability index: A study of reliability and validity. *J Manipulative Physiol Ther* 1991;14:409-15.
- Oshina M, Oshima Y, Tanaka S, Riew KD. Radiological fusion criteria of postoperative anterior cervical discectomy and fusion: A systematic review. *Global Spine J* 2018;8:739-50.
- Yang JJ, Yu CH, Chang BS, Yeom JS, Lee JH, Lee CK. Subsidence and nonunion after anterior cervical interbody fusion using a stand-alone polyetheretherketone (PEEK) cage. *Clin Orthop Surg* 2011;3:16-23.
- Vanek P, Bradac O, DeLacy P, Saur K, Belsan T, Benes V. Comparison of 3 fusion techniques in the treatment of the degenerative cervical spine disease. Is stand-alone autograft really the 'gold standard?': Prospective study with 2-year follow-up. *Spine (Phila Pa 1976)*. 2012;37:1645-51.
- Chamay A, Tschantz P. Mechanical influences in bone remodeling. Experimental research on Wolff's law. *J Biomech* 1972;5:173-80.
- Chu CW, Kung SS, Tsai TH, Huang TY, Hwang SL. Anterior discectomies and interbody cage fusion without plate fixation for 5-level cervical degenerative disc disease: A 5-year follow-up. *Kaohsiung J Med Sci* 2011;27:524-7.
- Hwang SL, Lin CL, Lieu AS, Lee KS, Kuo TH, Hwang YF, *et al.* Three-level and four-level anterior cervical discectomies and titanium cage-Augmented fusion with and without plate fixation. *J Neurosurg Spine*. 2004;1:160-7.
- Bagby GW. Arthrodesis by the distraction-compression method using a stainless steel implant. *Orthopedics* 1988;11:931-4.
- Sampath P, Bendebba M, Davis JD, Ducker T. Outcome in patients with cervical radiculopathy. Prospective, multicenter study with independent clinical review. *Spine (Phila Pa 1976)* 1999;24:591-7.
- Al-Habib AF, AlAqeel AM, Aldakkan AS, AlBadr FB, Shaik SA. Length of MRI signal may predict outcome in advanced cervical spondylotic myelopathy. *Neurosciences (Riyadh)* 2015;20:41-7.
- Chen J, Liu Z, Zhong G, Qian L, Li Z, Chen B, *et al.* Surgical treatment for cervical spondylotic myelopathy in elderly patients: A retrospective study. *Clin Neurol Neurosurg* 2015;132:47-51.
- Karpova A, Arun R, Cadotte DW, *et al.* Assessment of spinal cord compression by magnetic resonance imaging—can it predict surgical outcomes in degenerative compressive myelopathy? A systematic review. *Spine (Phila Pa 1976)*. 2013;38(16):1409-21
- Matsumoto M, Toyama Y, Ishikawa M, Chiba K, Suzuki N, Fujimura Y. Increased signal intensity of the spinal cord on magnetic resonance images in cervical compressive myelopathy. Does it predict the outcome of conservative treatment? *Spine (Phila Pa 1976)* 2000;25:677-82.
- Nouri A, Tetreault L, Zamorano JJ, Dalzell K, Davis AM, Mikulis D, *et al.* Role of magnetic resonance imaging in predicting surgical outcome in patients with cervical spondylotic myelopathy. *Spine (Phila Pa 1976)* 2015;40:171-8.
- Uchida K, Nakajima H, Sato R, Kokubo Y, Yayama T, Kobayashi S, *et al.* Multivariate analysis of the neurological outcome of surgery for cervical compressive myelopathy. *J Orthop Sci* 2005;10:564-73.
- Yukawa Y, Kato F, Yoshihara H, Yanase M, Ito K. MR T2 image classification in cervical compression myelopathy: Predictor of surgical outcomes. *Spine (Phila Pa 1976)* 2007;32:1675-8.

22. Dagi TF, Tarkington MA, Leech JJ. Tandem lumbar and cervical spinal stenosis. Natural history, prognostic indices, and results after surgical decompression. *J Neurosurg* 1987;66:842-9.
23. Epstein NE, Epstein JA, Carras R, Murthy VS, Hyman RA. Coexisting cervical and lumbar spinal stenosis: Diagnosis and management. *Neurosurgery* 1984;15:489-96.
24. LaBan MM, Green ML. Concurrent (tandem) cervical and lumbar spinal stenosis: A 10-yr review of 54 hospitalized patients. *Am J Phys Med Rehabil* 2004;83:187-90.
25. Ba Z, Zhao W, Wu D, Shen B, Yu B, Wang Z. Box cages packed with local decompression bone were efficient in anterior cervical discectomy and fusion: Five- to 10-year follow-up. *Spine (Phila Pa 1976)* 2012;37:E1260-3.
26. Samartzis D, Shen FH, Matthews DK, Yoon ST, Goldberg EJ, An HS. Comparison of allograft to autograft in multilevel anterior cervical discectomy and fusion with rigid plate fixation. *Spine J* 2003;3:451-9.
27. Hilibrand AS, Carlson GD, Palumbo MA, Jones PK, Bohlman HH. Radiculopathy and myelopathy at segments adjacent to the site of a previous anterior cervical arthrodesis. *J Bone Joint Surg Am* 1999;81:519-28.
28. Baba H, Furusawa N, Imura S, Kawahara N, Tsuchiya H, Tomita K. Late radiographic findings after anterior cervical fusion for spondylotic myeloradiculopathy. *Spine (Phila Pa 1976)* 1993;18:2167-73.
29. Bohlman HH, Emery SE, Goodfellow DB, Jones PK. Robinson anterior cervical discectomy and arthrodesis for cervical radiculopathy. Long-term follow-up of one hundred and twenty-two patients. *J Bone Joint Surg Am* 1993;75:1298-307.
30. Gore DR, Sepic SB. Anterior cervical fusion for degenerated or protruded discs. A review of one hundred forty-six patients. *Spine (Phila Pa 1976)* 1984;9:667-71.
31. Park JB, Cho YS, Riew KD. Development of adjacent-level ossification in patients with an anterior cervical plate. *J Bone Joint Surg Am.* 2005;87:558-63.
32. Park JB, Wathanaaphisit T, Riew KD. Timing of development of adjacent-level ossification after anterior cervical arthrodesis with plates. *Spine J* 2007;7:633-6.
33. Daniels AH, Riew KD, Yoo JU, Ching A, Birchard KR, Kranenburg AJ, *et al.* Adverse events associated with anterior cervical spine surgery. *J Am Acad Orthop Surg* 2008;16:729-38.
34. Starmer HM, Riley LH 3rd, Hillel AT, Akst LM, Best SR, Gourin CG. Dysphagia, short-term outcomes, and cost of care after anterior cervical disc surgery. *Dysphagia* 2014;29:68-77.
35. Barsa P, Suchomel P. Factors affecting sagittal malalignment due to cage subsidence in standalone cage assisted anterior cervical fusion. *Eur Spine J* 2007;16:1395-400.
36. Bartels RH, Donk R, van Azn RD. Height of cervical foramina after anterior discectomy and implantation of a carbon fiber cage. *J Neurosurg* 2001;95:40-2.
37. HealthCare (Greek Ministry of Health-National Insurance Program Price per ICD-10). Available from: https://heexperience.gr/drugs/ken.php?cp=drg&drg_code=%CE%9C09%CE%A7&srch=proc. [Last accessed on 2019 Apr 21].
38. Observe Net (Greek Ministry of Health- National HealthCare Price Observatory-Surgical Equipment). Available from: <http://84.205.248.47/front.php/simple/listing?page=175&orderby=3>. [Last accessed on 2019 Apr 21].