



Case report

Visual rehabilitation with limbal autologous stem cells transplant and cataract surgery in a patient with ocular surface squamous neoplasia

Eduardo J. Polania-Baron^a, Enrique O. Graue-Hernandez^a, Arturo Ramirez-Miranda^a, Guillermo Amescua^b, Alejandro Navas^{a,*}

^a Department of Cornea, External Disease, and Refractive Surgery, Instituto de Oftalmología "Conde de Valenciana", Mexico City, Mexico

^b Department of Ophthalmology, Bascom Palmer Eye Institute, University of Miami Miller School of Medicine, Miami, FL, USA



ARTICLE INFO

Keywords:

Ocular surface squamous neoplasia
Simple limbal epithelial transplantation
Limbal stem cell deficiency

ABSTRACT

Purpose: To describe the outcome of simple limbal epithelial transplantation along with Phacoemulsification and IOL implantation for visual rehabilitation in limbal stem cell deficiency due to ocular surface squamous neoplasia.

Observations: This case report of a 66-year-old woman clinically diagnosed with OSSN in her right eye involving all cornea and limbus meridians. Topical chemotherapy for tumor treatment was done, followed by SLET and sequential cataract surgery. The entire tumor could be clinically reduced with topical chemotherapy but a LSCD could not be avoided. After SLET, corneal transparency was restored, and anterior segment details could be seen, phacoemulsification was performed uneventfully. After a follow-up period of 18 months, stable ocular surface and visual acuity and no tumor recurrence was observed.

Conclusions: SLET is an option to restore not only corneal epithelium homeostasis but also gain cornea transparency, avoid keratoplasties and allow anterior segment surgeries to be performed.

Importance: This case report provide evidence of benefits of simple limbal epithelial transplantation in ocular surface squamous neoplasia and shows that cataract surgery could be performed uneventfully after limbal stem cell transplantation.

1. Introduction

Limbal stem cell deficiency (LSCD) is characterized by conjunctival epithelial ingrowth, persistent epithelial defects and or chronic epithelial staining leading to destruction of the basal membrane and superficial fibrovascular tissue ingrowth with functional impairment due to loss of transparency and/or integrity of the cornea.¹ In 2012 Sangwan et al.² proposed a novel technique they named simple limbal epithelial transplantation (SLET) for the treatment of unilateral LSCD. Limbal stem cell deficiency can be a cause of irregularities in the cornea in turn making it difficult to calculate the power of and intra-ocular lens. We present a case of visual rehabilitation in OSSN after SLET and phacoemulsification.

2. Case report

A 66-year-old female presented with a large corneal-conjunctival

lesion in her right eye causing progressive vision loss for the past 12 months. At initial evaluation, she had a visual acuity (VA) of hand movement (HM), and an intraocular pressure of 16 mmhg in her right eye, and a VA of 20/40 and 14 mmhg in her left eye. Slit-lamp examination of the right eye is shown in Fig. 1A. Biomicroscopy in her left eye only revealed a NO2NC2 cataract (according to Lens Opacities Classification System III). Due to clinical presentation the diagnosis of OSSN was made. The patient was administered 5-Fluorouracil 1 % (5-FU) 4 times daily every two weeks (two weeks on treatment and two week off treatment), this regimen was repeated 5 times until complete clinical regression (Fig. 1B and C).

After five months the OSSN was clinically diminished, visual acuity improved from HM to 20/200 but a secondary limbal stem cell deficiency and a vascularized leucoma remained, as well an age-related cataract (Fig. 1C).

SLET surgery was performed with the standard technique described by Sangwan et al.² Under local anesthesia a 2–3mm length of superior

* Corresponding author.

E-mail address: alejandro.navas@institutodeoftalmologia.org (A. Navas).

<https://doi.org/10.1016/j.ajoc.2021.101167>

Received 28 September 2020; Received in revised form 4 March 2021; Accepted 19 July 2021

Available online 23 July 2021

2451-9936/© 2021 Published by Elsevier Inc. This is an open access article under the CC BY-NC-ND license (<http://creativecommons.org/licenses/by-nc-nd/4.0/>).

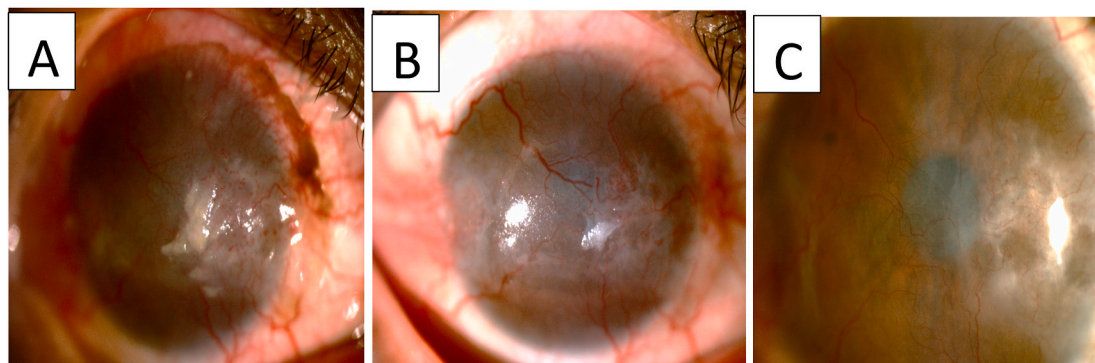


Fig. 1. Photographs of right eye with Ocular Surface Squamous Neoplasia.

Generalized bulbar conjunctival hyperemia and superior limbal pigmentation, 360°

vascularization of the cornea with a fleshy grayish lesion with central leukoplakia (A). 1 month after 5-FU topical treatment, with leukoplakia and pigmentation elimination and corneal lesion reduction (B). 5 months after 5-FU treatment, no lesion is seen, but 360° corneal vascularization, superficial leucoma, and epithelial irregularity remain (C).

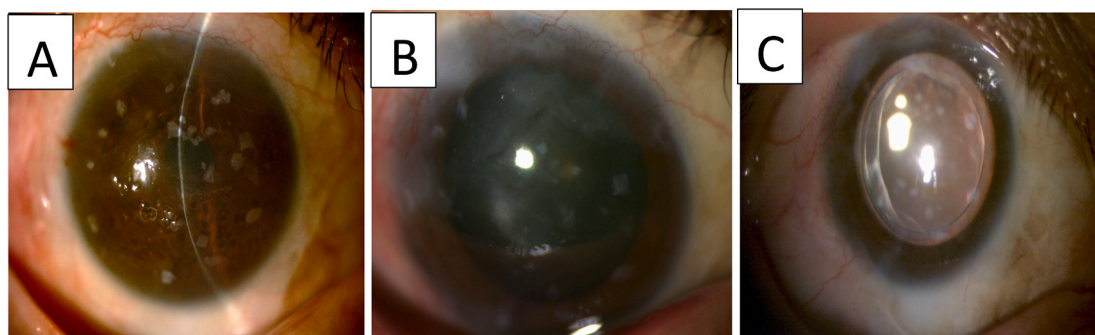


Fig. 2. Photographs of right eye after Simple Epithelial Transplantation.

One month after SLET, avascular cornea is seen, with transplant fragments placed in central, paracentral and peripheral cornea, and anterior segment details now could be seen (A).

One year after SLET, sectorial LSCD is seen in peripheral superior cornea, majority of transplant fragments has disappeared and cataract could be seen under pupil dilatation (B). 20 months after SLET and 7 months after cataract surgery (C).

limbus was excised from the healthy contralateral eye. The recipient site was prepared by a 360° peritomy and removal of pannus on the cornea by superficial keratectomy. The recipient cornea was then covered with a single layer amniotic membrane. This was glued to the surface with fibrin glue. The limbal graft was cut into approximately 20 pieces. The cut fragments of the transplant were then placed on the surface of the amniotic membrane and distributed evenly around the cornea. A small amount of fibrin glue was dropped on top of the grafts to secure them. A bandage contact lens was (ACUVUE® OASYS, senofilcon A, Plano, +0.50D) placed after 1 min when the glue has polymerized. The contact lens was removed at 10 days. VA at post-operative day 30 was 20/80, corneal vascularization regressed significantly with a minimal residual leucoma (Fig. 2A). At 12 months post-operatively we can observe a clearer cornea allowing the visualization of a cataract. VA remained at 20/80. For the cataract surgery planification corneal Scheimpflug based tomography was used (OCULUS Pentacam® AXL), with an axial length of 22.9 mm, the IOL power calculated for surgery was 22.5 diopters (D) with a predicted refractive outcome of -0.43 D using the Barret Universal II formula (A-constant of 119). Two months after the phacoemulsification, the patient's BSCVA was 20/25 with a manifest refraction of +1.25-2.25 x 15 (Fig. 2C).

3. Discussion

There is scant evidence regarding SLET in OSSN and all the reports show SLET can be used at the time of the tumor removal in order to help the limbus.^{3,4} This case represents a different cause of grade III LSCD

(according to LSCD global consensus)⁵ in OSSN due to direct limbal stem cell destruction from the tumor cells and/or toxicity from the topical 5-FU chemotherapy. Due to the location and extension of the OSSN, the decision was made to use medical treatment first to avoid surgical trauma. We attempted to calculate the IOL with and optical biometer but keratometries and anterior chamber depth could not be analyzed due to the presence of anterior surface irregularity so a tomography device was the ideal method to determine corneal power and made an accurate IOL power calculation.

4. Conclusions

We conclude that SLET could be used to restore epithelium homeostasis in some cases, providing enough corneal transparency to perform phacoemulsification to improve visual acuity.

Patient consent

The patients consented to publication of the case orally. This report does not contain any personal information that could lead to the identification of the patient.

Funding

No funding or grant support.

Declaration of competing interest

The following authors have no financial disclosures: EJP, EGH,ARM, GA,AN. All Authorship: authors attest that they meet the current ICMJE criteria for Authorship.

Acknowledgement

None.

References

1. Holland E. Management of limbal stem cell deficiency: a historical perspective, past, present, and future. *Cornea*. 2015;31(10):9–15.
2. Sangwan VS, Basu S, Macneil S, Balasubramanian D. Simple Limbal Epithelial Transplantation (SLET): A Novel Surgical Technique for the Treatment of Unilateral Limbal Stem Cell Deficiency. 2012. <https://doi.org/10.1136/bjophthalmol-2011-301164>.
3. Kaliki S, Mohammad FA, Tahiliani P, Sangwan VS. Concomitant simple limbal epithelial transplantation after surgical excision of ocular surface squamous neoplasia Swathi. *Am J Ophthalmol*. 2016. <https://doi.org/10.1016/j.ajo.2016.10.021>.
4. Mittal V, Narang P, Menon V, Mitta R, Honavar S. Primary simple limbal epithelial transplantation along with excisional biopsy in the management of extensive. *Cornea*. 2016;35:1650–1652.
5. Deng SX, Borderie V, Chan CC, et al. Global consensus on definition , classification , diagnosis , and staging of limbal stem cell deficiency. 2019;38(3):364–375.