

Neoscytalidium dimidiatum as onychomycosis causative agent in an Iranian patient: a case report and literature review

T. Razavyoon¹, S. J. Hashemi¹, S. Ansari², P. Mansouri³, R. Daie-Ghazvini¹, S. Khodavaisy¹, Z. Rafat⁴, H. Kamali Sarvestani¹, L. Hosseinpour¹, P. Afshar⁵, F. Hashemi⁶ and F. safaie⁷

1) Department of Medical Parasitology and Mycology, School of Public Health, Tehran University of Medical Sciences, 2) Department of Parasitology and Mycology, School of Medicine, Shahid Beheshti University of Medical Sciences, 3) Skin and Stem Cell Research Center, Tehran University of Medical Sciences, Tehran, 4) Department of Medical Microbiology, School of Medicine, Guilan University of Medical Sciences, Rasht, 5) Research and Development of Referral Laboratory, Deputy of Health Management, Mazandaran University of Medical Sciences, Sari, 6) School of Pharmacy, Tehran University of Medical Sciences and 7) Islamic Azad University, Tehran Medical Branch, Iran

Abstract

A 38-year-old healthy male presented to our medical mycology center with whitish opaque discoloration of the right toenail. He reported a history of some sand scratches subsequent to walking barefoot on the beach two years ago and wearing hard safety shoes for a period of two years. On clinical examination, onycholysis, onychodystrophy, and apparent thickening of the ungual bed in the left big toe were found. The microscopic examination of nail clippings using 15% potassium hydroxide (KOH) revealed the presence of septate pigmented hyphae. The fungus was identified as *Neoscytalidium dimidiatum* based on the cultural characteristics, the arrangement of arthroconidia on lactophenol cotton blue (LPCB) staining, blocky-brown pigmented hyphae on serum physiology mounts, and sequencing. Susceptibility of the isolated fungi to amphotericin B, itraconazole, voriconazole, and terbinafine was tested using the standard broth microdilution M38-A2 method developed by the Clinical and Laboratory Standards Institute (CLSI). The minimum inhibitory concentrations (MICs) of the four antifungal drugs used in this study were: amphotericin B: 1 mg/L, itraconazole: 2 mg/L, voriconazole: 0.25 mg/L, and terbinafine: 1 mg/L. The patient underwent terbinafine and clobetasol topical treatments for 6 months.

© 2022 Published by Elsevier Ltd.

Keywords: Iran, *Neoscytalidium dimidiatum*, Onychomycosis, Antifungal susceptibility testing, Sequencing

Original Submission: 22 May 2021; **Revised Submission:** 14 June 2021; **Accepted:** 17 December 2021

Article published online: 10 January 2022

Corresponding author: Seyed Jamal Hashemi
E-mail: Sjhashemi@tums.ac.ir

Introduction

Onychomycosis is a term that refers to all nail disorders caused by fungal etiologic agents with a prevalence of 18–40% of all onychopathies [1]. The main types of onychomycosis have been described as distal and lateral subungual onychomycosis, superficial white onychomycosis, proximal subungual onychomycosis, endonyx onychomycosis, and total dystrophic onychomycosis [2,3]. Etiologic agents of onychomycosis mostly

consist of three different groups of fungi; dermatophyte, molds, and yeasts. The prevalence of etiologic fungi varies and depends on different factors like sex, age, occupation, climate, health situation, cultural habits, country, geographic (urban and rural) area, underlying disease, and diagnostic evaluation methods [3]. Saprophytic fungi divided into hyaline and dematiaceous fungi. Dematiaceous or black refers to melanin-producing yeasts, yeast-like, and filamentous fungi. Mostly they live in soil and plants. Several of those can cause disease in humans and animals with a spectrum of superficial mycosis to severe encephalitis [4]. *Neoscytalidium* sp. (formerly: *Scytalidium*) are ascomycetous fungi belong to a large and heterogeneous group of fungi that cause Phaeohyphomycosis. Some though can infect humans via direct contact, sometimes traumatic, with colonized plants or vegetable residues [5]. *Neoscytalidium dimidiatum* and its hyaline

mutant, *N. dimidiatum* var. *hyalinum* can cause clinical lesions in nail and skin similar to those produced by dermatophytes [6]. Here, we report the case of a 38-year-old man with onychomycosis caused by *N. dimidiatum* in Iran.

Case report

A 38-year-old electrical engineer male presented to our medical mycology center with whitish opaque discoloration of the right toenail for a duration of two years. His medical history showed some sand scratches subsequent to walking barefoot on the beach two years ago and wearing hard safety shoes for a period of two years. Also, his medical reports showed that his allergic rhinitis due to concha surgery (nose flesh surgery) had been under control. Furthermore, the laboratory reports showed negative results for viral hepatic tests (HBC -Ab and HIV-Ab, HBs-Ab > 400 mIU/mL) and normal results for routine laboratory tests. On clinical examination, onycholysis and onychodystrophy, with apparent thickening of ungual bed in the left big toe were found (Fig 1: A). He underwent terbinafine and clobetasol topical treatments after initial diagnosis using potassium hydroxide (KOH) smear (Fig 2) and culture. No evidence of progress in treatment was seen. With the rest of the nail clipping, the second culture was conducted about two months later of the first visit. The microscopic examination of nail scrapings using 15% KOH revealed the presence of septate hyaline hyphae. The material was cultured on Sabouraud's dextrose agar (SDA) with and without cycloheximide and cornmeal agar. The SDA without cycloheximide grew woolly brown colonies after seven days of incubation at room temperature. There was no growth on SDA with cycloheximide. Greyish black colonies grew on SDA (Fig. 3: A&B). Normal

saline mounts showed numerous cylindrical or globose, one-to-two-celled barrel-shaped arthroconidia with dark walls and many wide and septate brown and hyaline hyphae (Fig 4). The fungus was identified as *Neoscytalidium* sp. based on the cultural characteristics, the arrangement of arthroconidia on lactophenol cotton blue (LPCB) staining, and dark hyphae on serum physiology mounts. Accurate identification was accomplished via sequencing analysis. Briefly, genomic DNA was isolated from fresh colonies using a method described previously [7]. Then, PCR was carried out bilaterally to amplify the ITS regions of the rDNA gene using the pan fungal primers: ITS1 (5'-TCCGTAGGTGAACCTGCGG-3') and ITS4 (5'-TCCTCCGCTTATTGATATGC-3') [8]. The amplicon was sent for sequencing, which showed 100% similarity with the sequence of *Neoscytalidium dimidiatum* clone URF_Pt01 (accession number MT010216) deposited in NCBI BLAST (<https://www.blast.ncbi.nlm.nih.gov/Blast.cgi>) database. The relevant sequence extracted from current study (*Neoscytalidium dimidiatum*) has been deposited in GenBank under accession number MZ377100. The *in-vitro* antifungal susceptibility testing was performed according to the Clinical and Laboratory Standards Institute (CLSI) document M38-A2 method [10]. The minimum inhibitory concentrations (MICs), the result of the four antifungal drugs used in the study were: amphotericin B: 1 mg/L, itraconazole: 2 mg/L, voriconazole: 0.25 mg/L, and terbinafine: 1 mg/L. The treatment has changed to itraconazole 100 mg/day and amorolfine nail lacquer for 10 weeks subsequently. Drug tolerance was well and toenail infected areas were reduced (Fig. 1B). Written informed consent was obtained from the patient. All data were de-identified. This Health Insurance Portability and Accountability Act-compliant study received approval from the institutional review board (IR.TUMS.SPH.REC.1398.197).

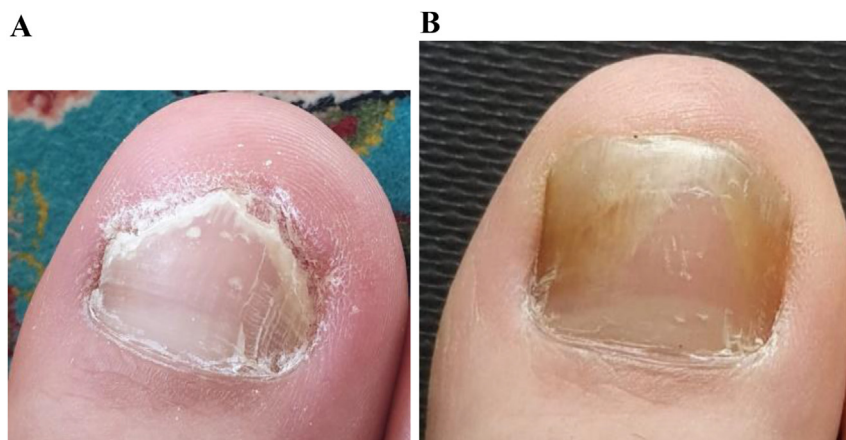

FIG. 1. A: Toe nail day 0; **B:** After 10 weeks treatment with oral itraconazole & Amorolfine nail lacquer.

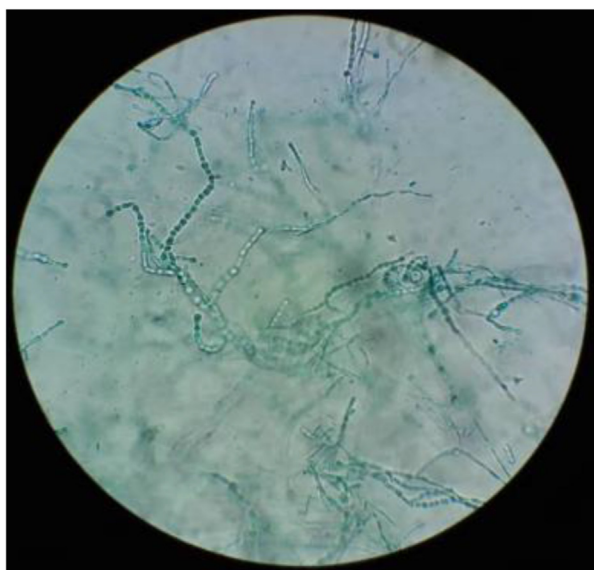


FIG. 2. KOH mount.

Discussion

Onychomycosis challenges such as aesthetic problems, difficulty in running or rotating, and more make discomfort situations for patients. Causative agents of onychomycosis include molds, dermatophytes, and yeasts [35]. Studies demonstrate that the prevalence and distribution of causative agents of onychomycosis can vary according to geographic location, climate, and cultural customs [11,35]. Non-dermatophyte molds (NDMs) are one of the etiologic agents of onychomycosis which divided into hyaline and dematiaceous fungi. The most common hyaline NDMs are different species of *Aspergillus*, *Scopulariopsis*, *Alternaria*, *Acremonium*, and *Fusarium* [12–14]. *A. flavus* and *A. niger* complex are generally isolated from abnormal nails [15], but

there are also reports of onychomycosis due to rare species of *Aspergillus* like *A. candidum* [16] or *A. sydowii* [15].

Among dematiaceous NDMs *Cyphellophora* and *Phialophora* are involved in onychomycosis and mild skin infections [4]. Also, *Neoscytalidium* sp. is a genus of dematiaceous fungi that has been isolated from several nail infections [11]. *N. dimidiatum* and its mutant *N. hyalinum* can both play a similar role in causing onychomycosis or superficial skin infections and are clinically indistinguishable from dermatophytosis. *N. dimidiatum* more commonly invade the nails, toe tissues, and soles of the feet with hyperkeratosis; however, hands are rarely affected [17]. The fungi first inhabit toenails by a laterodistal development. Paronychia may also occur as total nail dystrophy. Palm lesions are mainly unilateral although single affecting is classically bilateral reproducing the two-foot one-hand syndrome [6,17–19].

Neoscytalidium infections have a different prevalence in the world that it seems is more dependent on the geographic area than the susceptible population. Mostly there are two clinical forms of *Neoscytalidium* infections in published articles, onychomycosis, and systemic disease [20]. A systematic review conducted on NDMs etiologic agents of onychomycosis in 2012 among nine countries (Canada, Colombia, Spain, Italy, Greece, Pakistan, Thailand, and Brazil) shows that 4% of onychomycosis etiologic agent belong to *N. dimidiatum* which occurred only in the study conducted in Brazil and none in the other countries contribute in the article [13]. In São Paulo, Brazil from 588 cases of onychomycosis, NDMs were isolated in 7.4% of positive cultures related to toenail onychomycosis with 2.3% *Nat-rassia mangiferae* (*Neoscytalidium*) [21]. Furthermore, in Alagoas, Brazil during 2009–2016 only 0.1 percent of each annual sampling refers to *Neoscytalidium* sp. [22]. One report from Thailand showed *Fusarium* and *Scyrtalidium dimidiatum* are two major etiologic agents of onychomycosis due to NDMs

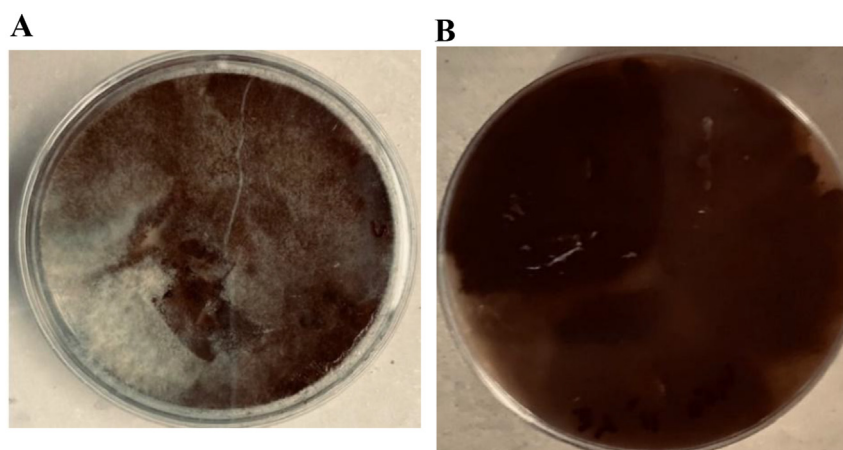


FIG. 3. **A:** *N. dimidiatum* SDA culture, forward view; **B:** *N. dimidiatum* SDA culture, reverse view.

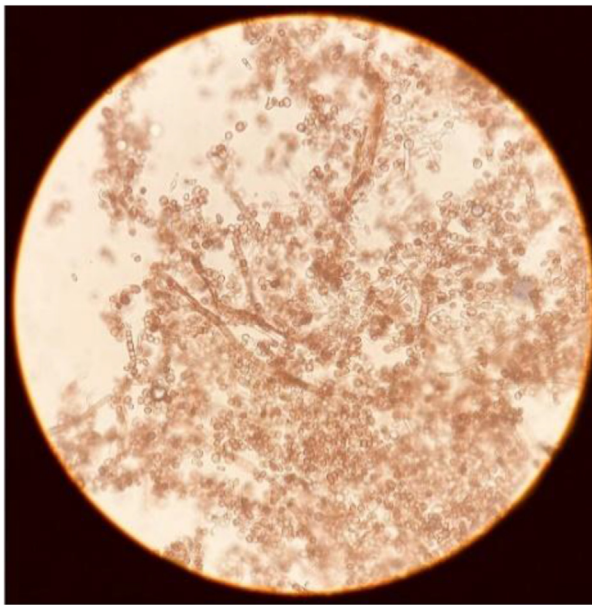


FIG. 4. Normal saline mount.

[23]. Deep infection in scytalidiosis is mostly accompanied by immune suppression in situations like lung and renal transplant, diabetes, or further underlying disease. There are several reports about profound infection as central nervous system abscesses, endophthalmitis, sinusitis, osteomyelitis mycetoma, subcutaneous lesions, and disseminated infection caused by *Neoscytalidium* sp. [22,24–31]. *N. dimidiatum* is involved more than *N. hyalinum* in deep mycosis [32] and its related mortality is about 50% [17]. A study from Iran presented a fatal case of *Nattractasia mangiferae* (*Neoscytalidium* sp.) encephalitis after thorn eye penetration in a diabetic 60-year-old male with cirrhosis and heart failure [33]. In another study, a cerebral

phaeohyphomycosis due to *Nattractasia mangiferae* (*Neoscytalidium* sp.) reported in Iran. This case was a 17-year-old male with a history of systemic lupus erythematosus and renal involvement. The diagnosis was based on histopathologic and mycologic evidence after craniotomy [27]. In onychomycosis, oral drugs in combination with nail lacquer should offer better results than single treatment with antifungals [5]. A professional removal of the infected area along with antifungal therapy is recommended as a perfect therapeutic method [34]. Also, several case reports had assessed *in vitro* antifungal susceptibility testing of different antifungal agents against *Neoscytalidium* sp. isolated from clinical specimens (Table 1).

Diagnosis of onychomycosis is challenging and it starts by the rollout of other dermatology disorders which can affect healthy nail appearance. After reaching fungal etiology, there are some differential diagnosis criteria that differ molds from dermatophytes like priority of skin involvement than the nail, infection in more than one nail in dermatophytes, and other practical evidence. But historically, scytalidiosis was distinguished from dermatophytic onychomycosis by resistance to routine anti-dermatophyte treatments. It is notable that clinically differentiate between scytalidiosis and dermatophytosis is unintelligible [7]. The primary diagnosis of onychomycosis is based on potassium hydroxide (KOH) smear and culture. In NDMs diagnosis in comparison to dermatophytes and yeasts diagnosis, there is a need to more evaluations such as identification of the NDM in the nail by microscopy (KOH preparation), culture isolation, repeated isolation in culture, inoculum counting, failure to isolate a dermatophyte in culture, and histology. [13]. The most reliable methods are molecular approaches such as PCR-sequencing for molds and also *Neoscytalidium*. Although it is uncommon due to special equipment and experience. Furthermore, the results achieved with mass analysis through

TABLE 1. Case reports demonstrated *in vitro* antifungal susceptibility testing of different antifungal agents against *Neoscytalidium* sp.

Reference	Case No	Country	Sex/Age	Infection site	Treatment	Diagnosis
Garinet et al. [36]/2001	1	French Guyana	M/53	Leg & toenail	Surgical, oral itraconazole, and local amphotericin B	<i>Neoscytalidium</i> sp.
Garinet et al. [36]/2002	2	Ivory coast	F/64	Sole & nail of feet/	Local terbinafine	<i>N. hyalinum</i>
Jabbarvand [37]/2004	3	Iran	M/32	Eye	Natamycin eyedrop and oral ketoconazole	<i>Neoscytalidium</i> sp.
Geramishoar [27]/2004	4	Iran	M/17	Soft tissue (cranial abases)	Corticosteroid and cyclophosphamide	<i>Neoscytalidium</i> sp.
Sadeghi Tai [33]/2005	5	Iran	M/60	Eye	Surgery & systemic imipenem, metronidazole, and amphotericin B with	<i>Neoscytalidium</i> sp.
Garinet [36]/2007	6	Mauritania	M/52	Ankle	Surgery	<i>N. dimidiatum</i>
Elinav [31]/2009	7	Israel	M/56	Lung and pleura	Intravenous voriconazole and Amphotericin B from intra pleural root	<i>N. dimidiatum</i>
Garinet [36]/2011	8	Cameroun	M/59	Leg & foot	Oral voriconazole and topical ketoconazole	<i>N. dimidiatum</i>
Garinet [36]/2011	9	Congo Brazzaville	M/59	Elbow, back, and leg	Oral voriconazole	<i>N. dimidiatum</i>
Roy [39]/2013	10	India	NA/55	Toenails	Oral Itraconazole	<i>Neoscytalidium</i> sp.
Dionne [38]/2015	11	USA	M/50	Lung	Amphotericin B, posaconazole	<i>N. dimidiatum</i>
Shokoohi et al. [9]/2020	12	Iran	F/52	Finger nail	Oral terbinafine plus ciclopirox nail lacquer	<i>N. novaehollandiae</i>
Present case/2021	13	Iran	M/38	Toe nail	Oral terbinafine then changed to itraconazole and ciclopirox lacquer	<i>N. dimidiatum</i>

Abbreviations: M: male; F: Female; *Neoscytalidium* sp.: not molecular base diagnosis; NA: not available.

dendrogram construction of MALDI-TOF MS of *N. dimidiatum* showed valuable and cost-effective assessed with ITS rDNA gene analysis technics [28].

In conclusion, to the best of our knowledge, the present case is the first report of onychomycosis caused by *N. dimidiatum* in Iran. The precise identification of etiologic agents of onychomycosis and antifungal susceptibility testing before antifungal treatment is necessary.

Transparency declaration

Authors declare no conflicts of interest.

Informed permission was attained for experimentation with human subjects.

Acknowledgments

This study was supported by funding from Tehran University of Medical Sciences (Grant number: 640).

References

- [1] André J, Rigopoulos D, Elewski B, Richert B. Histopathology of onychomycosis. *Onychomycosis Diagn Eff Manag* 2018;1:60–5.
- [2] Zaias N. Onychomycosis. *Arch Dermatol* 1972;105:263–74.
- [3] Baran R, Hay RJ, Tosti A, Haneke E. A new classification of onychomycosis. *Br J Dermatol* 1998;139:567–71.
- [4] Chowdhary A, Perfect J, de Hoog GS. Black molds and melanized yeasts pathogenic to humans. *Cold Spring Harb Perspec Med* 2015;5:a019570.
- [5] Avner S, Nir N, Henri T. Combination of oral terbinafine and topical ciclopirox compared to oral terbinafine for the treatment of onychomycosis. *J Dermatol Treat* 2005;16:327–30.
- [6] Hay RJ. Scytalidium infections. *Curr Opin Infect Dis* 2002;15:99–100.
- [7] Makimura K, Tamura Y, Mochizuki T, Hasegawa A, Tajiri Y, Hanazawa R, Uchida K, Saito H, Yamaguchi H. Phylogenetic classification and species identification of dermatophyte strains based on DNA sequences of nuclear ribosomal internal transcribed spacer 1 regions. *J Clin Microbiol* 1999;37:920–4.
- [8] White TJ, Bruns T, Lee SJ, Taylor J. Amplification and direct sequencing of fungal ribosomal RNA genes for phylogenetics. *PCR Protoc A Guide Methods Appl* 1990;18:315–22.
- [9] Shokoohi GR, Ansari S, Abolghazi A, Gramishoar M, Nouripour-Sisakht S, Mirhendi H, Makimura K. The first case of fingernail onychomycosis due to *Neoscytalidium novaehollandiae*, molecular identification and antifungal susceptibility. *J Mycol Med* 2020;30:100920.
- [10] Fothergill AW. Antifungal susceptibility testing: clinical laboratory and standards institute (CLSI) methods. In *Interactions of yeasts, moulds, and antifungal agents*. Human Press; 2012. p. 65–74.
- [11] Faure-Cognet O, Fricker-Hidalgo H, Pelloux H, Leccia MT. Superficial fungal infections in a French teaching hospital in Grenoble area: retrospective study on 5470 samples from 2001 to 2011. *Mycopathologia* 2016;181:59–66.
- [12] Moreno G, Arenas R. Other fungi causing onychomycosis. *Clin Dermatol* 2010;28:160–3.
- [13] Gupta AK, Drummond-Main C, Cooper EA, Brintnell W, Piraccini BM, Tosti A. Systematic review of nondermatophyte mold onychomycosis: diagnosis, clinical types, epidemiology, and treatment. *J Am Acad Dermatol* 2012;66:494–502.
- [14] English MP, Atkinson R. Onychomycosis in elderly chiropody patients. *Br J Dermatol* 1974;91:67–72.
- [15] Bongomin F, Batac CR, Richardson MD, Denning DW. A review of onychomycosis due to *Aspergillus* species. *Mycopathologia* 2018;183:485–93.
- [16] Ahmadi B, Hashemi SJ, Zaini F, Shidfar MR, Moazeni M, Mousavi B, Noorbakhsh F, Gheramishoar M, Rezaie S. A case of onychomycosis caused by *Aspergillus candidus*. *Med Mycol Case Rep* 2012;1:45–8.
- [17] Machouart M, Menir P, Helenon R, Quist D, Desbois N. Scytalidium and scytalidiosis: what's new in 2012? *J Mycol Med* 2013;23:40–6.
- [18] Belloeuf L, Boisseau-Garsaud AM, Saint-Cyr I, Desbois N, Helenon R, Quénehervé C, Calès-Quist D, Garsaud P. Onychomycoses à *Scytalidium* en Martinique. In: *Annales de dermatologie et de vénéréologie*, vol. 131. Elsevier Masson; 2004. p. 245–9.
- [19] Hay RJ, Moore MK. Clinical features of superficial fungal infections caused by *Hendersonula toruloidea* and *Scytalidium hyalinum*. *Br J Dermatol* 1984;110:677–83.
- [20] Ellis DH, Watson AB, Marley JE, Williams TG. Non-dermatophytes in onychomycosis of the toenails. *Br J Dermatol* 1997;136:490–3.
- [21] Godoy-Martinez P, Nunes FG, Tomimori-Yamashita J, Urrutia M, Zaror L, Silva V, Fischman O. Onychomycosis in São Paulo, Brazil. *Mycopathologia* 2009;168:111–6.
- [22] de Albuquerque Maranhão FC, Oliveira-Júnior JB, dos Santos Araújo MA, Silva DM. Mycoses in northeastern Brazil: epidemiology and prevalence of fungal species in 8 years of retrospective analysis in Alagoas. *Braz J Microbiol* 2019;50:969–78.
- [23] Ungpakorn R, Lohapathan S, Reangchainam S. Prevalence of foot diseases in outpatients attending the Institute of Dermatology, Bangkok, Thailand. *Clin Exp Dermatol Viewpoints Dermatol* 2004;29:87–90.
- [24] Sigler L, Summerbell RC, Poole L, Wieden M, Sutton DA, Rinaldi MG, Aguirre M, Estes GW, Galgiani JN. Invasive *Nattractia mangiferae* infections: case report, literature review, and therapeutic and taxonomic appraisal. *J Clin Microbiol* 1997;35(2):433–40.
- [25] Pfaller MA, Messer SA, Woosley LN, Jones RN, Castanheira M. Echinocandin and triazole antifungal susceptibility profiles for clinical opportunistic yeast and mold isolates collected from 2010 to 2011: application of new CLSI clinical breakpoints and epidemiological cutoff values for characterization of geographic and temporal trends of antifungal resistance. *J Clin Microbiol* 2013;51:2571–81.
- [26] Gumbo T, Mkanganwi N, Robertson VJ, Masvaire P. Case report. *Nattractia mangiferae* endophthalmitis. *Mycoses* 2002;45:118–9.
- [27] Gheramishoar M, Zomorodian K, Zaini F, Saadat F, Tarazooie B, Norouzi M, Rezaie S. First case of cerebral phaeohiphomyces caused by *Nattractia mangiferae* in Iran. *Jpn J Infect Dis* 2004;57:285–6.
- [28] Tan DH, Sigler L, Gibas CF, Fong IW. Disseminated fungal infection in a renal transplant recipient involving *Macrophomina phaseolina* and *Scytalidium dimidiatum*: case report and review of taxonomic changes among medically important members of the Botryosphaeriaceae. *Med Mycol* 2008;46:285–92.
- [29] Mani RS, Chickabasaviah YT, Nagarathna S, Chandramuki A, Shivprakash MR, Vijayan J, Prashantha DK, Vasudevan PS, Natarajan A, Kovoor J. Cerebral phaeohiphomyces caused by *Scytalidium dimidiatum*: a case report from India. *Med Mycol* 2008;46:705–11.
- [30] Sanglard D, Ischer F, Parkinson T, Falconer D, Bille J. Candida albicans mutations in the ergosterol biosynthetic pathway and resistance to several antifungal agents. *Antimicrob Agents Chemother* 2003;47:2404–12.

- [31] Elinav H, Izhar U, Benenson S, Admon D, Hidalgo-Grass C, Polacheck I, Korem M. Invasive *Scytalidium dimidiatum* infection in an immunocompetent adult. *J Clin Microbiol* 2009;47(4): 1259–63.
- [32] Zaatari GS, Reed R, Morewessel R. Subcutaneous hyphomycosis caused by *Scytalidium hyalinum*. *Am J Clin Pathol* 1984;82:252–6.
- [33] Tari AS, Mardani M, Rahnavardi M, Amoli FA, Abedinifar Z. Post-traumatic fatal *Nattractasia mangiferae* orbital infection. *Int Ophthalmol* 2005;26:247–50.
- [34] Malay DS, Yi S, Borowsky P, Downey MS, Mlodzienski AJ. Efficacy of debridement alone versus debridement combined with topical antifungal nail lacquer for the treatment of pedal onychomycosis: a randomized, controlled trial. *J Foot Ankle Surg* 2009;48(3): 294–308.
- [35] Rafat Z, Hashemi SJ, Saboor-Yaraghi AA, Pouragha B, Taheriniya A, Moosavi A, et al. A systematic review and meta-analysis on the epidemiology, casual agents and demographic characteristics of onychomycosis in Iran. *J Mycol Med* 2019;29:265–72.
- [36] Garinet S, Tourret J, Barete S, Arzouk N, Meyer I, Frances C, Datry A, Mazier D, Barrou B, Fekkar A. Invasive cutaneous *Neoscytalidium* infections in renal transplant recipients: a series of five cases. Invasive cutaneous *Neoscytalidium* infections in renal transplant recipients: a series of five cases. *BMC Infect Dis* 2015;15(535):1–7.
- [37] Jabbarvand M, Hashemian MR, Abedinifar Z, Amini A. *Nattractasia mangiferae* keratitis after laser in situ keratomileusis. *J Cataract Refract Surg* 2004;30(1):268–72.
- [38] Dionne B, Neff L, Lee SA, Sutton DA, Wiederhold NP, Lindner J, Fan H, Jakeman B. Pulmonary fungal infection caused by *Neoscytalidium dimidiatum*. *J Clin Microbiol* 2015;53:2381–4.
- [39] Roy P, Bhatt P. *Nattractasia mangiferae*: an uncommon agent of onychomycosis. *Med J Armed Forces India* 2015;71:297–9.