

## Brown-Séquard Syndrome Caused by Blunt Cervical Trauma with Radiographic Correlation

### Abstract

Brown-Séquard syndrome, while uncommon, is a neurological condition that classically results from the hemisection of the spinal cord as a result of a penetrating injury to the spinal cord. We present a reported case of blunt trauma causing a high-energy cervical burst fracture/dislocation with a significant cord signal change producing Brown-Séquard syndrome. In this case, the burst fracture at the level of C5 obtained from the motor vehicle accident led to the damage of the left-sided lateral spinal thalamic tract, descending lateral cortical spinal tracts, and ascending dorsal column. This is a unique case of blunt nonpenetrating trauma leading to a high-energy cervical burst fracture/dislocation causing significant cord signal change on T2-weighted magnetic resonance imaging (MRI). These physical changes produced symptoms of neurologic impairment commonly seen in those patients with Brown-Séquard syndrome.

**Keywords:** *Brown-Séquard, cervical burst fracture, hemisection spinal cord*

### Introduction

This is a reported case of blunt trauma causing a high-energy cervical burst fracture/dislocation with a significant cord signal change producing Brown-Séquard syndrome.

The first clinical description of Brown-Séquard syndrome was published in the Edinburgh Medical Journal of 1825, which documented the neurological changes sustained by a patient after falling from a scaffolding.<sup>[1]</sup> However, it was not until 1860 that Brown-Séquard, in his book *Physiology of the Nervous System*, recreated symptoms by transversely dividing the lateral half an animal's dorsal vertebrae.<sup>[1]</sup> Brown-Séquard syndrome, while uncommon, is a neurological condition that classically results from the hemisection of the spinal cord as a result of a penetrating injury to the spinal cord. The condition is characterized by a lesion of the spinal cord that results in ipsilateral hemiparaplegia and ipsilateral loss of proprioceptive sensation due to the disruption of the corticospinal and ascending dorsal column tracts, respectively.<sup>[2]</sup> These tracts only decussate once in the medulla above the lesion leading to same-sided losses.<sup>[2]</sup> Contralateral loss of pain and

temperature sensations, a few dermatomes below the cord injury, is due to the lesion of the ascending lateral spinal thalamic tracts, which decussate one to two levels above the dorsal root entrance.<sup>[3]</sup>

### Case Report

A 25-year-old male presented to Mid-Atlantic level 1 trauma center following a motor vehicle accident with complaints of severe neck pain and left-sided weakness of the upper and lower extremities.

His neurological examination showed 4 out of 5 strength in his right deltoid, biceps, wrist extensor, triceps, finger flexors, interossei, hip flexors, quadriceps, tibialis anterior, extensor hallucis longus, and gastrocnemius muscle groups. His left side, however, yielded 0 out of 5 strength of the previously mentioned muscle groups. He was sensory intact to light touch throughout all distributions tested. Pinprick and pinch testing, however, were diminished throughout his entire right side. Rectal examination demonstrated voluntary contraction and relief of the sphincter. In the perianal region, he was able to discriminate between sharp and dull sensations on the left side, but not the right.

A computed tomography (CT) of the cervical spine showed a C5 burst fracture

**David Z. Cai,**  
**Geoffrey Liu<sup>1</sup>,**  
**Christopher F. Wolf<sup>2</sup>,**  
**Zachary M. Mansell<sup>1</sup>,**  
**Jonathan P. Eskander<sup>3</sup>,**  
**Mark Eskander<sup>1</sup>**

*Departments of Otolaryngology and <sup>3</sup>Anesthesiology, Tulane University, New Orleans, LA, <sup>1</sup>Delaware Orthopaedic Specialists, Wilmington, Delaware, <sup>2</sup>Sports and Spine Orthopaedics, Torrance, California, USA*

#### Address for correspondence:

*Dr. David Z. Cai,  
Department of Otolaryngology,  
Tulane Medical Center,  
1415 Tulane Ave, New Orleans,  
LA 70112, USA.  
E-mail: dcai@tulane.edu*

#### Access this article online

**Website:** [www.asianjns.org](http://www.asianjns.org)

**DOI:** 10.4103/1793-5482.224833

#### Quick Response Code:



**How to cite this article:** Cai DZ, Liu G, Wolf CF, Mansell ZM, Eskander JP, Eskander M. Brown-Séquard syndrome caused by blunt cervical trauma with radiographic correlation. *Asian J Neurosurg* 2018;13:130-2.

This is an open access article distributed under the terms of the Creative Commons Attribution-NonCommercial-ShareAlike 3.0 License, which allows others to remix, tweak, and build upon the work non-commercially, as long as the author is credited and the new creations are licensed under the identical terms.

**For reprints contact:** [reprints@medknow.com](mailto:reprints@medknow.com)

with significant angulation deformity and retropulsion of fragments posteriorly [Figures 1-3]. T2-weighted MRI at C5 showed a C5 burst fracture with spinal cord signal change at C3–C4 [Figure 4]. Because of the incomplete nature of the spinal cord injury, emergent operative decompression and stabilization followed. Anterior cervical corpectomy and fusion from C4 to C6 was performed with structural iliac crest allograft and Depuy Skyline instrumentation. This was followed by C4–C6 posterior cervical fusion with Depuy Mountaineer lateral mass screws and autologous iliac crest bone graft [Figure 5]. On postoperative day number 1, the patient was ambulatory with assistance but still had profound upper extremity weakness. At 3-week follow-up, he was ambulating without an assist device, was writing with his left hand, and had 4 out of 5 strength in all groups tested. He still had persistent sensory changes, an inability to feel sharp pain, and distinguish hot versus cold water. At final follow-up, the patient was 4 out of 5 in strength in his left deltoid and subjectively diminished hot and cold sensation on the right arm as compared to the left arm.

## Discussion

This is a unique case of a blunt trauma causing a high-energy cervical burst fracture/dislocation with significant cord signal change leading to Brown-Séquad syndrome. A review of 61 patients with Brown-Séquad syndrome due to a variety of causes all had a recovery of voluntary motor strength and functional gait within 6 months of the injury.<sup>[3]</sup> It appears that individuals with Brown-Séquad syndrome due to blunt trauma have the best prognosis.<sup>[4]</sup> The mechanism of recovery is attributed to the resolution of the conduction block in the injured axons as edema resolves, in addition to the contribution of the uninjured side of the cord.<sup>[5]</sup>

Other reported causes of nontraumatic causes of Brown-Séquad syndrome include arachnoid cysts, syringomyelia, hematomyelia, tumors such as meningiomas and metastatic small cell carcinoma, disc extrusion, vasculitis after heroin injection, decompression sickness due to mechanical obstruction of blood flow, epidural hematomas after anticoagulant therapy, and thrombolytic therapy.<sup>[6]</sup>

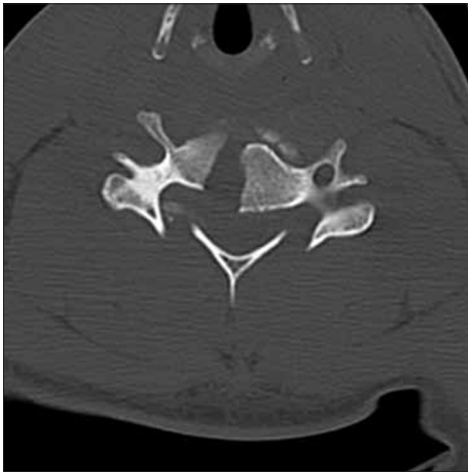


Figure 1: Preoperative axial computed tomography C5 burst fracture

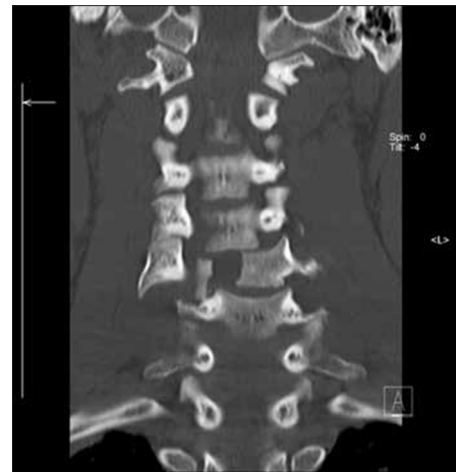

Figure 2: Preoperative coronal computed tomography of C5 burst fracture

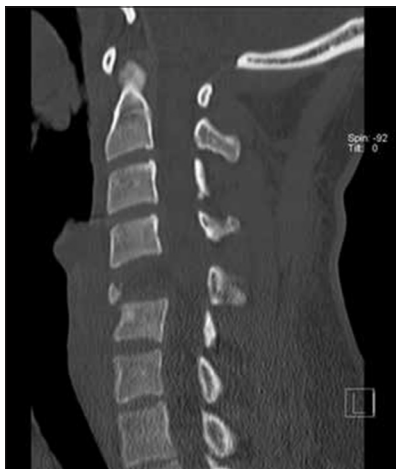

Figure 3: Preoperative sagittal computed tomography of C5 burst fracture

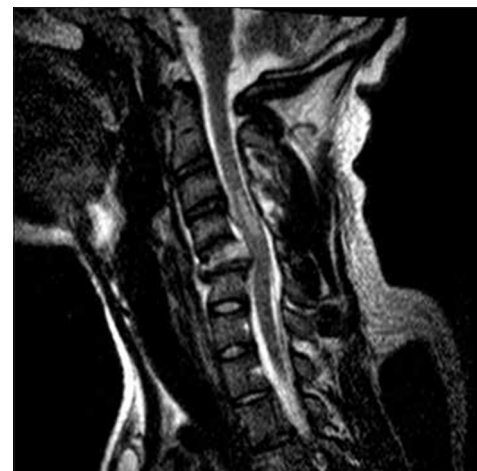
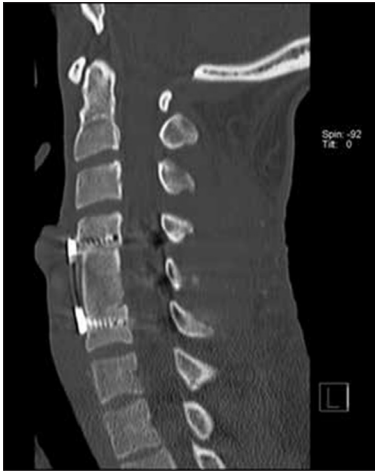
Figure 4: Preoperative sagittal T2-weighted magnetic resonance imaging of C5 burst fracture

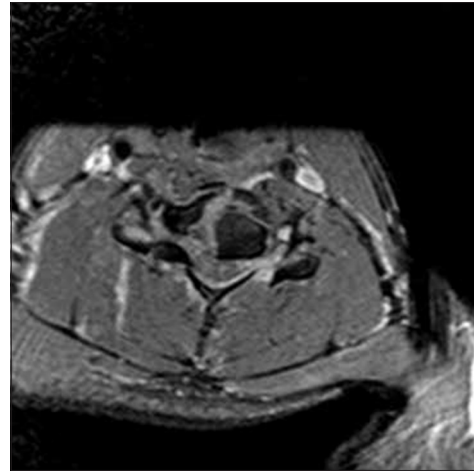


**Figure 5: Postoperative sagittal T2-weighted magnetic resonance imaging of C5 burst fracture**

Our patient was likely spared from a complete spinal cord injury because of the bilateral lamina fracture and wide coronal split and dislocation [Figure 2] that partially decompressed the spinal canal. The etiology of the unilateral spinal cord injury is best seen on the axial MRI [Figure 6] that demonstrates the fracture edge of the posterior aspect of the vertebral body driven into the left side of the spinal cord. While CT and plain radiographs play an important role in the initial management of spine-injured patients, MRI is considered superior in detecting the extent of spinal cord injury, spinal alignment, damage of the intervertebral discs, and involvement of the surrounding soft tissue.<sup>[3]</sup> Signal cord hyperintensity was noted on T2-weighted sagittal MRI suggestive of a contusion at the C4–C5 level [Figure 4].

Only a few cervical fractures from blunt trauma resulting in Brown-Séquard syndrome have been detailed in English literature. None has been observed in such a high-energy fracture/dislocation pattern. Despite the severity of the fracture, the patient recovered fully at 6 months follow-up. This underscores the importance of a standard treatment protocol for all incomplete spinal cord injuries related to cervical fractures. The patient's mean arterial pressure is kept at 85 mmHg or higher from the time of injury until 72 h postoperative. No steroids were administered, and emergent surgical decompression and stabilization occurred.

Some nuances in the neurological recovery are seen where a lower extremity recovery was first, and distal upper extremity groups recovered earlier function than the proximal groups. Recovery can occur within 24 h of the injury, but typically over the period of one to 6 months in extensors to flexors and proximal-to-distal fashion.<sup>[7]</sup>



**Figure 6: Preoperative axial T2-weighted magnetic resonance imaging C5 burst fracture**

## Conclusion

In this case, the burst fracture at the level of C5 obtained from the motor vehicle accident led to the damage of the left-sided lateral spinal thalamic tract, descending lateral cortical spinal tracts, and ascending dorsal column. This is a unique case of blunt nonpenetrating trauma leading to a high-energy cervical burst fracture/dislocation causing significant cord signal change on T2-weighted MRI. These physical changes produced symptoms of neurologic impairment commonly seen in those patients with Brown-Séquard syndrome.

## Financial support and sponsorship

Nil.

## Conflicts of interest

There are no conflicts of interest.

## References

1. Taylor RG, Gleave JR. Incomplete spinal cord injuries; with Brown-Sequard phenomena. *J Bone Joint Surg Br* 1957;39-B: 438-50.
2. Henderson S, Hoffner R. Brown-Séquard syndrome due to isolated blunt trauma. *Clin Commun* 1998;16:847-50.
3. Miranda P, Gomez P, Alday R, Kaen A, Ramos A. Brown-Sequard syndrome after blunt cervical spine trauma: Clinical and radiological correlations. *Eur Spine J* 2007;16:1165-70.
4. Oller DW, Boone S. Blunt cervical spine Brown-Séquard injury. A report of three cases. *Am Surg* 1991;57:361-5.
5. Duckler TB, Zeidman SM. Spinal cord injury. Role of steroid therapy. *Spine (Phila Pa 1976)* 1994;19:2281-7.
6. Kobayashi N, Asamoto S, Doi H, Sugiyama H. Brown-Séquard syndrome produced by cervical disc herniation: Report of two cases and review of the literature. *Spine J* 2003;3:530-3.
7. Little JW, Halar E. Temporal course of motor recovery after Brown-Sequard spinal cord injuries. *Paraplegia* 1985;23:39-46.