

# The role of endovascular therapy in acute mesenteric ischemia

Anna Maria Ierardi<sup>a</sup>, Dimitrios Tsetis<sup>b</sup>, Sara Sbaraini<sup>a</sup>, Salvatore Alessio Angileri<sup>a</sup>, Nikolaos Galanakis<sup>b</sup>, Mario Petrillo<sup>a</sup>, Francesca Patella<sup>a</sup>, Silvia Panella<sup>a</sup>, Federica Balestra<sup>a</sup>, Natalie Lucchina<sup>c</sup>, Gianpaolo Carrafiello<sup>a</sup>

University of Milan, San Paolo Hospital, Milan, Italy; University Hospital of Heraklion, School of Medicine, University of Crete, Crete, Greece; University of Insubria, Varese, Italy

## Abstract

**Background** Endovascular therapy, including aspiration thrombectomy and local thrombolytic therapy, often associated with angioplasty and stent placement, has been described in the literature. The purpose of this study was to review case series of patients with acute mesenteric ischemia treated with endovascular therapy and evaluate their outcomes.

**Methods** An online review using PubMed was carried out to identify all English articles about this topic in the time interval from 2005 to 2016. The following variables were extracted: number of patients, cause of occlusion, symptoms, arteries involved, number of sessions of treatment, technical success, clinical success, recurrence rate, complications, mortality rate, number of patients who underwent diagnostic laparoscopy or surgical resection of ischemic bowel.

**Results** Eighteen papers met the inclusion criteria and were included. Among the patients with arterial mesenteric ischemia treated with endovascular approach, the technical success rate was high (up to 100%) and data regarding clinical success are encouraging, even though they are few and heterogeneous. Technical success rate and clinical success of patients with acute venous mesenteric ischemia approached with endovascular treatment was 74-100% and 87.5-100% respectively.

**Conclusions** Current advances in endovascular therapies have made these treatments feasible for mesenteric ischemia.

**Keywords** Acute venous/arterial ischemia, interventional radiology, endovascular recanalization, thrombolysis, thromboaspiration

*Ann Gastroenterol* 2017; 30 (4): 526-533

<sup>a</sup>Department of Diagnostic and Interventional Radiology, University of Milan, San Paolo Hospital, Milan, Italy (Anna Maria Ierardi, Sara Sbaraini, Salvatore Alessio Angileri, Mario Petrillo, Francesca Patella, Silvia Panella, Federica Balestra, Gianpaolo Carrafiello); <sup>b</sup>Interventional Radiology Unit, Department of Medical Imaging, University Hospital of Heraklion, School of Medicine, University of Crete, Greece (Dimitrios Tsetis, Nikolaos Galanakis); <sup>c</sup>Unit of Interventional Radiology, Department of Radiology, University of Insubria, Varese, Italy (Natalie Lucchina)

Conflict of Interest: None

Correspondence to: Gianpaolo Carrafiello, Department of Diagnostic and Interventional Radiology, University of Milan, San Paolo Hospital, Via A. Di Rudini 8, 20142 Milan, Italy, Tel.: +39 335 6350002, e-mail: gcarraf@gmail.com

Received 25 November 2016; accepted 24 April 2017; published online 30 May 2017

DOI: <https://doi.org/10.20524/aog.2017.0164>

## Introduction

Vascular pathologies of the small and large bowel can be of venous or arterial etiology. Mesenteric ischemia is classified as acute (caused by thromboembolism or hypoperfusion) or chronic. The development of imaging technology has gradually increased the diagnostic rate of venous or arterial mesenteric ischemia. The standard care used to be open surgical repair, but in the last 15 years the development of endovascular procedures has introduced a minimally invasive treatment option [1]. In both chronic and acute settings, angioplasty and stenting have been successfully described for management of stenoses or occlusions [2].

Nowadays, apart from percutaneous transluminal angioplasty (PTA) and stenting, other endovascular techniques are available, including the use of intra-arterial thrombolysis, vasodilators

and suction embolectomy. Endovascular therapy can potentially modify clinical outcomes in patients with acute bowel ischemia; however, given the relative infrequency of this disease, it is hard to obtain wide experience over a relatively short interval and only small case series are available in the literature.

The objective of this study was to review the management of acute mesenteric ischemia (AMI) with endovascular procedures and to determine the efficacy and recanalization rates, the incidence of complications, and the mortality, in order to provide an update on the current concepts in the management of this disease.

## Materials and methods

### Search and selection process

A comprehensive search of the English-language published literature was carried out through PubMed to identify all articles reporting acute arterial and venous mesenteric ischemia treated by endovascular therapy. The research was performed using the following medical subject headings (MeSH): “endovascular therapy and acute arterial mesenteric ischemia”, “endovascular therapy and mesenteric infarction”, “endovascular therapy and interventional radiology and acute mesenteric ischemia”, “endovascular recanalization and acute mesenteric ischemia”, “thrombolysis and thromboaspiration and acute mesenteric ischemia”, “stenting and angioplasty and acute mesenteric ischemia”, “endovascular therapy and acute venous mesenteric ischemia and occlusion”, “acute venous mesenteric ischemia and interventional radiology”, “acute venous mesenteric ischemia and endovascular recanalization”, “acute venous mesenteric ischemia and thrombolysis and thromboaspiration”.

At the first stage, only titles and abstracts were reviewed to select articles focusing on patients with AMI who had venous or arterial occlusion treated with endovascular therapies. Case reports, small series revisions and papers that contained data reported previously were excluded. At the second stage, all articles selected were reviewed in their full text version.

Articles were considered eligible for inclusion in the present review if at least one outcome of interest was described. In studies involving patients treated with a surgical or endovascular approach, only those treated by endovascular therapy were extracted. Additional studies were identified through manual research of the bibliographies from primary studies, review articles, and key journals.

### Data extraction and analysis

Patients were assigned to acute arterial or acute venous ischemia groups, according to the nature of the mesenteric ischemia. The following variables were extracted, when available, from the included articles: number of patients, cause of occlusion, symptoms, arteries involved, number of sessions of treatment, technical success, clinical success, recurrence rate, complications, mortality rate, number of patients who

underwent diagnostic laparoscopy or surgical resection of ischemic bowel. Data are reported as described in the studies: authors sometimes reported a range and/or a median value; sometimes a rate and/or a value is reported. Information not mentioned was classified as not available.

Before the extraction of data from the eligible studies, the following clear definitions of all outcomes of interest were established. *Clinical success* was defined as the frequency of successful treatment in each study. *Technical success* was defined as the restoration of flow in the treated vessels and their branches on the final angiogram, without any need for further re-intervention (endovascular or vascular surgical intervention), as clearly mentioned in each manuscript. Sometimes, particularly in acute thrombolysis, more sessions were necessary: in this latter case the final result was reported. *Mortality* was defined as early death before discharge due to persistent ischemia, complications related to persistent ischemia, or hemorrhagic complications related to massive anticoagulant therapy.

## Results

Eighteen papers met the inclusion criteria and were included in this systematic review. All the data collected by 12 studies focusing on acute arterial mesenteric ischemia are summarized in Table 1 [2-14], and the data obtained from 6 papers focusing on acute venous mesenteric ischemia are presented in Table 2 [15-20]. In Tables we analyzed all studies published during the selected period (2005-2016).

### Endovascular treatment of acute arterial mesenteric ischemia

AMI was predominantly caused by arterial emboli from cardiac arrhythmias (40-50%), thrombosis at preexisting lesions (25%) and other non-occlusive causes. The superior mesenteric artery (SMA) is the commonest site of thromboembolic occlusion, because of its oblique origin from the aorta [21]. Abdominal pain, vomiting and nausea were the most common presenting symptoms.

On the basis of the data in Table 1 [2-14], the technical success rate is high (up to 100%) and data regarding clinical success are encouraging, even though they are few and heterogeneous. The main reason for these different results is the heterogeneity of patients and their characteristics (age, clinical history, performance status, etc.) from center to center.

The study of Arthurs *et al* [8] represents the largest series of patients with AMI treated with endovascular therapy in one center. The investigators excluded patients with mesenteric venous thrombosis, non-occlusive mesenteric ischemia or ischemia associated with aortic dissection. They retrospectively evaluated 70 patients with AMI in whom endovascular revascularization was the preferred treatment (81%). The primary technique was thrombolysis infusion, which was used in 48% of the population. Thirty-two percent of patients were treated with primary PTA and stenting. Aspiration thrombectomy in conjunction with

thrombolysis was performed in 12% of patients. Successful endovascular treatment was achieved in 87% of cases, and the mortality rate was 36%, compared with 50% ( $P < 0.05$ ) in patients treated with traditional therapy.

Acute renal failure, myocardial and cerebral infarctions, bowel ischemia and short bowel syndrome are the most common complications reported in literature.

Potential complications related to the endovascular procedure include access-related bleeding (e.g. hematoma, pseudoaneurysm) and vessel trauma that can lead to arterial dissection or atheroembolization. The use of distal embolic protection devices may mitigate the risk of bowel necrosis as a consequence of distal embolization, but there is a lack of data concerning their efficacy in the mesenteric circulation.

### Endovascular treatment of acute venous mesenteric ischemia

Among the cases of AMI, mesenteric vein thrombosis (MVT) has an incidence of 6-9%, and the vein mainly involved is the superior mesenteric vein (SMV) [22].

In Table 2 [15-20] we present the literature from patients treated via an endovascular approach. So far, only small series are available; only a little over 100 patients have been treated. In the majority of published case series, the primary treatment was local thrombolysis; Wichman *et al* [18] treated 8 patients with symptomatic portomesenteric venous occlusion, using endovascular procedures such as aspiration thrombectomy, thrombolysis and stent placement.

On the basis of the few data available, the technical success rate has been reported to be between 74% and 100%. When reported, the clinical success rate is high (87.5-100%), with a low recurrence rate.

The most common complication is hemorrhage; some cases of sepsis were also described.

In most cases a surgical revision was performed and in some cases bowel resection was necessary.

### Discussion

A key goal of endovascular therapy in AMI is to rapidly reestablish flow into the proximal arterial segments. The most appropriate therapy should be tailored according to the clinical symptoms, laboratory values and computed tomography (CT) findings. In some studies, primary endovascular therapy is applied with on-demand laparotomy for patients with mild or moderate clinical or laboratory signs of peritonitis [14]. Under these conditions, thrombolysis is associated with a greater risk of major bleeding from necrotic bowel. Thrombolytic therapy also increases the risk of potential early surgical revision. These represent the main reasons why adjunctive therapy was not applied in some studies. Series in which patients presented with early mesenteric ischemia recommend thrombolysis. Despite modern advances in current medicine, the early diagnosis of intestinal ischemia is still very difficult. In our daily practice, we often encounter patients with advanced mesenteric ischemia.

The most common percutaneous methods for AMI are aspiration thrombectomy, in which thrombus/embolus is removed by suction, and mechanical thrombectomy, using different automated devices for the fragmentation and removal of embolus [23]. Mechanical thrombectomy involves aspiration of embolus and massive thrombosis using a 6-Fr guiding catheter. Other thrombectomy techniques include: mechanical removal of the thrombus with the Rotarex system (Straub Medical AG, Wangs, Switzerland) or the Penumbra system [24], thrombolysis with a rheolytic system [25], or pharmacologic thrombolysis using the EKOS catheter [26,27]. Catheter-directed thrombolysis with urokinase is utilized if aspiration thrombectomy did not resolve the thrombus [28-30,13].

Balloon angioplasty is an alternative technique for clot fragmentation in cases of resistant thrombus. Published cases using percutaneous thrombectomy, with or without PTA, are rather low in number, but the results seem encouraging [31,32].

After removal of a thrombotic clot by aspiration, thrombolysis or angioplasty, treatment of the underlying stenotic or occlusive lesions can be achieved during the same session. Angioplasty and stenting, if performed early, have been shown to prevent intestinal infarction and obviate the need for laparotomy [33,34]. The hybrid approach facilitates endovascular intervention and represents a useful technique for the management of patients with AMI who require emergency laparotomy [35,36].

Wyers *et al* [3] drew attention to the benefits of combining laparotomy (direct bowel examination to confirm viability) with endovascular intervention (avoid the need for bypass grafting), particularly for patients who would otherwise require open surgical revascularization.

In cases of embolism, after the initial aspiration has failed, Raupach *et al* [14] currently tend to use direct surgical embolectomy of the SMA trunk and resection of necrotic bowel parts. This approach saves time and prevents a delayed diagnosis of bowel necrosis.

Acute embolic occlusion seems to be more suitable for thrombolytic therapy than thrombotic occlusions, because emboli typically are dislodged to the periphery of the SMA in an atherosclerosis-free segment and local pharmacologic thrombolysis has the potential to dissolve the clot completely, with minimal trauma to the occluded artery [37] (Fig. 1, A, B, C).

Successful recanalization does not preclude laparotomy to check or resect the intestine. Dead bowel has to be resected before the patient falls into profound septic shock [36].

### Endovascular treatment of acute venous mesenteric ischemia

Despite the lack of specific biomarkers or any insidious symptomatology profile, the incidence of acute superior mesenteric venous thrombosis (ASMVT) has increased in relation to the spread of contrast-enhanced CT; the portography phase facilitates early diagnosis with over 90% sensitivity [38].

As the overall mortality is still high (13-50% with traditional anticoagulation and bowel resection), the management of ASMVT remains a great clinical challenge [15]. In the literature, mortality ranged from 29-38% for surgical treatment and from 13-19% for non-operative management [39].

**Table 1** Acute mesenteric arterial ischemia

Study	N° patients	Cause occlusion			Symptoms	Arteries involved	Primary treatment		
		Emboli	Thrombosis	Other			Thrombolysis	Thrombectomy	PTA/stent
Lim 2005 [2]	3	0%	33% (1)	66% (2)	Acute abdominal pain 100%, Nausea 33%, Vomiting 33%, Diarrhea 33%, Hematemesis 33%, Melena 33%	SMA	33% (1)	0%	66% (2)
Wyers 2007 [3]	2	0%	100%	0%	NS	SMA	NS	NS	100%
Acosta 2009 [4]	21	48% (10)	52% (11)	0%	NS	SMA	10% (2)	38% (8)	24% (5)
Schermerhorn (2000-2006) 2009 [5]	1857	NS			NS	NS	0%	0%	100%
Block 2010 [6]	42	29% (12)	62% (26)	9% (4)	Abdominal pain, Vomiting, Diarrhea, Hematochezia	SMA	NS		
Bjornsson 2011 [7]	34	82% (28)	18% (6)	0%	Acute abdominal pain 30% (10), Sudden abdominal pain 36% (12), Bloody stools 3% (1), Diarrhea 36% (12), Vomiting 62% (21), Atrial fibrillation 62% (21)	SMA	100%	0%	0%
Arthurs 2011 [8]	56	35%	65%	0%	Abdominal pain 92%, Nausea 69%, Emesis 51%, Bloody diarrhea 31%	SMA 66%, SMA+ celiac artery 34%	48%	11%	32%
Ryer* 2012 [9]	11	31% (29)	54% (50)	0-6%	Abdominal pain (91-98%), Abdominal tenderness (58-79%), Diarrhea (38-23%), Nausea (42-38%), Vomiting (36-27%), LGIB (16-13%)	SMA +- celiac artery	67% (2)-25% (2)	0-13%	33% (1)-62.5% (5)
Beaulieu 2014 [10]	165	NS	NS	NS	Lactic acidosis 11.4%, ARDS 7%, SIRS 5.9%, Hypotension 4.9%	NS	NS		
Jia 2014 [11]	21	NS	NS	NS	Abdominal pain and no evidence of advanced bowel ischemia sign	SMA	0%	100%	0%
Barrera 2015 [12]	9	33%	45%	22%	No peritoneal irritation	Small intestine	18%	NS	NS
Karkkainen 2015 [13]	50	36% (18)	64% (32)	0%	Abdominal pain 94%, Abdominal distension 26%, Diarrhea 48%, Vomiting 56%, Paralytic ileus 20%, GI bleeding 14%, Acute kidney injury 6%, Clinical features of peritonitis 14%	SMA, SMA + celiac artery, SMA + IMA	0%	40% (20)	60% (30)
Raupach 2016 [14]	37	100%	0%	0%	Abdominal pain Diarrhea, Bloody diarrhea, Nausea, Emesis	SMA	0%	100%	0%

\*1990s-2000s

PTA, percutaneous transluminal angioplasty; LPT, laparotomy; LPS, laparoscopy; NS, not specified; SMA, superior mesenteric artery; ET, endovascular therapy; TIA, transient ischemic Attack; GI, gastrointestinal; ARDS, acute respiratory disease syndrome; SIRS, systemic inflammatory response syndrome

Table 1: (Continued)

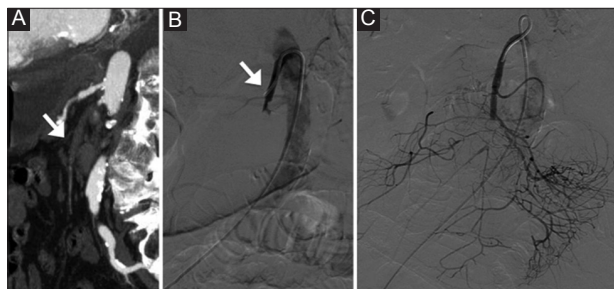
Secondary treatment			Technical succ	Clinical succ	Recurrence rate	Complications	Mortality	Lpt/Lps and/or resection		
Thrombolysis	Thrombectomy	PTA/Stent						LPT	LPS	Resection
NS			100% (3)	66% (2)	0%	Ischemic hepatitis 33% (1) Acute renal failure 33% (1) Malnutrition 33% (1)	0%	33% (1)	0%	33% (1)
NS			100%	NS	NS	NS	100%	0%	0%	100%
25% (2)	NS	NS	NS	NS	NS	SMA dissection distal emboli in arterial branch	14% (3)	67% (14)	8% (1)	43% (9)
NS			NS	NS	NS	Acute renal failure 11.4%, Acute myocardial infarction 5%, Cardiac 2.1% Stroke 1%, Peripheral vascular 0.5%, respiratory 1.1% Hemorrhage 2.4%	16%	NS	NS	28%
NS			79%	NS	NS	Groin hematoma (2) Renal embolization (1) Femoral artery occlusion (1)	27%	73% (27)	0%	40.5% (15)
0%	35.2% (12)	8.8% (3)	88%	NS	NS	Bleeding complication 15% (5)	26% (9)	38% (13)	0%	24%(8)
0%	12% (of thrombolysis)	33% (of thrombolysis) 22% (of thrombectomy)	87%	NS	NS	Acute renal failure 27% pulmonary failure 27% Myocardial infarction 2% GI bleeding 7%	36% ET success 50% ET failure	31%	NS	NS
NS			NS	NS	1%	Overall 73-63% Pulmonary 16-32% Renal 12% Neurologic (TIA/stroke) 5-2% GI 7-26%	17%-27%	63% (7)	NS	45% (5)
NS			NS	Survival 39.9%	NS	NS	24.9%	NS	NS	14.4%
28.6% (6)	NS	NS	Cerebral infarction 5% (1) short bowel syndrome 5% (1)	9.5% (2)	29% (6)	NS	24% (5)	-	-	-
NS	33.3% (3/9)	ET+Chir 67% (6)	NS	NS	NS	NS	33.3% (3)	NS	NS	33.3% (3)
NS			88% (44)	NS	NS	Access site bleeding 4% (2), Intra abdominal bleeding 2% (1), New GI bleeding 10% (5), Stroke 2% (1), Myocardial infarction 4% (2) Heart failure 12% (6) Acute kidney injury 8% (4) Pulmonary failure 4% (2)	30%	40%	NS	34%
5% (2)	0%	5% (2)	91.9%	NS	NS	Groin hematoma 5.4% (2) Renal embolization 3% (1) Femoral artery occlusion 3% (1)	27%	73% (27)	NS	40.5% (15)

**Table 2** Acute mesenteric venous thrombosis

Study	N° patients	Cause occlusion: thrombotic	Symptoms	Involved veins	Primary treat		
					Thrombolysis	Thrombectomy	PTA /stent
Liu, 2009 [15]	46	100% (46)	NS	PV, SMV	100% (46)	0%	0%
Wang 2011 [16]	12	66,6% (8)	Severe/mild abdominal pain, Distension, Nausea, Vomiting, Diarrhea, Melena, Anorexia	SMV 100%	100% (12)	0%	0%
Wichman 2014 [17]	8	100% (8)	Abdominal pain, Ascites, GI bleeding, Cholangitis	SMV =100% (8) SMV+PV= 62.5% (5) SMV+SV=25% (2)	12.5% (1)	50% (4)	
Yang 2014 [18]	13	100% (13)	NS	SMV 100%	100% (13)	0%	0%
Yang* 2015 [19]	19	100% (9)	Abdominal pain, Anorexia, Distension, Nausea, Vomiting, Diarrhea, Constipation, GI bleeding, Peritonitis, Fever	SMV= 41.86% SMV+PV =46.51% SMV+PV+SV=11.63%	100% (19)	0%	0%
Yang 2015 [20]	8	100% (8)	Abdominal pain, Distention, Ascites, Lumbodorsal pain, Peritonitis, Constipation, Fever, Diarrhea, Nausea, Emesis, Hematemesis, Hematochezia	IVC+SMV+PV=25% (2) SMV+PV=25% (2) SMV+PV+SV=25% (2)	100% (8)	0%	0%

\*All data refer to surgical and endovascular treatments

PTA, percutaneous transluminal angioplasty; LPT, laparotomy; LPS, laparoscopy; NS, not specified; SMV, superior mesenteric vein; PV, portal vein; SV, splenic vein; IVC, inferior vena cava; ARDS, acute respiratory distress syndrome; TIPS, transjugular intrahepatic portosystemic shunt



**Figure 1** (A) Maximum intensity projection sagittal reconstruction of the contrast-enhanced computed tomography revealed thrombosis of the superior mesenteric artery (SMA) (arrow). (B) Angiography confirmed complete thrombosis of the SMA, with the tip of the catheter for local thrombolysis localized proximally to the thrombosis (arrow). (C) The angiogram obtained after thrombolysis showed acceptable revascularization of the artery and of its branches

Systemic anticoagulation is of uncertain value, because it is associated with extrahepatic portal vein hypertension (25%), transmural bowel infarction (18%) and an elevated risk of bleeding [40]. In recent years, catheter-directed thrombolysis, combined with local anticoagulation and endovascular thrombectomy, has been introduced as a minimally invasive

treatment option to dissolve thrombus and rapidly restore SMV flow. This procedure may be performed directly (percutaneous transhepatic and transjugular intrahepatic), or indirectly, via an SMA approach [15]. Nevertheless, endovascular therapy in MVT carries a significant risk of complications and, although it can be life-saving in cases of severe ischemia (intense pain, bowel swelling and edema), the management should usually be stepwise, starting with low-molecular-weight heparin or heparin infusion, and followed by endovascular procedure if the patient's condition does not improve or deteriorates [39,40].

Aspiration thrombectomy, combined with angioplasty and/or stenting, is more frequently used as a secondary treatment. Rapid thrombus dissolution can be achieved by transjugular intrahepatic portosystemic shunt to create a low-pressure runoff in patients with acute superior mesenteric venous thrombosis, ascites or coagulation disorder [17].

Early detection is crucial for a correct endovascular or combined approach.

Emergent laparotomy is imperative with evidences of transmural bowel infarction and peritonitis [15]. In patients with no evidence of bowel infarction or perforation, transcatheter thrombolysis and aspiration thrombectomy may be proposed. Laparoscopic examination may be performed

Table 2: (Continued)

Secondary treat			Technical success	Clinical success	Recurrence rate	Complications	Mortality	Lpt/Lps and/or resection		
Thrombolysis	Thrombectomy	PTA/stent						LPT	LPS	Resection
NS	NS	NS	74% (34)	NS	6.5% (3)	NS	2% (1)	NS	NS	2% (1)
NS	NS	NS	100% (12)	100% (12)	0%	Small hematoma at puncture site 25% (3)	0%	NS		
37.5% (3)	0%	7 SMV 6 PV 2 SV 4 TIPS	100% (8)	87.5% (7)	NS	Splenic hemorrhage 12.5% (1) Mesenteric vein perforation 12.5% (1)	12.5% (1)	NS		
NS	NS	NS	84.6% (11)	NS	0%	0%	0%	NS	30.7% (4)	30.7% (4)
0%	51% (22)	14% (6)	79% 94,44%	NS	7% (3)	Sepsis 18.6% (8) Acute compartmental Syndrome 11.6% (5) Pneumonia 18.6% (8) ARDS 11.6% (5) Acute kidney injury 16.3% (7) Recurrent ischemia 9.3% (4) GI bleeding 11.6% (5) Short bowel syndrome 14% (6) Hemoperitoneum 9.3% (4) Catheter insertion site bleeding 7% (3) Incision site bleeding 7% (3)	16.3% (10)	23% (10)	NS	18.6% (8)
0%	100% (8)	0%	100% (8)	100% (8)	0	Bleeding and flare at puncture site 25% (2) Fever 25% (2) Sepsis 25% (2)	0%	25% (2)	NS	50% (4)

after initiation of thrombolytic therapy. This treatment option decreases the risk of short-bowel syndrome due to extensive bowel resection and unnecessary laparotomy, which is a bad prognostic factor in compromised patients.

On the basis of the heterogeneity of the studies published, the indications for the combination of systemic anticoagulation and loco-regional thrombolysis are not easily deduced; bleeding complications (encephalic, gastrointestinal tract, etc.) were observed more frequently in patients who underwent systemic anticoagulation after previously being treated with endovascular thrombolysis. Literature data and clinical practice show that the indication for systemic anticoagulation usually depends on the causes of the acute event (embolic or not) and in some cases it is not possible to avoid systemic therapy and its risks. In these patients (usually compromised and at high risk for further therapies) endovascular therapy represents a life-saving treatment [41]. Mortality is reported in almost all the articles examined, but the causes of death are not always indicated. Selection bias in the patient populations influences the mortality rate, which varies from center to center. There are no treatment protocols or international guidelines for AMI. Considering the low incidence, as well as the constant evolution of therapeutic techniques, it is hard to conduct a large-scale, randomized, controlled trial.

In conclusion, the analysis of the data presented here proves the feasibility of the endovascular procedures with encouraging results. Most of these studies show lower bowel morbidity and lower mortality after endovascular therapy compared with

open surgery. In the future, more studies are necessary to assess long-term outcomes and to outline detailed indications regarding the type of treatment (thromboaspiration and/or thrombolysis) and association with systemic therapy.

## References

- Resch T, Lindh M, Dias N, et al. Endovascular recanalisation in occlusive mesenteric ischemia—feasibility and early results. *Eur J Vasc Endovasc Surg* 2005;**29**:199-203.
- Lim RP, Dowling RJ, Mitchell PJ, Vrazas JI, Thomson KR, Tress BM. Endovascular treatment of arterial mesenteric ischaemia: a retrospective review. *Australas Radiol* 2005;**49**:467-475.
- Wyers MC, Powell RJ, Nolan BW, Cronenwett JL. Retrograde mesenteric stenting during laparotomy for acute occlusive mesenteric ischemia. *J Vasc Surg* 2007;**45**:269-275.
- Acosta S, Sonesson B, Resch T. Endovascular therapeutic approaches for acute superior mesenteric artery occlusion. *Cardiovasc Intervent Radiol* 2009;**32**:896-905.
- Schermerhorn ML, Giles KA, Hamdan AD, Wyers MC, Pomposelli FB. Mesenteric revascularization: management and outcomes in the United States, 1988-2006. *J Vasc Surg* 2009;**50**:341-348.
- Block TA, Acosta S, Björck M. Endovascular and open surgery for acute occlusion of the superior mesenteric artery. *J Vasc Surg* 2010;**52**:959-966.
- Björnsson S, Björck M, Block T, Resch T, Acosta S. Thrombolysis for acute occlusion of the superior mesenteric artery. *J Vasc Surg* 2011;**54**:1734-1742.

## Summary Box

### What is already known:

- Feasibility of endovascular treatment in acute bowel ischemia has been reported in the available literature

### What the new findings are:

- Endovascular therapy in acute mesenteric ischemia shows high technical and clinical success rates with few complications
- No treatment has proven superiority over the rest in acute mesenteric ischemia
- No superiority of a treatment compared to another is still showed

- Arthurs ZM, Titus J, Bannazadeh M, et al. A comparison of endovascular revascularization with traditional therapy for the treatment of acute mesenteric ischemia. *J Vasc Surg* 2011;**53**:698-704.
- Ryer EJ, Kalra M, Oderich GS, et al. Revascularization for acute mesenteric ischemia. *J Vasc Surg* 2012;**55**:1682-1689.
- Beaulieu RJ, Arnaoutakis KD, Abularrage CJ, Efron DT, Schneider E, Black JH 3<sup>rd</sup>. Comparison of open and endovascular treatment of acute mesenteric ischemia. *J Vasc Surg* 2014;**59**:159-164.
- Jia Z, Jiang G, Tian F, et al. Early endovascular treatment of superior mesenteric occlusion secondary to thromboemboli. *Eur J Vasc Endovasc Surg* 2014;**47**:196-203.
- Serracant Barrera A, Luna Aufroy A, Hidalgo Rosas JM, et al. Acute mesenteric ischemia: Utility of endovascular techniques. *Cir Esp* 2015;**93**:567-572.
- Kärkkäinen JM, Lehtimäki TT, Saari P, et al. Endovascular therapy as primary revascularization modality in acute mesenteric ischemia. *Cardiovasc Intervent Radiol* 2015;**38**:1119-1129.
- Raupach J, Lojik M, Chovanec V, et al. Endovascular management of acute embolic occlusion of the superior mesenteric artery: a 12-year single-centre experience. *Cardiovasc Intervent Radiol* 2016;**39**:195-203.
- Yang S, Liu B, Ding W, He C, Wu X, Li J. Acute superior mesenteric venous thrombosis: transcatheter thrombolysis and aspiration thrombectomy therapy by combined route of superior mesenteric vein and artery in eight patients. *Cardiovasc Intervent Radiol* 2015;**38**:88-99.
- Liu FY, Wang MQ, Fan QS, Duan F, Wang ZJ, Song P. Interventional treatment for symptomatic acute-subacute portal and superior mesenteric vein thrombosis. *World J Gastroenterol* 2009;**15**:5028-5034.
- Wang MQ, Liu FY, Duan F, Wang ZJ, Song P, Fan QS. Acute symptomatic mesenteric venous thrombosis: treatment by catheter-directed thrombolysis with transjugular intrahepatic route. *Abdom Imaging* 2011;**36**:390-398.
- Wichman HJ, Cwikel W, Keussen I. Interventional treatment of mesenteric venous occlusion. *Pol J Radiol* 2014;**79**:233-238.
- Yang SF, Liu BC, Ding WW, He CS, Wu XJ, Li JS. Initial transcatheter thrombolysis for acute superior mesenteric venous thrombosis. *World J Gastroenterol* 2014;**20**:5483-5492.
- Yang S, Fan X, Ding W, et al. Multidisciplinary stepwise management strategy for acute superior mesenteric venous thrombosis: an intestinal stroke center experience. *Thromb Res* 2015;**135**:36-45.
- Oldenburg WA, Lau LL, Rodenberg TJ, Edmonds HJ, Burger CD. Acute mesenteric ischemia: a clinical review. *Arch Intern Med* 2004;**164**:1054-1062.
- Singal AK, Kamath PS, Tefferi A. Mesenteric venous thrombosis. *Mayo Clin Proc* 2013;**88**:285-294.
- Kuhelj D, Kavcic P, Popovic P. Percutaneous mechanical thrombectomy of superior mesenteric artery embolism. *Radiol Oncol* 2013;**47**:239-243.
- Popovič P, Kuhelj D, Bunc M. Superior mesenteric artery embolism treated with percutaneous mechanical thrombectomy. *Cardiovasc Intervent Radiol* 2011;**34** Suppl 2:S67-S69.
- Sternbergh WC 3<sup>rd</sup>, Ramee SR, DeVun DA, Money SR. Endovascular treatment of multiple visceral artery paradoxical emboli with mechanical and pharmacological thrombolysis. *J Endovasc Ther* 2000;**7**:155-160.
- Ballehaninna UK, Hingorani A, Ascher E, et al. Acute superior mesenteric artery embolism: reperfusion with AngioJet hydrodynamic suction thrombectomy and pharmacologic thrombolysis with the EKOS catheter. *Vascular* 2012;**20**:166-169.
- Zeleňák K, Sinák I, Janík J, Míkolajčík A, Mištuna D. Successful recanalization of acute superior mesenteric artery thromboembolic occlusion by a combination of intraarterial thrombolysis and mechanical thrombectomy with a carotid filter. *Cardiovasc Intervent Radiol* 2013;**36**:844-847.
- Yang HJ, Cho YK, Jo YJ, Jung YY, Choi SA, Lee SH. Successful recanalization of acute superior mesenteric artery thrombotic occlusion with primary aspiration thrombectomy. *World J Gastroenterol* 2010;**16**:4112-4114.
- Heiss P, Zorger N, Kaempfe I, et al. [Stenting in the treatment of chronic mesenteric ischemia: technical and clinical success rates]. *Rofo* 2008;**180**:906-914.
- Kawasaki R, Miyamoto N, Oki H, et al. Aspiration therapy for acute superior mesenteric artery embolism with an angled guiding sheath and guiding catheter. *J Vasc Interv Radiol* 2014;**25**:635-639.
- Kawarada O, Sonomura T, Yokoi Y. Direct aspiration using rapid-exchange and low-profile device for acute thrombo-embolic occlusion of the superior mesenteric artery. *Catheter Cardiovasc Interv* 2006;**68**:862-866.
- Nishida A, Fukui K. Images in clinical medicine. Transcatheter treatment of thromboembolism in the superior mesenteric artery. *N Engl J Med* 2005;**353**:e4.
- Demirpolat G, Oran I, Tamsel S, Parildar M, Memis A. Acute mesenteric ischemia: endovascular therapy. *Abdom Imaging* 2007;**32**:299-303.
- Gartenschlaeger S, Bender S, Maeurer J, Schroeder RJ. Successful percutaneous transluminal angioplasty and stenting in acute mesenteric ischemia. *Cardiovasc Intervent Radiol* 2008;**31**:398-400.
- Moyes LH, McCarter DH, Vass DG, Orr DJ. Intraoperative retrograde mesenteric angioplasty for acute occlusive mesenteric ischaemia: a case series. *Eur J Vasc Endovasc Surg* 2008;**36**:203-206.
- Branco BC, Montero-Baker MF, Aziz H, Taylor Z, Mills JL. Endovascular therapy for acute mesenteric ischemia: an NSQIP analysis. *Am Surg* 2015;**81**:1170-1176.
- Heiss P, Loewenhardt B, Manke C, et al. Primary percutaneous aspiration and thrombolysis for the treatment of acute embolic superior mesenteric artery occlusion. *Eur Radiol* 2010;**20**:2948-2958.
- Morasch MD, Ebaugh JL, Chiou AC, Matsumura JS, Pearce WH, Yao JS. Mesenteric venous thrombosis: a changing clinical entity. *J Vasc Surg* 2001;**34**:680-684.
- Brunaud L, Antunes L, Collinet-Adler S, et al. Acute mesenteric venous thrombosis: case for nonoperative management. *J Vasc Surg* 2001;**34**:673-679.
- Bergqvist D, Svensson PJ. Treatment of mesenteric vein thrombosis. *Semin Vasc Surg* 2010;**23**:65-68.
- Zhao Y, Yin H, Yao C, et al. Management of acute mesenteric ischemia: a critical review and treatment algorithm. *Vasc Endovascular Surg* 2016;**50**:183-192.