



Late-onset calcinosis in burn scars: A review of the literature and two case reports

Lili Róbert, Enikő Kuroli, Gyula Bottlik, Bernadett Hidvégi

Department of Dermatology, Venereology and Dermatocology, Faculty of Medicine, Semmelweis University, Budapest, Hungary

Summary

Calcinosis cutis is a heterotopic accumulation of calcium salts in the skin. It has been described as a late-onset complication of burn scars in a few cases, in contrast to heterotopic ossification, which may be an early-onset complication of burn injuries. Diagnosis of calcinosis can be confirmed by radiography, ultrasonography, computed tomography, magnetic resonance imaging or histology. Almost all cases of late-onset calcinosis in burn scars present as non-healing ulcers on the lower extremities near contracture bands. It has been hypothesized that this localization is due to the more frequent microtrauma of the lower extremities, and that ulceration is due to the presence of calcium deposits as foreign bodies. In our study, the mean age at the time of burn injury was 12.5 ± 8.27 years, and calcinosis developed after a mean time of 37.5 ± 14.95 years (mean age at onset was 50.5 ± 14.53 years). There was no significant difference between burn scars managed with skin grafting and those where skin grafting was not carried out. The ulcers healed after resection or extraction of the deposits without any recurrence at the same site. In contrast to previously reported cases, we observed two cases of non-ulcerating late-onset calcinosis in burn scars of the upper extremities.

Introduction

Calcinosis is a heterotopic accumulation of calcium salts (hydroxyapatite crystals and amorphous calcium phosphate) [1] in soft tissues. It can be subdivided into four subtypes. The dystrophic subtype is caused by calcium deposition in areas of tissue damage (e.g. trauma, connective tissue diseases, neoplasms); the metastatic subtype is due to altered calcium and phosphate homeostasis; the iatrogenic subtype is an undesirable side effect of medical care (e.g. extravasation of calcium-containing solutions), and the idiopathic subtype is of unknown origin. The most common subtype is the dystrophic one, especially calcinosis related to autoimmune connective tissue diseases [1]. Calcinosis has also been reported as a rare, late-onset complication of extensive burn scars [2]. It may be classified as dystrophic calcification in the absence of alterations in serum calcium and phosphate levels. The diagnosis of burn scar calcinosis may be confirmed by

radiography, ultrasonography, computed tomography, magnetic resonance imaging or histology.

In this paper, we review case reports and review articles related to burn-associated calcification that were available in English on the Pubmed®, Scopus®, Web of Science®, and Google Scholar® databases, and provide a meta-analysis of the patient data. The articles included in this work contain relevant data on burn calcinosis cases. Reports of ossification after burns and accounts where the term “calcinosis” was used inconsistently as a synonym for “ossification” were excluded. The following keywords were searched for: calcinosis, calcification, soft tissue calcification, burn, burn scar, and burn keloid.

Epidemiology

The exact epidemiology of calcinosis is still unknown. Kolář et al. reported a 3.3 % incidence of early-onset calcinosis occurring within five weeks to two years after burns [3].

Munster et al. observed a high incidence of early-onset calcification of the arms in a prospective study, with a frequency of 22 % of third-degree burns and 2.4 % without third-degree burns. This high incidence was probably due to the fact that it incorporated spontaneously resolving lesions, which were the vast majority of cases. In this early-onset calcinosis group, radiological evidence of calcification was noted 48 days post-burn on average, and no histological examinations were performed. There was no significant alteration of serum calcium levels, but there was a significant reduction in serum alkaline phosphatase levels in patients who had calcinosis. There was no significant correlation with the burned surface area or immobilization of the patients after trauma, but there was a significant correlation with burn depth and limitation of mobility of adjacent joints [4]. In contrast to calcinosis, where amorphous calcium salt deposits are present, heterotopic ossification with bone tissue formation is a complication of burn scars in 1.25–13.6 % of cases, mainly periarticular

on the upper extremities [4–10]. This usually occurs weeks to months after sustaining burn injuries [11, 12].

Pathogenesis

Soft tissue calcification differs fundamentally from soft tissue ossification [11], and calcification is usually not converted into bone formation (Figure 1) [10]. The pathomechanism and risk factors of calcium deposition in burn injuries are unknown. Presumably, in dystrophic calcification local trauma, chronic inflammation or tissue hypoxia may precipitate the calcifying process in the presence of local promoters and systemic mediators that decrease the level of calcification inhibitors, such as pyrophosphate or fetuin A [13, 14]. Damaged or altered collagen, elastin, and subcutaneous fat promote calcification, and phosphate-bound denatured proteins of necrotic cells serve as a nidus for ectopic calcification [1]. Furthermore, the cell membrane cannot maintain the normal

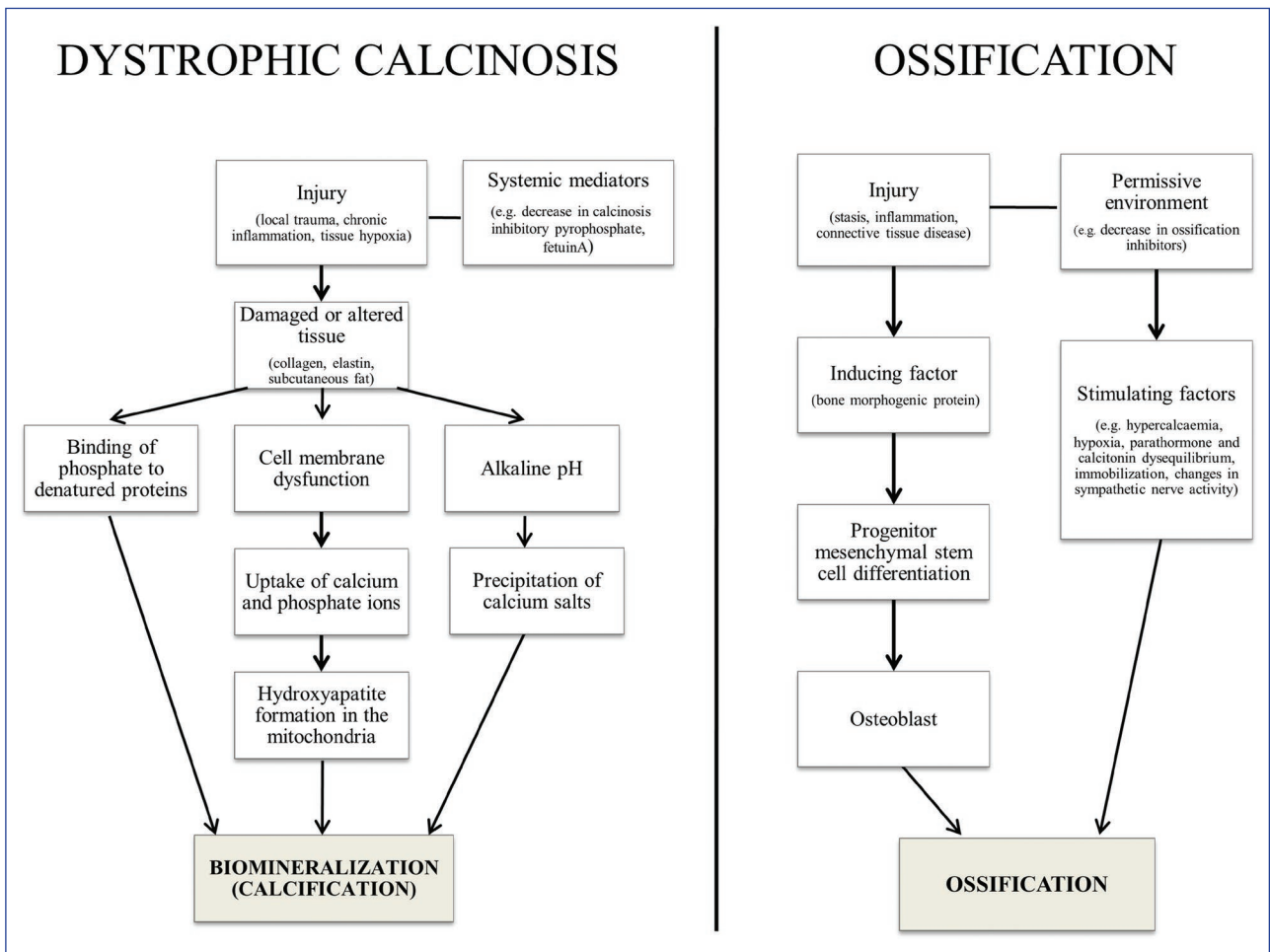


Figure 1 Pathophysiology of dystrophic calcification and ossification.

low concentration of intracellular calcium and phosphate; this results in the uptake of these ions and hydroxyapatite formation in the mitochondria. During the propagation phase, these hydroxyapatite crystals grow in size [15]. The precipitation of calcium salts may be due to the increased alkalinity of necrotic tissues.

In heterotopic ossification, mesenchymal stem cells undergo osteogenic differentiation; burn injury causes an up-regulation of osteogenic gene signaling [16]. Venous stasis, inflammation, or connective tissue disease may lead to the release of bone morphogenetic proteins (BMPs), which are growth factors [11, 17]. Inducing agents such as BMPs serve as promoting factors that can cause osteogenic differentiation of mesenchymal stem cells in a permissive environment. Osteoblasts are stimulated by various factors such as hypercalcemia, hypoxia, parathormone and calcitonin disequilibrium, decreased levels of ossification inhibitors, immobilization and changes in sympathetic nerve activity [18, 19]. Risk factors for burn-associated ossification include body surface burns greater than 30 % in area, arm burns, and skin grafting of arms after thermal injury [7].

Diagnosis and differential diagnosis

Diagnoses of burn scar calcinosis may be confirmed by radiography, ultrasonography, computed tomography, magnetic resonance imaging or histology. Three-phase bone scintigraphy may be applied to distinguish calcinosis from ossification [11, 12]. During ossification, osteoblasts, osteoclasts, and osteoid formation can be identified with histopathology. This is in contrast to calcinosis, where amorphous calcium deposits appear as fine granules in the dermis and as large irregular masses in the subcutis; these are stained dark blue with hematoxylin and eosin and black with von Kossa [20, 21]. In the differential diagnosis of burn scar calcinosis, ossification, keloidal and hypertrophic scars should be considered, and it may be necessary to rule out scar carcinoma with histopathology (Figure 2).

Cases of late-onset burn scar calcinosis

Only a few cases of late-onset burn scar calcinosis have been reported in the literature (Table 1). Almost all of these

presented as non-healing ulcers on the lower extremities in or near contracture bands several years after the burn trauma. Calcium and phosphate levels were within the normal range. In some cases, a white coloration of the overlying skin was observed, presumably due to more severe scarring or translucency of the whitish calcium deposits [15]. Some authors hypothesize that involvement of the lower extremities is caused by more frequent microtrauma of these body parts, and that ulceration is due to the calcium deposit present as a foreign body [22].

In contrast to the cases reported earlier, we present two cases of burn scar calcinosis of the upper extremities without ulceration. To the best of our knowledge, only one case of non-ulcerating late-onset burn scar calcinosis has been reported (Sokhn et al.); this was located on the right cheek of a female patient 39 years of age after a burn injury sustained at the age of three [23].

Our first case is a 65-year-old woman without any relevant comorbidities, who suffered a burn injury on her arms and back at the age of four. Sixty-one years later, she presented at our department with infiltration and hyperkeratosis of the scar keloid in the left scapular region (Figure 3). Histopathological examination was performed to exclude scar carcinoma; this revealed keloid with dystrophic calcification (Figure 4). Six years later she presented with a calcified nodule on her left forearm (Figure 5), which was confirmed radiologically and excised (Figure 6). Serum calcium and phosphate levels were within the normal range. There was no recurrence of the calcified lesions, and no ulceration developed during a follow-up period of nine years.

Our second case is a 74-year-old woman without any relevant comorbidities or serum calcium and phosphate level abnormalities, who suffered a burn injury of her right arm at the age of three. Seventy-one years later she presented at our department with a radiologically proven calcium deposit in the right forearm keloid, which was excised. The patient was lost to follow-up.

We took data from the 15 cases reported in the literature as well as our own two cases (male : female = 10 : 7) [2, 15, 22–29]. In the literature cases, twelve patients had calcinosis on the lower extremities (including the buttocks), one on the upper extremity, one on the abdomen and one on the face. Both of our two cases had calcinosis on the upper

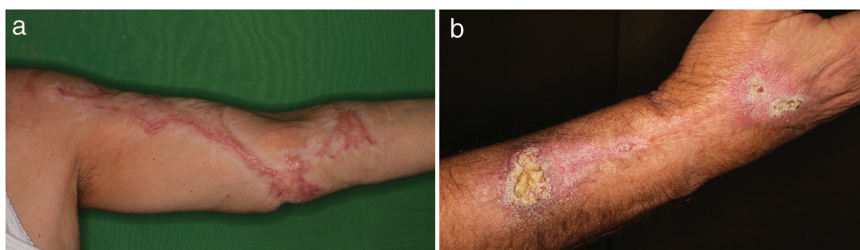


Figure 2 Two entities requiring differential diagnosis of calcinosis associated with burn injury. Burn scar keloid on the arm without calcification (a). Verrucous carcinoma in a burn scar of the forearm (b).

Table 1 Demographic and treatment data of late-onset burn scar calcinosis patients.

Sex	Age at on-set (years)	Age at burn (years)	Time interval (years)	Skin grafting after burn	Location of calcinosis	Ulceration	Therapy	Follow-up (months)	Result (same site)	Author, year
M	66	29	37	N	LE	Y	E	36	NR	Beninson et al. 1964 [24]
M	36	9	27	Y	LE	Y	E	24	NR	Beninson et al. 1964 [24]
F	58	8	50	Y	LE	Y	S	ND	NR	Hogan et al. 1964 [25]
F	46	26	20	N	LE	Y	E, triamcinolone il.	ND	NR	Coskey et al. 1984 [26]
M	42	17	25	N	LE	Y	S, split skin graft	36	NR	Ebrahim et al. 2003 [15]
M	35	10	25	Y	LE	Y	S	36	NR	Ebrahim et al. 2003 [15]
M	48	18	30	Y	LE	Y	S	24	NR	Ebrahim et al. 2003 [15]
M	28	8	20	Y	LE	Y	S, split skin graft	30	NR	Ebrahim et al. 2003 [15]
M	31	2	29	N	LE	Y	E	ND	NR	Choi et al. 2003 [29]
M	44	14	30	N	A	Y	E	6	NR	Lee et al. 2005 [22]
F	76	22	54	N	UE	Y	E	LFU	NR	Lee et al. 2005 [22]
F	42	3	39	N	H	N	ND	ND	NR	Sokhn et al. 2009 [23]
M	57	15	42	N	LE	Y	S	6	NR	Rosmaninho et al. 2015 [2]
F	52	12	40	N	LE	Y	S, skin graft	4	NR	Moon et al. 2018 [27]
M	59	ND	ND	Y	LE	Y	S	36	NR	Lockwood et al. 2018 [28]
F	65	4	61	N	UE, B	N	S	108	NR	Róbert et al.
F	74	3	71	N	UE	N	S	LFU	ND	Róbert et al.

Abbr: A, abdomen; B, back; E, deposit extraction; F, female; H, head; il., intralesional; LE, lower extremity; LFU, lost to follow-up; M, male; N, no; ND, no data; NR, no recurrence; S, surgical excision; UE, upper extremity; Y, yes.

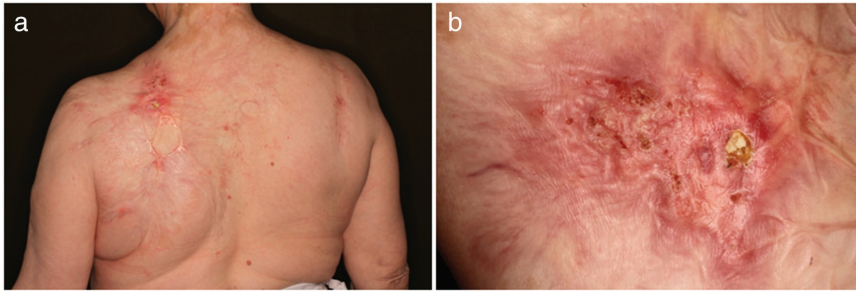


Figure 3 Calcified nodule in a burn scar of the left scapular region in a 65-year old female patient, 61 years after burn trauma (a). Greater magnification of the same nodule (b).

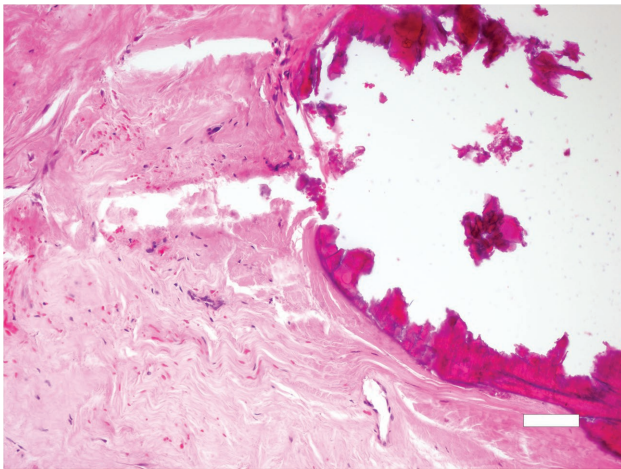


Figure 4 Histological image of calcinosis in a burn scar, with purple-stained calcified deposits on the right side of the image (hematoxylin and eosin, scale bar: 200 μ m).

44.6 \pm 12.75, and 58 \pm 12.96 years, in total, males and females, respectively. Mean age at the time of the burn was 14.6 \pm 7.72, 13.5 \pm 7.67, and 17 \pm 8.4 years, mean time interval was 33 \pm 10.85, 29.4 \pm 6.62, and 41 \pm 15.19 years, in total, males and females respectively. Mean age in the non-ulcerating group was 60.3 \pm 16.5 years at onset, 3.3 \pm 0.58 years after burn, and mean time to onset was 57 \pm 16.37 years.

Therapy of calcinosis

There is no accepted therapeutic algorithm for the management of calcinosis. Recommendations are based on case reports and retrospective studies of small populations of mainly dystrophic calcinosis related to autoimmune connective tissue diseases. For solitary lesions, surgical excision is recommended [30, 31], especially if the trigger factor is no longer present, or if excision is expected to be curative (e.g. calcifying neoplasms) [32]. Carbon dioxide laser [33] and extracorporeal shock wave lithotripsy [34, 35] may also be applied [36]. With regard to burn scar calcinosis, almost all the cases reported in the literature were managed with surgical monotherapy. To the best of our knowledge, the only exception was intralesional triamcinolone administered as an adjunct to surgical excision in individual cases [26]. Considering that systemic medications may not achieve sufficient penetration into the scar tissue and that there are no other data regarding pharmacotherapy for burn scar calcinosis, medications that were administered in other forms of dystrophic calcinosis (mainly calcinosis associated with autoimmune connective tissue diseases) cannot be recommended as first-line treatment. These agents include the calcium

extremities (including the scapular region). The mean age at onset was 50.5 \pm 14.53 years (range 28–76) in total, 44.6 \pm 12.75 (range 28–66), and 59 \pm 13.28 (range 42–76) years between males and females respectively. Mean age at the time of the burn was 12.5 \pm 8.27 years (range 2–29) in total, 13.5 \pm 7.67 (range 2–29), and 11.1 \pm 9.42 (range 3–26) years between males and females respectively. Mean time to onset of calcinosis was 37.5 \pm 14.95 (range 20–71), 29.4 \pm 6.62 (range 20–42), and 47.8 \pm 16.67 (range 20–71) years in total, between males and females respectively. If we consider only the ulcerating calcinosis cases, the mean age was 48.4 \pm 13.81,

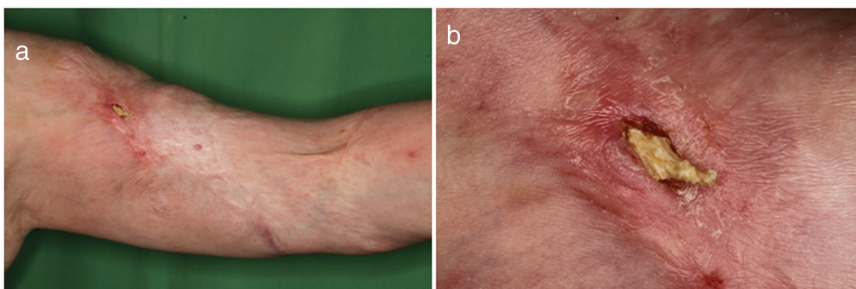


Figure 5 Calcinosis in a burn scar of the left upper extremity in a 65-year old female patient 67 years after the burn trauma (a). Greater magnification of the same burn scar (b).

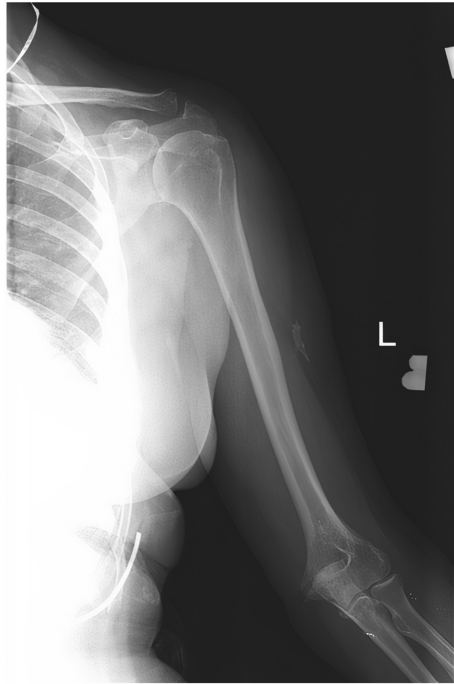


Figure 6 Radiograph of dense calcinosis in a burn scar of the left upper extremity.

channel-blocker diltiazem [30, 31], bisphosphonates [30, 37, 38], probenecid [30, 39, 40], aluminum hydroxide [30, 41], warfarin [42], ceftriaxone [43], intravenous immunoglobulin [44–46], topical sodium-thiosulphate [47–49] and, for inflamed lesions, colchicine [31, 50], minocycline [30, 51], thalidomide [52], intralesional corticosteroids [53, 54] and rituximab [36, 55]. The pharmacotherapy of calcinosis is not discussed in detail in this paper.

Concerning late-onset calcinosis following burn injuries, there was no significant difference between burn scars managed with skin grafting after the trauma and scars where skin grafting was not carried out. This suggests that remaining surgical material such as sutures are unlikely to play a role in the development of calcification. Ulcers healed after resection or extraction of the calcified deposits without any recurrence at the same site. In some cases, if there was no wide excision or skin grafting, a new lesion developed at another site – probably due to an earlier microcalcification that was not removed [2, 22, 29]. This suggests that silent microcalcification may be relatively frequent in burn scars.

Discussion

Interestingly, all the three patients who were reported to have non-ulcerating calcinosis sustained the burn injury in their early childhood (at ages of three to four) and none had lesions

on a lower extremity, only on an upper extremity and face. This may be explained by the location, which is less exposed to recurrent microtrauma, or a more complete tissue repair in early childhood, which prevented the formation of deposits. Calcinosis generally developed later in female patients than in male patients. Given the small population, far-reaching conclusions cannot be drawn.

Based on data in the literature and our own experience with management of burn scar calcinosis, we recommend laboratory testing to rule out calcium metabolism deficits and excision of calcified ulcers with direct closure or skin grafting, or removal of the calcified deposits [15, 22]. Recurrence may occur if small deposits remain, since these can lead to ulceration and chronic inflammation [22, 56]. Follow-up of patients is recommended due to the possibility of recurrence and malignant transformation of chronic ulcers.

Conclusions

Dystrophic calcinosis can develop in each type of tissue alteration or trauma. Late-onset calcinosis in burn scars is a rare variant that differs in its pathophysiology from ossification, which is a slightly more common complication of burn injuries with real ectopic bone formation. Late-onset burn scar calcinosis presents as non-healing ulcers in lower extremities in most cases, and this may lead to increased susceptibility to infections and other complications. Removal of calcified nodules is advisable in order to prevent undesirable consequences. The efficacy of drug therapy for burn scar calcinosis is likely to be limited, because pharmaceuticals do not reach adequate concentrations in the scar tissue. This requires further research.

Correspondence to

Lili Róbert, MD
 Department of Dermatology, Venereology and
 Dermatooncology
 Faculty of Medicine, Semmelweis University
 41 Mária Street
 1085 Budapest, Hungary
 E-mail: robert.lili@med.semmelweis-univ.hu

References

- 1 Reiter N, El-Shabrawi L, Leinweber B et al. Calcinosis cutis: part I. Diagnostic pathway. *J Am Acad Dermatol* 2011; 65: 1–12; quiz 13–4.
- 2 Rosmaninho A, Carvalho S, Lobo I. Photoletter to the editor: Calcinosis cutis in a burn scar. *J Dermatol Case Rep* 2015; 9: 120–1.
- 3 Kolar J, Vrabec R. Periarticular soft-tissue changes as a late consequence of burns. *J Bone Joint Surg Am* 1959; 41-a: 103–11.

- 4 Munster AM, Bruck HM, Johns LA et al. Heterotopic calcification following burns: a prospective study. *J Trauma* 1972; 12: 1071–4.
- 5 Pandit SK, Malla CN, Zarger HU et al. A study of bone and joint changes secondary to burns. *Burns* 1993; 19: 227–8.
- 6 Evans EB. Orthopaedic measures in the treatment of severe burns. *J Bone Joint Surg Am* 1966; 48: 643–69.
- 7 Levi B, Jayakumar P, Giladi A et al. Risk factors for the development of heterotopic ossification in seriously burned adults: A National Institute on Disability, Independent Living and Rehabilitation Research burn model system database analysis. *J Trauma Acute Care Surg* 2015; 79: 870–6.
- 8 Agarwal S, Sorkin M, Levi B. Heterotopic ossification and hypertrophic scars. *Clin Plast Surg* 2017; 44: 749–55.
- 9 Hoffer MM, Brody G, Ferlic F. Excision of heterotopic ossification about elbows in patients with thermal injury. *J Trauma* 1978; 18: 667–70.
- 10 Edlich RF, Horowitz JH, Rheuban KS et al. Heterotopic calcification and ossification in the burn patient. *J Burn Care Rehabil* 1985; 6: 363–8.
- 11 Shehab D, Elgazzar AH, Collier BD. Heterotopic ossification. *J Nucl Med* 2002; 43: 346–53.
- 12 Vanden Bossche L, Vanderstraeten G. Heterotopic ossification: a review. *J Rehabil Med* 2005; 37: 129–36.
- 13 Hsu V, Varga J, Schlesinger N. Calcinosis in scleroderma made crystal clear. *Curr Opin Rheumatol* 2019; 31: 589–94.
- 14 Valenzuela A, Chung L. Calcinosis: pathophysiology and management. *Curr Opin Rheumatol* 2015; 27: 542–8.
- 15 Ebrahim MK, Kanjoor JR, Bang RL. Heterotopic calcification in burn scars and non-healing ulcers. *Burns* 2003; 29: 461–8.
- 16 Peterson JR, De La Rosa S, Eboda O et al. Treatment of heterotopic ossification through remote ATP hydrolysis. *Sci Transl Med* 2014; 6: 255ra132.
- 17 Urist MR, Nakagawa M, Nakata N et al. Experimental myositis ossificans: cartilage and bone formation in muscle in response to a diffusible bone matrix-derived morphogen. *Arch Pathol Lab Med* 1978; 102: 312–6.
- 18 Chantraine A, Minaire P. Para-osteo-arthropathies. A new theory and mode of treatment. *Scand J Rehabil Med* 1981; 13: 31–7.
- 19 Stover SL, Hataway CJ, Zeiger HE. Heterotopic ossification in spinal cord-injured patients. *Arch Phys Med Rehabil* 1975; 56: 199–204.
- 20 Lever WF S-LG. Metabolic diseases. Histopathology of the skin. Philadelphia: JB Lippincott; 1990: 452–87.
- 21 Touart DM, Sau P. Cutaneous deposition diseases. Part II. *J Am Acad Dermatol* 1998; 39: 527–44; quiz 545–6.
- 22 Lee HW, Jeong YI, Suh HS et al. Two cases of dystrophic calcinosis cutis in burn scars. *J Dermatol* 2005; 32: 282–5.
- 23 Sokhn S, Nasseh I. Dermal fibrosis and calcification secondary to burn injury. *Quintessence Int* 2009; 40: 503–6.
- 24 Beninson J, Morales A. SUBCUTANEOUS CALCIFICATIONS IN LEG ULCERS; THREE CASES. *Arch Dermatol* 1964; 90: 314–8.
- 25 Hogan VM, Conway H. CALCIFICATION OF BURN SCARS. *Plast Reconstr Surg* 1964; 33: 559–63.
- 26 Coskey RJ, Mehregan AH. Calcinosis cutis in a burn scar. *J Am Acad Dermatol* 1984; 11: 666–8.
- 27 Moon YJ, Jeong SY, Lee KB. Extra-articular soft-tissue calcification after burn injury: a case study. *J Burn Care Res* 2018; 39: 835–7.
- 28 Lockwood KA, Oliphant T. Dystrophic calcinosis cutis within burns, successfully treated with excision and secondary intention wound healing. *Clin Exp Dermatol* 2018; 43: 648–9.
- 29 Choi HU LH, Bae JH, Lee SK. A case of dystrophic calcinosis cutis in a burn scar. *Korean J Dermatol* 2003; 41: 242–4.
- 30 Gutierrez A, Jr., Wetter DA. Calcinosis cutis in autoimmune connective tissue diseases. *Dermatol Ther* 2012; 25: 195–206.
- 31 Balin SJ, Wetter DA, Andersen LK et al. Calcinosis cutis occurring in association with autoimmune connective tissue disease: the Mayo Clinic experience with 78 patients, 1996–2009. *Arch Dermatol* 2012; 148: 455–62.
- 32 Róbert L, Kiss N, Medvecz M et al. Epidemiology and treatment of calcinosis cutis: 13 years of experience. *Indian J Dermatol* 2020; 65: 105–11.
- 33 Bottomley WW, Goodfield MJ, Sheehan-Dare RA. Digital calcification in systemic sclerosis: effective treatment with good tissue preservation using the carbon dioxide laser. *Br J Dermatol* 1996; 135: 302–4.
- 34 Chan AY, Li E. Electric shock wave lithotripsy (ESWL) as a pain control measure in dermatomyositis with calcinosis cutis-old method, new discovery. *Clin Rheumatol* 2005; 24: 172–3.
- 35 Sparsa A, Lesaux N, Kessler E et al. Treatment of cutaneous calcinosis in CREST syndrome by extracorporeal shock wave lithotripsy. *J Am Acad Dermatol* 2005; 53: S263–5.
- 36 Reiter N, El-Shabrawi L, Leinweber B et al. Calcinosis cutis: part II. Treatment options. *J Am Acad Dermatol* 2011; 65: 15–22; quiz 23–14.
- 37 Marco Puche A, Calvo Penades I, Lopez Montesinos B. Effectiveness of the treatment with intravenous pamidronate in calcinosis in juvenile dermatomyositis. *Clin Exp Rheumatol* 2010; 28: 135–40.
- 38 Rabens SF, Bethune JE. Disodium etidronate therapy for dystrophic cutaneous calcification. *Arch Dermatol* 1975; 111: 357–61.
- 39 Eddy MC, Leelawattana R, McAlister WH et al. Calcinosis universalis complicating juvenile dermatomyositis: resolution during probenecid therapy. *J Clin Endocrinol Metab* 1997; 82: 3536–42.
- 40 Nakamura H, Kawakami A, Ida H et al. Efficacy of probenecid for a patient with juvenile dermatomyositis complicated with calcinosis. *J Rheumatol* 2006; 33: 1691–3.
- 41 Park YM, Lee SJ, Kang H et al. Large subcutaneous calcification in systemic lupus erythematosus: treatment with oral aluminum hydroxide administration followed by surgical excision. *J Korean Med Sci* 1999; 14: 589–92.
- 42 Cukierman T, Elinav E, Korem M et al. Low dose warfarin treatment for calcinosis in patients with systemic sclerosis. *Ann Rheum Dis* 2004; 63: 1341–3.
- 43 Reiter N, El-Shabrawi L, Leinweber B et al. Subcutaneous morphea with dystrophic calcification with response to ceftriaxone treatment. *J Am Acad Dermatol* 2010; 63: e53–5.
- 44 Peñate Y, Guillermo N, Melwani P et al. Calcinosis cutis associated with amyopathic dermatomyositis: response to intravenous immunoglobulin. *J Am Acad Dermatol* 2009; 60: 1076–7.

- 45 Schanz S, Ulmer A, Fierlbeck G. Response of dystrophic calcification to intravenous immunoglobulin. *Arch Dermatol* 2008; 144: 585–7.
- 46 Touimy M, Janani S, Rachidi W et al. Calcinosis universalis complicating juvenile dermatomyositis: improvement after intravenous immunoglobulin therapy. *Joint Bone Spine* 2013; 80: 108–9.
- 47 Bair B, Fivenson D. A novel treatment for ulcerative calcinosis cutis. *J Drugs Dermatol* 2011; 10: 1042–4.
- 48 Wolf EK, Smidt AC, Laumann AE. Topical sodium thiosulfate therapy for leg ulcers with dystrophic calcification. *Arch Dermatol* 2008; 144: 1560–2.
- 49 von Hodenberg C, Neufeld M, Wohlrab J et al. Topical sodium thiosulfate: a reliable treatment for digital calcinosis cutis – a case series with six patients. *J Dtsch Dermatol Ges* 2020; 18: 1181–3.
- 50 Fuchs D, Fruchter L, Fishel B et al. Colchicine suppression of local inflammation due to calcinosis in dermatomyositis and progressive systemic sclerosis. *Clin Rheumatol* 1986; 5: 527–30.
- 51 Robertson LP, Marshall RW, Hickling P. Treatment of cutaneous calcinosis in limited systemic sclerosis with minocycline. *Ann Rheum Dis* 2003; 62: 267–9.
- 52 Miyamae T, Sano F, Ozawa R et al. Efficacy of thalidomide in a girl with inflammatory calcinosis, a severe complication of juvenile dermatomyositis. *Pediatr Rheumatol Online J* 2010; 8: 6.
- 53 Al-Mayouf SM, Alsonbul A, Alismail K. Localized calcinosis in juvenile dermatomyositis: successful treatment with intralesional corticosteroids injection. *Int J Rheum Dis* 2010; 13: e26–8.
- 54 Hazen PG, Walker AE, Carney JF et al. Cutaneous calcinosis of scleroderma. Successful treatment with intralesional adrenal steroids. *Arch Dermatol* 1982; 118: 366–7.
- 55 de Paula DR, Klem FB, Lorencetti PG et al. Rituximab-induced regression of CREST-related calcinosis. *Clin Rheumatol* 2013; 32: 281–3.
- 56 Lee SY, Kim KS, Kim DY et al. Dystrophic calcinosis cutis in a patient with squamous cell carcinoma secondary to postburn scar. *Ann Plast Surg* 2001; 46: 457–8.