



## Case report

# *Mycobacterium mucogenicum* bacteremia in an immunocompetent host: A case report and concise review

N. Beydoun<sup>a,\*</sup>, Z. Wiley<sup>b</sup>, N. Roupael<sup>b,c</sup><sup>a</sup> Emory University School of Medicine, Department of Internal Medicine, Atlanta, GA, USA<sup>b</sup> Emory University School of Medicine, Department of Internal Medicine, Division of Infectious Diseases, Atlanta, GA, USA<sup>c</sup> The Hope Clinic of the Emory Vaccine Center, Emory University, Decatur, GA, USA

## ARTICLE INFO

## Article history:

Received 22 May 2020

Received in revised form 15 December 2020

Accepted 17 December 2020

## Keywords:

Rapidly growing mycobacterium

*Mycobacterium mucogenicum*

Peripherally inserted central catheter

Bloodstream infection

## ABSTRACT

Rapidly growing mycobacterium (RGM) bloodstream infections (BSI) have been described in the literature mostly in immunocompromised patients such as those with malignancies. Here, we describe a case of a RGM, *Mycobacterium mucogenicum*, bloodstream infection in an immunocompetent host who was receiving antibiotics via a peripherally inserted central catheter (PICC).

© 2020 The Authors. Published by Elsevier Ltd. This is an open access article under the CC BY-NC-ND license (<http://creativecommons.org/licenses/by-nc-nd/4.0/>).

## Introduction

Around 800,000 cases of central venous catheter (CVC) related BSI are diagnosed in the United States each year in intensive care setting [1]. Depending on the type of catheter, method of insertion and duration of catheter placement, the risk of BSI varies [2]. The most commonly isolated microorganisms that cause Catheter-Related Bloodstream Infections (CRBSI) are: coagulase-negative *Staphylococcus*, *Staphylococcus aureus*, *Candida* species, and enteric gram-negative rods [2]. Rarely, acid-fast bacilli (AFB) can be a cause of BSI, mostly in immunocompromised patients with CVCs. Therefore, it is important to recognize these infections promptly in order to administer the appropriate antibiotic regimen.

## Case presentation

A 54-year-old Caucasian woman presented with fever and body aches. Two months earlier, she had undergone anterior cervical discectomy and fusion of C6-C7 for cervical spondylosis and myelopathy, after which she had wound dehiscence and infection with Methicillin Resistant *Staphylococcus aureus* (MRSA) proven by culture. She was undergoing treatment with daptomycin intravenously, after intolerance of her initial regimen of vancomycin and rifampin.

Her medical history included breast cancer (bilateral mastectomy and chemotherapy 8 years prior) and prior cholecystectomy and appendectomy. Family and social histories were unremarkable.

On physical examination, vital signs were stable except for a temperature of 38.9 °C. Her surgical wound site was completely healed. The peripherally inserted central catheter (PICC) site was mildly tender without warmth, swelling, or discharge.

Laboratory results included: white blood cells (WBCs) count of 13,100/mcL (normal range 4,000–10,000/mcL), erythrocyte sedimentation rate of 55 mm/h (reference high >30 mm/h), C-reactive protein (CRP) of 52 mg/L (reference high >10 mg/L). Her HIV test was negative. Nine out of nine blood cultures were positive for AFB. The catheter was removed and catheter tip culture grew more than 15 colonies of AFB. Upon further analysis and speciation, culture results were positive for *Mycobacterium mucogenicum* (Fig. 1).

The isolated *M. mucogenicum* was susceptible to amikacin, cefoxitin, ciprofloxacin, clarithromycin and trimethoprim/sulfamethoxazole. Intermediate resistance was noted for linezolid, and the isolate was resistant to doxycycline.

A four week course of meropenem, azithromycin and ciprofloxacin was initiated and repeat blood cultures drawn on the third day of therapy were negative. A week into therapy, a new PICC line was placed, before discharge. She also completed a ten week course of daptomycin for her MRSA wound infection. Repeat MRI and WBC scan showed no evidence of infection and her CRP decreased to 10 mg/L.

\* Corresponding author at: 500 Irvin Court #200, Decatur, GA, 30030, USA.

E-mail address: [nbeydoun@emory.edu](mailto:nbeydoun@emory.edu) (N. Beydoun).

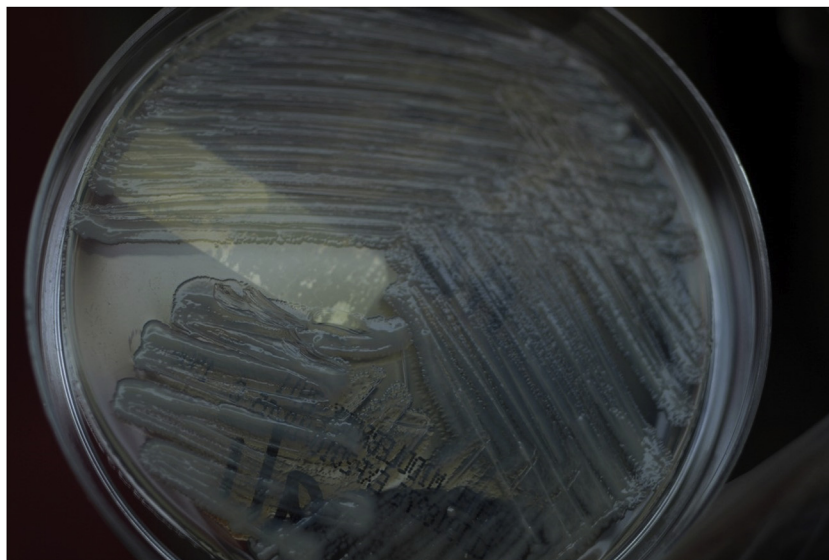


Fig. 1. Abundant growth of *Mycobacterium mucogenicum* on Middlebrook 7H11 Agar with typical mucoid appearance of the colonies.

## Discussion

With the increase of immunocompromising conditions, the prevalence of rapidly growing mycobacterium (RGM) infections has been rising [3]. This rise is also partly due to improved laboratory methodologies in the detection and rapid isolation of RGM species [4]. Some of the groups included under RGM are *Mycobacterium fortuitum*, *Mycobacterium mucogenicum*, *Mycobacterium neoaurum*, *Mycobacterium abscessus*, *Mycobacterium cosmeticum*, *Mycobacterium Smegmatis*, and *Mycobacterium phlei*.

*M. mucogenicum*'s name is derived from the mucoid-like appearance of the isolates [5]. The mucoid surface helps these organisms with biofilm formation, making it an important culprit among catheter-related infections. *M. mucogenicum* is ubiquitous in the environment and can be present in both public and hospital water supplies. Multiple outbreaks in patients with CVCs have been traced back to water sources contaminated with *M. mucogenicum*. This happens mostly while flushing the catheter with tap water or contamination of the CVC while bathing [5,6].

In our review of the literature, we found 20 articles on *M. mucogenicum* BSI, with detailed clinical and microbiological information available on a total of 172 patients (Table 1).

Among the rapidly growing mycobacteria, *M. mucogenicum* was found to be the most common cause of BSI. The majority of *M. mucogenicum* BSI cases reported in the literature were seen in adult and pediatric patients with malignancies. Other underlying diseases included end stage renal disease, cirrhosis, sickle cell disease, thalassemia major, chronic gastrointestinal pathology and autoimmune diseases. The most important risk factor was the presence of CVCs, on which these organisms are capable of biofilm formation [4]. Management of these infections includes removal of the catheter and administration of appropriate antibiotics. Removal of the catheter has been shown to have favorable outcomes and leads to a decrease in the rate of relapse of *M. mucogenicum* bacteremia [7].

There are no treatment guidelines outlining the optimal choice of antibiotics or length of treatment necessary for the management of these infections; it is often based on expert opinion. RGM are inherently resistant to first-line antituberculous drugs such as isoniazid, rifampin, and pyrazinamide [4]. Fortunately, *M. mucogenicum* is considered to be one of the most susceptible

strains amongst RGM, and susceptibility testing should be performed for the following antibiotics: amikacin, tobramycin, clarithromycin, doxycycline, minocycline, ciprofloxacin, imipenem, linezolid, and cefoxitin [25].

Several studies have shown good outcomes with the use of two or more antibiotics, for a period of around 4 weeks, owed to the highly susceptible nature of the strain to multiple antibiotics. A study by El Helou et al. found that regimens that included Amikacin were associated with lower relapse and better outcomes [7], suggesting its use as initial empiric treatment of RGM bacteremia. Rodriguez-Coste et al. recommend using clarithromycin, imipenem and amikacin as broad empiric therapy while waiting for sensitivity testing, since this combination will provide at least two active agents [3].

Upon review of the literature, the most frequently used combination of antibiotics was a macrolide plus a quinolone, commonly clarithromycin and ciprofloxacin, which generally lead to good outcomes.

The challenge of identifying *M. mucogenicum* as a cause of bacteremia is its slow growth as compared to other microorganisms responsible for catheter related BSI, such as *Staphylococcus*. RGM can take up to 7 days to grow on culture media, while blood cultures are usually incubated for only 5 days. The other challenge is that this organism is often thought of as affecting only the immunocompromised, however, it can also cause bacteremia in immunocompetent hosts, such as our patient. *M. mucogenicum* should be considered in any patient with a catheter in place and managed accordingly.

## Author statement

Dr. Nour Beydoun contributed to the conception and design of the work, literature review, acquisition on data, analysis of data, drafting and revising the work. Dr. Nadine Rouphael contributed to the conception and design of the work, planning, interpretation of data, revising the work critically for important intellectual content. Dr. Zanthia Wiley contributed to the design of the work, analysis of data, and critically revising the work for important intellectual content.

All authors approved the final version published.

**Table 1**  
Review of the literature on *Mycobacterium mucogenicum* bloodstream infections.

Reference	Year	Total # of patients	# of patients with <i>M. mucogenicum</i>	Sex/Age	Underlying disease/comorbidity	Presence of CVC	Source	Treatment	Removal of CVC	Outcome
[3]	2016	32	9	44.4% M/55.9 (mean)	Malignancy (5) Chronic GI pathology (2) Autoimmune disease (1)	Yes (88.9 %)	Not specified	Not specified	Not specified	Favorable (62.5 %)
[6]	2017	1	1	M/34	ESRD on home HD	Yes	Tap water supply	MXF + CLR for 6 weeks	Yes	Favorable
[7]	2013	116	45	57.8% M/52 (median)	Malignancy	Yes (95.7 %)	Not specified	Most frequently: ML + FQ (60 %)	Yes (78.4 %)	Resolved (79.3 %)
[8]	2004	6	6	N/A (adults and pediatrics patients)	BMT or HSCT (5) Malignancy (1)	Yes (100 %)	Tap water supply	Not specified	Not specified	Not specified
[9]	2016	39	39	59% M/52 (median)	SCT Malignancy	Yes (84.6 %)	Not specified	>1 ABx (most frequently: IV AMK + PO CLR) Median = 42 days	Yes (100 %)	Favorable
[10]	2015	5	4	50 % M/42.25 (mean)	Malignancy	Yes (100 %)	Tap water supply	No ABx Observation only	Yes (100 %)	Favorable
[11]	2012	4	4	25 % M/26.75 (mean)	Sickle-cell disease	Yes (100 %)	Tap water supply	Combination >1 ABx	Yes (100 %)	Favorable
[12]	2011	5	4	25 % M/47.4 (mean)	Malignancy	Yes (100 %)	Tap water supply	Combination >1 ABx	Yes (100 %)	Favorable (75 %) Death (25 %, post-transplant complications unrelated to infection)
[13]	2011	8	8	62.5 % M/6.9 (mean)	Malignancy (7) Thalassemia major (1)	Yes (100 %)	Not specified	No ABx (50 %) AMK (25 %, for febrile neutropenia) IPM followed by CIP for 6 weeks (25 %)	Yes (100 %)	Favorable (100 %)
[14]	2008	5	5	80 % M/9.1 (mean)	Malignancy	Yes (100 %)	Tap water supply (exposure during bathing)	CLR (20 %) CLR + CIP (40 %) Amikacin (20 %)	Yes (80 %)	Favorable (80 %) Death (20 %, died before culture results were available)
[15]	2008	6	2	50 % M/37.5 (mean)	Malignancy	Yes (100 %)	Not specified	AMK + CLR for 8 weeks (50 %) Multiple combinations for 24 weeks (50 %)	Yes (100 %)	Favorable (100 %)
[16]	1998	1	1	M/47	Cirrhosis	Yes	Uncertain	IPM + AMK	Not specified	Defervesced but died of other causes
[17]	2007	115	28	66% M/48.4 (mean)	Malignancy	Yes (100 %)	Not specified	Combination >1 ABx	Yes (100 %)	Favorable (100 %)
[18]	2000	40	2	N/A	HSCT	Yes (100 %)	Not specified	IV ABx for 2–4 weeks followed by PO ABx for 4–6 weeks (100%)	Not specified	Favorable (100%)
[19]	2015	25	2	100 % F/9 (mean)	Malignancy	Yes (100 %)	Not specified	CLR + IPM for 2 weeks followed by CLR for 22 weeks (50 %) CLR for 8 weeks (50 %)	Yes (100 %)	Favorable (100 %)
[20]	2010	39	3	N/A (adults and pediatrics patients)	Malignancy in majority	Not specified	Not specified	Not specified	Not specified	Not specified
[21]	2004	13	2	50 % M/9 (mean)	Malignancy	Yes (100 %)	Not specified	No ABx (50 %) CLR + unspecified agent (50 %)	Yes (100 %)	Favorable (100 %)
[22]	2006	1	1	F/6	MDS s/p cord blood transplant	Yes	Tap water supply (flushed her CVC)	IV AMK + PO CIP + PO CLR	Yes	Favorable
[23]	2008	5	5	40 % M/67 (median)	Malignancy	Yes (100 %)	Tap water supply	Not specified	Yes (100 %)	Not specified
[24]	2007	1	1	M/16	Malignancy (ALL)	Yes	Possible exposure of line to tap water supply during bathing	MRM (kept Hickman) Then catheter removed and MRM + TEC + ACV due to relapse	Yes	Favorable

M=Male; N/A=Not applicable; GI=Gastrointestinal; ESRD=End stage renal disease; SCT=Stem cell transplant; BMT=Bone marrow transplant; HSCT=Hematopoietic stem cell transplant; MDS=Myelodysplasia syndrome; ALL=Acute lymphocytic leukemia; CVC=Central venous catheter; ABx=Antibiotics; PO=Orally; IV=Intravenous; MXF=Moxifloxacin; CLR=Clarithromycin; ML=Macrolide; FQ=Fluoroquinolone; AMK=Amikacin; IPM=Imipenem; CIP=Ciprofloxacin; MRM=Meropenem; TEC=Teicoplanin; ACV=Acyclovir.

All authors are in agreement to be accountable for all aspects of the work in ensuring that questions related to the accuracy or integrity of any part of the work are appropriately investigated and resolved.

### Funding

The present study had no sources of funding or sponsorships. It was carried out with own resources of the authors.

### Consent

Written informed consent was obtained from the patient for publication of this case report and accompanying images. A copy of the written consent is available for review by the Editor-in-Chief of this journal on request.

### Declaration of Competing Interest

The authors report no declarations of interest.

### Acknowledgements

NB is supported by the Stimulating Access to Research in Residency of the National Institutes of Health under Award Number R38AI140299. The content is solely the responsibility of the authors and does not necessarily represent the official views of the National Institutes of Health.

### References

- [1] Mermel LA. Prevention of intravascular catheter-related infections. *Ann Intern Med* 2000;132(5):391–402, doi:<http://dx.doi.org/10.7326/0003-4819-132-5-200003070-00009>.
- [2] Safdar N, Mermel LA, Maki DG. The epidemiology of catheter-related infection in the critically ill. In: O'Grady N, Pittet D, editors. *Catheter related infections in the critically ill*. New York, NY: Kluwer; 2004. p. 1–23.
- [3] Rodriguez-Coste MA, Chirca I, Steed LL, Salgado CD. Epidemiology of rapidly growing mycobacteria bloodstream infections. *Am J Med Sci* 2016;351(3):253–8, doi:<http://dx.doi.org/10.1016/j.amjms.2015.12.012>.
- [4] El Helou G, Viola GM, Hachem R, Han XY, Raad II. Rapidly growing mycobacterial bloodstream infections. *Lancet Infect Dis* 2013;13(2):166–74, doi:[http://dx.doi.org/10.1016/S1473-3099\(12\)70316-X](http://dx.doi.org/10.1016/S1473-3099(12)70316-X).
- [5] Adekambi T. *Mycobacterium mucogenicum* group infections: a review. *Clin Microbiol Infect* 2009;15(10):911–8.
- [6] Dhruve MJ, Bunce PE, D'Gama C, Chan CT. Case of *Mycobacterium mucogenicum* in home hemodialysis patient. *Hemodial Int* 2017;21(4):E79–81, doi:<http://dx.doi.org/10.1111/hdi.12574>.
- [7] El Helou G, Hachem R, Viola GM, El Zakhem A, Chaftari AM, Jiang Y, et al. Management of rapidly growing mycobacterial bacteremia in cancer patients. *Clin Infect Dis* 2013;56(6):843–6, doi:<http://dx.doi.org/10.1093/cid/cis1032>.
- [8] Kline S, Cameron S, Streifel A, Yakrus MA, Kairis F, Peacock K, et al. An outbreak of bacteremias associated with *Mycobacterium mucogenicum* in a hospital water supply. *Infect Control Hosp Epidemiol* 2004;25(12):1042–9.
- [9] Abidi MZ, Ledebner N, Banerjee A, Hari P. *Mycobacterium mucogenicum* bacteremia in immune-compromised patients, 2008–2013. *Diagn Microbiol Infect Dis* 2016;85(2):182–5, doi:<http://dx.doi.org/10.1016/j.diagmicrobio.2016.02.012>.
- [10] Tagashira Y, Kozai Y, Yamasa H, Sakurada M, Kashiyama T, Honda H. A cluster of central line-associated bloodstream infections due to rapidly growing nontuberculous mycobacteria in patients with hematologic disorders at a Japanese tertiary care center: an outbreak investigation and review of the literature. *Infect Control Hosp Epidemiol* 2015;36(1):76–80, doi:<http://dx.doi.org/10.1017/ice.2014.14>.
- [11] Ashraf MS, Swinker M, Augustino KL, Nobles D, Knupp C, Liles D, et al. Outbreak of *Mycobacterium mucogenicum* bloodstream infections among patients with sickle cell disease in an outpatient setting. *Infect Control Hosp Epidemiol* 2012;33(11):1132–6, doi:<http://dx.doi.org/10.1086/668021>.
- [12] Baird SF, Taori SK, Dave J, Willocks LJ, Roddie H, Hanson M. Cluster of nontuberculous mycobacteremia associated with water supply in a haematology unit. *J Hosp Infect* 2011;79(4):339–43, doi:<http://dx.doi.org/10.1016/j.jhin.2011.07.006>.
- [13] Shachor-Meyouhas Y, Sprecher H, Eluk O, Ben-Barak A, Kassis I. An outbreak of *Mycobacterium mucogenicum* bacteremia in pediatric hematology-oncology patients. *Pediatr Infect Dis J* 2011;30(1):30–2, doi:<http://dx.doi.org/10.1097/INF.0b013e3181ee31d7>.
- [14] Livni G, Yaniv I, Samra Z, Kaufman L, Solter E, Ashkenazi S, et al. Outbreak of *Mycobacterium mucogenicum* bacteraemia due to contaminated water supply in a paediatric haematology-oncology department. *J Hosp Infect* 2008;70(3):253–8, doi:<http://dx.doi.org/10.1016/j.jhin.2008.07.016>.
- [15] Hawkins C, Qi C, Warren J, Stosor V. Catheter-related bloodstream infections caused by rapidly growing nontuberculous mycobacteria: a case series including rare species. *Diagn Microbiol Infect Dis* 2008;61(2):187–91, doi:<http://dx.doi.org/10.1016/j.diagmicrobio.2008.01.004>.
- [16] Paterson DL, Singh N, Gayowski T, Marino IR. *Mycobacterium mucogenicum* bacteremia in a patient with cirrhosis. *J Clin Gastroenterol* 1998;27(4):346–7, doi:<http://dx.doi.org/10.1097/00004836-199812000-00014>.
- [17] Han XY, Dé I, Jacobson KL. Rapidly growing mycobacteria: clinical and microbiologic studies of 115 cases. *Am J Clin Pathol* 2007;128(4):612–21, doi:<http://dx.doi.org/10.1309/1KB2GKYT1BUEYLB5>.
- [18] Gavia JM, Garcia PJ, Garrido SM, Corey L, Boeckh M. Nontuberculous mycobacterial infections in hematopoietic stem cell transplant recipients: characteristics of respiratory and catheter-related infections. *Biol Blood Marrow Transplant* 2000;6(4):361–9, doi:[http://dx.doi.org/10.1016/S1083-8791\(00\)70012-7](http://dx.doi.org/10.1016/S1083-8791(00)70012-7).
- [19] Apiwattankul N, Flynn PM, Hayden RT, Adderson EE. Infections caused by rapidly growing *Mycobacteria* spp in children and adolescents with cancer. *J Pediatric Infect Dis Soc* 2015;4(2):104–13, doi:<http://dx.doi.org/10.1093/jpids/piu038>.
- [20] Redelman-Sidi G, Sepkowitz KA. Rapidly growing mycobacteria infection in patients with cancer. *Clin Infect Dis* 2010;51(4):422–34, doi:<http://dx.doi.org/10.1086/655140>.
- [21] Reilly AF, McGowan KL. Atypical mycobacterial infections in children with cancer. *Pediatr Blood Cancer* 2004;43(6):698–702, doi:<http://dx.doi.org/10.1002/pbc.20061>.
- [22] Fleming GA, Frangoul H, Dermody TS, Halasa N. A cord blood transplant recipient with *Mycobacterium mucogenicum* central venous catheter infection after infusion of tap water. *Pediatr Infect Dis J* 2006;25(6):567–9, doi:<http://dx.doi.org/10.1097/01.inf.0000219406.06431.67>.
- [23] Cooksey RC, Chung MA, Yakrus MA, Butler WR, Adékambi T, Morlock GP, et al. Multiphasic approach reveals genetic diversity of environmental and patient isolates of *Mycobacterium mucogenicum* and *Mycobacterium phocaicum* associated with an outbreak of bacteremias at a Texas hospital. *Appl Environ Microbiol* 2008;74(8):2480–7, doi:<http://dx.doi.org/10.1128/AEM.02476-07>.
- [24] Marshall C, Samuel J, Galloway A, Pedler S. *Mycobacterium mucogenicum* from the Hickman line of an immunocompromised patient. *J Clin Pathol* 2007;61(1):140–1, doi:<http://dx.doi.org/10.1136/jcp.2007.049486>.
- [25] Al-Anazi KA, Al-Jasser AM, Al-Anazi WK. Infections caused by non-tuberculous mycobacteria in recipients of hematopoietic stem cell transplantation. *Front Oncol* 2014;4:311, doi:<http://dx.doi.org/10.3389/fonc.2014.00311>.