

Protoscolicidal Effects of the Garlic Chloroformic Extract on the Protoscolices of Hydatid Cyst at a Short Exposure Time, up to Five Minutes

Zahra Barzin^{1,2}, MSc;
Seyed Mahmoud Sadjjadi^{2,3}, PhD;
Mohammad Reza Panjehshahin⁴, PhD

¹Department of Parasitology and Mycology, School of Medicine, Jiroft University of Medical Sciences, Jiroft, Iran;

²Department of Parasitology and Mycology, School of Medicine, Shiraz University of Medical Sciences, Shiraz, Iran;

³Basic Sciences in Infectious Diseases Research Center, Shiraz University of Medical Sciences, Shiraz, Iran;

⁴Department of Pharmacology, School of Medicine, Shiraz University of Medical Sciences, Shiraz, Iran

Correspondence:

Seyed Mahmoud Sadjjadi, PhD;
Department of Parasitology and Mycology, School of Medicine,
Shiraz University of Medical Sciences,
P. O. Box: 71345-1735, Shiraz, Iran
Tel/Fax: +98 71 32305291

Email: smsadjjadi@sums.ac.ir
sadjjadi316@gmail.com

Received: 12 March 2017

Revised: 8 May 2017

Accepted: 16 July 2017

What's Known

- Different chemical agents are injected into the cyst before surgery to prevent secondary hydatidosis.
- Common protoscolicidal agents often cause side effects such as liver necrosis and cholangitis.

What's New

- Protoscolicidal effects of the garlic chloroformic extract within 30 minutes on protoscolices are comparable to those of cetrимide
- Protoscolicidal effects of the garlic chloroformic extract in a limited exposure time (<5 min) on protoscolices can be applicable during hydatid cyst surgery.

Abstract

Background: The treatment of choice for hydatidosis as an important zoonotic disease is surgery. Different agents are injected into the cyst to prevent secondary hydatidosis. To avoid the side effects of such protoscolicidal agents, considering the high protoscolicidal effects of the garlic extract, we conducted the present study on protoscolices in limited applicable times and compared the extract with some chemical agents.

Methods: Sheep's liver and lung cysts were collected. Ninety tubes were selected and divided into 3 sets (for different exposure times), each one comprising 5 groups of 6 tubes. Each tube contained 3000–4000 protoscolices. The groups were 0.5% cetrимide (as positive control), 20% hypertonic sodium chloride, 0.5% silver nitrate, 0.9% normal saline (as negative control), and the garlic chloroformic extract (200 mg/mL). The viability of the protoscolices was assessed using 0.1% eosin. The ANOVA and LSD were used to compare the mean viability of the protoscolices after exposure to the different agents at different times and concentrations. The data were analyzed using SPSS software, version 17. A $P < 0.05$ was considered significant.

Results: Our findings showed that the protoscolicidal effects of the garlic extract at 1 ($P < 0.001$) and 2 ($P < 0.001$ and $P = 0.003$) minutes of exposure were higher than those of sodium chloride and silver nitrate. At 5 minutes of exposure, there was no difference between the garlic extract and sodium chloride ($P = 0.36$); however, the difference between these agents and silver nitrate was significant.

Conclusion: The garlic chloroformic extract in a short exposure time had high protoscolicidal effects and could substitute other agents.

Please cite this article as: Barzin Z, Sadjjadi SM, Panjehshahin MR. Protoscolicidal Effects of the Garlic Chloroformic Extract on the Protoscolices of Hydatid Cyst at a Short Exposure Time, up to Five Minutes. *Iran J Med Sci.* 2019;44(1):28-34.

Keywords • Echinococcosis • Garlic • In Vitro techniques

Introduction

Hydatidosis/ echinococcosis is one of the most important zoonotic parasitic diseases, with a high parasite prevalence in many parts of the world, including Iran.¹⁻⁴ The causative agent is the larval stage of parasitic platyhelminth, *Echinococcus granulosus* (*E. granulosus*). Humans are infected by ingesting

parasite eggs released from infected dogs and canine species, and the infection is usually diagnosed via imaging and serologic tests.⁵⁻⁹ Consequently, in areas where *E. granulosus* is endemic, care should be taken to prevent dogs from having access to raw offal and carcasses. Where dogs may have access to carcasses or raw viscera, especially from sheep, goats, cattle, or camels, they should be treated at least every 6 weeks with an effective anthelmintic containing praziquantel.¹

Cystic echinococcosis affects mainly the intermediate host's internal organs such as the liver, lungs, and rarely spleen, kidneys, brain, and other organs.⁶⁻¹⁰ It has been suggested that surgery is still the most important treatment method with chemotherapy as the adjuvant treatment; nevertheless, the leakage of protoscolices during surgery may cause secondary hydatidosis.^{11,12} The inoculation of protoscolicidal agents into the hydatid cyst in order to reduce the leakage risk of the viable protoscolices to the adjacent regions is a part of surgery or the PAIR technique (Puncture, Aspiration, Injection of scolical agent, Reaspiration).^{13,14} They are used for destroying the germinal layer and killing the viable protoscolices of the hydatid cyst.¹⁵ Different protoscolicidal agents such as hypertonic saline, silver nitrate, and cetrимide have been used to sterilize cysts.¹⁶ In vitro studies using glucose 50% have shown that the hypertonic glucose solution is highly effective in killing the protoscolices of *E. granulosus*.¹⁷ Common protoscolicidal agents like 20% hypertonic sodium chloride, 0.5% silver nitrate, cetrимide, and formalin cause severe complications such as liver necrosis and cholangitis.¹⁸ Therefore, the World Health Organization's working group on hydatidosis proposed an urgent need for new protoscolicidal agents which would be more effective with fewer complications.¹⁸ Subsequent research has suggested garlic (*Allium sativum*), the antiparasitic effects of which have been evaluated for a number of parasites such as *Hymenolepis nana*, *Ascaris lumbricoides*, and *Giardia intestinalis*.^{19,20} Many in vitro studies on the protoscolicidal effects of herbal extracts have applied long exposure times between protoscolices and herbal extracts. A previously conducted investigation has shown the successful in vitro protoscolicidal effects of the chloroformic extract of garlic at 30 minutes of exposure or longer.¹¹ However, such long exposure times are not applicable during surgery or the PAIR technique and shorter exposure times are needed before cyst evacuation. Accordingly, the present study was designed with exposure

times of under 5 minutes (i.e., 1 min, 2 min, and 5 min) in order to assess the applicability of the chloroformic extract of garlic as a usable protoscolicidal agent during surgery or the PAIR technique. A number of other protoscolicidal agents such as cetrимide were also used for the comparison of the protoscolicidal effects of the garlic chloroformic extract.

Materials and Methods

The agents used in the present study were 0.5% cetrимide, 20% sodium chloride, 0.5% silver nitrate, normal saline, and a solution of the garlic chloroformic extract (200 mg/mL). The garlic chloroformic extract was prepared as follows: 150 g of fresh garlic (Hamadan origin) was crushed and placed in a succillate apparatus, and while it was being warmed for 24 hours, 400 mL of chloroform was added. The extract was desiccated with a rotary evaporator to remove the extra chloroform solvent, and the remaining powder in the form of crystal was used for the assay. A negative control group was also considered using 0.9% normal saline. Hydatid cysts of sheep's liver and lungs were carried to the laboratory, and protoscolices measuring a total of 30000/mL to 40000/mL were collected in a sterile condition. The samples of protoscolices were selected while the viability was more than 90%. A total of 90 tubes were selected and divided into 3 sets each with 5 groups of 6 tubes. Each set was used for different exposure times of 1, 2, and 5 minutes. Each tube was transferred to 0.1 mL of a fluid containing 3000–4000 protoscolices in a sterile condition. The groups were divided as follows: (1) 0.5% cetrимide, (2) 0.5% silver nitrate, (3) 20% hypertonic sodium chloride, (4) garlic chloroformic extract (200 mg/mL), and (5) normal saline as the negative control. The tests were carried out at exposure times of 1, 2, and 5 minutes in each group, and the viability of the protoscolices was assessed using 0.1% eosin.

The experimental protocols were approved by the Ethics Committee of Shiraz University of Medical Sciences.

After 1 minute of exposure, 10 mL of normal saline was added. The upper fluid (supernatant) was discarded after centrifugation at 500 rpm and the procedure was repeated 3 times. The viability of the protoscolices was evaluated using 0.1% eosin.¹⁷ For the validity test, 0.01 mL of the exposed protoscolices was transferred onto a slide and mixed with 0.01 mL of 0.1% eosin to look for dead or living protoscolices.²¹ The protoscolicidal ability of each agent was repeated 6 times. At least 250 protoscolices

were counted in each sample while the dead and living protoscolices were measured. The dead protoscolices were stained (figure 1A), while the living protoscolices remained colorless (figure 1B). These steps were also repeated at the exposure times of 2 and 5 minutes. The ANOVA test was utilized to compare the mean viability for the different materials. Additionally, the mean viability was compared between the group of agents via the least significant difference (LSD) method. The data were analyzed using SPSS software, version 8. A $P < 0.05$ was considered statistically significant. The mean percentage of the dead protoscolices and the agents used for each time of exposure are summarized in tables 1 to 3.

Results

The exposure results of the protoscolicidal agents are shown in tables 1, 2, and 3. In vitro observations at 5 minutes of exposure showed no difference between the garlic chloroformic extract (200 mg/mL) and 20% sodium chloride

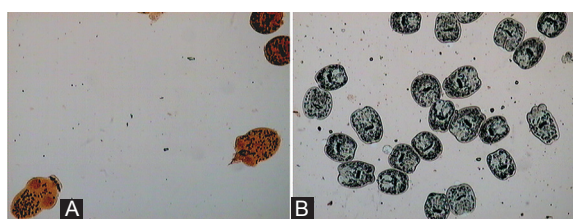


Figure 1: A) Dead protoscolices were stained red using 0.1% eosin. B) Living protoscolices were remained colorless using 0.1% eosin.

($P = 0.36$); however, the difference between these agents and 0.5% silver nitrate was significant ($P < 0.001$) (table 3).

According to table 1, while the protoscolicidal effects of the garlic chloroformic extract (200 mg/mL) at 1 minute were higher than those of 0.5% silver nitrate and 20% sodium chloride ($P < 0.001$), the effects were similar to those of 0.5% cetrime (= 0.36).

At 1 minute of exposure, the protoscolicidal effects of the garlic chloroformic extract (200 mg/mL) were significantly different from those of 0.5% silver nitrate and 20% hypertonic sodium chloride ($P < 0.001$ and $P = 0.003$).

The application of the agents at 2 minutes of exposure revealed no statistically significant difference in terms of protoscolicidal effects between the garlic chloroformic extract (200 mg/mL) and 0.5% cetrime (table 2). Nonetheless, the ANOVA test demonstrated statistically significant differences regarding protoscolicidal effects between 0.5% cetrime and the other agents ($P < 0.001$). Table 2 shows that while the mean protoscolicidal effect of the garlic chloroformic extract (200 mg/mL) was comparable with that of 0.5% cetrime, it was statistically different from that of the 20% sodium chloride, 0.5% silver nitrate, and normal saline groups ($P < 0.05$) (figure 1A and figure 1B).

Discussion

Different protoscolicidal agents have been used for hydatidosis as an important zoonotic disease.^{12,15-17,19} Nevertheless, the long exposure

Table 1: Protoscolicidal effects of the garlic chloroformic extract in comparison with cetrime, silver nitrate, and sodium chloride solutions at 1 minute of exposure**

Agents Groups	Test reagents	n	Mean protoscolices exposed	Mean protoscolices dead after Exposure \pm SD	% dead/total	LSD* P value
1	Cetrime 0.5%	6	255	255 \pm 0	100%	1 vs. 2: <0.001 1 vs. 3: <0.001 1 vs. 4: 0.037 1 vs. 5: <0.001
2	0.5% Silver nitrate	6	261	148 \pm 1.5	56.7%	2 vs. 1: <0.001 2 vs. 3: <0.001 2 vs. 4: <0.001 2 vs. 5: <0.001
3	20% Hypertonic sodium chloride	6	255	225 \pm 1.6	88.2%	3 vs. 1: <0.001 3 vs. 2: <0.001 3 vs. 4: <0.001 3 vs. 5: <0.001
4	Garlic chloroformic extract (200 mg/mL)	6	253	251 \pm 0.5	99.2%	4 vs. 1: 0.037 4 vs. 2: <0.001 4 vs. 3: <0.001 4 vs. 5: <0.001
5	Normal saline	6	265	5 \pm 0.6	1.8%	5 vs. 1: <0.001 5 vs. 2: <0.001 5 vs. 3: <0.001 5 vs. 4: <0.001

*Least significant difference; **P value for one-way ANOVA was <0.001

time of their application is not suitable for hydatid cyst surgery or the PAIR technique.

The World Health Organization has suggested that the protoscolicidal effects of protoscolicidal agents be compared to those of cetrimide.¹⁸ In the present study, this agent showed a 100% protoscolicidal effect at 1 minute of exposure. In addition, the protoscolicidal effects of the garlic chloroformic extract at 1 minute of exposure were similar to those of cetrimide, although the protoscolicidal effects of these 2 agents had a

significant difference with those of the other agents used.

Silver nitrate solution²¹ has been used since 1963. It has been observed that its 0.5% solution is more effective than its 1% solution.²¹ Protoscolices are killed within 30 seconds when exposed to 0.5% silver nitrate; their internal structure is separated and they form an individual granule. Be that as it may, in the present study, 0.5% silver nitrate exhibited only a 94% protoscolicidal effect. A concentrated salty

Table 2: Protoscolicidal effects of the garlic chloroformic extract in comparison with cetrimide, silver nitrate, and sodium chloride solutions at 2 minutes of exposure **

Agents Groups	Test reagents	n	Mean protoscolices exposed	Mean protoscolices dead after Exposure±SD	% dead/total	LSD P value
1	0.5% Cetrimide	6	252	252±0	100%	1 vs. 2: <0.001 1 vs. 3: 0.008 1 vs. 4: 0.104 1 vs. 5: <0.001
2	0.5% Silver nitrate	6	253	208±3.70	82.2%	2 vs. 1: <0.001 2 vs. 3: <0.001 2 vs. 4: <0.001 2 vs. 5: <0.001
3	20% Hypertonic sodium chloride	6	253	240±4	94.8%	3 vs. 1: 0.008 3 vs. 2: <0.001 3 vs. 4: <0.001 3 vs. 5: <0.001
4	Garlic chloroformic extract (200 mg/mL)	6	259	259±0	100%	4 vs. 1: 0.104 4 vs. 2: <0.001 4 vs. 3: <0.001 4 vs. 5: <0.001
5	Normal saline	6	257	5±1.7	1.95	5 vs. 1: <0.001 5 vs. 2: <0.001 5 vs. 3: <0.001 5 vs. 4: <0.001

**P value for one-way ANOVA was<0.001

Table 3: Protoscolicidal effects of the garlic chloroformic extract in comparison with cetrimide, silver nitrate, and sodium chloride solutions at 5 minutes of exposure**

Agents Groups	Test reagents	n	Mean protoscolices exposed	Mean protoscolices dead after Exposure±SD	% dead/total	LSD P value
1	0.5% Cetrimide	6	263	263 ± 0	100%	1 vs. 2: <0.001 1 vs. 3: 0.056 4 vs. 1: 0.510 1 vs. 5: <0.001
2	0.5% Silver nitrate	6	257	241 ± 1.5	93.8%	2 vs. 1: <0.001 2 vs. 3: <0.001 2 vs. 4: <0.001 2 vs. 5: <0.001
3	20% Hypertonic sodium chloride	6	258	257 ± 0.4	99.6%	3 vs. 1: 0.056 3 vs. 2: <0.001 3 vs. 4: 0.193 3 vs. 5: <0.001
4	Garlic chloroformic extract (200 mg/mL)	6	261	261 ± 0	100%	4 vs. 1: 0.510 4 vs. 2: <0.001 4 vs. 3: 0.193 4 vs. 5: <0.001
5	Normal saline	6	259	4 ± 1.6	1.4	5 vs. 1: <0.001 5 vs. 2: <0.001 5 vs. 3: <0.001 5 vs. 4: <0.001

**P value for one-way ANOVA was <0.001

solution will cause the lysis and devastation of protoscolices by establishing a proper osmotic difference in the cuticle or outer layer.²² A number of studies have demonstrated that sodium chloride at concentrations of 3% and 10% has no protoscolicidal effect, while at a 20% concentration and at 15 minutes of exposure, it is capable of devastating all protoscolices.²² In the present study, this agent showed 88%, 94.8%, and 99.6% protoscolicidal effects at exposure times of 1, 2, and 5 minutes, respectively.

Several studies have investigated the protoscolicidal effects of different anthelmintic drugs. For example, in an in vitro study, the effects of flubendazole at concentrations of 1, 5, and 10 µg/mL on the protoscolices of *E. granulosus* were examined and the results showed that the first signs of protoscolices destruction appeared 3 days after exposure to this drug; still, its obvious protoscolicidal effect (i.e., decrease in protoscolex viability) was seen 18 days after the drug exposure. Additionally, 25 days after the exposure of the protoscolices to fluconazole at a concentration of 5 µg/mL, only 13.9% of the protoscolices were viable and protoscolex mortality after 30 days of exposure was 100%. In that study, the validity test results were indicative of tissue damage at the ultrastructural level.¹⁵ Hosseini et al.¹⁷ compared protoscolicidal effects between hypertonic glucose at concentrations of 10, 15, 25, and 50% and some protoscolicidal agents such as 0.5% cetrimide (as a positive control), 0.5% silver nitrate, 20% hypertonic saline, and normal saline (as a negative control) at the exposure times of 1, 2, and 5 minutes and reported that the high concentration of glucose (50%) had a stronger protoscolicidal effect than 0.5% silver nitrate but this effect was similar to that of 20% hypertonic saline.

The importance of protoscolicidal agents is still considerable in the treatment of hydatid disease; nonetheless, the ideal substances are those which are highly effective, inexpensive, and quick-acting with the fewest complications. Since many of the protoscolicidal agents are not safe enough and induce some side effects, there is a tendency to use natural substances as protoscolicidal solutions. In an in vitro investigation, the essential oils of *Mentha piperita* and *Mentha pulegium* were used separately and both together as protoscolicidal agents at different concentrations and exposure times on the protoscolices of *E. granulosus*. The results indicated that *Mentha pulegium* had an obviously more potent protoscolicidal effect, with its maximum effect seen 12 days after incubation. Additionally, transmission electron microscopy proved the ultrastructural damage

to the protoscolices caused by this essential oil.²³ In another in vitro study, the protoscolicidal effects of the hydroalcoholic extract of *Satureja khuzestanica* leaves and the hydrated extract of *Olea europaea* leaves were examined at different concentrations and exposure times. Among them, concentrations of 0.1% and 0.01% had strong protoscolicidal effects at the exposure time of 120 minutes. *Satureja khuzestanica* at a concentration of 0.1% had a very strong protoscolicidal effect at the exposure times of 30, 60, and 120 minutes.⁶

Garlic has a special position among herbal and traditional medicines and its antibacterial,²⁴ antifungal,²⁵ and antiparasitic²⁶ effects have been confirmed in many studies. The scolical effects of *Allium sativum* flowers on hydatid cyst protoscolices have also been used with success.²⁷ Various extracts of garlic such as hydrated, alcoholic, and chloroformic extracts have exhibited significant effects on parasites such as *Hymenolepis nana*, *Leishmania*, and *Giardia intestinalis*.^{19,20} Their long-term (≥30 min) protoscolicidal effects were confirmed in an in vitro study,¹¹ which showed that the garlic chloroformic extract at a concentration of 200 mg/mL exerted good protoscolicidal effects on the protoscolices of hydatid cysts at an exposure time of 1 hour and longer. However, such long exposure times are not applicable during hydatid cyst surgery. We used the garlic chloroformic extract in the current study at exposure times much shorter than those in previous research.

In another in vitro study, the protoscolicidal effects of the metanolic extract of *Allium sativum* at 2 concentrations of 25 and 50 mg/mL at the exposure times of 10, 20, 30, 40, and 60 minutes were evaluated and the results showed that the protoscolicidal effect of the 50 mg/mL concentration was 100% after 10 minutes of exposure.¹² In contrast, in the present study, the garlic chloroformic extract (200 mg/mL) had a 100% protoscolicidal effect at shorter exposure times of 2 and 5 minutes. Among the agents tested, the garlic chloroformic extract, which has previously been evaluated in animals with acceptable results,²⁸ can be introduced as a new and desirable protoscolicidal agent.

Conclusion

According to the results of the present study, the chloroformic extract of garlic (200 mg/mL) has a high protoscolicidal effect at a short exposure time and it could, therefore, substitute the protoscolicidal agents in current use. To determine both whether the garlic extract has

any side effects in the human body and what concentrations and exposure times are suitable for cyst surgery or the PAIR technique, we recommend ex vivo and in vivo studies on this issue.

Acknowledgement

This study was granted by the office of Vice Chancellor for Research at Shiraz University of Medical Sciences, Grant no: 954.

Conflict of Interest: None declared.

References

- Craig PS, Hegglin D, Lightowers MW, Torgerson PR, Wang Q. Echinococcosis: Control and Prevention. *Adv Parasitol.* 2017;96:55-158. doi: 10.1016/bs.apar.2016.09.002. PubMed PMID: 28212791.
- Yanagida T, Mohammadzadeh T, Kamhawi S, Nakao M, Sadjjadi SM, Hijjawi N, et al. Genetic polymorphisms of *Echinococcus granulosus sensu stricto* in the Middle East. *Parasitol Int.* 2012;61:599-603. doi: 10.1016/j.parint.2012.05.014. PubMed PMID: 22668837.
- Sadjjadi SM. Present situation of echinococcosis in the Middle East and Arabic North Africa. *Parasitol Int.* 2006;55 Suppl:S197-202. doi: 10.1016/j.parint.2005.11.030. PubMed PMID: 16337429.
- Fallah M, Taherkhani H, Sadjjadi M. Echinococcosis in stray dogs in Hamedan, west of Iran. *Iran J Med Sci.* 1995;29:170-2.
- Sadjjadi SM, Sedaghat F, Hosseini SV, Sarkari B. Serum antigen and antibody detection in echinococcosis: application in serodiagnosis of human hydatidosis. *Korean J Parasitol.* 2009;47:153-7. doi: 10.3347/kjp.2009.47.2.153. PubMed PMID: 19488422; PubMed Central PMCID: PMC2688797.
- Sadjjadi SM, Ardehali S, Noman-Pour B, Kumar V, Izadpanah A. Diagnosis of cystic echinococcosis: ultrasound imaging or countercurrent immunoelectrophoresis? *East Mediterr Health J.* 2001;7:907-11. PubMed PMID: 15332731.
- Khalilpour A, Sadjjadi SM, Moghadam ZK, Yunus MH, Zakaria ND, Osman S, et al. Lateral flow test using *Echinococcus granulosus* native antigen B and comparison of IgG and IgG4 dipsticks for detection of human cystic echinococcosis. *Am J Trop Med Hyg.* 2014;91:994-9. doi: 10.4269/ajtmh.14-0170. PubMed PMID: 25200268; PubMed Central PMCID: PMC4228898.
- Mohammadzadeh T, Sako Y, Sadjjadi SM, Sarkari B, Ito A. Comparison of the usefulness of hydatid cyst fluid, native antigen B and recombinant antigen B8/1 for serological diagnosis of cystic echinococcosis. *Trans R Soc Trop Med Hyg.* 2012;106:371-5. doi: 10.1016/j.trstmh.2012.01.012. PubMed PMID: 22472966.
- Sadjjadi SM, Abidi H, Sarkari B, Izadpanah A, Kazemian S. Evaluation of enzyme linked immunosorbent assay, utilizing native antigen B for serodiagnosis of human hydatidosis. *Iran J Immunol.* 2007;4:167-72. doi: 10.1016/j.ijpara.2013.06.008. PubMed PMID: 23891711.
- Sadjjadi SM, Zoharizadeh MR, Panjeshahin MR. In vitro screening of different *Allium sativum* extracts on hydatid cysts protoscolices. *J Invest Surg.* 2008;21:318-22. doi: 10.1080/08941930802348261. PubMed PMID: 19160141.
- Moazeni M, Nazer A. In vitro effectiveness of garlic (*Allium sativum*) extract on scolices of hydatid cyst. *World J Surg.* 2010;34:2677-81. doi: 10.1007/s00268-010-0718-7. PubMed PMID: 20625727.
- Adas G, Arikan S, Kemik O, Oner A, Sahip N, Karatepe O. Use of albendazole sulfoxide, albendazole sulfone, and combined solutions as scolicidal agents on hydatid cysts (in vitro study). *World J Gastroenterol.* 2009;15:112-6. PubMed PMID: 19115476; PubMed Central PMCID: PMC2653288.
- Brunetti E, White AC, Jr. Cestode infestations: hydatid disease and cysticercosis. *Infect Dis Clin North Am.* 2012;26:421-35. doi: 10.1016/j.idc.2012.02.001. PubMed PMID: 22632647.
- Elissondo M, Dopchiz M, Ceballos L, Alvarez L, Sanchez Bruni S, Lanusse C, et al. In vitro effects of flubendazole on *Echinococcus granulosus* protoscolices. *Parasitol Res.* 2006;98:317-23. doi: 10.1007/s00436-005-0026-6. PubMed PMID: 16374619.
- Prasad J, Bellamy PR, Stubbs RS. Instillation of scolicidal agents into hepatic hydatid cysts: can it any longer be justified? *N Z Med J.* 1991;104:336-7. PubMed PMID:

- 1876339.
17. Hosseini SV, Ghanbarzadeh K, Barzin J, Sadjjadi SM, Tanideh N, Mehrabani D. In vitro protoscolicidal effects of hypertonic glucose on protoscolices of hydatid cyst. *Korean J Parasitol.* 2006;44:239-42. PubMed PMID: 16969062; PubMed Central PMCID: PMC2532656.
 18. Pawlowski ZS. Echinococcosis in human and clinical aspects, diagnosis and treatment in day. In: Eckert J, Gemmell MI, Mesline Fx, Pawlowski ZS, editors. *Manual on echinococcosis in Human and Animal: A Public Health Problem of Global Concern.* France: WHO/OIE; 2001. p. 20-71.
 19. Soffar SA, Mokhtar GM. Evaluation of the antiparasitic effect of aqueous garlic (*Allium sativum*) extract in *hymenolepiasis nana* and giardiasis. *J Egypt Soc Parasitol.* 1991;21:497-502. PubMed PMID: 1875077.
 20. Azadbakht M, Sadjjadi SM, Rostami J. Giardiacidal activity of the express obtained from bulbs of three *Allium* species on *Giardia intestinalis* cysts. *Iran J Basic Med Sci.* 2003;6:184-8. Persian.
 21. Meymerian E, Luttermoser GW, Frayha GJ, Schwabe CW, Prescott B. Host-Parasite Relationships in Echinococcosis: X. Laboratory Evaluation of Chemical Scolicides as Adjuncts to Hydatid Surgery. *Ann Surg.* 1963;158:211-5. PubMed PMID: 14047542; PubMed Central PMCID: PMC2532656.
 22. Abbassi Dezfuli A, Shishineh P, Shadmehr M, Ghaffarnejad M. Early and latest effects of scolicidal agents on liver and bile ducts, an experimental study. *Iranian J Med Sci.* 1991;16:36-9.
 23. Maggiore MA, Albanese AA, Gende LB, Eguaras MJ, Denegri GM, Elissondo MC. Anthelmintic effect of *Mentha* spp. essential oils on *Echinococcus granulosus* protoscoleces and metacestodes. *Parasitol Res.* 2012;110:1103-12. doi: 10.1007/s00436-011-2595-x. PubMed PMID: 21845411.
 24. Gonzalez-Fandos E, Garcia-Lopez ML, Sierra ML, Otero A. Staphylococcal growth and enterotoxins (A-D) and thermonuclease synthesis in the presence of dehydrated garlic. *J Appl Bacteriol.* 1994;77:549-52. PubMed PMID: 8002479.
 25. Appleton JA, Tansey MR. Inhibition of growth of zoopathogenic fungi by garlic extract. *Mycologia.* 1975;67:882-5. PubMed PMID: 1177972.
 26. Mansourian S, Sadjjadi SM, Hosseini SV, Barzin Z, Mehrabani D, Tanideh N, et al. Evaluation of different chemical agents on the germinative layer of sheep hydatid cyst after implantation to peritoneal cavity of BALB/c. *J Invest Surg.* 2009;22:183-7. doi: 10.1080/08941930902866238. PubMed PMID: 19466655.
 27. Rahimi-Esboei B, Ebrahimzadeh MA, Fathi H, Rezaei Anzahaee F. Scolicidal effect of *Allium sativum* flowers on hydatid cyst protoscolices. *Eur Rev Med Pharmacol Sci.* 2016;20:129-32. PubMed PMID: 26813464.
 28. Hosseini SV, Mohebzadeh J, Kumar PV, Mehrabani D, Bagheri M, Sadjjadi SM, et al. The effect of silver nitrate, chloroformic garlic extract, and normal saline in induction of sclerosing cholangitis in rabbits. *Saudi Med J.* 2008;29:1095-8. PubMed PMID: 18690298.