

Cortical aspiration - The "POPS" technique

Viraj A Vasavada, Abhay R Vasavada, Vijayavarshcini Dhanasekaran, Vaishali Vasavada, Aditya Sudhalkar, Shail Vasavada, Samaresh Srivastava, Alper Bilgic¹

In the present study, we describe a step-by-step technique for cortex aspiration during cataract surgery- POPS (positioning, occlusion, posterior displacement, and swiping). Firstly, the aspiration probe is positioned under the bulk of cortical fibers beyond the capsulorhexis margin. Subsequently, the aspiration port is occluded with minimal vacuum, and the occluded port is displaced posteriorly to detach the cortical fibers off the anterior capsule. Now, tangential, arc-like swiping movements are performed while gradually increasing vacuum at the same time. The fibers are brought to the center and finally aspirated. This allows complete removal of the equatorial fibers and lens epithelial cells (LEC) with the least stress to the capsulozonular complex. Unlike the conventional technique, which involves the radial pull of cortical fibers, in this technique, there is swiping and posterior displacement of the cortical fibers before pulling towards the center and aspirating. We believe this technique will ensure safer, more effective cortical and LEC removal, reducing zonular stress.

Key words: Capsule-zonular stress, cortex aspiration, occlude posterior detachment, position, stripping, technique

Videos Available on:
www.ijo.in

Access this article online

Website:
www.ijo.in

DOI:
10.4103/ijo.IJO_2384_19

Quick Response Code:



Incessant refinements in techniques and technology have made cataract surgery one of the most rewarding procedures, achieving pristine visual outcomes. Yet, the preservation of the same is put to test when the mitotically active lens epithelial cells (LECs) left behind in the capsular fornices lead to visually disabling posterior capsular opacification (PCO).^[1,2] Besides, these residual LECs are also responsible for anterior capsule fibrosis/opacification (ACO) and interlenticular opacification (ILO).^[3-6]

The role of meticulous cortex removal, particularly hydrodissection enhanced cortical cleanup in the reduction or retardation of PCO^[7-9] has been reported long ago. However, of all the steps involved in cataract surgery, the step of cortical removal is often not adequately emphasized and paid attention to. Cortical removal not only influences PCO, but if performed without due consideration, can lead to capsule-zonular stress, and can even lead to/enhance zonular dehiscence in eyes with preexisting zonular pathologies, such as pseudoexfoliation syndrome, Marfan's syndrome, homocysteinemia, or previous trauma. Herein, we describe a simple, step-by-step technique for cortical aspiration to ensure a more stress-free and thorough removal of cortical fibers as well as possibly even equatorial LECs.

Surgical Technique

This modified technique of cortical aspiration can be simplified into four basic steps – position, occlude, posterior displacement, and swiping (POPS). As a first step, the aspiration probe is positioned such that the aspiration port is placed under the

anterior capsular fibers beyond the capsulorhexis margin [Fig. 1a]. Care is taken to maintain a safe distance from the capsulorhexis edge and posterior capsule and to ensure that the aspiration port is facing toward the corneal endothelium. The second step involves pressing the foot pedal to occlude the anterior fibers with a minimal vacuum. With the port occluded, the aspiration probe is directed posteriorly to detach the cortical fibers off the anterior capsule [Fig. 1b]. Following this, circumferential arc-like swiping movements are performed to further detach these fibers from the capsular fornices [Fig. 1c]. Now, the vacuum is escalated, the aspiration port is brought to the center and the fibers are aspirated completely using linear vacuum and aspiration and flow rate [Fig. 1d]. This concept is demonstrated in this animation [Online Video 1]. The technique may be performed using bimanual irrigation/aspiration (I/A) or coaxial I/A. The preset parameters for cortical aspiration that we use are as follows: the vacuum of around 300 to 400 mmHg, aspiration flow rate (AFR) of 20 cc/min, and a bottle height around 80–90 cm. Both vacuum and AFR are used with linear control.

Results

The POPS technique is performed as a routine in all cases of manual phacoemulsification as well as femtosecond laser-assisted cataract surgeries (FLACS) in our center. Multiple surgeons, with

Iladevi Cataract and IOL Research Centre, Ahmedabad, Gujrat, India, ¹Department of Ophthalmology, Alphavision Augenzentrum Bremerhaven, Germany

Correspondence to: Dr. Viraj A Vasavada, Raghudeep Eye Hospital, Gurukul Road, Ahmedabad - 380 052, Gujarat, India. E-mail: viraj@raghudeepeyeclinic.com

Received: 27-Dec-2019

Revision: 01-Apr-2020

Accepted: 14-Apr-2020

Published: 26-Oct-2020

This is an open access journal, and articles are distributed under the terms of the Creative Commons Attribution-NonCommercial-ShareAlike 4.0 License, which allows others to remix, tweak, and build upon the work non-commercially, as long as appropriate credit is given and the new creations are licensed under the identical terms.

For reprints contact: WKHLRPMedknow_reprints@wolterskluwer.com

Cite this article as: Vasavada VA, Vasavada AR, Dhanasekaran V, Vasavada V, Sudhalkar A, Vasavada S, et al. Cortical aspiration - The "POPS" technique. Indian J Ophthalmol 2020;68:2476-8.

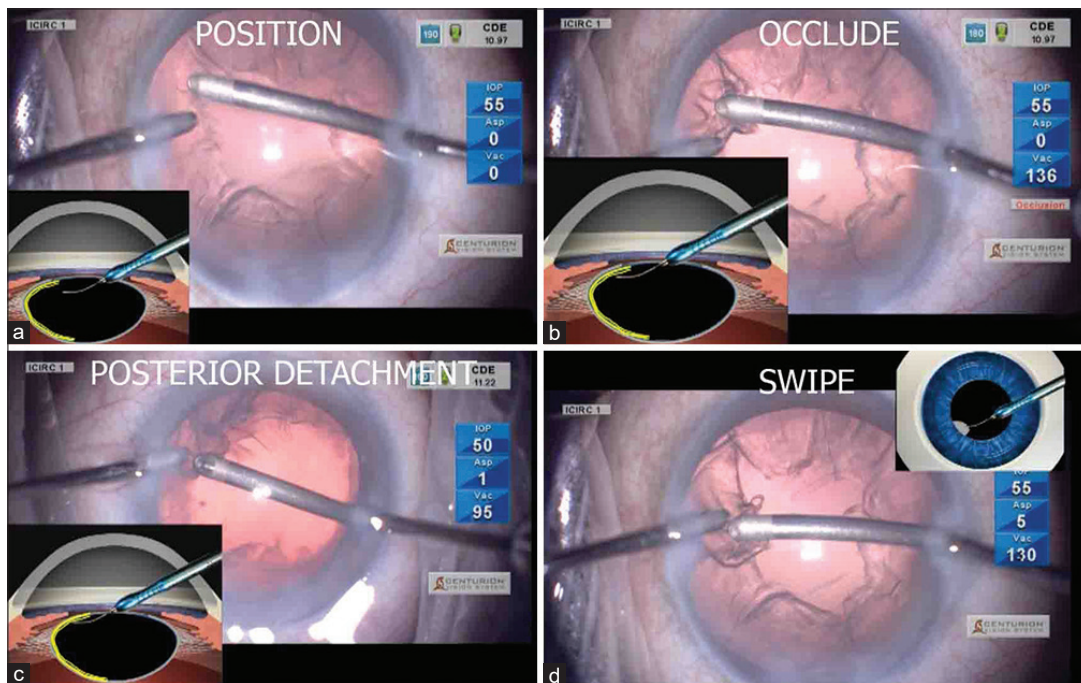


Figure 1: (a) The aspiration port is positioned beneath the cortical fibers well beyond the anterior capsulorhexis margin. (b) The vacuum is now built up by pressing the foot pedal, to achieve occlusion at the aspiration port (c) The entire aspiration probe, with the occluded fibers is now depressed posteriorly, with the port still facing upwards (d) With the occluded aspiration port, side-to-side movements of the entire probe is performed to ensure freeing the equatorial cortical fibers from the forniceal capsular attachments

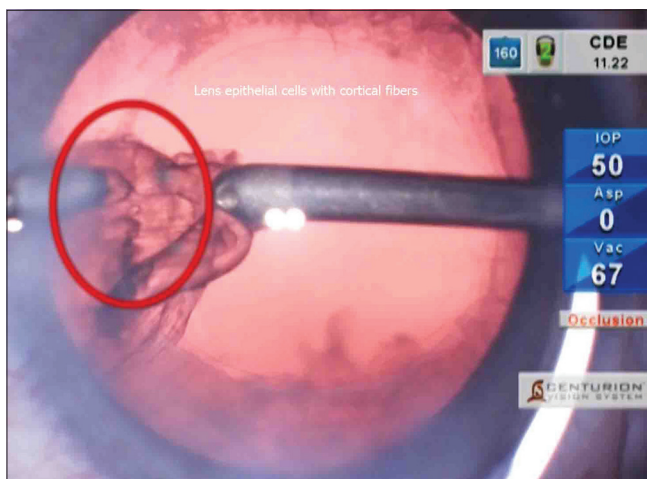


Figure 2: Lens epithelial cells being removed (red highlighted) along with cortical fibers during irrigation/aspiration

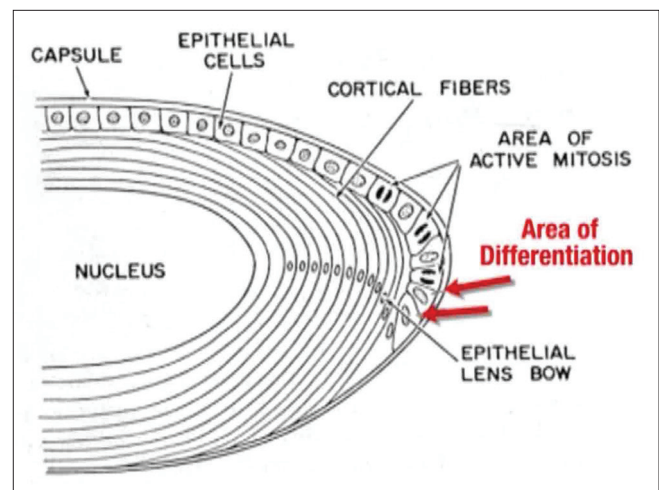


Figure 3: Equatorial, mitotically active LECs lining the lens capsule

varying degrees of surgical experience and expertise, perform cortical aspiration using this technique. We prefer bimanual I/A for all our cases, including difficult situations such as small pupils, pseudoexfoliation syndrome, and those with zonular weakness. In our consecutive series of more than 500 eyes, there have been no reported complications such as zonular dialysis or posterior capsule rupture (PCR) during the step of cortical aspiration. The POPS technique ensures a more thorough and complete cortical fiber removal, and therefore, probably a more effective LEC removal from the fornices [Fig. 2 and Online Video 2].

Discussion

It has been shown that mitotically active equatorial LECs are the major cause of PCO.^[1] If these cells are left behind,

no amount of anterior or posterior capsular polishing can prevent PCO formation.^[3,4] There have even been reports suggesting that posterior capsular polishing does not affect postoperative laser posterior capsulotomy rates.^[2] Therefore, the best way to ensure minimal PCO would be to perform as complete removal of the equatorial cortical fibers containing the germinative “B” type LECs as possible [Fig. 3]. A combination of a good cortical cleaving hydrodissection and subsequent meticulous cortical cleanup has been well-recognized as a means to achieve better cortical removal and thereby reduce PCO.^[7,8] However, the technique of cortex removal is often not paid much attention to during performing as well as teaching cataract surgery. The prevailing literature on cortical aspiration has mostly been a description of bimanual and coaxial techniques of irrigation and aspiration.^[3-6] In the

conventional technique of cortical aspiration, the aspiration port is placed just under the capsulorhexis margin and the anterior cortical fibers occluded. These fibers are then aspirated by pulling radially towards the center, all in one motion. Although this technique of centripetal pull will detach the anterior subcapsular fibers, it may cause the fibers to break off from their attachment to the equatorial region, resulting in residual cortical fibers along with LECs in the capsular fornices, invisible to surgeons. Further, when performing a radial pull of the fibers, there may be stress on the zonular apparatus, leading to localized dehiscence of weakness in the zonules. This would be particularly important in eyes with preexisting zonular pathologies, such as trauma, pseudo-exfoliation syndrome, Marfan's syndrome, homocystinemia, and other such conditions. Therefore, Nakano and coauthors^[10] have described the Hurricane technique for cortical removal. Here, tangential traction is applied circumferentially around the capsular bag, and this has been shown to reduce zonular stress as compared to radial pulling forces in conventional I/A very elegantly by the Miyake Apple viewing technique. However, compared to the Hurricane technique, the POPS technique not only involves circumferential swiping motion but also has an additional step of posterior displacement of the aspiration probe, which allows more complete removal of cortical fibers with a relatively lower vacuum. In our current series, none of the eyes where the POPS technique was performed needed an Nd:YAG laser capsulotomy until 12 months follow-up. However, this is our personal surgical experience in 500 eyes, where digital retroillumination images were captured at 1 month and 12-month follow-up intervals and the presence or absence of PCO in the central 3 mm and 5 mm zones of the optic analyzed. There was no comparative analysis with the radial pull technique. We do acknowledge that more randomized studies with larger sample sizes would be needed to provide clinical validation of this technique in comparison to the radial pull technique for PCO reduction.

The POPS technique aims to lay emphasis on and simplify the technique of cortical aspiration into four components. The positioning of the aspiration port is closer to the fibers attached to the anterior capsule. This facilitates their occlusion with a relatively little vacuum. Further, once occlusion is achieved, the posterior displacement of the probe causes detachment of the fibers from the undersurface of the anterior capsule. The cortical fibers are firmly attached to the LECs lining the anterior capsule. Posterior displacement of the occluded tip and not a radial pull with a high vacuum detaches the fibers off this attachment with the anterior capsule. Cortical fibers are firmly attached to the LECs lining the anterior capsule. Gentle, circumferential swiping movements then cause detachment of the entire bulk of occluded cortex from the forniceal capsular bag. Once these three steps are performed, then the occluded fibers may be pulled centripetally and aspirated. We believe that this technique enables us to completely remove the fibers harboring differentiating epithelial cells from the epithelial bow region. Moreover, since there are posterior displacement and swiping movements, these fibers are free from the equatorial capsule and therefore, the subsequent centripetal pull will exert minimal force on the zonules.

The POPS technique is very useful for beginner surgeons as well as experienced surgeons. It can be performed using bimanual or coaxial I/A, depending on the surgeon's comfort. The learning curve for this technique is small. However, it needs to be kept in mind that both posterior displacement and side-to-side swiping movements should be performed only once there is occlusion at the aspiration port. This can be recognized by paying attention to the occlusion sound in the phacoemulsification machine. If this is kept in mind, there

is no additional risk of capsular damage even in the hands of beginner surgeons. This technique is also very useful in cases with corticocapsular adhesions,^[11] zonular weakness, pseudoexfoliation, or posterior capsule rupture where cortex removal is being performed with an I/A probe or a vitrector. With the widespread use of FLACS, cortex removal is a little different than manual phacoemulsification, since the femtosecond laser leaves behind a sharply cut edge of the cortex. In the absence of free edges of cortical fibers, the POPS technique has an advantage over conventional radial pulling technique as the aspiration port is placed underneath the bulk of cortical fibers.

Conclusion

To conclude, the POPS technique simplifies the core components of the very important maneuver of cortex removal into four basic steps, which, if followed, will make cortex aspiration safer, effective, and will ensure a stress-free as well as more thorough removal of the cortex and equatorial lens epithelial cells.

Financial support and sponsorship

Nil.

Conflicts of interest

There are no conflicts of interest.

References

1. Apple DJ. Influence of intraocular lens material and design on postoperative intracapsular cellular reactivity. *Trans Am Ophthalmol Soc* 2000;98:257-83.
2. Werner L, Apple DJ, Pandey SK. Postoperative proliferation of anterior and equatorial lens epithelial cells: A comparison between various foldable IOL designs. In: Buratto L, Osher R, Masket S, editors. *Cataract Surgery in Complicated Cases*. Thorofare, NJ, Slack Inc.; 2000. p. 399-417.
3. Werner L, Pandey SK, Escobar-Gomez M, Visessook N, Peng Q, Apple DJ. Anterior capsule opacification: A histopathological study comparing different IOL styles. *Ophthalmology* 2000;107:463-67.
4. Werner L, Pandey SK, Apple DJ, Escobar-Gomez M, McLendon L, Macky T. Anterior capsule opacification: Correlation of pathological findings with clinical sequelae. *Ophthalmology* 2001;108:1675-81.
5. Gayton JL, Apple DJ, Peng Q, Visessook N, Sanders V, Werner L, et al. Interlenticular opacification: Clinicopathological correlation of a complication of posterior chamber piggyback intraocular lenses. *J Cataract Refract Surg* 2000;26:330-6.
6. Werner L, Apple DJ, Pandey SK, Snyder ME, Brint SF, Gayton JL, et al. Analysis of elements of interlenticular opacification. *Am J Ophthalmol* 2002;133:320-26.
7. Peng Q, Apple DJ, Visessook N, Werner L, Pandey SK, Escobar-Gomez M, et al. Surgical prevention of posterior capsule opacification. Part II. Enhancement of cortical clean up by focusing on hydrodissection. *J Cataract Refract Surg* 2000;26:188-97.
8. Vasavada AR, Singh R, Apple DJ, Trivedi RH, Pandey SK, Werner L. Efficacy of hydrodissection step in the phacoemulsification for age related senile cataract. *J Cataract Refract Surg* 2002;28:1623-28.
9. Vasavada AR, RajSM, Johar K, Nanavaty MA. Effect of hydrodissection alone and hydrodissection combined with rotation on lens epithelial cells: Surgical approach for the prevention of posterior capsule opacification. *J Cataract Refract Surg* 2006;32:145-50.
10. Nakano CT, Motta AF, Hida WT, Nakamura CM, Tzelikis PF, Ruiz Alves M, et al. Hurricane cortical aspiration technique: One-step continuous circular aspiration maneuver. *J Cataract Refract Surg* 2014;40:514-6.
11. Vasavada AR, Goyal D, Shastri L, Singh R. Corticocapsular adhesions and their effect during cataract surgery. *J Cataract Refract Surg* 2003;29:309-14.