

Metastatic Thyroid Cartilage Lesion from Prostatic Adenocarcinoma on ⁶⁸Ga-Prostate-Specific Membrane Antigen Positron Emission Tomography-Computed Tomography Scan: Case Series

Abstract

Prostate cancer usually metastasizes to regional lymph nodes and bone. Laryngeal cartilage metastases are very rare and only few cases have been published so far describing thyroid cartilage metastatic lesions from prostate cancer. Here, we describe 5 cases of carcinoma prostate, 3 staging and 2 follow-up, where ⁶⁸Ga-prostate-specific membrane antigen positron emission tomography/computed tomography (PET/CT) scan revealed multiple skeletal lesions along with thyroid cartilage metastasis. Initially, laryngeal cartilage metastases remain asymptomatic and in later stages patients present with symptoms. These metastatic lesions to thyroid cartilage are rare entities and can often easily be missed on conventional imaging. PET-CT imaging has overcome this diagnostic problem due to its ability to provide for both anatomical and functional imaging.

Keywords: ⁶⁸Ga prostate-specific membrane antigen positron emission tomography/computed tomography scan, adenocarcinoma prostate gland, thyroid cartilage

Introduction

Prostate cancer is primarily a disease of the elderly with majority of patients presenting with age above 65 years.^[1] It is the most common cancer in men worldwide and fifth most common cancer overall. Most metastatic prostate cancer patients present with high serum prostate-specific antigen (PSA) levels and often metastases occur at sites such as pelvic lymph nodes (LNs), bones, lungs, and liver in advanced cases. In literature, very few cases have been described of metastatic lesions from prostate carcinoma to thyroid cartilage. Here, we describe 5 cases with rare presentation of metastatic lesions to thyroid cartilage detected on ⁶⁸Ga prostate-specific membrane antigen (PSMA) positron emission tomography/computed tomography (PET/CT) scan.

Case Reports

The salient features of all 5 cases are described in Table 1.

Case 1

A 65-year-old male patient, recently diagnosed case of carcinoma prostate

This is an open access journal, and articles are distributed under the terms of the Creative Commons Attribution-NonCommercial-ShareAlike 4.0 License, which allows others to remix, tweak, and build upon the work non-commercially, as long as appropriate credit is given and the new creations are licensed under the identical terms.

For reprints contact: WKHLRPMedknow_reprints@wolterskluwer.com

gland, was referred for staging whole body ⁶⁸Ga-PSMA PET/CT scan. Anterior and lateral maximal intensity projection (MIP) [Figure 1a and b] images revealed multiple PSMA avid lesions. Axial CT and fused PET/CT images [Figure 1c-f] in bone and soft-tissue window showed PSMA avid sclerotic lesions in the bilateral laminae of the thyroid cartilage. Axial CT and fused PET/CT images [Figure 1g and h] also showed PSMA avid primary lesion in the prostate gland.

Case 2

A 92-year-old male, recently diagnosed case of carcinoma prostate gland was referred for staging ⁶⁸Ga-PSMA PET/CT scan. Anterior and lateral MIP [Figure 2a and b] image showed multiple PSMA avid lesions. Axial CT and fused PET/CT images [Figure 2c-f] in bone and soft-tissue window showed PSMA avid sclerotic lesion in the left lamina of the thyroid cartilage. Axial CT and fused PET/CT images [Figure 2g and h] also showed PSMA avid primary lesion in the prostate gland.

Case 3

A 54-year-old male patient, recently diagnosed case of carcinoma prostate

How to cite this article: Gupta N, Verma R, Belho ES. Metastatic thyroid cartilage lesion from prostatic adenocarcinoma on ⁶⁸Ga-prostate-specific membrane antigen positron emission tomography-computed tomography scan: Case series. Indian J Nucl Med 2021;36:183-8.

**Nitin Gupta,
Ritu Verma,
Ethel Shangne
Belho**

Department of Nuclear
Medicine, Mahajan Imaging
Centre, Sir Ganga Ram
Hospital, New Delhi, India

Address for correspondence:

Dr. Nitin Gupta,
Department of Nuclear
Medicine, Mahajan Imaging
Centre, Sir Ganga Ram
Hospital, New Delhi, India.
E-mail: drnitingpt@gmail.com

Received: 26-10-2020

Revised: 02-12-2020

Accepted: 07-12-2020

Published: 21-06-2021

Access this article online

Website: www.ijnm.in

DOI: 10.4103/ijnm.ijnm_218_20

Quick Response Code:



Table 1: Clinical and imaging details of patients

Age (years)	History	Scan findings	Thyroid cartilage lesions findings
Case 1 65	Staging scan, serum PSA >100 ng/mL, Gleason's score 4+5=9	PSMA avid lesions in primary prostate gland and metastatic abdominal and pelvic lymph nodes, lung lesions and sclerotic skeletal lesions	PSMA avid sclerotic lesions in both laminae of the thyroid cartilage (more in right lamina) with SUVmax of 8.7
Case 2 92	Staging scan, serum PSA 3983.85 ng/mL, Gleason's score 4+5=9	PSMA avid lesions in primary prostate gland and metastatic abdominal and pelvic lymph nodes and sclerotic skeletal lesions	PSMA avid sclerotic lesion in the left lamina of the thyroid cartilage posteriorly with associated soft-tissue component with SUVmax of 40.0
Case 3 54	Staging scan, serum PSA 210 ng/mL, Gleason's score 4+4=8	PSMA avid lesions in primary prostate gland and metastatic left cervical, left supraclavicular, abdominal and pelvic lymph nodes and sclerotic skeletal lesions	PSMA avid subtle sclerotic lesion in the right lamina of the thyroid cartilage posteriorly with SUVmax of 21.1
Case 4 72	Follow-up case of carcinoma prostate gland, on Injection Denosumab and hormonal therapy, being evaluated for rising serum PSA levels, with recent value of 411 ng/mL	PSMA avid lesions in primary prostate gland and metastatic mildly PSMA avid liver lesions, left adrenal gland lesion, and sclerotic skeletal lesions	PSMA avid mixed lytic-sclerotic lesion in the left lamina of the thyroid cartilage with SUVmax of 8.8
Case 5 69	Follow up case of carcinoma prostate gland, on hormonal therapy, being evaluated for rising serum PSA levels with recent value of 180 ng/ml	PSMA avid lesions in primary prostate gland and metastatic liver lesions, abdominal lymph nodes and skeletal lesions	PSMA avid sclerotic lesion in the right lamina of thyroid cartilage with SUVmax of 11.6

PSA: Prostate-specific antigen, SUVmax: Maximum standardized uptake values, PSMA: Prostate-specific membrane antigen

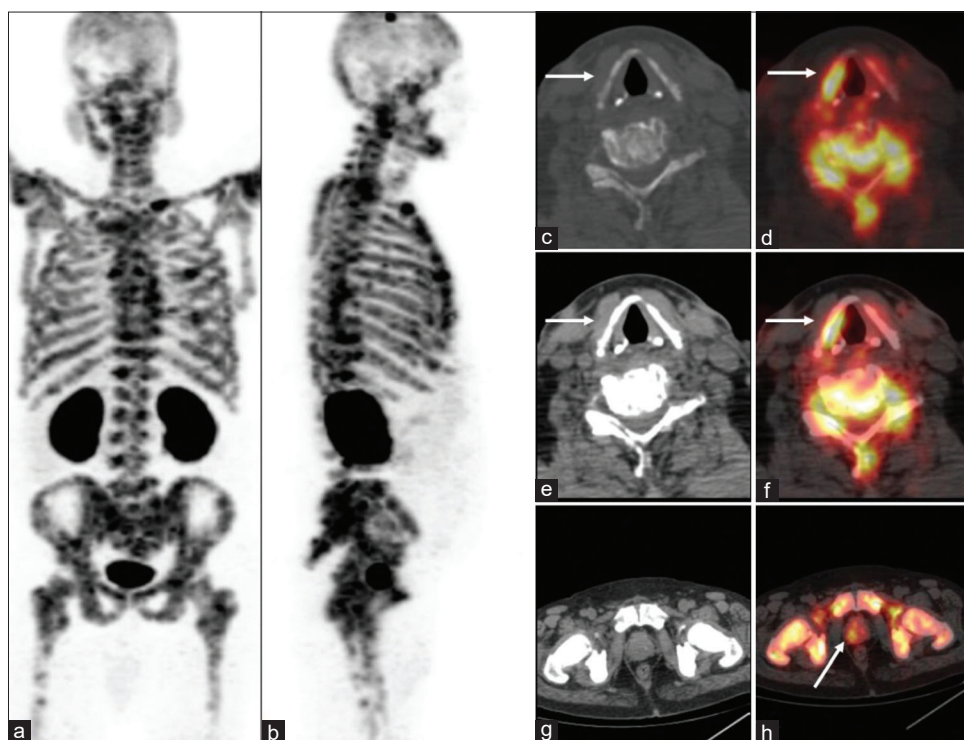


Figure 1: ⁶⁸Ga-prostate-specific membrane antigen positron emission tomography/computed tomography scan, anterior and lateral maximal intensity projection (a and b) suggestive of multiple prostate-specific membrane antigen avid lesions. Axial computed tomography and fused positron emission tomography/computed tomography images (c-f) showing prostate-specific membrane antigen avid lesions in the thyroid cartilage and multiple prostate-specific membrane antigen avid sclerotic skeletal metastases. Axial computed tomography and fused positron emission tomography/computed tomography images (g and h) showing prostate-specific membrane antigen avid primary lesion in the prostate gland

gland, was referred for staging ⁶⁸Ga-PSMA PET/CT scan. Anterior and lateral MIP [Figure 3a and b] images showed multiple PSMA avid lesions. Axial CT and fused

PET/CT images [Figure 3c-f] in bone and soft-tissue window showed PSMA avid subtle sclerotic lesion in the right lamina of the thyroid cartilage. Axial CT and fused

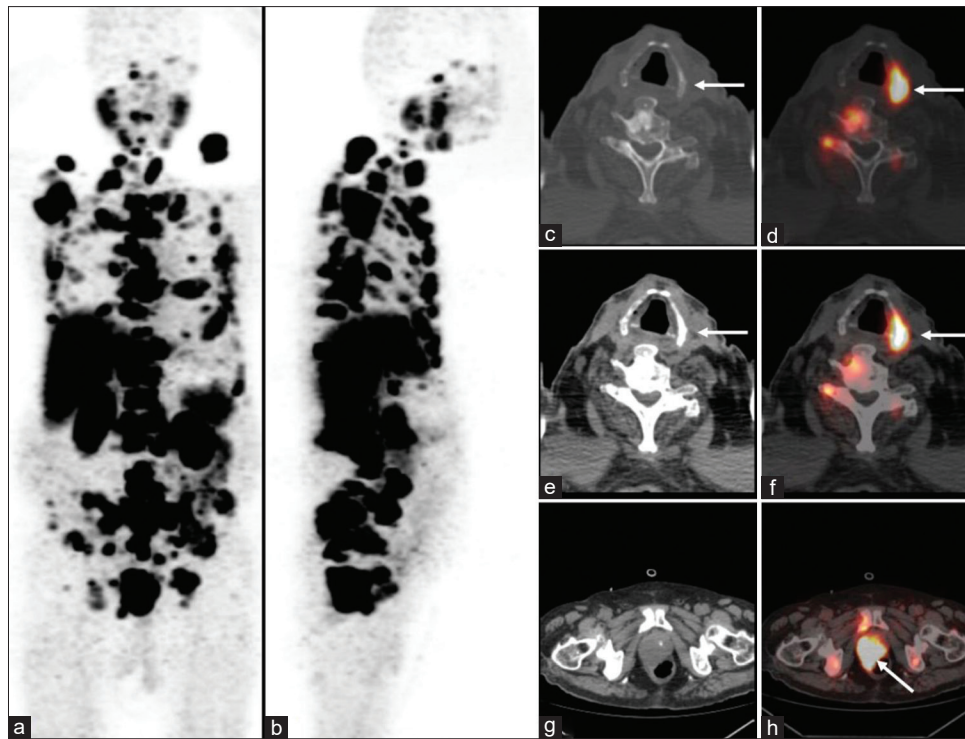


Figure 2: ^{68}Ga -prostate-specific membrane antigen positron emission tomography/computed tomography scan, anterior and lateral maximal intensity projection (a and b) image showing multiple prostate-specific membrane antigen avid lesions. Axial computed tomography and fused positron emission tomography/computed tomography images (c-f) showing prostate-specific membrane antigen avid lesion in the left lamina of the thyroid cartilage posteriorly and few prostate-specific membrane antigen avid sclerotic skeletal metastasis. Axial computed tomography and fused positron emission tomography/computed tomography images (g and h) showing prostate-specific membrane antigen avid primary lesion in the prostate gland

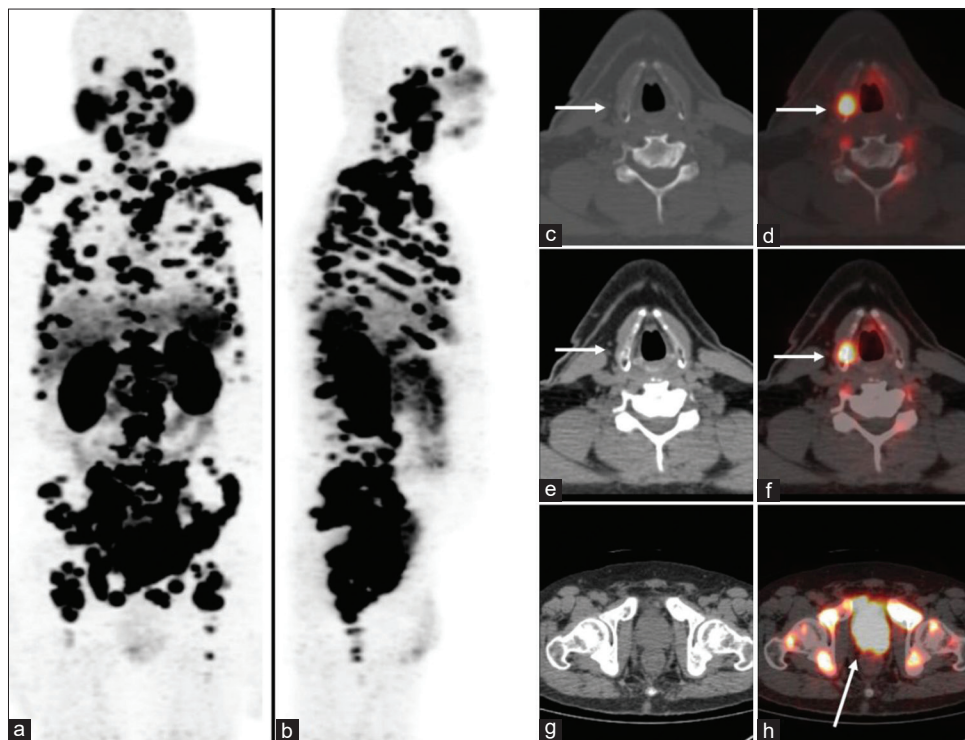


Figure 3: ^{68}Ga -prostate-specific membrane antigen positron emission tomography/computed tomography scan, anterior and lateral maximal intensity projection (a and b) image showing extensive prostate-specific membrane antigen avid metastatic lesions. Axial computed tomography and fused positron emission tomography/computed tomography images (c-f) showing prostate-specific membrane antigen avid lesion in the right lamina of the thyroid cartilage posteriorly. Axial computed tomography and fused positron emission tomography/computed tomography images (g and h) showing prostate-specific membrane antigen avid primary lesion in the prostate gland and multiple prostate-specific membrane antigen avid sclerotic skeletal metastases

PET/CT images [Figure 3g and h] also showed PSMA avid primary lesion in the prostate gland.

Case 4

A 72-year-old male patient, follow-up case of carcinoma prostate gland, on injection denosumab and hormonal therapy, being evaluated for rising serum PSA levels, was referred for ^{68}Ga -PSMA PET/CT scan. Anterior and lateral MIP [Figure 4a and b] images showed multiple PSMA avid lesions. Axial CT and fused PET/CT images [Figure 4c-f] in bone and soft-tissue window showed PSMA avid mixed lytic-sclerotic lesion in the left lamina of the thyroid cartilage with maximum standardized uptake values (SUV_{max}) of 8.8. Axial CT and fused PET/CT images [Figure 4g and h] also showed PSMA avid primary lesion in the prostate gland.

Case 5

A 69-year-old male patient, follow-up case of carcinoma prostate gland, on hormonal therapy, being evaluated for rising serum PSA levels, was referred for ^{68}Ga -PSMA PET/CT scan. Anterior and lateral MIP [Figure 5a and 5b] images showed multiple PSMA avid lesions. Axial CT and fused PET/CT images [Figure 5c-f] in bone and soft-tissue window showed PSMA avid sclerotic lesion in the thyroid cartilage with SUV_{max} of 11.6. Axial CT and fused PET/CT images [Figure 5g-h] also showed PSMA avid primary lesion in the prostate gland.

Discussion

Prostate cancer is mainly a disease of the elderly with majority of the cases occurring in men above 65 years of age. Prostate cancer is the most common cancer in men and is the second leading cause of cancer deaths among men.^[2] PSMA is a Type II integral membrane glycoprotein with a large extracellular domain,^[3] with increased expression in metastatic disease and disease recurrence. Accurate staging of prostate cancer is of high importance for treatment decisions and patient management. Prostate cancer most often spreads to LNs and bone, and high PSMA expression has been demonstrated in adenocarcinoma of the prostate and its metastatic sites.

Melanomas and hypernephromas have been found to be the most common tumors in case of laryngeal metastasis diagnosis, followed by breast, lung, and colon tumors.^[4] Although prostate cancer can metastasize to any part of the body, thyroid cartilage metastases are extremely rare and only few reports are available in literature describing the same. Metastatic involvement of the larynx is very uncommon due to the absence of vessels within the cartilaginous tissue. The thyroid cartilage involvement is suggestive of poor prognosis as it means extensive metastases.^[5] In case of advanced prostatic cancer, the ossified laryngeal cartilage can be affected, like any other bone of the skeleton. The tumor cells first metastasize to

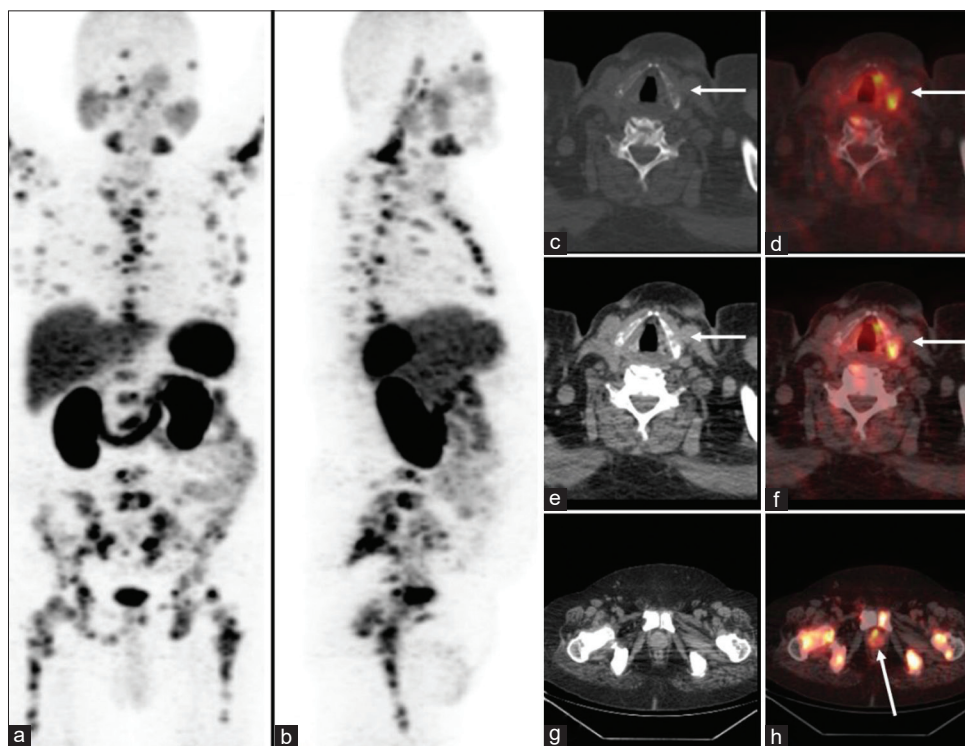


Figure 4: ^{68}Ga -prostate-specific membrane antigen positron emission tomography/computed tomography scan, anterior and lateral maximal intensity projection (a and b) image suggestive of multiple PSMA avid metastatic lesions. Axial computed tomography and fused positron emission tomography/computed tomography images (c-f) showing prostate-specific membrane antigen avid lesion in left lamina of the thyroid cartilage and few prostate-specific membrane antigen avid sclerotic skeletal lesions. Axial computed tomography and fused positron emission tomography/computed tomography images (g and h) showing prostate-specific membrane antigen avid primary lesion in the prostate gland and few prostate-specific membrane antigen avid sclerotic skeletal lesions

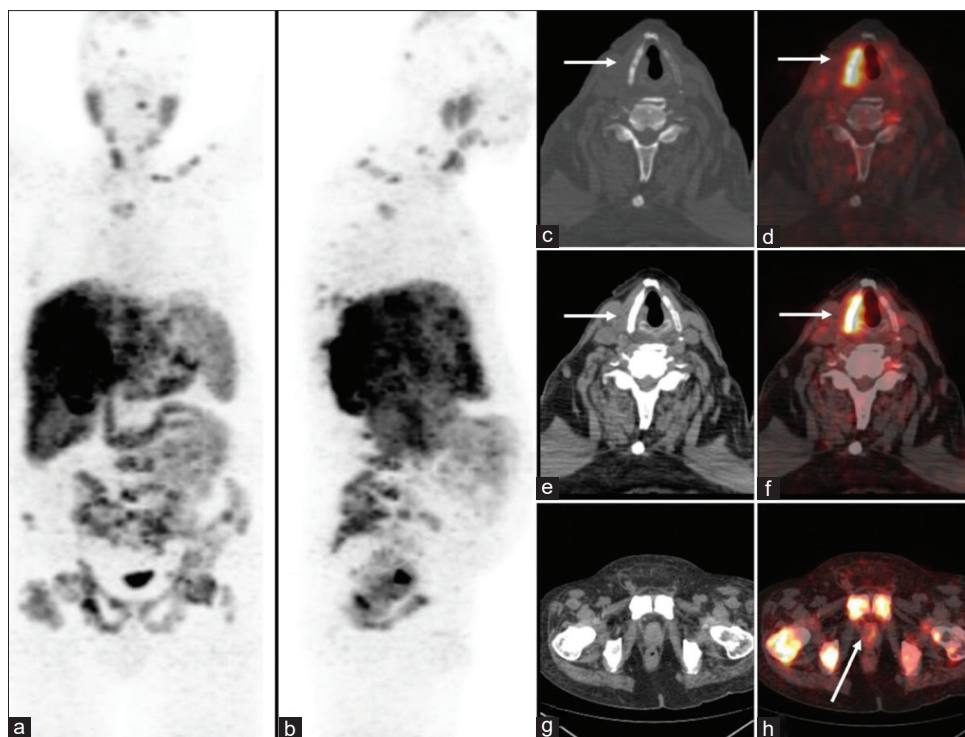


Figure 5: ^{68}Ga -prostate-specific membrane antigen positron emission tomography/computed tomography scan, Anterior and lateral maximal intensity projection (a and b) suggestive of multiple prostate-specific membrane antigen avid lesions. Axial computed tomography and fused positron emission tomography/computed tomography images (c-f) showing prostate-specific membrane antigen avid lesion in the right lamina of the thyroid cartilage. Axial computed tomography and fused positron emission tomography/computed tomography images (g and h) suggestive of prostate-specific membrane antigen avid primary lesion in the prostate gland and prostate-specific membrane antigen avid skeletal metastases

the hematopoietic tissue within the laryngeal cartilages, followed by local destruction and subsequent development of a perilaryngeal soft-tissue mass.^[5] The various symptoms with which the patient can present are hoarseness of voice, neck pain, or respiratory distress.^[6] The first fully documented case was from an adenocarcinoma of the kidney.^[7] The first case report describing thyroid cartilage metastasis from prostate cancer was published in 1954.^[6] Few cases have been described in literature previously of metastasis to cartilages of larynx.^[8-12] The laryngeal metastases usually remain unnoticed and may or may not present with clinical symptoms. The same was seen in our series and none of the patient had any thyroid cartilage involvement symptoms and since multiple metastases were seen, the histopathological confirmation of the thyroid cartilage lesions was not done. Out of 5 patients discussed in our series, 3 had thyroid cartilage involvement in staging and only and in other 2 the metastatic lesions in thyroid cartilage were detected on follow-up.

The CT characteristics features for detecting cartilage involvement by neoplastic lesion are sclerosis, erosion, lysis, and presence of extralaryngeal tissue. While sclerosis has high sensitivity (83%), it has low specificity (40% for thyroid cartilage).^[13] Erosion or lysis are highly specific criteria (86–95%) for neoplastic cartilage disease, however, their sensitivity varies, as they occur in late course of disease. Magnetic resonance imaging has high

sensitivity (89–95%) but lower specificity (74–84%) as compared to CT for the detection of cartilage invasion.^[14] The recent fusion imaging PSMA PET/CT scan can help in staging carcinoma prostate and detecting common and uncommon sites of metastasis due to high sensitivity. This case series highlights the great potential of PSMA PET/CT in detecting anatomically occult lesions which would have been otherwise missed on conventional imaging.

Declaration of patient consent

The authors certify that they have obtained all appropriate patient consent forms. In the form the patient (s) has/have given his/her/their consent for his/her/their images and other clinical information to be reported in the journal. The patients understand that their names and initials will not be published and due efforts will be made to conceal their identity, but anonymity cannot be guaranteed.

Financial support and sponsorship

Nil.

Conflicts of interest

There are no conflicts of interest.

References

1. Hariharan K, Padmanabha V. Demography and disease characteristics of prostate cancer in India. *Indian J Urol* 2016;32:103-8.

2. Siegel RL, Miller KD, Jemal A. Cancer statistics, 2020. *CA Cancer J Clin* 2020;70:7-30.
3. Jadvar H. PSMA PET in prostate cancer. *J Nucl Med* 2015;56:1131-2.
4. Batsakis JG, Luna MA, Byers RM. Metastases to the larynx. *Head Neck Surg* 1985;7:458-60.
5. Prescher A, Schick B, Stütz A, Brors D. Laryngeal prostatic cancer metastases: An underestimated route of metastases? *Laryngoscope* 2002;112:1467-73.
6. EHRlich A. Tumor involving the laryngeal cartilages. *AMA Arch Otolaryngol* 1954;59:178-85.
7. Turner AL. Metastatic malignant tumour of the larynx, secondary to adenocarcinoma of the right kidney. *J Laryngol Otol* 1924;39:181-94.
8. Tupalli A, Damle NA, Thankarajan AS, Mangu BS, Kumar A, Khan D, *et al.* An unusual case of simultaneous cricoid and thyroid cartilage metastases from prostatic adenocarcinoma on ⁶⁸Ga-PSMA PET/CT. *Nucl Med Mol Imaging* 2020;54:61-2.
9. Annovazzi A, Faiella A, Pescarmona E, Sanguineti G, Sciuto R. Asymptomatic metastasis to thyroid cartilage detected by 18F-choline and 64Cu-PSMA PET/CT as a single site of disease relapse in a patient with castration-resistant prostate carcinoma. *Clin Nucl Med* 2020;45:214-6.
10. Escudero RM, Amo FH, Martínez MC, Jiménez JT, Alonso AH, Piniés GO, *et al.* Metastatic prostate cancer on the thyroid cartilage: Unusual symptoms of prostatic adenocarcinoma. Case report. *Arch Esp Urol* 2011;64:132-5.
11. Olvera M, Delgado M, Vázquez M, Zavala J, Macedo V, Puentes M, *et al.* Unusual presentation of prostate cancer metastatic to the cricoid cartilage and oral cavity. *Case Rep Med* 2018;2018:5207204.
12. Ng SJ, Sinha AK, Loi HY, Khor LK. Asymptomatic metastasis to cricoid from prostate carcinoma: An incidental finding detected on 18F-choline PET/CT. *Jpn J Radiol* 2015;33:298-301.
13. Beitler JJ, Muller S, Grist WJ, Corey A, Klein AM, Johns MM, *et al.* Prognostic accuracy of computed tomography findings for patients with laryngeal cancer undergoing laryngectomy. *J Clin Oncol* 2010;28:2318-22.
14. Zbären P, Becker M, Läng H. Pretherapeutic staging of laryngeal carcinoma. Clinical findings, computed tomography, and magnetic resonance imaging compared with histopathology. *Cancer* 1996;77:1263-73.