

## Robot-assisted laparoscopic pyeloplasty for ureteropelvic junction obstruction with duplex system

Kazuyuki Numakura, Yumina Muto, Mitsuru Saito, Shintaro Narita, Takamitsu Inoue, Tomonori Habuchi\*

Akita University Graduate School of Medicine, Department of Urology, Japan

### ARTICLE INFO

#### Keywords:

Ureteropelvic junction obstruction  
Duplex system  
Robotics surgery

### ABSTRACT

Management of ureteropelvic junction obstruction with a duplex system is technically challenging even when laparoscopic procedure is the standard approach for ureteropelvic junction obstruction. The patient was an otherwise healthy 21-year-old woman who presented with symptomatic ureteropelvic junction obstruction with the duplex system, which was completely excised using a robot-assisted approach. Robotic assistance allows for proper tissue dissection, minimal manipulation of the normal ureter, and meticulous fine suturing and would overcome the potential challenges involved in the minimally invasive management of such complex anomalies as shown in this patient.

### Introduction

Ureteropelvic junction obstruction (UPJO) is a common anomaly of the genitourinary tract, and laparoscopic pyeloplasty is a standard approach for patients because its long-term outcome is equivalent to open approach. Furthermore, robot-assisted laparoscopic pyeloplasty has been accepted as the standard approach by urologic surgeons because of its superiority over conventional laparoscopy in terms of the fine procedure.

A duplex kidney system is an also relatively common anomaly as well as UPJO. The prevalence of the anomaly was reported at 0.8% in the general population. However, obstruction at the level of the UPJ in duplex kidneys is rarely seen, with an incidence was 2–7% in all duplex cases.

The use of robotic assistance in urologic laparoscopic surgery has expanded exponentially in recent years, given the unique features provided by the robotic platform, especially for reconstructive procedures where extensive dissection and suturing is necessary.

Here, we describe our experience of performing robot-assisted laparoscopic pyeloplasty in a patient presented with repeated urinary tract infections (UTI) due to UPJO with a duplex system.

### Case presentation

A 21-year-old woman presented with repeated UTIs, at least three

times, during the course of 1 year. Ultrasonography and computed tomography (CT) scan revealed hydronephrosis of the left kidney. Retrograde pyelography showed a left partial duplex system with the upper calyx as the upper moiety and the mid/lower calyx as the lower moiety. An UPJO was confirmed in the ureter as having originated from the extensive dilated lower moiety of the two systems (Fig. 1). Because of this complex anomaly, we planed a robot-assisted laparoscopic pyeloplasty after approval by the institutional review board.

The port placement was similar to standard robot-assisted laparoscopic pyeloplasty with ports for a camera, two robotic arms and an additional 10 mm port for assistance (Fig. 2). The Toldt line was incised, and the descending colon was mobilized. The Gerota's fascia was incised longitudinally, and the psoas muscle was identified. The ureter was identified by peristaltic movements and traced back to the UPJ of the lower collecting system with some adhesions to the surrounding fibrofatty tissue, which could be caused by repeated UTIs. The renal pelvis was dissected free, and the duplex system was identified (Fig. 3-A). The pelvis of the lower moiety was dilated extensively with a narrow segment at the UPJ. The UPJ of the lower moiety was incised and extended beyond into the renal pelvis (Fig. 3-B). The narrowed UPJ segment of the lower moiety was divided, and the common ureter was spatulated (Fig. 3-C). End to side pyeloureterostomy was performed with using 5-0 monocril sutures in a running fashion (Fig. 3-D). A double-J stent (DJS) was introduced across the anastomosis into both the bladder and lower moiety (Fig. 3-E). The total operative time was

\* Corresponding author. Akita University Graduate School of Medicine, 1-1-1 Hondo, Akita 010-8543, Japan.

E-mail address: [thabuchi@doc.med.akita-u.ac.jp](mailto:thabuchi@doc.med.akita-u.ac.jp) (T. Habuchi).

<https://doi.org/10.1016/j.eucr.2020.101138>

Received 16 January 2020; Accepted 18 February 2020

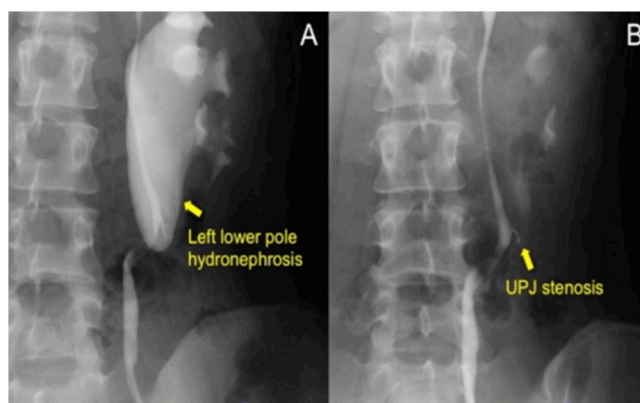
Available online 21 February 2020

2214-4420/© 2020 The Author(s).

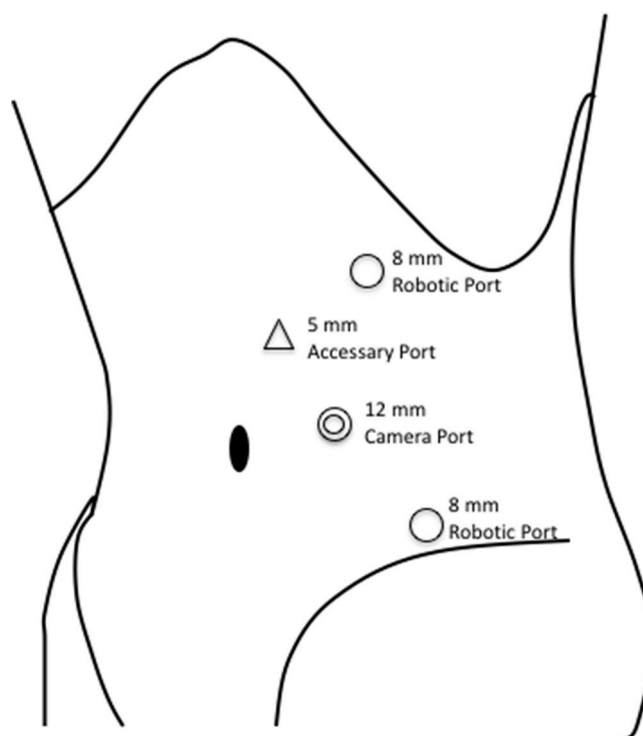
Published by Elsevier Inc.

This is an open access article under the CC BY-NC-ND license

(<http://creativecommons.org/licenses/by-nc-nd/4.0/>).



**Fig. 1.** Retrograde pyelography showing obstruction at the ureteropelvic junction of the lower pole moiety occurring immediately proximal to the portion where the lower and upper pole ureters join. The arrow in (A) indicates the dilated lower collecting system of the left kidney and that in (B) indicates the site of obstruction.



**Fig. 2.** Port placement of robot-assisted pyeloplasty.

277 minutes, with 17mL of blood loss. The postoperative course was uneventful and the patient was discharged on postoperative day 7. The DJS was removed at 6 weeks after the operation. Throughout the postoperative follow-up period, the patient has been UTI-free. MAG3 scintigraphy showed 47% split kidney function in the left kidney with preserved kidney function.

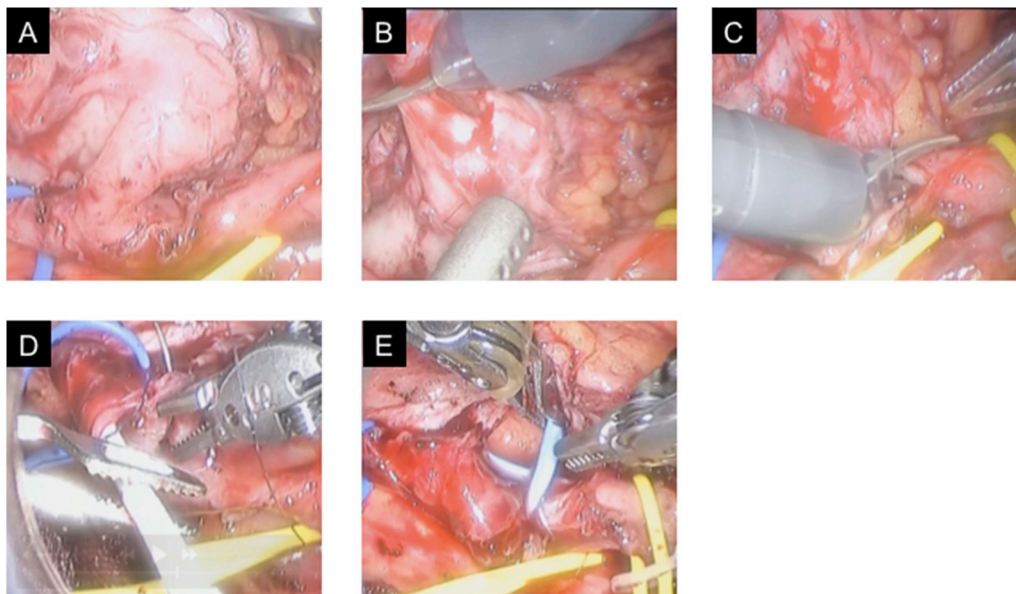
## Discussion

In dealing with this rare anomaly, we paid special attention to following two major points. First, dissection at the dilated pelvis should be minimal because it may damage the vascularity of the ureter at the junction. Second, anastomosis of the pelvis to the one single ureter could risk the development of stricture, which could injure both moieties.

First, to reduce both of these risks, careful radiological evaluation of

the obstructed duplex system is essential. CT urography is a standard evaluation for anatomical and diagnostic purpose. The kidney function in an affected kidney are often insufficient, and delayed urography with diuretics is recommended to visualize a narrow portion. Diuretic renal scintigraphy provides information on the renal function, degree of obstruction, and confirmation of reconstructive success after surgery. Cystoscopy and retrograde pyelography are recommended to exclude obstructions at other locations and to clarify the anatomy in duplex system.

The management should follow similar guidelines as for a single system UPJO to improve drainage with widely patent dependent anastomosis. The length of the ureter between the UPJ and junction of the lower and upper pole of the ureter are major determinant in an incomplete duplex system with obstruction. If enough ureteral length is available, a standard dismembered pyeloplasty should be considered.



**Fig. 3.** View of robot-assisted laparoscopic pyeloureterostomy in the patient. Narrow segment (arrow) in the ureteropelvic junction (UPJ) obstruction of the lower moiety is confirmed (A). The narrowed UPJ segment of the lower moiety is divided (B). The common ureter is spatulated beyond the UPJ (C). End-to-side pyeloureterostomy is performed using a 5-0 absorbable suture in a running fashion (D). Double J stent is inserted in the lower moiety (E).

For patients with a short ureteral length, pyeloureterostomy between the dilated and nondilated collecting systems is a feasible option in terms of good drainage of both portions of the upper collecting system. In the patient described here, we performed end-to-side pyeloureterostomy because of the short lower pole length of the ureter.

However, special attention is needed to preserve the vascularity of the upper moiety of the ureter and to avoid stenosis in the upper moiety system. This makes a laparoscopic intervention in duplex systems technically challenging and requires expertise for meticulous intracorporeal suturing although laparoscopic pyeloplasty for this complicated situation has been reported from some institute and reviewed. As mentioned above, several types of surgical intervention should be considered for reconstruction, depending on the severity and site of stenosis. In fact, the re-operative rate might be >6%, which is not low, as reported in conventional laparoscopic pyeloplasty.<sup>1</sup>

A robotic platform would allow for fine and careful dissection and suturing. Robot-assisted laparoscopic reconstruction for UPJO has been standard procedure because it makes long anastomoses easier than the conventional laparoscopic procedure. Although only three cases of robotic pyeloplasty for UPJO with a duplex system have been reported,<sup>2-4</sup> this only indicate its rarity and not its difficulty. Robotic assistance is useful in such complex disease because of its dexterity, better visualization, and faster and precise fine intracorporeal procedure. The present case showed the usefulness and feasibility of robotic assistance in managing such complex urogenital anomalies.

## Conclusions

UPJO with a duplex system is a rare entity and technically

challenging for reconstruction. Robot-assisted laparoscopic pyeloplasty in a duplex system is a safe and feasible option.

## Declaration of competing interest

No competing financial interest exist for Kazuyuki Numakura, Yumina Muto, Mitsuru Saito, Shintaro Narita, Takamitsu Inoue, or Tomonori Habuchi.

## Acknowledgments

This work was supported by Grants-in- Aid for Scientific Research, Japan (Grant No.: 17K11121).

## References

1. Rubenwolf P, Ziesel C, Beetz R, Kamal MM, Thuroff JW, Stein R. Presentation, management and long-term outcome of ureteropelvic junction obstruction in duplex kidneys. *J Urol*. 2015 Aug;194(2):427–432. PubMed PMID: 25640647. Epub 2015/02/03.
2. Nayyar R, Gupta NP, Hemal AK. Robotic management of complicated ureteropelvic junction obstruction. *World J Urol*. 2010 Oct;28(5):599–602. PubMed PMID: 19711084. Epub 2009/08/28.
3. Bora GS, Parmar K, Mavuduru RS. Robot-assisted pyeloplasty for pelvi-ureteric junction obstruction of lower moiety in partial duplex system: a technical challenge. *Indian J Urol*. 2016 Oct-Dec;32(4):314–316. PubMed PMID: 27843217. PubMed Central PMCID: PMC5054665. Epub 2016/11/16.
4. Baek M, Au J, Huang GO, Koh CJ. Robot-assisted laparoscopic pyeloureterostomy in infants with duplex systems and upper pole hydronephrosis: variations in double-J ureteral stenting techniques. *J Pediatr Urol*. 2017 Apr;13(2):219–220. PubMed PMID: 28153776. Epub 2017/02/06.