

Feasibility and safety of intrathecal treatment with nusinersen in adult patients with spinal muscular atrophy

Benjamin Stolte, Andreas Totzeck, Kathrin Kizina, Saskia Bolz, Lena Pietruck, Christoph Mönninghoff, Nika Guberina, Denise Oldenburg, Michael Forsting, Christoph Kleinschnitz and Tim Hagenacker

Abstract

Background: Nusinersen is an intrathecally administered antisense oligonucleotide (ASO) and the first approved drug for the treatment of spinal muscular atrophy (SMA). However, progressive neuromyopathic scoliosis and the presence of spondylodesis can impede lumbar punctures in SMA patients. Our aim was to assess the feasibility and safety of the treatment in adults with SMA.

Methods: For the intrathecal administration of nusinersen, we performed conventional, fluoroscopy-assisted and computer tomography (CT)-guided lumbar punctures in adult patients with type 2 and type 3 SMA. We documented any reported adverse events and performed blood tests.

Results: We treated a total of 28 adult SMA patients (9 patients with SMA type 2 and 19 patients with SMA type 3) aged between 18–61 years with nusinersen. The mean Revised Upper Limb Module (RULM) score at baseline in SMA type 2 and SMA type 3 patients was 9.9 ± 4.6 and 29.5 ± 8.5 , respectively. The mean Hammersmith Functional Motor Scale Expanded (HFMSE) score at baseline was 3.1 ± 2.5 and 31.2 ± 18.1 , respectively. Half of the SMA type 3 patients were ambulatory at treatment onset. In total, we performed 122 lumbar punctures with 120 successful intrathecal administrations of nusinersen. Lumbar punctures were well tolerated, and no serious adverse events occurred.

Conclusions: Our data demonstrate the feasibility and tolerability of intrathecal treatment with nusinersen in adults with SMA type 2 and type 3. However, treatment can be medically and logistically challenging, particularly in patients with SMA type 2 and in patients with spondylodesis.

Keywords: computer tomography, fluoroscopy, lumbar puncture, scoliosis, SMA, spondylodesis

Received: 12 July 2018; revised manuscript accepted: 5 September 2018.

Introduction

Spinal muscular atrophy (SMA) is an autosomal-recessive inherited neuromuscular disease leading to progressive muscle atrophy and weakness due to degeneration of anterior horn cells.¹ It has an incidence of 1:11,000 with a pan-ethnic carrier frequency of 1:54.^{2,3} The classification of disease is based on the achievement of motor milestones

with a broad range of phenotypes from very weak infants never achieving the ability to sit (SMA type 1, 'nonsitters'), to individuals able to sit, but never achieving the ability to walk (SMA type 2, 'sitters'), to ambulatory patients (SMA type 3, 'walkers').⁴ Remarkably, achieved motor milestones can be lost during the course of the disease. While most infants with SMA type 1 die in

Ther Adv Neurol Disord

2018, Vol. 11: 1–9

DOI: 10.1177/
1756286418803246

© The Author(s), 2018.
Article reuse guidelines:
sagepub.com/journals-
permissions

Correspondence to:

Tim Hagenacker
Department of Neurology,
University Hospital Essen,
Hufelandstr.55, Essen,
45147, Germany
Tim.hagenacker@uk-essen.de

Benjamin Stolte
Andreas Totzeck
Kathrin Kizina
Saskia Bolz
Lena Pietruck
Christoph Kleinschnitz
Department of Neurology,
University Hospital Essen,
Essen, Germany

Christoph Mönninghoff
Nika Guberina
Denise Oldenburg
Michael Forsting
Department of Diagnostic
and Interventional
Radiology and
Neuroradiology, University
Hospital Essen, Essen,
Germany

early childhood without nutritional and respiratory support, individuals with SMA type 2 often reach adulthood, and patients with SMA type 3 generally have a normal lifespan.^{5,6} Furthermore, patients with SMA type 2 can benefit from respiratory support such as airway clearance and non-invasive ventilation, whereas there is usually no need for respiratory support in individuals with SMA type 3.⁷ A further feature of SMA is a progressive neuromyopathic scoliosis affecting patients with SMA type 2 more than patients with type 3. Among other things, severe scoliosis can impair respiratory function due to restrictive lung disease, making a spinal bracing or fusion reasonable.^{8–10}

In most cases, SMA is caused by a homozygous deletion or mutation in the survival motor neuron 1 gene (SMN1) localised on chromosome 5q13.2, which results in insufficient levels of SMN protein.^{11,12} SMN2 is a centromeric copy of SMN1; both genes differ by only five basepairs.¹³ However, a single C-to-T transition in SMN2 results in a predominantly truncated nonfunctional SMN protein.^{14,15} The number of SMN2 gene copies varies between different individuals and correlates negatively with disease severity.^{12,16} Upregulating the level of functional SMN protein by modifying the function of SMN2 is a main target for therapeutic approaches.

Nusinersen is an antisense oligonucleotide (ASO) that is capable of modifying SMN2 and, thus, increasing SMN protein production and improving motor function. Because of the lacking ability of ASOs to cross the blood–brain barrier, nusinersen is administered by intrathecal injections.¹⁷ In clinical trials, intrathecal treatment with nusinersen has led to a significantly better motor development, motor function, and survival in infants and children with SMA type 1 or type 2 compared with placebo groups.^{18,19} Based on the results of these pivotal studies, nusinersen was approved by the United States Food and Drug Administration in December 2016 and by the European Medicines Agency (EMA) in May 2017.

However, there are a lack of data for treatment with nusinersen in adults with SMA thus far. Whereas the progressive scoliosis in SMA types 2 and 3 often impedes a conventional lumbar puncture, the safe administration of nusinersen in adult patients is challenging and even more complicated in the case of spondylodesis. Here,

we report our first experience of the feasibility and safety of the intrathecal treatment with nusinersen in adult patients with SMA type 2 and type 3.

Methods

In the Department of Neurology of the University Hospital Essen, Germany, treatment with nusinersen had been initiated shortly after the approval by the EMA in July 2017. It was offered to ambulatory and nonambulatory adult patients with SMA meeting the following inclusion criteria: a reported SMA type 2 or type 3, a documented mutation of SMN1 (i.e. 5q-SMA) as well as the copy number of SMN2, and a reported disease progression over the last 12 months under standard of care. The study was approved by the Ethics Committee of the University Duisburg-Essen, Germany (approval number: 18-8071-BO). Written informed consent was obtained from every patient before therapy started. Patients were not treated if they had one of the following conditions: a mutation other than 5q-SMA, a history of brain or spinal cord disease that would interfere with lumbar punctures, or impairments of the cerebrospinal fluid (CSF) circulation.

The dosage of nusinersen was 12 mg in 5 ml carrier solution per injection. In accordance with the recommended dosing schedule, the intrathecal administration of nusinersen was performed on treatment days 0, 14, 28, and 63 (loading dosing) followed by maintenance doses every 4 months.

In SMA type 3 patients with no or only mild scoliosis in physical examination, no relevant respiratory impairment, and no history of scoliosis surgery, a team of two neurologists performed conventional lumbar puncture. Otherwise, either fluoroscopy-assisted or computer tomography (CT)-guided lumbar punctures were performed. An example of severe scoliosis in a SMA type 2 patient from our cohort is illustrated in Figure 1. For all conventional lumbar punctures, we used a Sprotte needle (21 gauge). Patients were positioned sitting or lying on the side. After disinfection of the puncture site, lumbar puncture was performed between L3/4, L4/5, or L5/S1 under sterile conditions and without local anaesthesia. After removing 5 ml of CSF, the drug was administered intrathecally over 1–3 min. When the injection was completed, patients were positioned in the supine position for 2–3 h. The

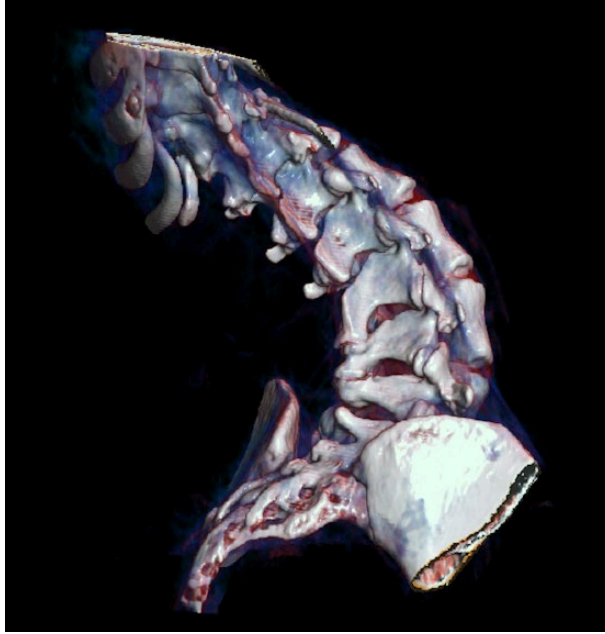


Figure 1. Three-dimensional computed tomography reconstruction in a volume rendering technique of a 44-year-old patient with SMA type 2 demonstrates the torsion of the scoliotic thoracolumbar spine, which complicates lumbar puncture for the intrathecal administration of nusinersen. SMA, spinal muscular atrophy.

fluoroscopy-assisted (AXIOM-Artis, Siemens Healthcare, Germany) and CT-guided (SOMATOM Definition Flash, Siemens Healthcare, Germany) lumbar punctures were performed by a neuroradiologist using a Quincke needle (20 or 21 gauge). Patients were positioned in a lateral or prone position. The injections were done by a neurologist analogously to the procedure previously described. An example of a CT-guided lumbar puncture in a patient with SMA type 2 and spondylolysis is illustrated in Figure 2(a) and (b).

The following patient data were collected before therapy started: age, sex, SMA type, genetic data including SMN2 gene copy number, age at symptom onset, age at genetic diagnosis, history of back surgery, and medication. In addition, we documented clinical findings at defined time points, such as walking ability, need for respiratory or nutritional support, spirometry, and grip strength as well as the functional scores the Revised Upper Limb Module (RULM) and the Hammersmith Functional Motor Scale Expanded (HFMSSE). To assess the safety of the treatment, we documented any reported adverse events due to the injection procedure and the treatment with

nusinersen, respectively. In addition, we performed blood tests and CSF analysis after each injection. Furthermore, the radiation dose per injection was documented for each patient undergoing a fluoroscopy-assisted or CT-guided lumbar puncture. For a CT-guided intervention, the effective dose was examined as a primary dosimetric parameter following ICRP103. By contrast, for a fluoroscopy-guided intervention, the dose area product (DAP) was assessed as a primary dosimetric parameter.

Results

From July 2017 to May 2018, we treated a total of 28 adult SMA patients with nusinersen. Among these 28 patients, 9 patients had SMA type 2 and 19 patients had SMA type 3. The mean age at first lumbar puncture in SMA type 2 patients was 31.2 years (range 24–48 years), whereas the SMA type 3 patients had a mean age at first lumbar puncture of 37.9 years (range 18–61 years). Approximately half of the SMA type 3 patients were able to walk when therapy started, whereas none of the SMA type 2 patients was ambulatory. The initial mean RULM score in SMA type 2 patients was 9.9 ± 4.6 , whereas the SMA type 3

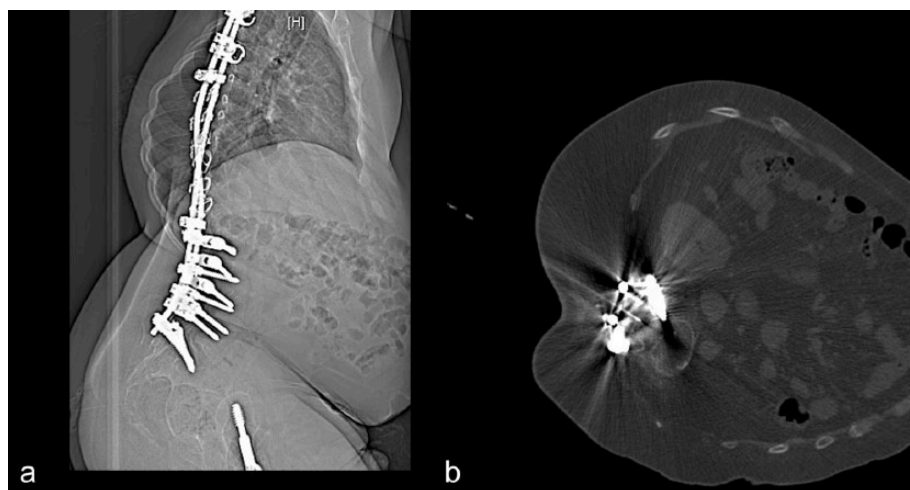


Figure 2(a). Lateral tomogram of a 29-year-old patient with SMA type 2 with implanted spondylodesis and femoral head replacement. The scoliosis, the spondylodesis, and the reduced visibility of the demineralised vertebral bodies complicate the lumbar puncture without computed tomographic guidance. SMA, spinal muscular atrophy.

Figure 2(b). Axial computed tomography scan of the same patient with intrathecal needle placement at the level of L 4/5. Despite the use of iterative metal artefact reduction, the contrast between the spinal canal and the spinous processes is challenging for intrathecal needle placement.

Table 1. Baseline data.

| | SMA type 2 | SMA type 3 | Total |
|--|----------------|-----------------|-----------------|
| Number of patients (%) | 9 | 19 | 28 |
| Male | 3 (33.3%) | 15 (78.9%) | 18 (64.3%) |
| Female | 6 (66.7%) | 4 (21.1%) | 10 (35.7%) |
| Ambulatory | 0 (0%) | 10 (52.6%) | 10 (35.7%) |
| Spondylodesis | 4 (44.4%) | 2 (10.5%) | 6 (21.4%) |
| Non-invasive ventilation | 3 (33.3%) | 1 (5.3%) | 4 (14.3%) |
| Age in years at first injection (mean \pm SD) | 31.2 \pm 8.2 | 37.9 \pm 12.7 | 35.8 \pm 11.8 |
| Age in years at first injection (range) | 24–48 | 18–61 | 18–61 |
| HFMSE score (mean \pm SD) | 3.1 \pm 2.5 | 31.2 \pm 18.1 | 22.1 \pm 19.9 |
| RULM score (mean \pm SD) | 9.9 \pm 4.6 | 29.5 \pm 8.5 | 23.2 \pm 11.8 |
| HFMSE, Hammersmith Functional Motor Scale Expanded; RULM, Revised Upper Limb Module; SD, standard deviation; SMA, spinal muscular atrophy. | | | |

patients had a mean RULM score of 29.5 ± 8.5 . The mean HFMSE scores were 3.1 ± 2.5 for type 2 patients and 31.2 ± 18.1 for type 3 patients. Overall, six patients had a spondylodesis. For more detailed baseline data, see Table 1.

In total, we performed 122 lumbar puncture procedures in 28 patients with 120 successful intrathecal administrations of nusinersen in 27 patients. A total of 26 patients completed at least the loading dosing, which means that they received four

Table 2. Lumbar punctures.

| | SMA type 2 | SMA type 3 | Total |
|---|--------------|--------------|--------------|
| Number of patients | 9 | 19 | 28 |
| Conventional | 0 | 14 | 14 |
| Fluoroscopy | 0 | 3* | 3* |
| CT | 9** | 2 | 11** |
| Number of procedures (%) | 33 | 89 | 122 |
| Conventional | 0 (0%) | 65 (73.0%) | 65 (53.3%) |
| Fluoroscopy | 0 (0%) | 14 (15.7%) | 14 (11.5%) |
| CT | 33 (100%) | 10 (11.2%) | 43 (35.2%) |
| Success rate*** | 97.0% | 98.9% | 98.4% |
| Conventional | – | 100% | 100% |
| Fluoroscopy | – | 92.9% | 92.9% |
| CT | 97.0% | 100% | 97.7% |
| Number of patients with 6 injections | 0 | 2 | 2 |
| Number of patients with 5 injections | 3 | 8 | 11 |
| Number of patients with 4 injections | 4 | 9 | 13 |
| Number of patients with 1 injection | 1 | 0 | 1 |
| Number of patients with 0 injections | 1** | 0 | 1** |
| *in one additional patient fluoroscopy-assisted puncture failed, so we switched to CT-guided punctures. | | | |
| **of these, in one patient CT-guided puncture failed. | | | |
| ***defined as successful injections per procedure. | | | |
| CT, computer tomography; SMA, spinal muscular atrophy. | | | |

or more injections of nusinersen. Overall, one patient with SMA type 2 did not receive the first dose administration of nusinersen because the CT-guided lumbar puncture failed. The other patient received the first dose before the observation period ended. We performed 65 conventional lumbar punctures in 14 patients, all of which were successful. CT-guided lumbar punctures were performed in 10 patients, of which 9 had SMA type 2; the other patient had SMA type 3 with a spondylodesis. However, in one additional case of a SMA type 3 patient with a spondylodesis, the fluoroscopy-assisted injection failed; therefore, the further injections were successfully performed *via* CT-guided punctures. In three SMA type 3 patients without spondylodesis, the fluoroscopy-assisted punctures succeeded each time, which corresponds to 13 injections of

nusinersen. CT-guided lumbar punctures were performed in all patients with SMA type 2 and in all patients with a spondylodesis. The total number of CT-guided lumbar punctures was 43, of which 42 were successful (Table 2).

In summary, with the exception of two cases, all injections were performed by the method originally intended. Finally, a well-tolerated injection of nusinersen succeeded in all but one patient, independent of age, type of SMA, and the presence of a spondylodesis. No patient stopped the treatment, and the lumbar punctures were well tolerated. A total of 22 patients (81.5%) reported at least one adverse event under treatment, including headache persisting up to several days and remitting spontaneously in all affected patients, back pain, nausea, constipation, and

Table 3. Adverse events.

| | No. of lumbar punctures (%) | No. of patients (%) |
|-----------------------------|-----------------------------|---------------------|
| Any adverse event | 47 (39.2%) | 22 (81.5%) |
| Headache | 32 (26.7%) | 17 (63.0%) |
| Back pain | 10 (8.3%) | 6 (22.2%) |
| Nausea | 7 (5.8%) | 4 (14.8%) |
| Constipation | 5 (4.2%) | 2 (7.4%) |
| Dizziness | 3 (2.5%) | 2 (7.4%) |
| Upper respiratory infection | 1 (0.8%) | 1 (3.7%) |
| No adverse event | 73 (60.8%) | 5 (18.5%) |

dizziness. In addition, a single patient with SMA type 3 had an upper respiratory infection after the fourth injection (Table 3). No serious adverse events occurred.

In one patient with a mild thrombocytopenia at therapy initiation, we observed a further slight decrease of platelet count from 103,000/ μ l to 66,000/ μ l between the first and third dose with a recovery to 87,000/ μ l before the fourth injection. In all the other cases, only physiological fluctuations of platelet count were observed. Similarly, we detected no relevant changes in serum creatinine, glomerular filtration rate, prothrombin time, and activated partial thromboplastin time (aPTT).

CT-guided intrathecal nusinersen administrations comprised an average patient dose of 2.6 mSv, and fluoroscopy-assisted intrathecal nusinersen administrations an average DAP of 261 cGycm².

Discussion

Our data provide evidence for the feasibility and safety of intrathecal treatment with nusinersen in adults with SMA type 2 and type 3. Although our patient cohort was heterogenous with regard to patient age, clinical baseline scores, type of SMA, walking ability, and the possible presence of a spondylodosis, this reflected 'real life' clinical experience. According to our experience, therapy *via* conventional lumbar puncture is feasible in many patients with SMA type 3 and with no existent spondylodosis. However, in some adults with

SMA type 3 and advanced scoliosis, fluoroscopy-assisted lumbar punctures can be useful. In SMA type 2 patients, conventional lumbar puncture is rarely feasible due to severe scoliosis, and it may increase the risk of adverse events. To an even lesser extent, a safe intrathecal administration *via* conventional lumbar puncture is possible in patients with spondylodosis, independent of the type of SMA. Thus, in patients with SMA type 2 and in patients with a spondylodosis, we recommend CT-guided lumbar puncture. However, in one case of a SMA type 2 patient, even CT-guided lumbar puncture failed. In addition to severe scoliosis, this patient had a history of surgically removed spondylodosis with ossification of the puncture site. In some adult SMA patients, recurring safe lumbar punctures, even with the assistance of imaging techniques, might be a problem, which leads to the question of alternative admission routes. Intracerebroventricular administration of nusinersen is a conceivable option, but to date there is no approval for this. In addition, data from nonhuman primates provide evidence for a better global distribution of nusinersen to the spinal cord when delivered intrathecally in comparison with intracerebroventricular administration.²⁰ Hence, use of intrathecal port catheter systems could be considered as an alternative administration route. Interestingly, a group demonstrated an off-label use of an Ommaya reservoir with an intrathoracic catheter connected to the thoracic spinal canal for intrathecal nusinersen delivery in a 20-year-old patient with SMA type 2.²¹ However, when using permanent catheters, the risk of occlusions or infections as well as that they are not approved remain unsolved

problems.²² Furthermore, there is a report of fluoroscopic-guided lateral cervical puncture as an alternative administration route for nusinersen in three teenage patients with spondylodesis precluding lumbar access.²³ Alternatively, surgical interventions such as hemilaminectomy or laminotomy could be considered to facilitate lumbar access.

Most of our patients received at least four injections of nusinersen. To date, the recurrent lumbar punctures have not led to any difficulties with respect to the puncture mode. Moreover, in particular, the CT-guided lumbar punctures became faster to perform over time, probably due to a learning effect. Nevertheless, therapy with nusinersen is a long-term therapy, so deterministic and stochastic risk (e.g. for colon cancer, lung cancer and leukemia) of recurrent radiation exposure should be taken into account.²⁴ In our cohort, CT-guided intrathecal nusinersen administrations comprised an average patient dose of 2.6 mSv, and fluoroscopy-assisted intrathecal nusinersen administrations an average DAP of 261 cGycm². For comparison, the dose of a routine CT examination of the abdomen is about 8–20 mSv, while the DAP for diagnostic cerebral angiography in patients with aneurysms is about 10,600 cGycm².²⁵ Image-guided therapy can be challenging in SMA patients and requires a high expertise as well as interdisciplinary cooperation between neurologists and neuroradiologists to successfully administer nusinersen and to minimise radiation exposure.

In our cohort, adverse events were headache, back pain, nausea, and dizziness, all of which are reported side effects of nusinersen but also common complications of lumbar punctures.^{26,27} In the CHERISH trial, the incidence of headache, vomiting, and back pain in children was higher in the nusinersen group than in the control group.¹⁹ Furthermore, we detected constipation in two patients and a single case of an upper respiratory infection in a patient with SMA type 3 after the fourth injection as a possible adverse drug reaction. In our cohort, no drug-induced thrombocytopenia or coagulation abnormalities were detected, which are part of the warnings associated with nusinersen treatment or other ASO therapies.²⁸

The most important point to consider is the current lack of data on the efficacy of nusinersen in

adult patients; thus, the proof of concept is still pending. In contrast, the efficacy in infants and children is already demonstrated by the ENDEAR and CHERISH trials.^{18,19} Although similar results may not be expected in adult patients, even small improvements of motor function may have a high impact on quality of life in affected patients. Equally, stopping the disease progression or delaying the necessity of non-invasive ventilation may be desirable therapy targets in adult patients. Future efficacy studies in adults still have to show whether the benefit of nusinersen justifies the high therapy costs. Furthermore, considering the invasiveness and the logistical effort of the treatment, any detailed patient information about possibilities and limitations of the therapy seems particularly important. Finally, there are several other therapeutic approaches currently in development, including SMN-dependent and SMN-independent strategies with miscellaneous administration routes, which will hopefully lead to a broader range of effective therapy options for the individual patient.²⁹

Conclusion

Our data demonstrate the feasibility and safety of intrathecal treatment with nusinersen in adults with SMA type 2 and type 3, independent of age, motor function including walking ability, as well as severity of scoliosis or the presence of a spondylodesis. However, therapy can be medically and logistically challenging, particularly in patients with SMA type 2 and in patients with spondylodesis. Hence, detailed patient information, consideration of individual patient's resources, and interdisciplinary cooperation between neurologists and neuroradiologists are required.

Funding

This research received no specific grant from any funding agency in the public, commercial, or not-for-profit sectors.

Conflict of interest statement

BS received travel reimbursement from Biogen. CK received travel reimbursement and speaker honoraria from Biogen. TH received travel reimbursement from Biogen and speaker honoraria from Novartis and Biogen. AT, KK, SB, LP, NG, CM and MF declared no conflicts of interest.

References

1. Mercuri E, Bertini E and Iannaccone ST. Childhood spinal muscular atrophy: controversies and challenges. *Lancet Neurol* 2012; 11: 443–452.
2. Sugarman EA, Nagan N, Zhu H, *et al.* Pan-ethnic carrier screening and prenatal diagnosis for spinal muscular atrophy: clinical laboratory analysis of >72,400 specimens. *Eur J Hum Genet* 2012; 20: 27–32.
3. Lunn MR and Wang CH. Spinal muscular atrophy. *Lancet* 2008; 371: 2120–2133.
4. Munsat TL and Davies KE. *International SMA consortium meeting.* (26–28 June 1992, Bonn, Germany). *Neuromuscul Disord* 1992; 2: 423–428.
5. Zerres K, Rudnik-Schöneborn S, Forrest E, *et al.* A collaborative study on the natural history of childhood and juvenile onset proximal spinal muscular atrophy (type II and III SMA): 569 patients. *J Neurol Sci* 1997; 146: 67–72.
6. Oskoui M, Levy G, Garland CJ, *et al.* The changing natural history of spinal muscular atrophy type 1. *Neurology* 2007; 69: 1931–1936.
7. Finkel RS, Mercuri E, Meyer OH, *et al.* Diagnosis and management of spinal muscular atrophy: part 2: pulmonary and acute care; medications, supplements and immunizations; other organ systems; and ethics. *Neuromuscul Disord* 2018; 28: 197–207.
8. Catteruccia M, Vuillerot C, Vaugier I, *et al.* Orthopedic management of scoliosis by Garches Brace and Spinal fusion in SMA type 2 children. *J Neuromuscul Dis* 2015; 2: 453–462.
9. Chua K, Tan CY, Chen Z, *et al.* Long-term follow-up of pulmonary function and scoliosis in patients with Duchenne’s muscular dystrophy and spinal muscular atrophy. *J Pediatr Orthop* 2016; 36: 63–69.
10. Mercuri E, Finkel RS, Muntoni F, *et al.* Diagnosis and management of spinal muscular atrophy: part 1: recommendations for diagnosis, rehabilitation, orthopedic and nutritional care. *Neuromuscul Disord* 2018; 28: 103–115.
11. Lefebvre S, Bürglen L, Reboullet S, *et al.* Identification and characterization of a spinal muscular atrophy-determining gene. *Cell* 1995; 80: 155–165.
12. Lefebvre S, Burlet P, Liu Q, *et al.* Correlation between severity and SMN protein level in spinal muscular atrophy. *Nat Genet* 1997; 16: 265–269.
13. Bürglen L, Lefebvre S, Clermont O, *et al.* Structure and organization of the human survival motor neurone (SMN) gene. *Genomics* 1996; 32: 479–482.
14. Lorson CL and Androphy EJ. An exonic enhancer is required for inclusion of an essential exon in the SMA-determining gene SMN. *Hum Mol Genet* 2000; 9: 259–265.
15. Lorson CL, Hahnen E, Androphy EJ, *et al.* A single nucleotide in the SMN gene regulates splicing and is responsible for spinal muscular atrophy. *Proc Natl Acad Sci U S A* 1999; 96: 6307–6311.
16. Feldkötter M, Schwarzer V, Wirth R, *et al.* Quantitative analyses of SMN1 and SMN2 based on real-time lightCycler PCR: fast and highly reliable carrier testing and prediction of severity of spinal muscular atrophy. *Am J Hum Genet* 2002; 70: 358–368.
17. Geary RS, Yu RZ and Levin AA. Pharmacokinetics of phosphorothioate antisense oligodeoxynucleotides. *Curr Opin Investig Drugs* 2001; 2: 562–573.
18. Finkel RS, Mercuri E, Darras BT, *et al.* Nusinersen versus sham control in infantile-onset spinal muscular atrophy. *N Engl J Med* 2017; 377: 1723–1732.
19. Mercuri E, Darras BT, Chiriboga CA, *et al.* Nusinersen versus sham control in later-onset spinal muscular atrophy. *N Engl J Med* 2018; 378: 625–635.
20. Passini MA, Bu J, Richards AM, *et al.* Antisense oligonucleotides delivered to the mouse CNS ameliorate symptoms of severe spinal muscular atrophy. *Sci Transl Med* 2011; 3: 72ra18.
21. Lakhotia A, Bhalla S, Doll E, *et al.* Use of Ommaya reservoir with a thoracic spinal catheter for intrathecal delivery of nusinersen in a patient with spinal muscular atrophy type 2 (P4.464). *Neurology* 2018; 90(Suppl. 15).
22. Cohen-Pfeffer JL, Gururangan S, Lester T, *et al.* Intracerebroventricular delivery as a safe, long-term route of drug administration. *Pediatr Neurol* 2017; 67: 23–35.
23. Veerapandiyan A, Pal R, D’Ambrosio S, *et al.* Cervical puncture to deliver nusinersen in patients with spinal muscular atrophy. *Neurology* 2018; 91: e620–e624.
24. Berrington de González A, Mahesh M, Kim KP, *et al.* Projected cancer risks from computed tomographic scans performed in the United States in 2007. *Arch Intern Med* 2009; 169: 2071–2077.

25. Ihn YK, Kim BS, Byun JS, *et al.* Patient radiation exposure during diagnostic and therapeutic procedures for intracranial aneurysms: a multicenter study. *Neurointervention* 2016; 11: 78–85.
26. Vilming ST and Kloster R. Pain location and associated symptoms in post-lumbar puncture headache. *Cephalalgia* 1998; 18: 697–703.
27. Engelborghs S, Niemantsverdriet E, Struyfs H, *et al.* Consensus guidelines for lumbar puncture in patients with neurological diseases. *Alzheimers Dement (Amst)* 2017; 8: 111–126.
28. Choy M. Pharmaceutical approval update. *P T* 2017; 42: 165–166.
29. Shorrock HK, Gillingwater TH and Groen EJN. Overview of current drugs and molecules in development for spinal muscular atrophy therapy. *Drugs* 2018; 78: 293–305.

Visit SAGE journals online
[journals.sagepub.com/
home/tan](http://journals.sagepub.com/home/tan)

 SAGE journals