



Case report

Favorable outcome with early initiation of VV-ECMO for unilateral lung disease in children

Hammad A. Ganatra^{a,b,*}, Daniah Shamim^c, Angela Farnan^d, Girish Deshpande^{d,e}^a Division of Pediatric Critical Care Medicine, Kansas University Medical Center, Kansas City, KS, United States^b Department of Pediatrics, University of Kansas School of Medicine, Kansas City, KS, United States^c Department of Neurology, University of Kansas School of Medicine, Kansas City, KS, United States^d Children's Hospital of Illinois, OSF St Francis Medical Center, Peoria, IL, United States^e Division of Pediatric Critical Care Medicine, University of Illinois College of Medicine, Peoria, IL, United States

ARTICLE INFO

Keywords:

Unilateral lung disease

Pediatric

ECMO

Extracorporeal membrane oxygenation

Ventilator induced lung injury

Lung protection

ABSTRACT

Unilateral lung diseases such as unilateral pneumonia, trauma or pulmonary hemorrhage can cause profound hypoxemic respiratory failure necessitating mechanical ventilation. These disorders are characterized by marked asymmetry in lung mechanics, with the affected lung having a lower compliance compared to the healthier lung, and management involves complex strategies such as simultaneous independent lung ventilation. However, such strategies can be challenging in pediatric populations due to technical limitations, and also lead to ventilator induced lung injury. We report two unique cases that support the use of venovenous extracorporeal membrane oxygenation as an alternative strategy for management of unilateral lung disease in children.

1. Introduction

According to published reports, 20–30% of children admitted to pediatric intensive care units (PICU) receive invasive mechanical ventilation [1,2]. Most critically ill children with acute respiratory failure involve pathologies in both lungs, but management of unilateral lung disorders such as unilateral pneumonia, trauma or pulmonary hemorrhage, requires more complex strategies. Unilateral lung diseases causing profound hypoxemia are characterized by marked asymmetry in lung mechanics, with the affected lung having a lower compliance compared to the healthier lung.

Venovenous extracorporeal membrane oxygenation (VV-ECMO) is often utilized in the setting of severe, refractory respiratory failure with normal cardiac function, when mechanical ventilation fails. VV-ECMO provides adequate oxygenation for the patient, thereby allowing lower inspiratory pressures and tidal volumes on the ventilator, and potentially preventing ventilator associated lung injury. We searched the Extracorporeal Life Support Organization (ELSO) registry for records of children with unilateral lung disease that received ECMO support, but the registry only identifies patients with respiratory failure and does not differentiate between unilateral lung disease and bilateral lung disease [3]. We identified two cases at our center that developed unilateral lung disease and VV-ECMO was utilized during management, both with

favorable outcomes. Our working hypothesis for this report is that early implementation of VV-ECMO in acute hypoxic respiratory failure from unilateral lung disease offers a pragmatic option minimizing ventilator associated lung injury. In this manuscript, we describe these pediatric cases in further detail, and discuss the benefits of early initiation of ECMO support for unilateral lung disease.

2. Case 1

A previously healthy 4-year-old male was admitted to the pediatric floor with diagnosis of left lower lobe pneumonia with symptoms of dyspnea, cough and mild fever. Due to rapid deterioration in his clinical condition with acute desaturations, he was transferred to the PICU, intubated and placed on positive pressure ventilation for acute hypoxemic respiratory failure. His pre-intubation venous blood gas was: pH 7.1, pCO₂ 90, pO₂ 47, base deficit –6. Chest x-ray revealed complete atelectasis of the left lung and hyperinflation of the right lung, with small pneumomediastinum (Fig. 1A). He was extremely difficult to ventilate and oxygenate, requiring peak inspiratory pressures greater than 40 cm H₂O. We attempted manual positive pressure ventilation at different rates (12–30 breaths per minute), different levels of positive end expiratory pressures (PEEP) ranging from 5 to 15 cm H₂O, and different inspiration times without any improvement in oxygen

* Corresponding author. Pediatric Critical Care Medicine, Kansas University Medical Center, 3901 Rainbow Blvd, Miller 2023, Kansas City, KS, 66160, United States.

E-mail address: hganatra@kumc.edu (H.A. Ganatra).

<https://doi.org/10.1016/j.rmcr.2018.11.019>

Received 17 October 2018; Received in revised form 26 November 2018; Accepted 26 November 2018

2213-0071/ © 2018 The Authors. Published by Elsevier Ltd. This is an open access article under the CC BY-NC-ND license (<http://creativecommons.org/licenses/by-nc-nd/4.0/>).

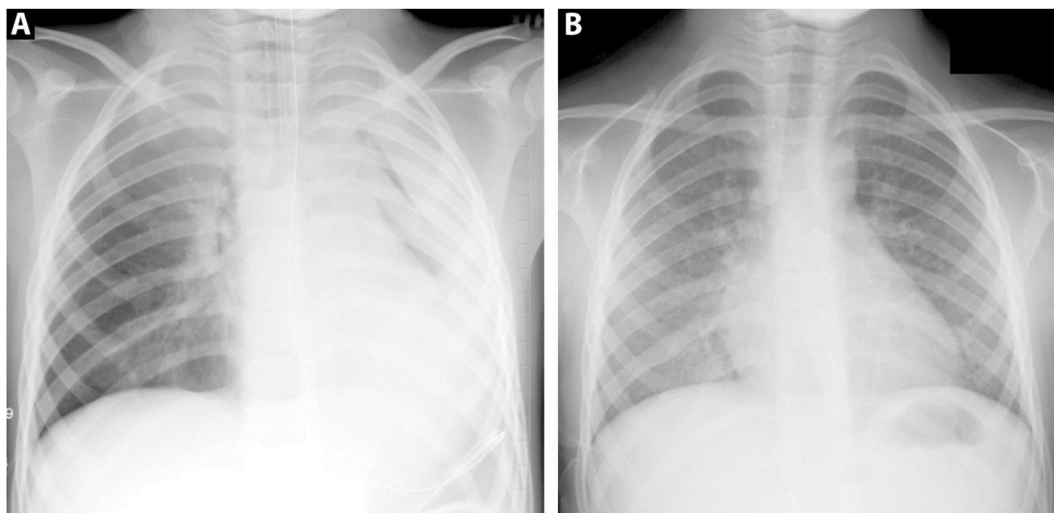


Fig. 1. A) Chest x-ray at presentation, and B) Chest x-ray prior to home discharge for Case 1.

saturation, which remained mid-70s.

We suspected the presence of a foreign body and performed an emergent rigid bronchoscopy. The left mainstem bronchus was found to be completely obstructed by a thick mucus plug which could only be partially removed, without much improvement in oxygenation. Despite high mechanical ventilatory support with inspired oxygen at 100%, PEEP of 8, rate of 24 bpm, and exhaled tidal volume of 250 ml (8 ml/kg), the patient's oxyhemoglobin saturations remained near 80%. His arterial blood gas (ABG) at this time showed: pH 7.39, $p_a\text{CO}_2$ 39, $p_a\text{O}_2$ 40, measured O_2 saturation 81%, base deficit -1 . This worsening clinical course prompted the decision to initiate VV-ECMO within 6 hours of admission to PICU and an 18-French dual lumen cannula was placed percutaneously in the right internal jugular vein with an additional 15-French cannula in the left femoral vein to augment ECMO flows. Arterial oxygen saturations were maintained between 90 and 93%. Ventilator settings were adjusted to minimize ventilator induced lung injury and optimize healing. These adjustments included tidal volume at 6-ml/kg, low rate of 15 bpm, and a PEEP of 8 cm H_2O to maintain alveolar recruitment.

Fiberoptic bronchoscopy was performed shortly after VV-ECMO initiation, and diagnosis of plastic bronchitis was established based on the presence of extensive bronchial mucus casts (Fig. 2). Pathological examination of mucus plugs revealed inflammatory debris with proteinaceous inspissated material. Work up for cystic fibrosis and infectious diseases were negative. Patient had elevated Mycoplasma IgG, however IgM was negative.

Patient remained on VV-ECMO for 6 days, while undergoing 7 therapeutic bronchoscopies for cast removal. He was extubated 4 days after decannulation from ECMO support and discharged home on day 18, without any supplemental oxygen requirement. Chest x-ray prior to discharge showed complete resolution of the left sided lung opacification noted on earlier imaging (Fig. 1B).

3. Case 2

A previously healthy 6-year-old male was admitted to an outlying hospital with diagnosis of ruptured appendix. Exploratory laparotomy and appendectomy were performed by pediatric surgical team, without any immediate complications. On postoperative day 3, he developed respiratory distress and hypoxia. Chest X-ray revealed alveolar opacities in the right upper and left lower lobes. At this point he was transferred to the general pediatric floor at our facility. Examination on arrival revealed respiratory distress, with oxygen saturations of 97% on 2L/minute of supplemental oxygen through a nasal cannula. Nasogastric

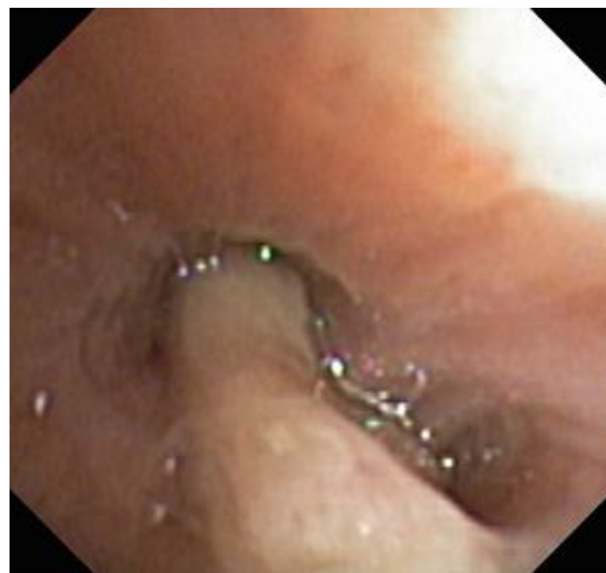

Fig. 2. Bronchial mucus cast observed on flexible bronchoscopy in Case 1.

tube placement was attempted to relieve abdominal distension, but he experienced bilious emesis during the process, followed by acute worsening of hypoxia. His oxyhemoglobin saturations remained in mid-80s despite administration of 100% oxygen via non-rebreather mask.

Due to persistent hypoxia presumed secondary to bilious aspiration, he was intubated and initiated on conventional ventilator support which was then quickly switched over to high frequency oscillatory ventilation (HFOV) due to persistent hypoxia. He was provided FiO_2 of 1.0 and 20 parts per million of inhaled nitric oxide, and oxygen saturations transiently improved to 90%. Chest x-ray following intubation showed significant right sided parenchymal lung disease, with relative sparing of the left side (Fig. 3A).

Over the next 3 hours his oxygen saturations steadily declined, prompting the decision to initiate VV-ECMO support. His pre-ECMO ABG was: pH 7.42, $p_a\text{CO}_2$ 41, $p_a\text{O}_2$ 41, measured O_2 saturation 78%. Patient was cannulated through an 18-French dual lumen cannula in the right internal jugular vein, with an additional 14-French venous cannula in the left femoral vein to augment ECMO flows. There was immediate improvement in $p_a\text{O}_2$ to 70, and measured O_2 saturation to 96%. Arterial oxyhemoglobin saturations were maintained between 90 and 95%. HFOV was replaced by a conventional ventilator and settings

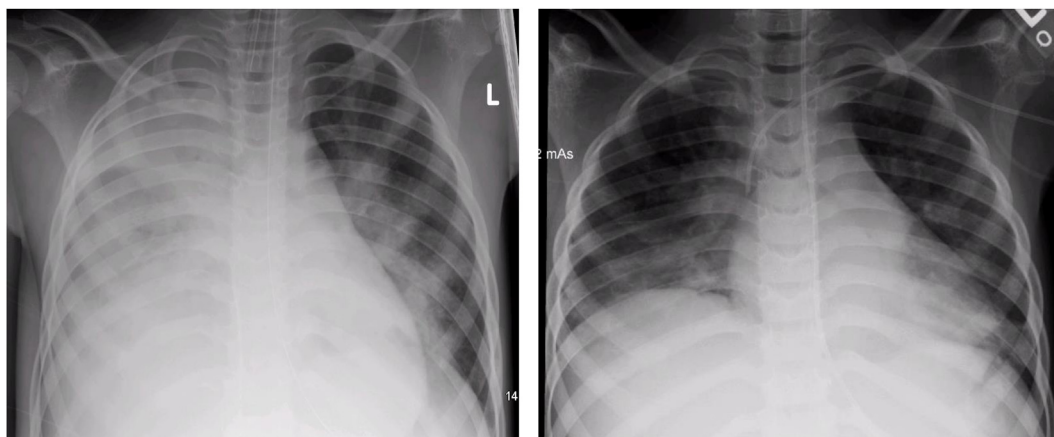


Fig. 3. A) Chest x-ray at presentation, and B) Chest x-ray prior to home discharge for Case 2.

were adjusted to allow lung rest, with low tidal volumes, low rate, and a PEEP of 10 cm H₂O to prevent atelectrauma.

Patient was maintained on VV-ECMO for 5 days and underwent an intra-abdominal abscess drainage on 2nd day of ECMO run. He was extubated 7 days after decannulation from ECMO, and discharged home after a 15-day inpatient stay. Chest x-ray prior to discharge showed complete resolution of his unilateral lung disease (Fig. 3B).

4. Discussion

Mechanical ventilation in children with unilateral lung disease offers significant challenges for the pediatric intensivist, primarily due to the differential lung compliance of the two lungs. In most conditions such as unilateral pneumonia, trauma, contusion or hemorrhage, the affected lung suffers from low compliance and a shorter time constant. In rare instances, such as cases with bronchopleural fistula, the affected lung will have an increased compliance and longer time constant. Conventional ventilator strategies apply equal pressure and flow to both lungs through single lumen endotracheal tube, and the distribution of gas is determined by the airway resistance and the compliance of the different lung lobes. In the case of low compliance unilateral lung disease, there is preferential delivery of tidal volume to the healthier, more compliant lung, subjecting it to barotrauma, volutrauma, and overdistension. The overdistension also diverts blood flow away from the healthier lung, resulting in worsening ventilation-perfusion mismatch and hypoxia [4]. Meanwhile, the affected lung being relatively stiffer, remains underinflated and prone to atelectrauma, causing profound hypoxemia from venous shunting and diffusion impairment. Similarly, in unilateral lung disease with increased compliance, tidal volumes are favorably redistributed to the affected lung, whereas the healthy lung is hypoventilated. Again, this leads to worsening hypoxia resulting from ventilation-perfusion mismatch.

Therefore, traditional ventilator management fails to produce adequate oxygenation and ventilation, and potentially leads to further lung injury when utilized for unilateral lung diseases. There is no consensus regarding the appropriate levels of PEEP and tidal volume in patients with unilateral lung injury. Whether PEEP worsens or improves gas exchange in these patients depends on the relative magnitude of regional lung mechanics [5]. Also, we did not attempt prone positioning in our patients as both situations involved rapid clinical deterioration necessitating urgent transition to VV-ECMO. However, even with favorable clinic scenarios, routine use of prone positioning in pediatric ARDS is not recommended by the Pediatric Acute Lung Injury Consensus Conference [6]. The only RCT that studied prone positioning in pediatric ARDS showed improved oxygenation, but no improvement in mortality or ventilator-free days, and was halted at interim analysis due to futility [7].

Simultaneous independent lung ventilation (SILV) can be utilized to ventilate each lung independently of the other, with inspiratory pressures and tidal volumes targeted to each lung's needs. SILV is generally accomplished through a dual-lumen endotracheal tube, with one lumen being the longer “bronchial” tube and the other shorter “tracheal” tube [8]. Each lumen is connected to a separate ventilator, allowing different modes of ventilation and different PEEP levels for each lung. Existing data suggests that SILV is beneficial in the treatment of unilateral lung disease among adults [5,8], however, its application in infants and children can be challenging because of the lack of appropriate sized dual-lumen endotracheal tubes. The smallest size of double-lumen tubes currently available are 26 and 28 Fr, which may be suitable for children 8–12 years of age, but inappropriately large for younger children [9,10]. Dual lumen endotracheal tubes also pose technical difficulties during insertion, and may lead to tracheobronchial injuries [9,11]. This problem is compounded when one considers that even in the best circumstances, pediatric airways are more challenging to intubate due to anatomical properties such as larger occiput and tongue, redundant soft tissue, and the relatively anterior location of the laryngeal inlet [12]. Additionally, SILV requires muscle relaxation and clinical competency with managing two independent ventilators, and smaller lumens of the endotracheal tubes pose difficulties in passing suction catheters to clear airway secretions [5,8]. Therefore, early initiation of VV-ECMO offers an opportunity to manage pediatric unilateral lung disease when SILV is not an option due to technical and equipment limitations.

Our first patient with unilateral plastic bronchitis experienced left lung collapse secondary to left mainstem bronchial obstruction, and resultant hyperinflation of the right lung. Due to the starkly asymmetrical lung mechanics, conventional ventilation produced ineffective oxygenation and ventilation, and could have had potentially damaging effect from the inflating pressures on the relatively unaffected right lung. Early initiation of VV-ECMO in this patient proved to be life-saving as well as ‘lung-sparing’. It allowed for adequate gas exchange while minimizing lung injury and allowed us to perform repeat bronchoscopies for removal of the bronchial casts. The severity of his respiratory failure would have made bronchoscopy intervention impossible without ECMO support. Similar situations have been reported in the literature where conditions such as foreign body aspiration, plastic bronchitis, and sand aspiration were rescued with ECMO support to permit safe bronchoscopic procedures [13–15]. Similarly, Kamat et al. published a series of 153 bronchoscopies performed safely on 79 children on ECMO support [16].

Our second case involved a child with right sided bilious aspiration leading to unilateral ARDS causing profound hypoxemia. There are case reports of adults developing ARDS secondary to bilious aspiration, often with fatal outcomes [17,18]. Bile acids cause decreased lung compliance and direct lung injury by producing chemical pneumonitis, and

Table 1
Patient demographics and VV-ECMO parameters.

	Case 1	Case 2
Age	4 years	6 years
Sex	Male	Male
Weight (kg)	18 kg	22 kg
Height (cm)	108 cm	118 cm
Oxygenation index prior to ECMO initiation	40	40
Oxygenation index following decannulation from ECMO	8	11
Mean Airway Pressure prior to ECMO initiation (cm H ₂ O)	16	16
Mean Airway Pressure following decannulation from ECMO (cm H ₂ O)	14	19
Total ECMO duration (hours)	148 hours	98 hours
Packed RBC transfusions during ECMO course	90mls + Circuit Prime 275mls volume	0 + Circuit Prime 275 mls volume
Platelet transfusions during ECMO course	None	None
Plasma transfusions during ECMO course	None	None
Cryoprecipitate transfusions during ECMO course	None	None
Respiratory complications during or after ECMO course	None	None
Hematological complications during or after ECMO course	None	None
Cardiac complications during or after ECMO course	None	None
Neurologic complications during or after ECMO course	None	None
Renal complications during or after ECMO course	None	None
PICU length of stay (days)	13 days	12 days
Hospital length of stay (days)	18 days	15 days

by enhancement of secretory phospholipase A2 resulting in surfactant inactivation, thus causing ARDS in animals [19]. Our patient had unilateral lung disease from bilious aspiration, and the use of oscillatory ventilation and high mean airway pressure would have led to hyperinflation and potential lung injury to the relatively healthy left lung. Similar to the first case, ECMO support allowed us to adequately oxygenate and ventilate the patient, while resting the diseased lung and protecting the healthy lung from ventilator associated lung injury.

Table 1 shows the patient characteristics and VV-ECMO parameters. Both patients were initially cannulated with a double lumen cannula in the internal jugular vein per our VV-ECMO protocol and the surgeon's preference. Dual lumen cannulae provide laminar bi-directional flow, with simultaneous drainage of deoxygenated blood from the superior and inferior vena cava (SVC and IVC) through one lumen, while the second lumen returns oxygenated blood back to the right atrium through a dedicated outlet. Blood flow through the VV-ECMO circuit for pediatric patients is measured in milliliters/kilogram/minute (ml/kg/min) and is adjusted based on the patient's oxygen needs. Even with the maximum flow achievable through the dual lumen cannula, we were unable to maintain adequate oxygenation, therefore another venous cannula was placed in the femoral vein. This allowed for increased drainage of deoxygenated blood from the IVC, that was then oxygenated and returned to the right atrium via the dedicated return lumen on the dual lumen internal jugular cannula.

Although life-saving, ECMO support can be associated with significant mortality and morbidity. Major complications include hemorrhagic or thrombotic events, leading to ischemic or hemorrhagic strokes, pulmonary hemorrhage, gastrointestinal bleeding, or circuit thrombosis leading to circuit failure [20]. Other commonly encountered problems include infections, malposition of ECMO cannulae, fluid overload, and equipment failure [20].

We still believe that SILV can be a life-saving in children with unilateral lung disease, although it would necessitate increased sedatives and paralytic agents, and would require stringent monitoring of lung mechanics [8]. Indeed, a recent case report highlighted the use of SILV as a means of weaning a patient with unilateral lung disease off ECMO support [10]. However, there will always be a subset of pediatric patients that are unamenable to SILV due to technical and size limitations, and early deployment of VV-ECMO support offers a prudent alternative with favorable outcomes as shown by our report.

Conflicts of interest

The authors have no conflicts of interest relevant to this article to disclose.

Funding sources and financial disclosure

No funding was secured for this study, and the authors have no financial relationships relevant to this article to disclose.

References

- [1] B.D. Benneyworth, W.E. Bennett, A.E. Carroll, Cross-sectional comparison of critically ill pediatric patients across hospitals with various levels of pediatric care, *BMC Res. Notes* 8 (2015) 693.
- [2] R.G. Khemani, B.P. Markovitz, M.A. Curley, Characteristics of children intubated and mechanically ventilated in 16 PICUs, *Chest* 136 (3) (2009) 765–771.
- [3] Extracorporeal Life Support Organization (ELSO) Registry. <https://www.elseo.org/Registry.aspx>. (Accessed 16 October 2018).
- [4] L. Blanch, C. Roussos, S. Brotherton, R.P. Michel, M.R. Angle, Effect of tidal volume and PEEP in ethchlorvynol-induced asymmetric lung injury, *J. Appl. Physiol.* 73 (1) (1985) 108–116 1992.
- [5] L. Blanch, J.L. Aguilar, A. Villagra, Unilateral lung injury, *Curr. Opin. Crit. Care* 9 (1) (2003) 33–38.
- [6] R.F. Tamburro, M.C. Kneyber, Pediatric acute lung injury consensus conference G. Pulmonary specific ancillary treatment for pediatric acute respiratory distress syndrome: proceedings from the pediatric acute lung injury consensus conference, *Pediatr. Crit. Care Med. J. Soc. Crit. Care Med. World Fed. Pediatr. Intensive Crit. Care Soc.* 16 (5 Suppl 1) (2015) S61–S72.
- [7] M.A. Curley, P.L. Hibberd, L.D. Fineman, et al., Effect of prone positioning on clinical outcomes in children with acute lung injury: a randomized controlled trial, *Jama* 294 (2) (2005) 229–237.
- [8] A.R. Thomas, T.L. Bryce, Ventilation in the patient with unilateral lung disease, *Crit. Care Clin.* 14 (4) (1998) 743–773.
- [9] A. Purohit, S. Bhargava, V. Mangal, V.K. Parashar, Lung isolation, one-lung ventilation and hypoxaemia during lung isolation, *Indian J. Anaesth.* 59 (9) (2015) 606–617.
- [10] M.E. Lovett, T.J. Karsies, An 11-year-old girl with life-threatening pneumonia. Independent lung ventilation as a means to facilitate extracorporeal membrane oxygenation decannulation, *Ann. Am. Thorac. Soc.* 13 (10) (2016) 1789–1793.
- [11] D. Anantham, R. Jagadesan, P.E. Tiew, Clinical review: independent lung ventilation in critical care, *Crit. Care* 9 (6) (2005) 594–600.
- [12] R.A. Sunder, D.T. Haile, P.T. Farrell, A. Sharma, Pediatric airway management: current practices and future directions, *Paediatr. Anaesth.* 22 (10) (2012) 1008–1015.
- [13] K.A. Baqais, M. Mahoney, K. Tobler, A. Hui, M. Noseworthy, Pediatric sand aspiration managed using bronchoscopy and extracorporeal membrane oxygenation, *Can. Respir. J.* 22 (5) (2015) 261–262.
- [14] T. Jasinovic, F.K. Kozak, J.P. Moxham, et al., Casting a look at pediatric plastic bronchitis, *Int. J. Pediatr. Otorhinolaryngol.* 79 (10) (2015) 1658–1661.
- [15] A.H. Park, D.E. Tunkel, E. Park, et al., Management of complicated airway foreign body aspiration using extracorporeal membrane oxygenation (ECMO), *Int. J.*

- Pediatr. Otorhinolaryngol. 78 (12) (2014) 2319–2321.
- [16] P.P. Kamat, J. Popler, J. Davis, et al., Use of flexible bronchoscopy in pediatric patients receiving extracorporeal membrane oxygenation (ECMO) support, *Pediatr. Pulmonol.* 46 (11) (2011) 1108–1113.
- [17] T. Kaneko, M. Tamaru, T. Sato, Anesthesia for the patient in postoperative period of esophageal cancer: the risk of aspiration of gastric contents, *J. Clin. Anesth.* 5 (1981) 73–77.
- [18] D.T. Porembka, A. Kier, S. Sehlhorst, S. Boyce, J.P. Orlowski, K. Davis Jr., The pathophysiologic changes following bile aspiration in a porcine lung model, *Chest* 104 (3) (1993) 919–924.
- [19] D. De Luca, A. Minucci, E. Zecca, et al., Bile acids cause secretory phospholipase A2 activity enhancement, revertible by exogenous surfactant administration, *Intensive Care Med.* 35 (2) (2009) 321–326.
- [20] S. Vaquer, C. de Haro, P. Peruga, J.C. Oliva, A. Artigas, Systematic review and meta-analysis of complications and mortality of veno-venous extracorporeal membrane oxygenation for refractory acute respiratory distress syndrome, *Ann. Intensive Care* 7 (1) (2017) 51.