




S. Ferrucci,<sup>1</sup> M. Romagnuolo,<sup>1,2</sup> L. Angileri,<sup>1,2</sup>  E. Berti,<sup>1,2</sup>   
S. Tavecchio<sup>1,2,\*</sup> 

<sup>1</sup>Dermatology Unit, Fondazione IRCCS Ca' Granda Ospedale Maggiore Policlinico, Milan, Italy, <sup>2</sup>Department of Physiopathology and Transplantation, Università degli Studi di Milano, Milan, Italy

\*Correspondence: S. Tavecchio. E-mail: simona.tavecchio@gmail.com

## References

- 1 Harb H, Chatila T. Mechanisms of dupilumab. *Clin Exp Allergy* 2020; **50**: 5–14.
- 2 Wollenberg A, Barbarot S, Bieber T *et al.* Consensus-based European guidelines for treatment of atopic eczema (atopic dermatitis) in adults and children: part II. *J Eur Acad Dermatol Venereol* 2018; **32**: 850–878.
- 3 Blauvelt A, deBruin-Weller M, Gooderham M *et al.* Long-term management of moderate-to-severe atopic dermatitis with dupilumab and concomitant topical corticosteroids (LIBERTY AD CHRONOS): a 1-year, randomised, double-blinded, placebo-controlled, phase 3 trial. *Lancet* 2017; **389**: 2287–2303.
- 4 Bruin-Weller M, Thaçi D, Smith CH *et al.* Dupilumab with concomitant topical corticosteroids in adult patients with atopic dermatitis who are not adequately controlled with or are intolerant to ciclosporin A, or when this treatment is medically inadvisable: a placebo-controlled, randomized phase. *Br J Dermatol* 2018; **178**: 1083–1101.
- 5 Tauber M, Apoil PA, Richet C *et al.* Effect of dupilumab on atopic manifestations in patients treated for atopic dermatitis in real-life practice. *Br J Dermatol* 2019; **180**: 1551–1552.
- 6 Olesen CM, Holm JG, Nørreslet LB *et al.* Treatment of atopic dermatitis with dupilumab: experience from a tertiary referral center. *J Eur Acad Dermatol Venereol* 2019; **33**: 1562–1568.
- 7 Ferrucci S, Casazza G, Angileri L *et al.* Clinical response and quality of life in patients with severe atopic dermatitis treated with dupilumab: a single-center real-life experience. *J Clin Med* 2020; **9**: 791.
- 8 Akinlade B, Guttman-Yassky E, de Bruin-Weller M *et al.* Conjunctivitis in dupilumab clinical trials. *Br J Dermatol* 2019; **181**: 459–473.
- 9 Deleuran M, Thaçi D, Beck LA *et al.* Dupilumab shows long-term safety and efficacy in patients with moderate to severe atopic dermatitis enrolled in a phase 3 open-label extension study. *J Am Acad Dermatol* 2020; **82**: 377–388.
- 10 Wollenberg A, Flohr C, Simon D *et al.* European Task Force on Atopic Dermatitis (ETFAD) statement on severe acute respiratory syndrome coronavirus 2 (SARS-Cov-2)-infection and atopic dermatitis. *Eur Acad Dermatol Venereol* 2020. <https://doi.org/10.1111/jdv.16411>. [Epub ahead of print].

DOI: 10.1111/jdv.16527

## SARS-CoV-2 infection presenting as a febrile rash

Dear Editor,

The World Health Organization (WHO) has declared that Coronavirus disease 2019 (Covid-19) is a public health emergency of international concern as it continues to spread worldwide.<sup>1</sup>

After a median incubation period of 4 days, fever and cough are the two most common manifestations of severe acute respiratory syndrome coronavirus 2 (SARS-CoV-2) infection.<sup>2</sup> Physicians

worldwide are facing this new disease for which little is known about the full spectrum of its clinical features. For instance, some patients with Covid-19 associated cutaneous manifestation have been reported, but there is a lack of iconographic and histological documentation.<sup>3–9</sup> Herein, we describe a febrile rash as the only clinical manifestation of SARS-CoV-2 infection in a patient free from pulmonary symptoms.

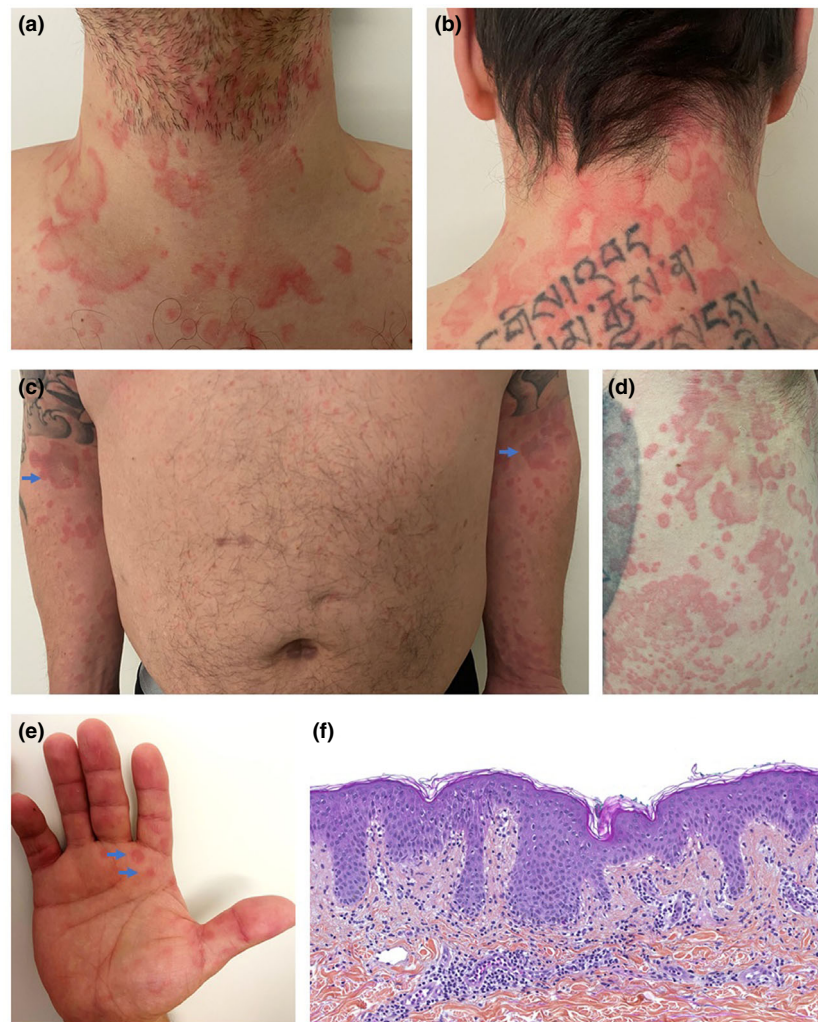
On March the 7th this year, a 39-year-old Caucasian male with no relevant medical history presented to the emergency department with a fever of 39°C, along with a concomitant skin rash that had appeared the same day. This rash was characterized by erythematous and oedematous non-pruritic annular fixed plaques involving the upper limbs, chest, neck, abdomen and palms, sparing the face and mucous membranes (Fig. 1a–e). Importantly, the patient declared having taken no medication in the days and weeks before the onset of symptoms. His vitals were normal, and he had no signs of upper respiratory tract or pulmonary infection.

The patient promptly reported to the physician that he had been in contact 5 days earlier with a family member, who was afterwards tested positive for SARS-CoV-2. Quantitative reverse-transcriptase–polymerase-chain-reaction (qRT-PCR) assay performed on both nasopharyngeal swab and sputum sample revealed the presence of SARS-CoV-2 RNA. The search for other respiratory viruses, such as influenza A and B viruses, rhinovirus, and common coronaviruses was negative, as was the blood culture. Blood count, electrolytes, C-reactive protein and anti-DNA antibodies were normal too. The histological examination of the skin showed non-specific changes, compatible with viral exanthemata: predominantly superficial perivascular infiltrate of lymphocytes without eosinophils, papillary dermal oedema, subtle epidermal spongiosis, mild lymphocyte exocytosis, lichenoid and vacuolar interface dermatitis with occasional dyskeratotic keratinocytes in the basal layer (Fig. 1f). No virally-induced cytopathic alterations or intranuclear inclusions were present. Direct immunofluorescence was negative.

Despite normal chest radiograph on admission, a chest CT scan showed bilateral and peripheral ground-glass and consolidative pulmonary opacities, highly suggestive of SARS-CoV-2 infection.<sup>10</sup>

On March the 8th, the patient started oral hydroxychloroquine sulfate 200 mg three times per day for 10 days with a daily monitoring of SARS-Cov-2 qRT-PCR on nasopharyngeal swab. No pulmonary symptoms developed. On March the 14th, the rash fully recovered and laboratory tests for SARS-CoV-2 qRT-PCR became negative on March the 20th.

Our case report provides two important facts that need highlighting. Firstly, Covid-19 disease can present with a distinctive rash, which is histologically similar but clinically different to classic viral exanthemata. Indeed, the annular, polycyclic and circinate appearance of the skin lesions differed from classic paraviral rashes in adults, as did the papules on the palms. In addition, unlike viral infection-associated urticaria, the plaques were both fixed and non-pruritic. Secondly, a febrile rash may be the only clinical



**Figure 1** Clinical and histological features of Covid-19-associated febrile rash. (a, b) Erythematous, edematous, annular and circinate plaques involving the anterior and posterior neck. (c) Symmetrical distribution of lesions on the upper limbs. (d) Well-defined polycyclic erythematous plaques of various diameters on the right flank. (e) Annular papules of the palms. (f) HPS  $\times 200$ . Histological findings were unspecific but consistent with viral exanthemata: superficial perivascular lymphocytic infiltrate, papillary dermal edema, mild spongiosis, lichenoid and vacuolar interface dermatitis, dyskeratotic basilar keratinocytes, occasional neutrophils but no eosinophils within the dermal infiltrate.


manifestation of Covid-19. As the outbreak spreads around the world, including in medically underdeveloped countries, choices will have to be made regarding which patients need to be tested or not for SARS-CoV-2. We suggest that patients presenting with a febrile rash during the current pandemic should be tested.

### Acknowledgement

The patient in this manuscript has given written informed consent to the publication of his case details.

### Funding source

none.

F. Amatore,<sup>1,\*</sup>  N. Macagno,<sup>2</sup> M. Mailhe,<sup>3,4</sup> B. Demarez,<sup>1</sup> C. Gaudy-Marqueste,<sup>1</sup> J.J. Grob,<sup>1</sup> D. Raoult,<sup>3,4</sup> P. Brouqui,<sup>3,4</sup> M.A. Richard<sup>5</sup>

<sup>1</sup>Department of Dermatology, Timone Hospital, Assistance Publique des Hôpitaux de Marseille, Aix-Marseille University, Marseille, France,

<sup>2</sup>Department of Pathology, Timone Hospital, Assistance Publique des Hôpitaux de Marseille, Aix-Marseille University, Marseille, France, <sup>3</sup>IHU-

Méditerranée Infection, Marseille, France, <sup>4</sup>IRD, APHM, MEPHI, Aix-Marseille University, Marseille, France, <sup>5</sup>CEReSS-EA 3279, Research

Centre in Health Services and Quality of Life Aix Marseille University, Dermatology Department, University Hospital Timone, Assistance

Publique Hôpitaux de Marseille, Marseille, France

\*Correspondence: F. Amatore. E-mail: florent.amatore@ap-hm.fr

## References

- 1 Team E editorial. Note from the editors: World Health Organization declares novel coronavirus (2019-nCoV) sixth public health emergency of international concern. *Eurosurveillance* 2020; **25**: 200131e.
- 2 Huang C, Wang Y, Li X *et al*. Clinical features of patients infected with 2019 novel coronavirus in Wuhan, China. *Lancet* 2020; **395**: 497–506.
- 3 Recalcati S. Cutaneous manifestations in COVID-19: a first perspective. *J Eur Acad Dermatol Venereol* 2020. [Epub ahead of print]. <https://doi.org/10.1111/jdv.16387>
- 4 Joob B, Wiwanitkit V. COVID-19 can present with a rash and be mistaken for Dengue. *J Am Acad Dermatol* 2020; **82**: e177.
- 5 Mahé A, Birckel E, Krieger S *et al*. A distinctive skin rash associated with Coronavirus Disease 2019? *J Eur Acad Dermatol Venereol* 2020. [Epub ahead of print]. <https://doi.org/10.1111/jdv.16471>
- 6 Estébanez A, Pérez-Santiago L, Silva E *et al*. Cutaneous manifestations in COVID-19: a new contribution. *J Eur Acad Dermatol Venereol* 2020. [Epub ahead of print]. <https://doi.org/10.1111/jdv.16474>
- 7 Su CJ, Lee CH. Viral exanthem in COVID-19, a clinical enigma with biological significance. *J Eur Acad Dermatol Venereol* 2020. [Epub ahead of print]. <https://doi.org/10.1111/jdv.16469>
- 8 Henry D, Ackerman M, Sancelme E *et al*. Urticarial eruption in COVID-19 infection. *J Eur Acad Dermatol Venereol* 2020. [Epub ahead of print]. <https://doi.org/10.1111/jdv.16472>
- 9 Mungmungpantipantip R, Wiwanitkit V. COVID-19 and cutaneous manifestations. *J Eur Acad Dermatol Venereol* 2020. [Epub ahead of print]. <https://doi.org/10.1111/jdv.16483>
- 10 Ai T, Yang Z, Hou H *et al*. Correlation of Chest CT and RT-PCR Testing in Coronavirus Disease 2019 (COVID-19) in China: a report of 1014 cases. *Radiology* 2020. [Epub ahead of print]. <https://doi.org/10.1148/radiol.2020200642>

DOI: 10.1111/jdv.16528

## Cutaneous manifestations in COVID-19: the experiences of Barcelona and Rome

Dear Editor,

In December 2019, a new virus called severe acute respiratory syndrome coronavirus 2 (SARS-CoV-2) causing coronavirus disease 2019 (COVID-19) emerged in Wuhan, Hubei Province, China.<sup>1–3</sup> SARS-CoV-2 is transmitted through respiratory droplets and object infected with droplets containing the virus.<sup>1,2</sup> The diagnosis is made employing quantitative reverse transcriptase-polymerase chain reaction to identify the viral nucleic acid in respiratory specimens or blood samples.<sup>2</sup> The symptoms that have been associated with COVID-19 are dry cough, fever, runny nose, dyspnoea, anorexia and even nausea and diarrhoea.<sup>1,2</sup> In severe cases, the patients may develop coagulation dysfunction, acute respiratory distress syndrome (ARDS), arrhythmia and septic shock.<sup>1,2</sup>

Since December 2019, the virus has spread in Europe and other regions of the world: Italy and Spain have been among the most affected countries.<sup>4,5</sup>

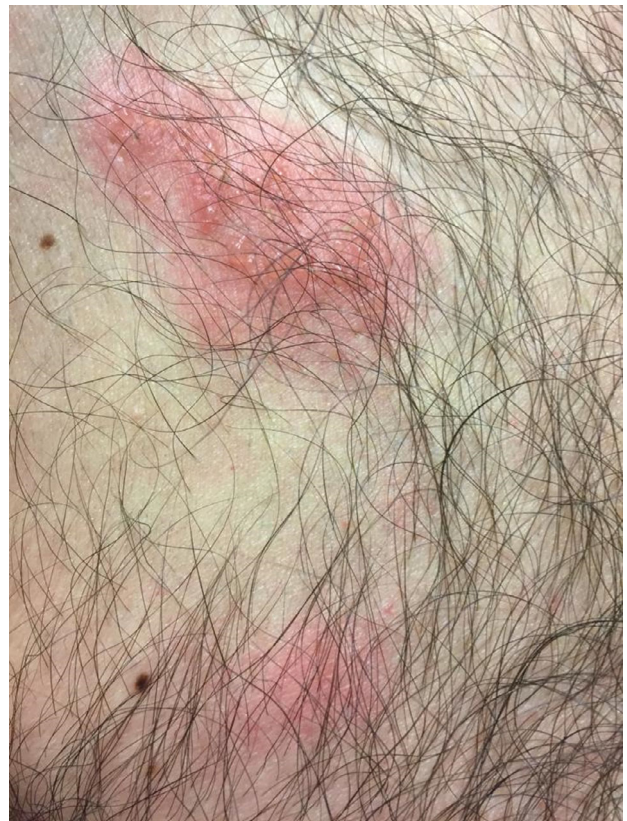
As dermatologists, we tried to comprehend the cutaneous involvement in COVID-19 as there is not much information in this regard in the literature.<sup>6,7</sup>

We identified and visited 130 patients affected by COVID-19 in Sant'Andrea Hospital in Rome, and 2 (1.5%) of them presented with isolated herpetiform lesions on their trunk that had appeared during their inpatient stay (Fig. 1). Such lesions were characterized by vesicles surrounded by erythematous halos and were accompanied by mild pruritus. In one of the patients, the vesicles had started to form crusts.

Furthermore, we visited COVID-19 patients in Vall d'Hebron Hospital in Barcelona and found one patient who presented with numerous vesicular isolated lesions on her back which appeared 8 days after she had been diagnosed with COVID-19 (Fig. 2).

The lesions that we found in both hospitals are suggestive and typical of the infections caused by the members of the Herpesviridae family. We could speculate that they could be caused by either human herpes virus 1 (HHV-1), human herpes virus 2 (HHV-2) or varicella-zoster virus (VZV, HHV-3).

To date, there is only one report that investigates the prevalence and nature of dermatological manifestations associated



**Figure 1** Vesicular lesions surrounded by erythema on the trunk of a patient.