

Ten-Year Outcomes After Catcher's Mask Cranioplasty for Large Cranial Bone Defects in Children: A Report of Two Cases

Toru Sakurai*
Nobuaki Ishii*
Ichiro Takumi†
Rei Ogawa‡
Masataka Akimoto*

SUMMARY: Cranioplasty is complicated in children with severe, extensive head trauma because allografting is not advisable in pediatric patients and the amount of available autologous materials is limited. To overcome these problems, Takumi reported a novel procedure called “catcher’s mask cranioplasty” in 2008, in which split-rib grafts are placed perpendicularly over each other while calvarial grafts are placed in the hairless forehead region. Despite the small amount of grafts used, this method can yield esthetically satisfactory results and provides excellent structural integrity. Here, we report 2 cases of catcher’s mask cranioplasty and their long-term outcomes. After more than 10 years, the transplanted bone grafts have not resorbed and have maintained their esthetically pleasing contours. In conclusion, catcher’s mask cranioplasty is an effective option for traumatic cranial defects in children. (*Plast Reconstr Surg Glob Open* 2019;7:e2395; doi: 10.1097/GOX.0000000000002395; Published online 19 August 2019.)

INTRODUCTION

Preserved autologous bones are often used in staged cranioplasty. However, infected, contaminated, and tumor-bearing bones cannot be used. Another option is to use alloplastic materials. However, they should be avoided in growing children because they do not expand as the child grows and can result in bone fractures and deformation. Since a preserved skull, if available, would be resorbed, fresh autologous bones are the best option for cranioplasty in children. However, the amount of available fresh bones is limited. Thus, it is difficult to cover large skull defects in pediatric patients with fresh autologous bones.

To address this, Takumi developed and reported a novel procedure called “catcher’s mask cranioplasty” for children with an open head injury in 2008.¹ This approach generates esthetically satisfactory results and excellent structural integrity despite employing a relatively small amount of grafts. We report here the cases and long-term

(>10 years) outcomes of 2 children who underwent this surgery.

CASE PRESENTATION

Case 1

A 6-year-old boy was admitted to our hospital following a traffic accident in May 2004. An initial examination revealed lacerated wound in the center of the frontal region, laceration of the dura mater, and an open depressed skull fracture with cerebral contusion and brain protrusion. Emergency surgery was performed with coronal skin incision in which contaminated bones and dura mater and the contused left frontal brain were excised. The dura was fabricated with a free right fascia lata. The patient had a good clinical course after the surgery.

A catcher’s mask reconstruction was performed in June 2005 (Fig. 1A). The grafts were strong enough to help the patient succeed in postsurgical rehabilitation: after the rehabilitation programs had finished, the patient no longer needed assistance with daily living. He also did not have to wear a helmet. Computed tomography (CT) imaging 11 years after the cranioplasty revealed bone regeneration between the grafts and no apparent bone resorption. This resulted in good maintenance of the anatomic contours that were obtained by the cranioplasty (Fig. 1B).

Case 2

A 9-year-old boy was brought to our hospital in January 2002 after his head was crushed by a tractor. He had

Disclosure: The authors have no financial interest to declare in relation to the content of this article.

From the *Department of Plastic Surgery, Nippon Medical School, Chiba Hokusoh Hospital, Chiba, Japan; †Department of Neurosurgery, St. Marianna University of Medicine, Kanagawa, Japan; and ‡Department of Plastic, Reconstructive, and Aesthetic Surgery, Nippon Medical School, Tokyo, Japan.

Received for publication January 24, 2019; accepted June 24, 2019.

Copyright © 2019 The Authors. Published by Wolters Kluwer Health, Inc. on behalf of The American Society of Plastic Surgeons. This is an open-access article distributed under the terms of the Creative Commons Attribution-Non Commercial-No Derivatives License 4.0 (CCBY-NC-ND), where it is permissible to download and share the work provided it is properly cited. The work cannot be changed in any way or used commercially without permission from the journal.

DOI: 10.1097/GOX.0000000000002395

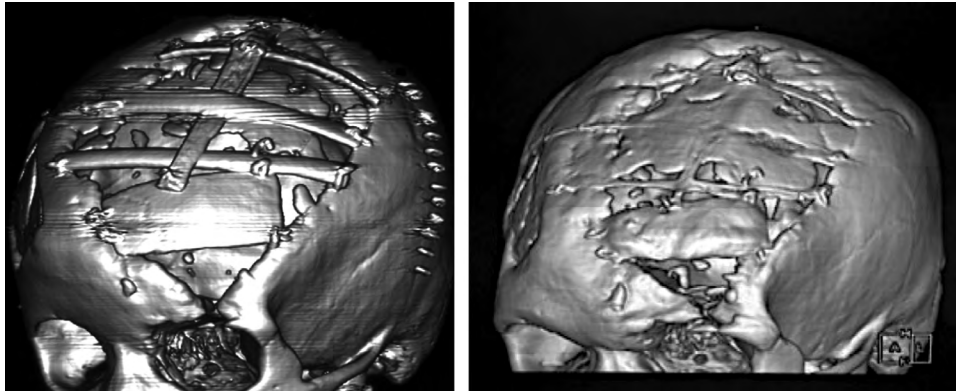


Fig. 1. Catcher's mask cranioplasty in a 6-year-old boy. A, The CT image 6 days after the cranioplasty. (Retrieved with permission from Ichiro T, Masataka A. Catcher's mask cranioplasty for extensive cranial defects in children with an open head trauma: a novel application of partial cranioplasty. *Childs Nerv Syst* 2008;24:927–932). B, The CT image 11 years after the cranioplasty at the age of 17 years.

a laceration in the right temporal region and prolapse of the brain. A head CT scan revealed subdural/subarachnoid hemorrhage and cerebral contusion in the right fronto-parietal area. An emergency decompressive craniectomy was performed to remove the hematomas and contaminated bones and to reconstruct the dura with free right fascia lata. He had a good clinical course after the surgery.

A catcher's mask reconstruction was performed in July 2002 (Fig. 2A). The graft strength also appears to have been sufficient in this case because 13 years after the cranioplasty, the patient has no associated physical or neurological deficits and is currently undergoing university education. The use of calvarial grafts in the forehead resulted in an esthetically pleasing shape. The CT imaging 13 years after the cranioplasty showed no apparent bone resorption (Fig. 2B).

DISCUSSION

The most important objective in cranioplasty is to protect the intracranium from external forces. Damage caused by these forces can be avoided by reconstruction

with hard tissues. It also decreases the risk of sinking skin flap syndrome.² Another crucial objective in cranioplasty is to revise the deformation of the head; cranial defects in a hairless area are associated with significant esthetic disadvantages.

Although alloplastic cranioplasty has been performed in children,³ many studies suggest the superiority of natural materials.⁴ Additionally, the presence of artificial materials during the child's growth may cause bone fractures and deformation. Preserved bones, if the contamination is mild, may be prepared for cranial reconstruction by ethanol treatment or freezing after autoclaving. However, a preserved skull would be easily resorbed in children with severe extensive head trauma.⁵ Therefore, fresh autologous bone is the preferred material for pediatric cranioplasty.

Calvarial bones have been used for cranioplasty and provide an esthetically pleasing shape.⁶ Fearon et al. reported split calvarial grafting up to 500 cm².⁷ However, the external and internal plates of the skull gradually separate in children; therefore, such grafting is not advisable to cover large defects as it is difficult to split the

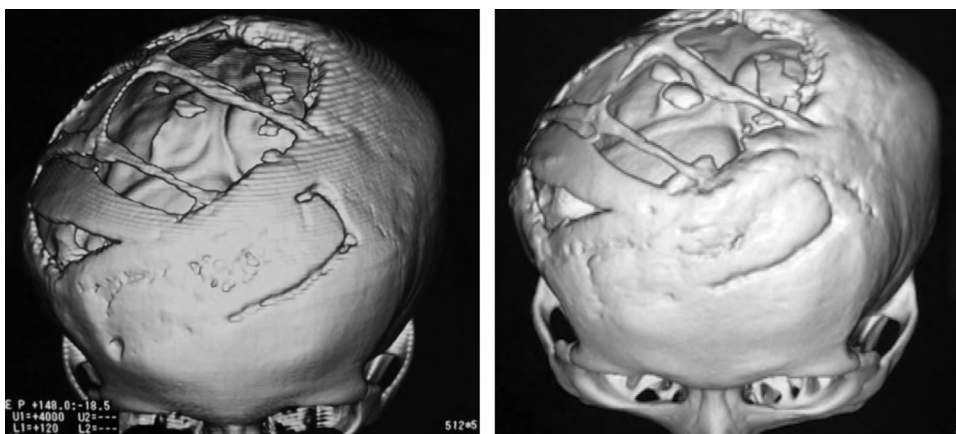


Fig. 2. Catcher's mask cranioplasty in a 9-year-old boy. A, The CT image 10 days after the cranioplasty. B, The CT image 13 years after the cranioplasty at the age of 22 years.

skull in children.⁸ When the cranial defect is large, one can place rib grafts in parallel over the defect.⁹ However, the cosmetic results of this approach are poor. Catcher's mask cranioplasty is a revised technique that combines both calvarial grafts at the forehead area and rib grafts,¹ which can be applied for large defects without complicated and difficult manipulation. The resulting cosmetic contours are satisfactory because of the placement of the calvarial grafts at the forehead or hairless area. The split rib grafts are placed perpendicularly across each other. This cross-rib fixation provides more strength than parallel placement.

The CT imaging in Case 1 showed that superior osteogenesis is observed when transplanted bones are combined with islands of osteoanagenesis. Although there may be concerns that osteogenesis of the reconstructed bones in Case 2 was less superior compared to that in Case 1, we insist on achieving the most important goal, which was to protect the intracranium. We may consider surgical revision if a more perfect symmetric contour and structural integrity is required in the future.

Another similar method of cranioplasty involves the use of parallel rib grafting to a secondary parietal calvarial donor site with the use of the parietal calvarium for the primary defect. This technique requires wider skin incisions, more than the catcher's mask technique, which is not desirable when repeated infection is an issue.¹⁰

CONCLUSIONS

We report here 2 cases of catcher's mask cranioplasty and their long-term outcomes. In both cases, the transplanted bone grafts were not resorbed and maintained their esthetically pleasing contour for more than 10 years. Thus, catcher's mask cranioplasty is an effective option for traumatic cranial defects in children.

Masataka Akimoto, MD, PhD

Department of Plastic Surgery, Nippon
Medical School, Chiba Hokusoh Hospital
1751 Kamagari, Inzai City
Chiba 270-1694, Japan
Telephone: +81-476-99-1111
Fax: +81-476-99-1939
E-mail: akimoto@nms.ac.jp

REFERENCES

1. Ichiro T, Masataka A. Catcher's mask cranioplasty for extensive cranial defects in children with an open head trauma: a novel application of partial cranioplasty. *Childs Nerv Syst.* 2008;24:927-932
2. Yamaura A, Makino H. Neurological deficits in the presence of the sinking skin flap following decompressive craniectomy. *Neurol Med Chir (Tokyo).* 1977;17(1 Pt 1):43-53.
3. Fu KJ, Barr RM, Kerr ML, et al. An outcomes comparison between autologous and alloplastic cranioplasty in the pediatric population. *J Craniofac Surg.* 2016;27:593-597.
4. Lee HJ, Choi JW, Chung IW. Secondary skull reconstruction with autogenous split calvarial bone grafts versus nonautogenous materials. *J Craniofac Surg.* 2014;25:1337-1340.
5. Bowers CA, Riva-Cambrin J, Hertzler DA II, et al. Risk factors and rates of bone flap resorption in pediatric patients after decompressive craniectomy for traumatic brain injury. *J Neurosurg Pediatr.* 2013;11:526-532.
6. Tessier P. Autogenous bone grafts taken from the calvarium for facial and cranial applications. *Clin Plast Surg.* 1982;9:531-538.
7. Fearon JA, Griner D, Dittthakasesem K, et al. Autogenous bone reconstruction of large secondary skull defects. *Plast Reconstr Surg.* 2017;139:427-438.
8. Koenig WJ, Donovan JM, Pensler JM. Cranial bone grafting in children. *Plast Reconstr Surg.* 1995;95:1-4.
9. Longacre JJ, Destefano GA. Further observations of the behavior of autogenous split-rib grafts in reconstruction of extensive defects of the cranium and face. *Plast Reconstr Surg (1946).* 1957;20:281-296.
10. Kawakami K, Takahara N, Yamanouchi Y, et al. Split rib cranioplasty [Article in Japanese]. *No Shinkei Geka.* 1989;17:1023-1027.