

## Case report

# Sebaceous carcinoma arising within an ovarian mature cystic teratoma: A case report with discussion of clinical management and genetic evaluation



Alyssa Wield<sup>a,\*</sup>, Melissa Hodeib<sup>a</sup>, Mohammad Khan<sup>b</sup>, Lindsay Gubernick<sup>a</sup>, Andrew J. Li<sup>a</sup>, Shivani Kandukuri<sup>b</sup>

<sup>a</sup> Department of Obstetrics and Gynecology, Division of Gynecologic Oncology, Cedars-Sinai Medical Center, United States

<sup>b</sup> Department of Pathology, Cedars-Sinai Medical Center, United States

## ARTICLE INFO

**Keywords:**

Sebaceous carcinoma  
Mature cystic teratoma  
Dermoid cyst  
Lynch syndrome  
Muir-Torre syndrome  
Hereditary nonpolyposis colorectal cancer (HNPCC)

## ABSTRACT

Sebaceous carcinomas are rare tumors, with the majority of described cases occurring within the eyelid. To date, there are nine documented reports of sebaceous carcinoma arising within a mature cystic teratoma of the ovary. Although the majority of cases originate from idiopathic mutations, there exists a strong association between this rare tumor and hereditary syndromes of DNA mismatch repair deficiency, such as Lynch syndrome and the lesser-known Muir-Torre syndrome. Here we present the case of a 67-year-old woman with a longstanding history of a small left ovarian cyst with sonographic features of an ovarian dermoid. After nine years, the left adnexal mass was noted to have enlarged, and she underwent a laparoscopic bilateral salpingo-oophorectomy. The final pathology was reported as sebaceous carcinoma arising within a mature cystic teratoma. The patient underwent subsequent surgical staging and has been followed for eight months without evidence of disease. This report includes a review of the current literature, as well as a brief discussion of the clinical management of women with sebaceous carcinoma arising within a mature teratoma. Additionally, we comment on the broader, hereditary significance of a diagnosis of sebaceous carcinoma, and use this case to demonstrate the thorough histologic and genetic evaluation that is recommended for patients diagnosed with this rare tumor.

## 1. Introduction

Mature cystic teratomas, or dermoid cysts, are the most common ovarian germ cell tumors. They are generally benign, with only 1–2% of cases undergoing malignant transformation (Ayhan et al., 2000). Sebaceous carcinomas are rare, with the majority of described cases occurring in the eyelid; sebaceous carcinomas arising within a mature teratoma are exceedingly uncommon, with only nine cases described to date (Search engine: PubMed; Search terms: sebaceous carcinoma AND mature cystic teratoma OR teratoma OR dermoid cyst) (Betta and Cosimi, 1984; Chumas and Scully, 1991; Changchien et al., 1994; Papadopoulos et al., 1995; Vartanian et al., 2002; Ribeiro-Silva et al., 2003; Venizelos et al., 2009; An et al., 2013; Moghaddam et al., 2013). A notable association exists between sebaceous carcinoma and Muir-Torre syndrome, a hereditary autosomal dominant cancer-predisposition syndrome associated with sebaceous tumors as well as the development of internal malignancies of the gastrointestinal and genitourinary tract. Muir-Torre syndrome is a phenotypic variant of Lynch syndrome that results from germline mutations in DNA mismatch repair (MMR) genes (Ponti and Leon, 2005). Due to the strength of the

association and the rarity of sebaceous carcinomas, most experts recommend screening all sebaceous neoplasms for MMR defects via immunohistochemistry or microsatellite instability (MSI) testing, even in the absence of a personal or family history of Muir-Torre syndrome. Those with negative immunohistochemistry for MSH2, MSH6, MLH1 or PMS2, or tumors with high MSI, should be referred to a genetic counselor (Everett et al., 2014).

## 2. Clinical history

A 67-year-old white female presented to the Gynecologic Oncology clinic at our hospital with several months of worsening abdominal distention, urinary frequency and pelvic pressure. Her medical history was notable for a 3 cm left adnexal mass first diagnosed nine years prior, with sonographic features of a dermoid cyst. The patient followed with her gynecologist for seven years with no sonographic changes appreciated. She was referred to Gynecologic Oncology in December 2017 after the aforementioned symptoms began. Upon presentation, a physical examination and pelvic ultrasound confirmed a 12.0 × 13.0 × 9 cm complex mass arising from the left adnexa. A pre-

\* Corresponding author at: Cedars-Sinai Medical Center, 8700 Beverly Blvd, Suite 3622, Los Angeles, CA 90048, United States.  
E-mail address: [Alyssa.Wield@cshs.org](mailto:Alyssa.Wield@cshs.org) (A. Wield).

<https://doi.org/10.1016/j.gore.2018.08.011>

Received 20 June 2018; Received in revised form 27 August 2018; Accepted 28 August 2018

Available online 29 August 2018

2352-5789/© 2018 The Authors. Published by Elsevier Inc. This is an open access article under the CC BY-NC-ND license (<http://creativecommons.org/licenses/by-nc-nd/4.0/>).

operative CA-125 level was 9 U/ml. The patient endorsed a dermatologic history including basal cell carcinoma, seborrheic dermatitis and actinic keratosis. Her family history was notable for melanoma in her father and son, and breast cancer in her paternal aunt. She denied family history of gynecologic, gastrointestinal or genitourinary malignancies.

The patient was recommended to undergo laparoscopic bilateral salpingo-oophorectomy. At the time of surgery, a pelvic examination under anesthesia resulted in incidental rupture of the mass. Intraoperative findings included a 10 cm ruptured cyst arising from the left ovary with hemorrhagic fluid and fat. Cyst contents were evacuated and sent for cytology. An intra-abdominal survey revealed normal anatomy without evidence of metastasis. An uncomplicated bilateral salpingo-oophorectomy was performed and frozen section was consistent with a mature teratoma.

On pathologic examination, the specimen was a unilocular pink-tan cystic structure filled with viscous creamy fluid measuring 13.0 × 9.0 × 2.5 cm. The internal lining was generally smooth, but focally shaggy and undulated. The cyst wall ranged from 0.1 cm to 0.3 cm. Microscopic examination revealed nests and lobules of lipid containing sebocytes surrounded by basaloid cells. Focal areas within the sebaceous differentiation had enlarged cells with significant nuclear atypia, a squamoid appearance with increased mitoses, and associated necrosis (Fig. 1). No sebaceous adenoma or basaloid lesion was identified in the background. Based on these features, a diagnosis of well-differentiated sebaceous carcinoma arising within a mature cystic teratoma was made. Immunohistochemical analysis revealed increased expression of Ki-67 (~30%), diffuse nuclear expression of P53 QL, and scattered expression of P16 (Fig. 2). Cytopathologic examination of the peritoneal washings was negative.

Given the association between sebaceous carcinoma and Muir-Torre syndrome, immunohistochemistry for DNA MMR gene expression was performed showing loss of expression of MSH-2 and MSH-6 proteins (Fig. 3). The patient was referred to a genetic counselor and testing revealed somatic inactivation of MSH2(p.Y165\*), MSH2(5'UTR\_3'UTRdel), EPCAM(5'UTR\_3'UTRdel) and MSH6(5'UTR\_3'UTRdel). No germline mutations or promoter hypermethylation of MLH1 gene were identified. Somatic inactivation in MSH6(p.R121C) and a heterozygous germline inactivation in BRCA(p.L1844R), (both variants of unknown significance), were also identified.

The patient's post-operative recovery was uncomplicated. After reviewing the final pathology, she underwent completion staging via total laparoscopic hysterectomy, bilateral pelvic and periaortic lymph node dissection and infracolic omentectomy. Three weeks later at time of reoperation, the uterus was unremarkable and there was no carcinomatosis or ascites. The patient made an uneventful recovery. Final pathology resulted as benign uterus, cervix, omentum and lymph nodes, meeting criteria for stage IC disease. Based on the limited available

data, as well as the low stage and grade of the tumor, the patient was recommended to undergo surveillance and remains without evidence of disease eight months later.

### 3. Discussion

At the time of this publication, only nine cases of sebaceous carcinoma arising within a mature teratoma have been reported, with an estimated incidence of 1–2 per 1,000,000 per year (Betta and Cosimi, 1984; Chumas and Scully, 1991; Changchien et al., 1994; Papadopoulos et al., 1995; Vartanian et al., 2002; Ribeiro-Silva et al., 2003; Venizelos et al., 2009; An et al., 2013; Moghaddam et al., 2013). Sebaceous carcinoma originates from the adnexal epithelium of sebaceous glands. Although it has the potential to develop from any sebaceous gland, this malignancy most commonly arises from the meibomian glands of the eye (Nelson et al., 1995). The exact pathogenesis is unclear; some posit that sebaceous carcinomas arise from pluripotent stem cells, while others suggest they develop from malignant transformation of differentiated sebaceous cells (Ribeiro-Silva et al., 2003). Sebaceous carcinomas arising within mature teratomas are grossly and microscopically similar to those arising from other sites, but are more often large with squamoid appearance and occasional squamous pearls (Vartanian et al., 2002; An et al., 2013). Histologically, sebaceous carcinomas have basaloid cells arranged in sheets with cytologic atypia, central areas of necrosis, and increased mitosis. Sebaceous carcinomas are challenging to classify, and must be distinguished from basal cell carcinomas with sebaceous differentiation or clear cell change, squamous cell carcinomas with clear cell change, and sebaceous adenomas. Although ocular sebaceous carcinomas are aggressive, often recurring locally after surgical resection and metastasizing via lymphatics, the prognosis of extraocular sebaceous carcinoma is thought to be far better (Nelson et al., 1995).

Given the paucity of data directing the management of patients with extraocular sebaceous carcinoma, the optimal treatment plan remains unclear. To date, none of the patients diagnosed with sebaceous carcinomas arising from a mature teratoma have developed recurrent disease, with follow up ranging from 4 to 72 months (Betta and Cosimi, 1984; Chumas and Scully, 1991; Changchien et al., 1994; Papadopoulos et al., 1995; Vartanian et al., 2002; Ribeiro-Silva et al., 2003; Venizelos et al., 2009; An et al., 2013; Moghaddam et al., 2013). In reviewing the literature, three patients with stage IA-IIIc disease were treated with adjuvant chemotherapy, regimens including cyclophosphamide plus adriamycin, combination cisplatin, bleomycin and vinblastine, or single-agent carboplatin. Compared to those with expectantly managed disease, there was no overall survival advantage (Betta and Cosimi, 1984; Changchien et al., 1994; Papadopoulos et al., 1995). However, it remains challenging to interpret these outcomes given the limited number of cases and wide range of disease stage, patient comorbidities,

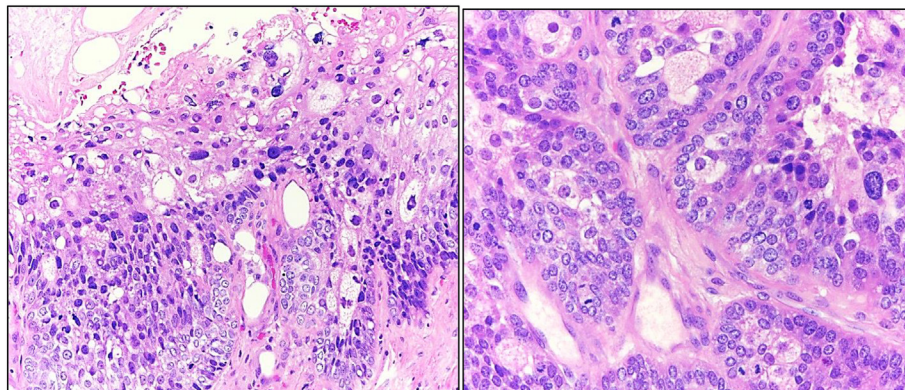
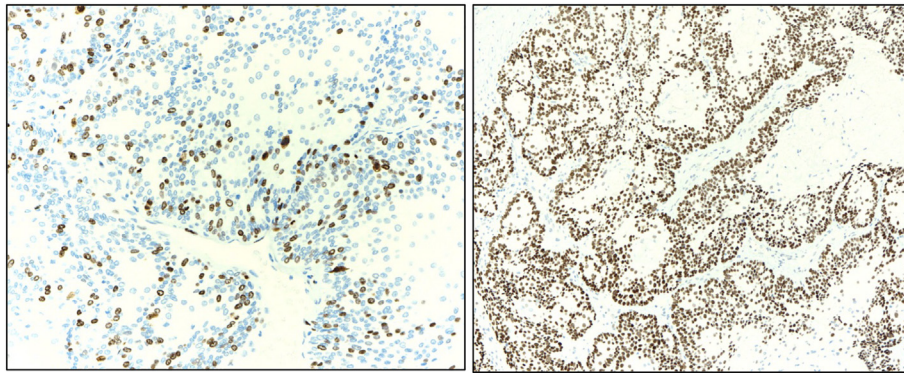


Fig. 1. (Left to right) 1A: Basaloid cells with squamoid features, atypia, pleomorphism and hyperchromasia (H&E original magnification × 100). 1B: Increased mitotic activity (H&E original magnification × 400).



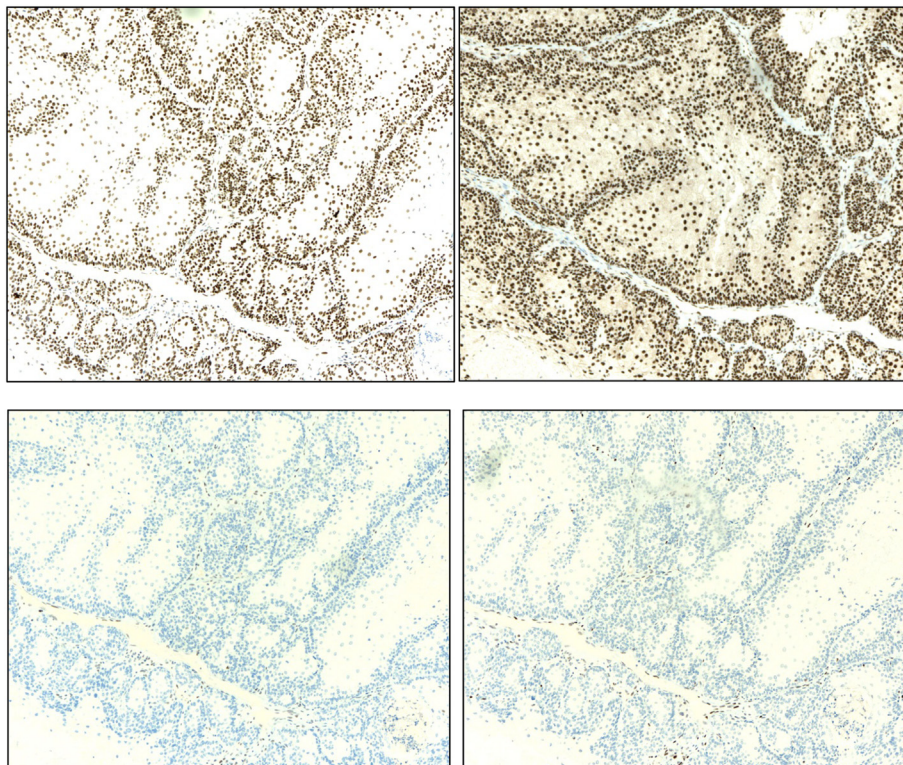
**Fig. 2.** (Left to right) 2A: Increased nuclear Ki-67 immunoreactivity (~30%) within tumors cells (magnification x40, immunohistochemistry) 2B: Strong and diffuse nuclear p53 immunoreactivity within tumor cells (magnification x40, immunohistochemistry).

and adherence to follow up.

In this case, the tumor was localized to the ovary until immediate pre-operative rupture occurred, thus upstaging from stage IA to IC. Research indicates that malignant dermoid cysts confined to the ovary have good overall 5-year survival rates approaching 75% (Changchien et al., 1994). However, capsular rupture and tumor extension are poor prognostic factors in cases of mature teratomas with malignant transformation (Papadopoulos et al., 1995). These conclusions are based on pooled data of all histologic types of malignant transformation within a mature dermoid, and are not specific to sebaceous carcinoma. Furthermore, although there are guidelines for the treatment of immature teratomas via complete surgical resection and staging plus adjuvant platinum-based chemotherapy for all patients except stage IA grade 1, when malignant transformation occurs within a mature teratoma treatment varies and must be tailored towards the transformed histology (Williams et al., 1994). Therefore, we opted to perform a second surgical staging procedure that confirmed only localized disease.

Considering the additional morbidity of adjuvant therapy without clear evidence of a survival benefit in previous case reports, the patient elected to proceed with surveillance.

Lastly, it is important to consider the broader impact of a diagnosis of sebaceous carcinoma. While most cases are idiopathic, there is a significant association with Muir-Torre syndrome. This is a rare genetic condition with autosomal dominant inheritance clinically characterized by the presence of at least one sebaceous skin tumor and at least one visceral malignancy (Ponti and Leon, 2005; John and Schwartz, 2016). Muir-Torre syndrome is a phenotypic variant of Lynch syndrome and results from mutations in DNA MMR genes (Ponti and Leon, 2005). Given the rarity of these tumors, strict use of the clinical criteria to diagnose Muir-Torre syndrome may result in low disease detection. Screening for MMR gene defects by immunohistochemistry or MSI is accessible and provides rapid results. Certain patterns of immunohistochemical loss of staining for DNA MMR gene products have shown high positive predictive value for detecting Muir-Torre



**Fig. 3.** (Left to right) 3A,B: Retained nuclear PMS-2 and MLH-1 immunoreactivity within tumor cells (magnification x40, immunohistochemistry) 3C,D: Loss of nuclear MSH-2 and MSH-6 immunoreactivity within tumor cells (magnification x40, immunohistochemistry).

syndrome (John and Schwartz, 2016). Therefore, most experts recommend screening all sebaceous neoplasms for germline MMR defects. This provides an opportunity for proper referral to a genetic counselor for formal genetic testing and discussion of risk reduction strategies (Ponti and Leon, 2005; Everett et al., 2014). Additionally, this information could be used to guide treatment, as the FDA has approved the use of checkpoint inhibitors (PD1/PD-L1 inhibitors) for patients with metastatic or unresectable solid tumors and evidence of MMR deficiency or MSI. Our patient's genetic testing revealed only somatic mutations of the Lynch syndrome related genes (MSH2, MSH6), and no germline mutations. However, there was increased MSI within the tumor, indicating that she is a candidate for PD1 checkpoint inhibitor therapy if necessary. The patient remains clinically well eight months after diagnosis, and continues with close surveillance.

### Consent

Written informed consent was obtained from the patient for the publication of this case report and accompanying images. A copy of the written consent is available for review upon request.

### Conflict of interest

The authors have no relevant financial relationships or conflicts of interest to report.

### Author contribution

All authors contributed to the literature search. Alyssa Wield, Lindsay Gubernick and Melissa Hodeib drafted the manuscript. Mohammad Khan and Shivani Kandukuri performed the pathologic evaluation and provided the figures and legends. All authors critically

reviewed, edited and approved the final manuscript for publication.

### References

- An, H.J., Jung, Y.H., Yoon, H.K., Jung, S.J., 2013. Sebaceous Carcinoma Arising in Mature Cystic Teratoma of Ovary. *Korean J. Pathol.* 47 (4), 383.
- Ayhan, A., Bukulmez, O., Genc, C., Karamursel, B.S., Ayhan, A., 2000. Mature cystic teratomas of the ovary: case series from one institution over 34 years. *Eur. J. Obstet. Gynecol. Reprod. Biol.* 88 (2), 153–157.
- Betta, P.G., Cosimi, M.F., 1984. Sebaceous carcinoma arising in a benign cystic teratoma of the ovary: case report. *Eur. J. Gynaecol. Oncol.* 2, 146–149.
- Changchien, C.-C., Chen, L., Eng, H.-L., 1994. Sebaceous carcinoma arising in a benign dermoid cyst of the ovary. *Acta Obstet. Gynecol. Scand.* 73 (4), 355–358.
- Chumas, J.C., Scully, R.E., 1991. Sebaceous Tumors Arising in Ovarian Dermoid Cysts. *Int. J. Gynecol. Pathol.* 10 (4), 356–363.
- Everett, J.N., Raymond, V.M., Dandapani, M., Marvin, M., Kohlmann, W., Chittenden, A., et al., 2014. Screening for Germline Mismatch Repair Mutations following Diagnosis of Sebaceous Neoplasm. *JAMA Dermatol.* 150 (12), 1315 Jan.
- John, A.M., Schwartz, R.A., 2016. Muir-Torre syndrome (MTS): an update and approach to diagnosis and management. *J. Am. Acad. Dermatol.* 74 (3), 558–566.
- Moghaddam, Y., Lindsay, R., Tolhurst, J., Millan, D., Siddiqui, N., 2013. A case of sebaceous carcinoma arising in a benign cystic teratoma of the ovary and review of the literature. *Scott. Med. J.* 58 (2).
- Nelson, B.R., Hamlet, K., Gillard, M., Railan, D., Johnson, T.M., 1995. Sebaceous carcinoma. *J. Am. Acad. Dermatol.* 33 (1), 1–15.
- Papadopoulos, A., Ahmed, H., Pakarian, F., Caldwell, C., McNicholas, J., Raju, K., 1995. Sebaceous carcinoma arising within an ovarian cystic mature teratoma. *Int. J. Gynecol. Cancer* 5 (1), 76–79.
- Ponti, G., Leon, M.P.D., 2005. Muir-Torre syndrome. *Lancet Oncol.* 6 (12), 980–987.
- Ribeiro-Silva, A., Chang, D., Bisson, F.W., Ré, L.O.M., 2003 Jan. Clinicopathological and immunohistochemical features of a sebaceous carcinoma arising within a benign dermoid cyst of the ovary. *Virchows Arch.* 443 (4), 574–578.
- Vartanian, R.K., Mcrae, B., Hessler, R.B., 2002. Sebaceous Carcinoma Arising in a Mature Cystic Teratoma of the Ovary. *Int. J. Gynecol. Pathol.* 21 (4), 418–421.
- Venizelos, I.D., Tatsiou, Z.A., Roussos, D., Karagiannis, V., 2009. A Case of Sebaceous Carcinoma Arising within a Benign Ovarian Cystic Teratoma. *Onkologie* 32 (6), 353–355.
- Williams, S., Blessing, J.A., Liao, S.Y., Ball, H., Hanjani, P., 1994. Adjuvant therapy of ovarian germ cell tumors with cisplatin, etoposide, and bleomycin: a trial of the Gynecologic Oncology Group. *J. Clin. Oncol.* 12 (4), 701.