

# Preoperative evaluation of pleural adhesion in patients with lung tumors using four-dimensional computed tomography performed during natural breathing

Kotaro Mizuno, MD<sup>a,\*</sup>, Masahiro Muto, MD<sup>b</sup>

## Abstract

The presence of pleural adhesions increases blood loss, occurrence of pulmonary fistulation due to lung injury, and operative time and may complicate thoracoscopic surgery. Recently, it has been reported that four-dimensional computed tomography (4D-CT) synchronized with breathing predicts pleural adhesion. These studies have been performed by asking the patients to maintain a constant respiratory rhythm at the time of scanning. However, many patients face difficulty in doing so, particularly elderly individuals and patients with respiratory dysfunction. We examined the utility of 4D-CT performed while maintaining a natural breathing pattern, which reduces patient burden, in detecting pleural adhesions.

A total of 36 patients with a lung tumor near the pleura underwent 4D-CT during free breathing. The migration distance between the lesion and the nearest point on the chest wall on 4D-CT was measured. A sufficient distance indicated the absence of adhesion in that area. The presence of actual adhesions was evaluated and confirmed by intraoperative thoracoscopic findings.

There were 7 cases determined to have adhesion by 4D-CT, and 4 of them had actual adhesions confirmed during surgery. The sensitivity and specificity were 80.0% and 90.3%, respectively. The mean migration distance of tumors was  $0.8 \pm 0.2$  cm in the 5 cases with adhesion and  $2.6 \pm 1.8$  cm in the 31 cases without adhesion ( $P = .01$ ).

These results suggest that 4D-CT is a convenient and useful technique for the preoperative assessment of pleural adhesion.

**Abbreviations:** 4D-CT = four-dimensional computed tomography, CT = computed tomography, VATS = video-assisted thoracoscopic surgery.

**Keywords:** four-dimensional computed tomography, pleural adhesion

## 1. Introduction

Video-assisted thoracoscopic surgery (VATS) plays a major role in the resection of lung tumors. VATS lobectomy is equivalent to thoracotomy in terms of overall survival and recurrence rates. However, it is more difficult to perform VATS than thoracotomy

for lung tumors. Furthermore, the presence of pleural adhesions may complicate thoracoscopic surgery and require switching to thoracotomy.<sup>[1]</sup> Pleural adhesions have disadvantages such as increased blood loss, pulmonary fistula due to lung injury, and longer operating times. Appropriate informed consent can be obtained from patients preoperatively if pleural adhesions can be predicted beforehand. Therefore, it is necessary to perform a preoperative assessment of the pleural adhesion. The purpose of this prospective study was to evaluate the presence of pleural adhesions preoperatively using four-dimensional computed tomography (4D-CT) synchronized with breathing to ensure a safe thoracoscopic surgical procedure. 4D-CT is an image inspection method that enables dynamic evaluation by adding a time axis to three-dimensional computed tomography. Recently, it has been reported that 4D-CT synchronized with breathing predicts pleural adhesion.<sup>[1]</sup> These studies were performed by asking patients to maintain a constant respiratory rhythm at the time of scanning. However, this may be difficult to carry out in clinical practice, where many patients, such as elderly individuals and patients with respiratory dysfunction, face difficulty in maintaining a constant respiratory rhythm. We employed and examined the utility of 4D-CT during natural breathing, a method that can be used to evaluate adhesions while reducing patient burden.

## 2. Materials and methods

This study was approved by the Institutional Review Board and all patients provided written informed consent. The patients were

Editor: Hyunjin Park.

The authors have no conflicts of interests to disclose.

The datasets generated during and/or analyzed during the current study are not publicly available, but are available from the corresponding author on reasonable request.

<sup>a</sup> Department of Thoracic Surgery, Nagoya City University East Medical Center, Nagoya, Japan, <sup>b</sup> Department of Radiology, Nagoya City University East Medical Center, Nagoya, Japan.

\* Correspondence: Kotaro Mizuno, Department of Thoracic Surgery, Nagoya City University East Medical Center, 1-2-23 Wakamizu-cho, Chikusa-ku, Nagoya-city, Aichi, Japan (e-mail: kotaro087@gmail.com).

Copyright © 2021 the Author(s). Published by Wolters Kluwer Health, Inc. This is an open access article distributed under the terms of the Creative Commons Attribution-Non Commercial License 4.0 (CCBY-NC), where it is permissible to download, share, remix, transform, and buildup the work provided it is properly cited. The work cannot be used commercially without permission from the journal.

How to cite this article: Mizuno K, Muto M. Preoperative evaluation of pleural adhesion in patients with lung tumors using four-dimensional computed tomography performed during natural breathing. *Medicine* 2021;100:47(e27800).

Received: 6 August 2021 / Received in final form: 14 October 2021 / Accepted: 28 October 2021

<http://dx.doi.org/10.1097/MD.00000000000027800>

<b>Table 1</b>	
<b>Patients' characteristics.</b>	
	<b>Number of patients n=36</b>
Age	71.7±7.75
Gender	
Male	23
Female	13
Tumor location	
RU	6
RM	3
RL	7
LU	10
LL	10
Tumor size	2.19±1.14 cm
Performed operation	
Lobectomy	20
Segmentectomy	3
Wedge resection	13
histology	
Adenocarcinoma	20
Squamous cell carcinoma	9
Large cell neuroendocrine carcinoma	1
Sarcomatoid carcinoma	1
Metastatic carcinoma	4
Benign tumor	1
prediction of pleural adhesion	
With	7
Without	29
actual pleural adhesion	
With	5
Without	31

LL = left lower lobe, LU = left upper lobe, RL = right lower lobe, RM = right middle lobe, RU = right upper lobe.

informed that 4D-CT has the advantage of predicting surgical invasion or adhesion, thereby ensuring a safe thoracoscopic surgical procedure, but it also has the disadvantage of an increased radiation dose compared to conventional computed tomography (CT).

The study population comprised 36 patients with lung tumors who were referred to our hospital between April 2018 and May 2020. To obtain sufficient patient population in terms of tumor location with respect to each lobe, consecutive cases were included until the required number of patients was obtained for every lobe. The tumors were located in the right upper lobe (n = 6), right middle lobe (n = 3), right lower lobe (n = 7), left upper lobe (n = 10), and left lower lobe (n = 10) of the lungs. There were 23 men and 13 women with a mean age of 71.7±7.75 years. The mean tumor size was 2.19±1.14 cm on axial CT imaging. Histopathological examinations revealed adenocarcinoma (n = 20), squamous cell carcinoma (n = 9), large cell neuroendocrine carcinoma (n = 1), sarcomatoid carcinoma (n = 1), metastatic carcinoma (n = 4), and a benign tumor (n = 1). The performed operations included lobectomy (n = 20), segmentectomy (n = 3), and wedge resection (n = 13; Table 1). The patients underwent 4D-CT with natural breathing preoperatively. Our 4D-CT technique involved the use of a 64-slice 1.2-mm multidetector CT scanner (SOMATOM Drive, Siemens, Munich, Germany). First, prior to performing 4D-CT, patients' natural breathing was observed, and a protocol was created according to each patient's breathing. The basic protocol involved scanning for 12 seconds. The scanning parameters were as follows: tube voltage, 100 kV;

tube current, 100 mA; rotation time, 0.28 sec; field of view, 150 to 284 mm; collimation, 1.2 mm; and slice thickness, 1.5 mm. The scan data were reconstructed and analyzed using an image analysis software (SYNAPSE VINCENT, FUJI FILM, Tokyo, Japan).

The outcome was the migration distance between the lesion and the nearest point on the chest wall. A sufficient distance indicated the absence of adhesion in that area. The presence of actual adhesions was evaluated and confirmed by intraoperative thoracoscopic findings.

The diagnostic accuracy of the 4D-CT assessment, including sensitivity and specificity was evaluated. Comparisons between the groups with and without pleural adhesion were performed using the Student *t* test.

### 3. Results

4D-CT imaging revealed restricted movements between the tumor and the nearest point on the chest wall in 7 cases, suggesting the presence of adhesions. Case 1 involved a 5.9 cm tumor in the left upper lobe, and the migration distance from the nearest point on the chest wall was 0.4 cm. Case 2 involved a 1.4 cm tumor in the left upper lobe, and the migration distance starting from the nearest point on the chest wall was 0.6 cm. Case 3 involved a 1.8 cm tumor in the right lower lobe, and the migration distance from the nearest point on the chest wall was 7.7 cm. The tumor was in contact with the diaphragm, and there was no movement in that area, suggesting the presence of adhesions. Case 4 involved a 5.0 cm tumor in the left upper lobe, and the migration distance from the nearest point on the chest wall was 0.6 cm. Case 5 involved a 1.7 cm tumor in the left lower lobe, and the migration distance from the nearest point on the chest wall was 0.8 cm. Case 6 involved a 2.1 cm tumor in the left lower lobe, and the migration distance from the nearest point on the chest wall was 0.6 cm. Case 7 involved a 1.2 cm tumor in the right upper lobe, and the migration distance from the nearest point on the chest wall was 0.7 cm. Adhesion in cases 4, 5, 6, and 7 was confirmed only by operation. Case 8 involved a 1.0 cm tumor in the right upper lobe, and the migration distance from the nearest point on the chest wall was 0.7 cm. No adhesion was initially found on 4D-CT, but slight adhesions were observed after surgery (Table 2). The mean migration distance of the tumors was 0.8±0.2 cm in the 5 cases with adhesion and 2.6±1.8 cm in the 31 cases without adhesion ( $P=.01$ ) (Table 3). Furthermore, when the pleural adhesions and the migration distance were evaluated in the upper and lower lobes on both sides, a significant difference was found only in the lower lobe ( $P<.01$ ) (Tables 4 and 5). The sensitivity and specificity of the evaluation of adhesion using 4D-CT were 80.0% and 90.3%, respectively.

### 4. Discussion

Preoperative evaluation of pleural adhesion for lung tumors is essential for selecting the optimal treatment strategy and procedure.<sup>[2-6]</sup> The proper management of pleural adhesion or invasion is important for curative resection, especially for malignant tumors.<sup>[4,7]</sup> In this study, despite 4D-CT being performed while breathing naturally, adhesions could be evaluated in the same way as in the conventional procedure. This procedure may reduce patient burden while evaluating pleural adhesions in elderly patients and patients with respiratory

**Table 2**  
**Comparison of tumor size and migration distance with and without adhesion.**

Case	Age	Gender	Location	Tumor size (cm)	Migration distance (cm)	Prediction of adhesions	Actual adhesions
1	72	Female	LU	5.9	0.4	With	Without
2	78	Male	LU	1.4	0.6	With	Without
3	75	Male	RL	1.8	7.7	With	Without
4	75	Male	LU	5	0.6	With	With
5	79	Male	LL	1.7	0.8	With	With
6	78	Female	LL	2.1	0.6	With	With
7	79	Female	RU	1.2	0.7	With	With
8	59	Male	RU	1	0.7	Without	With

LL = left lower lobe, LU = left upper lobe, RL = right lower lobe, RU = right upper lobe.

**Table 3**  
**Comparison of tumor size and migration distance with and without adhesion.**

	mean+- SD		P value
	Patients with pleural adhesion (n=5)	Patients without pleural adhesion (n=31)	
Tumor size (cm)	2.2+-1.6	2.2 + -1.1	NS (0.5)
total migration distance (cm)	0.8+-0.2	2.6 + -1.8	.01

SD = standard deviation, NS = not significant.

dysfunction. It has been reported that pleural adhesion can be detected by pleural thickening, subpleural interstitial shadows, and visceral pleural retraction even with conventional CT.<sup>[3]</sup> However, these findings rely on the experience of the technician and lack objectivity.<sup>[3]</sup> 4D-CT, which allows for observation of organ movement due to respiration, is more advantageous for the objective evaluation of adhesions compared to conventional CT.<sup>[7,8]</sup> When the tumor is not adherent to the chest wall, it moves along the chest wall in synchrony with breathing. In contrast, it will move less in the presence of adhesion.<sup>[4]</sup> Furthermore, other CT imaging modalities such as three-dimensional computed tomography of blood vessels can be performed simultaneously, which reduces the burden on the patient.<sup>[8]</sup> Because the movement of the lung tumor is not two-dimensional, it is necessary to construct a 3D image from the 4D-CT information and judge the tumor’s movement three-

dimensionally.<sup>[1]</sup> The radiation exposure in 4D-CT is higher than that in conventional CT, which is a disadvantage of 4D-CT. To reduce the radiation dose, ultra-low-dose CT should be considered in the future. Furthermore, four-dimensional magnetic resonance imaging can be performed instead of 4D-CT to evaluate adhesion and avoid radiation exposure, but this is not done at our hospital because both temporal and spatial resolutions of four-dimensional magnetic resonance imaging are inferior to those of 4D-CT.

In this study, the total migration distance of the lung tumor and the surrounding structures was significantly different between patients with and without pleural adhesions. Regarding the location of the lesion’s contact point, the lower lobe showed a significant difference in the migration distance with and without adhesions, but the upper lobe did not. In this study, the tumor of the upper lobe that had adhesion had a migration distance of 0.7

**Table 4**  
**Comparison of tumor size and migration distance with and without adhesion of upper lobe.**

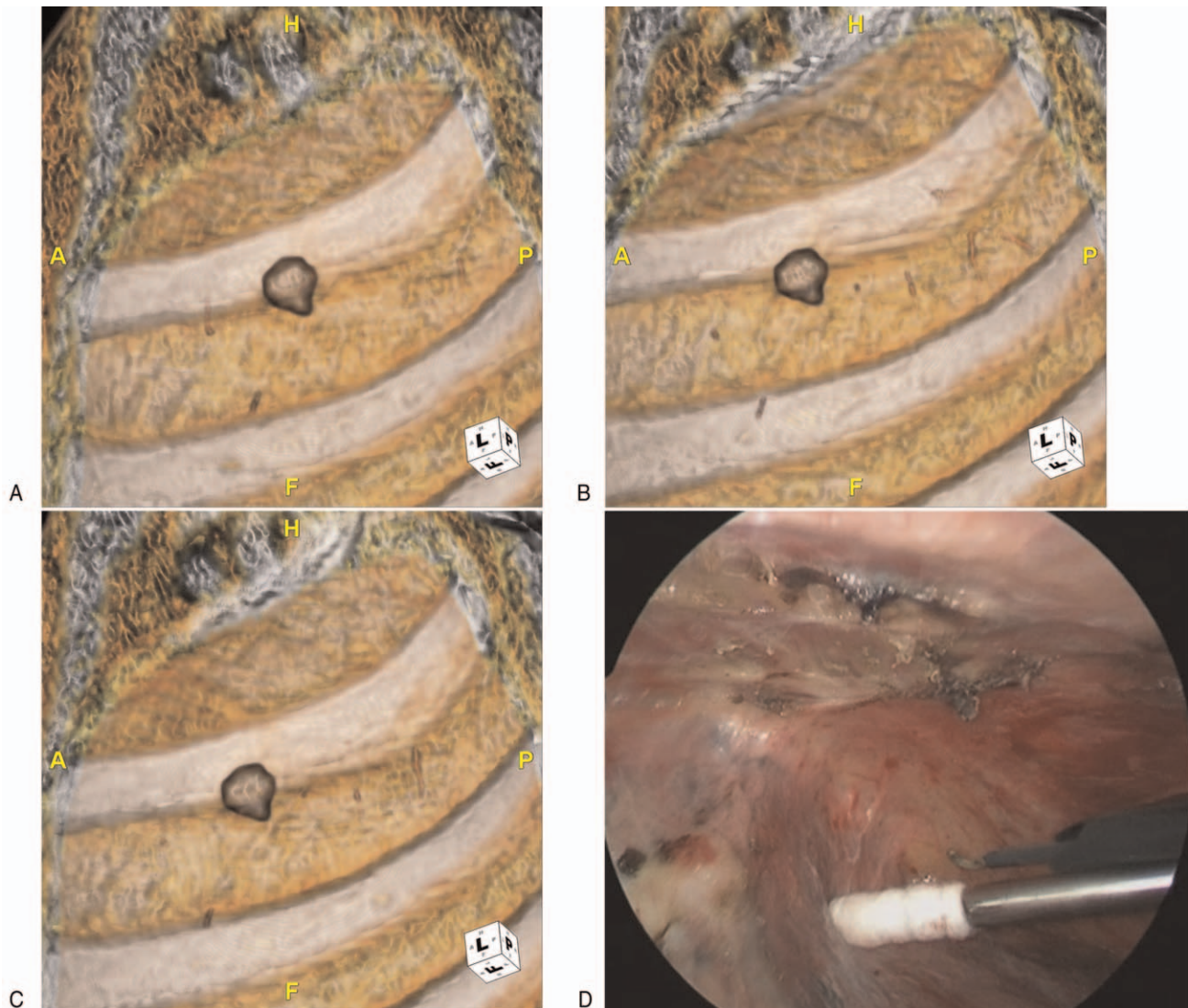
	mean+- SD		P value
	Patients with pleural adhesion of upper lobe (n=3)	Patients without pleural adhesion of upper lobe (n=13)	
Tumor size (cm)	2.4 + -2.3	2.3 + -1.3	NS (0.9)
total migration distance (cm)	0.8 + -0.3	1.3 + -0.8	NS (0.08)

SD = standard deviation, NS = not significant.

**Table 5**  
**Comparison of tumor size and migration distance with and without adhesion of lower lobe.**

	mean+- SD		P value
	Patients with pleural adhesion of lower lobe (n=2)	Patients without pleural adhesion of lower lobe (n=15)	
Tumor size (cm)	1.9 + -0.3	2.3 + -0.9	NS (0.2)
total migration distance (cm)	0.7 + -0.1	3.9 + -1.5	<.01

SD = standard deviation, NS = not significant.



**Figure 1.** (A, B, C): Adenocarcinoma of the right upper lobe. 4D-CT revealed almost no movement of the lesions due to breathing. The migration distance due to respiration was 0.7 cm. The presence of adhesion was also predicted. (D): Presence of adhesion was confirmed during operation.

cm (Fig. 1), and that of cases with no adhesions were 0.4 cm or 0.6 cm, which made adhesion difficult to evaluate for the upper lobe. Because the movement of the upper lobe is restricted by the shape of the thorax, the decrease in the migration distance by the lesion may be a factor that makes evaluation of the adhesion difficult.<sup>[1,9]</sup> One case on the diaphragm had a short horizontal migration distance, so even cases without pleural adhesion may be erroneously evaluated as having adhesion.<sup>[9]</sup> A previous study reported on the evaluation of an adhesion in the aorta, and 2 cases in this study where the tumor was in contact with the aorta were found to be evaluated correctly.<sup>[10]</sup>

## 5. Limitation

This study was useful for investigating the preoperative evaluation of pleural adhesions. However, this study only included a small number of patients, and there were some cases

that could not be evaluated correctly. Therefore, it is necessary to collect and evaluate more cases.

## 6. Conclusion

Using 4D-CT, we were able to effectively evaluate the adhesion of lung tumors preoperatively. 4D-CT is a convenient and useful technique that may provide significant preoperative information for the treatment of lung tumors. Further large-scale prospective studies are needed to assess the relative value of the preoperative information obtained using 4D-CT.

## Author contributions

**Conceptualization:** Kotaro Mizuno.

**Data curation:** Kotaro Mizuno.

**Investigation:** Kotaro Mizuno, Masahiro Muto.

**Software:** Masahiro Muto.

**Writing – original draft:** Kotaro Mizuno.

**Writing – review & editing:** Kotaro Mizuno.

## References

- [1] Yamashiro T, Moriya H, Tsubakimoto M, et al. ACTive Study Group investigators Preoperative assessment of parietal pleural invasion/adhesion of subpleural lung cancer: advantage of software-assisted analysis of 4-dimensional dynamic-ventilation computed tomography. *Eur Radiol* 2019;29:5247–52.
- [2] Choong CK, Pasricha SS, Li X, Briggs P, et al. Dynamic four-dimensional computed tomography for preoperative assessment of lung cancer invasion into adjacent structures. *Eur J Cardiothorac Surg* 2015;47:239–43.
- [3] Hashimoto M, Nagatani Y, Oshio Y, et al. investigators of ACTive study group Preoperative assessment of pleural adhesion by four-dimensional ultra-low-dose computed tomography (4D-ULDCT) with adaptive iterative dose reduction using three-dimensional processing (AIDR-3D). *Eur J Radiol* 2018;98:179–86.
- [4] Akata S, Kajiwara N, Park J, et al. Evaluation of chest wall invasion by lung cancer using respiratory dynamic MRI. *J Med Imaging Radiat Oncol* 2008;52:36–9.
- [5] Kajiwara N, Akata S, Uchida O, et al. Cine MRI enables better therapeutic planning than CT in cases of possible lung cancer chest wall invasion. *Lung Cancer* 2010;69:203–8.
- [6] Mason AC, Miller BH, Krasna MJ, et al. Accuracy of CT for the detection of pleural adhesions: correlation with video-assisted thoracoscopic surgery. *Chest* 1999;115:423–7.
- [7] Fujimoto R, Sato M, Miyata R, et al. Successful resection of recurrent mediastinal liposarcoma using preoperative evaluation of organ invasion by four-dimensional computed tomography. *Gen Thorac Cardiovasc Surg* 2016;64:488–91.
- [8] Suzuki J, Oizumi H, Watarai H, et al. The preoperative assessment of subpleural lung cancer movement to distinguish thoracic wall adhesion or invasion using four-dimensional computed-tomography. *Gen Thorac Cardiovasc Surg* 2019;67:1097–9.
- [9] Sakuma K, Yamashiro T, Moriya H, et al. Parietal pleural invasion/adhesion of subpleural lung cancer: quantitative 4-dimensional CT analysis using dynamic-ventilatory scanning. *Eur J Radiol* 2017;87:36–44.
- [10] Troupis JM, Pasricha SS, Narayanan H, et al. 4D CT and lung cancer surgical resectability: a technical innovation. *J Med Imaging Radiat Oncol* 2014;58:469–71.