



Contents lists available at ScienceDirect

International Journal of Surgery Case Reports

journal homepage: www.casereports.com

Successful adult-to-adult living donor liver transplantation using liver allograft after the resection of hemangioma: A suggestive case for a further expansion of living donor pool



Yasuharu Onishi*, Hideya Kamei, Hisashi Imai, Nobuhiko Kurata, Tomohide Hori, Yasuhiro Ogura

Department of Transplantation Surgery, Nagoya University Hospital, Nagoya, Japan

ARTICLE INFO

Article history:

Received 13 July 2015

Received in revised form

17 September 2015

Accepted 30 September 2015

Available online 8 October 2015

Keywords:

Hemangioma

Liver graft

Adult-to-adult

Living donor

Liver transplantation

Donor pool

ABSTRACT

INTRODUCTION: Hepatic hemangioma is one of the most common benign liver tumors. There are few published reports regarding liver transplantation using liver allografts with hemangioma.

PRESENTATION OF CASE: A 45-year-old man was evaluated as a living donor for 19-year-old son with cirrhosis due to hepatic fibrosis. Preoperative investigations revealed 20 and 7 mm hemangiomas, at segment 2 (S2) and 4 (S4) respectively. Considering the anatomical relation of S2 hemangioma and Glisson 2, liver graft was designed as left lobe excluded S2 hemangioma by partial resection. Estimated graft recipient weight ratio (GRWR) even after partial resection of hemangioma was reasonable. During the donor operation, a partial hepatic resection of S2 hemangioma was performed. Intraoperative pathologic findings revealed a cavernous hemangioma, and then, the left hepatic graft with the caudate lobe was harvested. Actual GRWR was 0.90%. Donor's postoperative course was uneventful. Recipient's postoperative course was almost uneventful. Postoperative computed tomography of the recipient showed the graft regeneration without increase or recurrence of hemangioma.

DISCUSSION: Organ shortage is a major concern in the field of liver transplantation. A novel donor source with a further option is extremely crucial for a guarantee of liver transplantation. We experienced the first case of adult-to-adult living donor liver transplantation using liver allograft after the resection of hemangioma.

CONCLUSION: We advocate that the use of liver allograft with hemangiomas in adult-to-adult LDLT settings can be remarkable strategy to reduce the problem of organ shortage without any unfavorable consequences in both living donor and recipient.

© 2015 The Authors. Published by Elsevier Ltd. on behalf of Surgical Associates Ltd. This is an open access article under the CC BY-NC-ND license (<http://creativecommons.org/licenses/by-nc-nd/4.0/>).

1. Introduction

Because the usage of extended criteria for donation of liver transplantation has been needed due to donor organ scarcity for transplantation [1], liver grafts from marginal donors including liver with benign tumors have been accepted as treatment options. Hepatic hemangioma is one of the most common benign tumors of the liver, as described up to 7% in autopsy findings [2].

The hemangioma usually remains asymptomatic [3] and has a benign course [4–6], although symptomatic hemangiomas may rarely require either interventional or surgical treatment [7–9].

Abbreviations: LDLT, living donor liver transplantation; GRWR, graft recipient weight ratio; POD, post-operative day; GV/SLV, graft liver volume to standard liver volume.

* Corresponding author at: 65 Tsurumai-cho, Showa-ku, Nagoya 466-8550, Japan. Fax: +81 52 744 2293.

E-mail address: onishiy@med.nagoya-u.ac.jp (Y. Onishi).

<http://dx.doi.org/10.1016/j.ijscr.2015.09.043>

2210-2612/© 2015 The Authors. Published by Elsevier Ltd. on behalf of Surgical Associates Ltd. This is an open access article under the CC BY-NC-ND license (<http://creativecommons.org/licenses/by-nc-nd/4.0/>).

There are few published reports regarding liver transplantation using liver allografts with hemangiomas [10–16]. In not only deceased donor liver transplantation but also living donor liver transplantation (LDLT), liver allografts with hemangiomas have been utilized for transplantation. However, in LDLT setting, there are only two published reports about liver allografts with hemangioma, and they were both liver transplants for pediatric recipients [12,15]. Until now, there has been no report in adult-to-adult LDLT with liver grafts with hemangioma.

We present here the first report of successful adult-to-adult LDLT using liver allograft with hemangioma.

2. Presentation of case

A 19-year-old male was admitted with liver failure due to congenital hepatic fibrosis. A prior diagnosis of congenital hepatic fibrosis had been established by gastroenterologists before 13 years. His liver function deteriorated progressively, with the

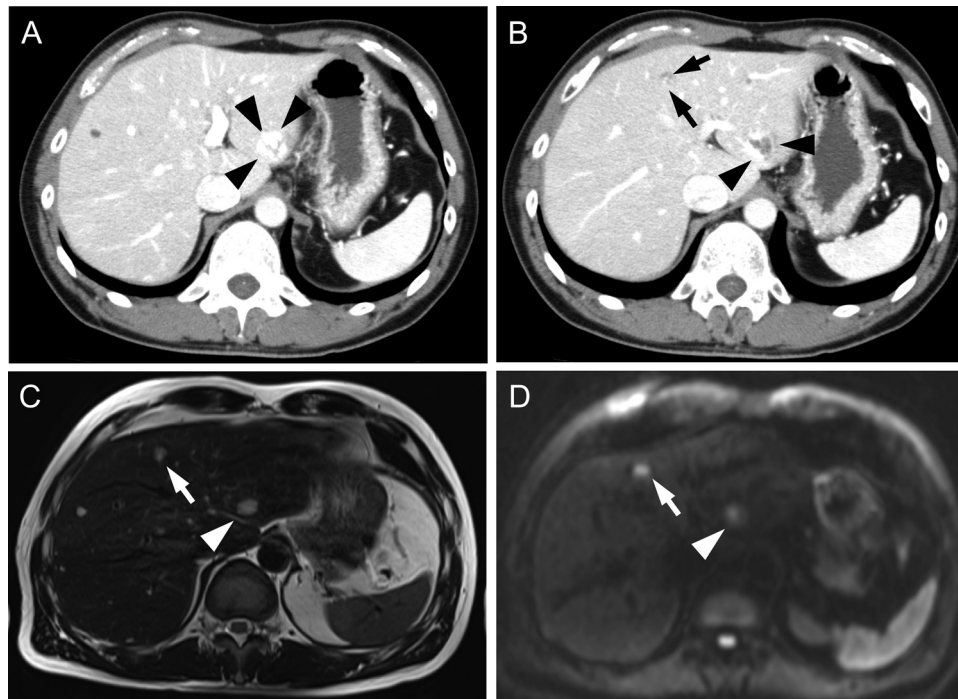


Fig. 1. Preoperative contrast-enhanced abdominal computed tomography (A, B) and magnetic resonance imaging (C, D) of the donor liver with cavernous hemangiomas. S2 hemangioma was indicated by arrowheads, and S4 hemangioma was indicated by arrows.

following laboratory findings: serum total bilirubin 25.2 mg/dl, prothrombin time-international normalized ratio 1.78, aspartate aminotransferase 119 IU/l, and alanine aminotransferase 71 IU/l. No rupture of esophageal and gastric varices was seen. However, he had some critical episodes of grade 2 hepatic encephalopathy, and intensive cares including plasma exchange was seriously required. The preoperative liver profile was evaluated as Child-Pugh classification of grade C (11 points) and an MELD (Model for End Stage Liver Disease) score of 34 points.

A 45-year-old male was evaluated as a living donor for his son. The liver function tests of the donor were totally within the normal range with no evidence of any coagulopathy. Donor preoperative computed tomography and magnetic resonance imaging revealed 20 mm and 7 mm hemangiomas, at segment 2 (S2) and 4 respectively (Fig. 1). Estimated left lobe volume with the caudate was 503 ml. Considering the anatomical relationship of S2 hemangioma and Glisson 2, liver graft was designed as the left lobe graft with caudate lobe excluded S2 hemangioma by partial resection (Fig. 2). Estimated graft volume after hemangioma partial resection was 482 ml, which accounted for 0.83% of graft recipient weight ratio (GRWR).

Thus, the recipient status was an end-stage liver disease (i.e., advanced liver cirrhosis), and this donor was only a candidate for this recipient. After an approval of institutional ethical committee, we scheduled LDLT for this case.

A LDLT donor and recipient procedure was performed as described elsewhere [17,18]. At the beginning of living donor operation, in vivo partial hepatic resection of the S2 hemangioma was performed without the Pringle maneuver. Intraoperative ultrasonography was used to identify the location of S2 hemangioma and Glisson 2 to avoid the injury to Glisson 2 structures (Fig. 3A). The resected specimen from the donor liver was confirmed to be a cavernous hemangioma by an intraoperative pathologic examination, and then, the left hepatic graft with caudate lobe was harvested. The donor operation time was 521 min, and the bleeding volume of the donor operation was 1250 ml, but most of the bleeding occurred

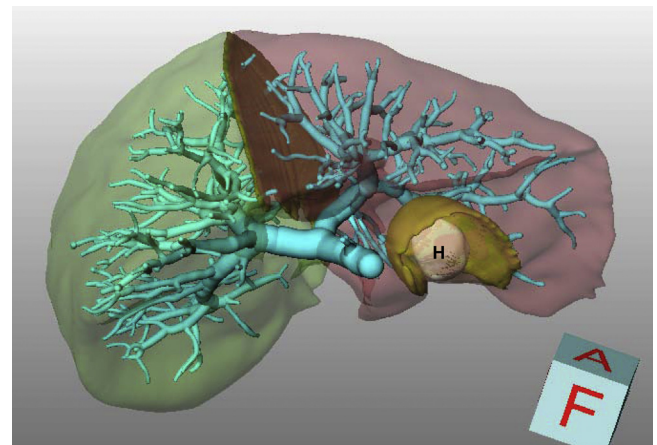


Fig. 2. The 3D-image simulation. Hemangioma was shown in H, with partial resection margin.

after the resection of the hemangioma. The actual liver graft weight was 504 g, and resulting in an actual GRWR of 0.90%.

The recipient operation was performed with standard procedures. At the time of reperfusion, no bleeding was observed from the resection site of S2 hemangioma (Fig. 3B). Splenectomy was added in this case, because of the existence of splenic artery aneurysm. Recipient operation time was 632 min, and blood loss was 5320 ml.

The donor's postoperative course was almost uneventful, and he was discharged from the hospital on the post-operative day (POD) 12. The recipient was discharged from the hospital on POD 31 without subsequent liver necrosis or bile leakage from the resection site of S2 hemangioma. However, on POD 39, the recipient was readmitted to the hospital because of the intra-abdominal bleeding, and urgent operation was performed for hemostasis. The cause of bleeding was gastric varix rupture close to splenectomy site, and there was no bleeding sign from the resection site of S2 heman-

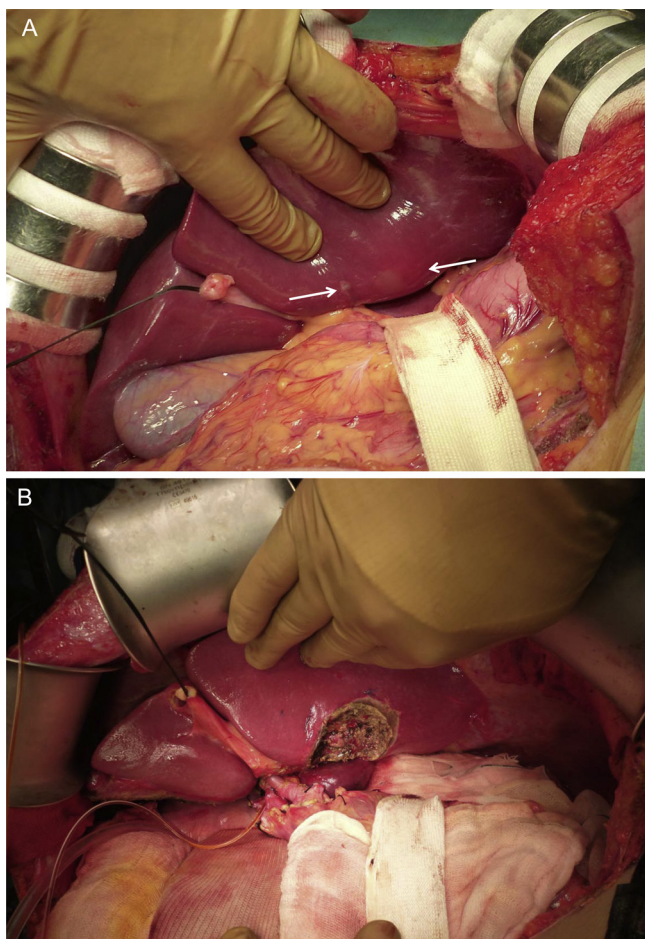


Fig. 3. (A) Donor operation. Ultrasound sonogram was used to confirm the location of S2 hemangioma and Glisson 2. Location of hemangioma was indicated by white arrows. (B) Final view of recipient operation. Note no Glisson 2 injured after partial resection of hemangioma.

gioma. He was discharged from hospital 8 weeks after the second operation with good general condition and liver graft function. He is currently doing well 2 years after the LDLT. Also, the recipient’s CT scans on the post-operative 132 days and 19 months showed that the good regeneration of the liver graft without any recurrence or growth of hemangioma (Fig. 4).

3. Discussion

Although liver transplantation has been widely performed for end-stage liver failure, organ shortage is the greatest problem facing the field of organ transplantation today. Therefore, the usage of extended criteria donors for organ transplantation has become a necessity due to donor organ scarcity for transplantation [1]. Actually, the use of marginal or expanded pool donors was shown to have outcome similar to ideal liver graft [19]. In renal transplantation, Khurram et al. reported that use of kidneys after tumor resection seems a feasible source to increase the donor pool [20]. Thus, it is extremely important to try to use a novel donor source as a further option to increase the number of patients who might be able to receive a liver transplantation as well as kidney transplantation.

Hepatic hemangioma is one of the most common hepatic tumors. The Mayo Clinic team suggested that most liver hemangioma could be observed safely [4], and Farges et al. confirmed the statement [5]. However, there are few published reports regarding liver transplantation using liver allografts with hemangioma so far.

Table 1
Review of the documented reports of liver allografts with hemangioma.

Case no.	Year	Author	Reference	Deceased/living donor	Donor age	Recipient age	Hemangioma	Location	Resection	Size after transplantation
1	1995	Mor et al.	[10]	Deceased	54	30	10 × 10 × 8 cm	Posterior segment	Done at backtable	Unknown
2	2005	Onaca et al.	[11]	Deceased	65	59	9 cm, 3 cm	Right lobe, left lobe	Done at backtable	No recurrence
3	2005	Pacheco-Moreira et al.	[12]	Living	32	4	4.2 cm	Lateral segment	No	Unknown
4	2006	Aucejo et al.	[13]	Deceased	65	53	10 × 8 × 9	Right lobe	No	Reduction
5	2007	Nikeghbalian et al.	[14]	Deceased	36	37	20% of whole liver	Right lobe	No	Reduction
6	2011	Sanada et al.	[15]	Living	27	2	2 cm	Lateral segment	Done in operation	No recurrence
7	2013	Sun et al.	[16]	Living (otherwise discarded)	41	27	7.8 cm	Left lobe	No	No change
Our case	2015	Onishi et al.		Living	45	19	2 cm, 0.7 cm	S2, S4	Done in operation, no	No recurrence, no change

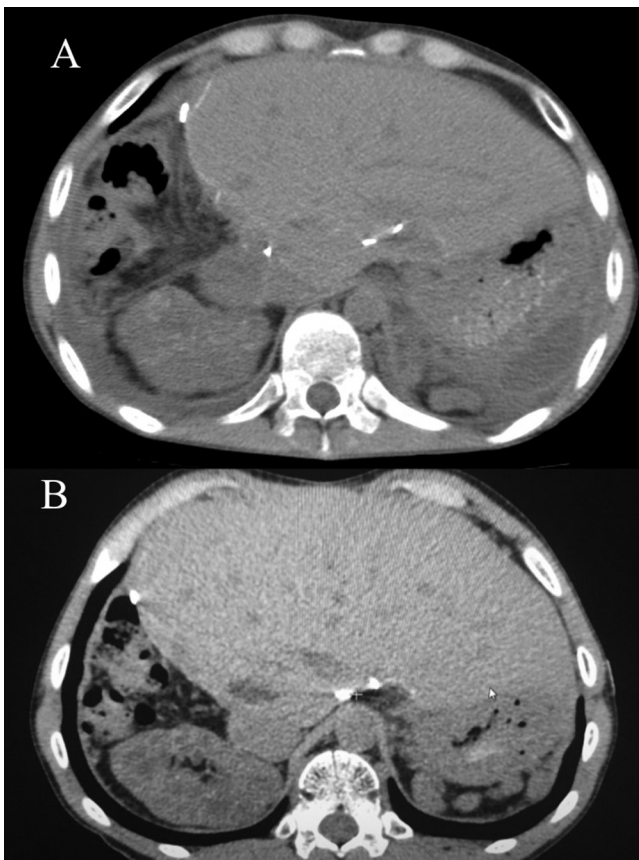


Fig. 4. Post-operative CT findings in the recipient. The CT findings at 132 days (A) and at 19 months (B) were shown.

As shown in Table 1, seven cases of donor livers with hemangiomas have been reported previously [10–16]. There are only two reports of left lateral segment from a living donor containing hemangioma transplanted to pediatric patients but not to adult patients [12,15]. While Sun et al. indicated adult-to-adult liver transplantation of an otherwise discarded partial liver allograft with a cavernous hemangioma [16], there has been no report about adult-to-adult LDLT using liver allograft with a cavernous hemangioma. To our knowledge, this is the first case demonstrating adult-to-adult liver transplantation using left hepatic lobe graft with caudate lobe after the resection of hemangioma from a living donor.

Sanada et al. have proposed a strategy for the usage of liver allograft with hemangiomas in pediatric LDLT settings [15]. They proposed that the resection of hemangiomas depends on the tumor location, the estimated graft liver volume to standard liver volume (GV/SLV) ratio after the tumor resection, and the tumor size. Hemangiomas at a peripheral location and the estimated GV/SLV ratio of 40% and more after the tumor resection are considered to be an indication of surgical resection. Similar to their proposal, we resected the 20 mm hemangioma of S2, because the hemangioma was relatively larger at peripheral site, and the estimated GRWR, which we use instead of GV/SLV ratio, after the resection of S2 hemangioma was 0.83%. On the other hand, smaller 7 mm hemangioma at S4 was not resected because the location was relatively central and the size was smaller. The size and feature of the hemangioma in the transplanted liver should be strictly followed, because detailed long-termed analysis of liver allograft with hemangioma has not been performed and a possibility of symptomatic changes may remain.

Technically speaking, in order to resect the hemangioma, there are two surgical procedures, backtable resection [10,11] or in vivo resection in the donor surgery [15]. We chose in vivo resection during the donor operation, because we believe that in vivo procedure contains the easier anatomical resection of the tumor and the shorter cold ischemic time than backtable resection.

4. Conclusions

Our case is the first report of adult-to-adult transplantation using a living donor liver graft after the resection of hemangioma. Based on our experience, donor liver with hemangioma can be safely used even for adult-to-adult LDLT, while the follow-up is needed in case of the hemangioma remained in the transplanted liver. We advocate that liver allografts with hemangiomas should not be considered as a contraindication for adult-to-adult LDLT, and can be accepted as a potential liver allograft.

Conflict of interest

No financial conflicts of interest.

Funding

All authors did not receive any funding for this report.

Ethical approval

This case report is written based on institutional ethical committee.

Consent

Written informed consent was obtained from the patient for publication of this Case report and any accompanying images. A copy of the written consent is available for review by the Editor-in-Chief of this journal.

Author contributions

Yasuharu Onishi contributed reports retrieval and drafting of this manuscript. Yasuharu Onishi, Hideya Kamei and Yasuhiro Ogura contributed surgical procedures of this case report. Hisashi Imai and Nobuhiko Kurata contributed acquisition of clinical data. Tomohide Hori contributed critical revision of this manuscript. Yasuhiro Ogura supervised this report. All authors read and approved the final manuscript.

Guarantor

The guarantor of this manuscript is Yasuharu Onishi, corresponding author.

References

- [1] E. Mor, G.B. Klintmalm, T.A. Gonwa, H. Solomon, M.J. Holman, J.F. Gibbs, I. Watemberg, R.M. Goldstein, B.S. Husberg, The use of marginal donors for liver transplantation. A retrospective study of 365 liver donors, *Transplantation* 53 (1992) 383–386.
- [2] C.K. Charny, W.R. Jarnagin, L.H. Schwartz, H.S. Frommeyer, R.P. DeMatteo, Y. Fong, L.H. Blumgart, Management of 155 patients with benign liver tumours, *Br. J. Surg.* 88 (2001) 808–813.
- [3] P.A. Vagefi, I. Klein, B. Gelb, B. Hameed, S.L. Moff, J.P. Simko, O.K. Fix, H. Eilers, J.R. Feiner, N.L. Ascher, C.E. Freise, N.M. Bass, Emergent orthotopic liver transplantation for hemorrhage from a giant cavernous hepatic hemangioma: case report and review, *J. Gastrointest. Surg.* 15 (2011) 209–214.
- [4] V.F. Trastek, J.A. van Heerden, P.F. Sheedy 2nd, M.A. Adson, Cavernous hemangiomas of the liver: resect or observe? *Am. J. Surg.* 145 (1983) 49–53.

- [5] O. Farges, S. Daradkeh, H. Bismuth, Cavernous hemangiomas of the liver: are there any indications for resection, *World J. Surg.* 19 (1995) 19–24.
- [6] S.S. Yoon, C.K. Charny, Y. Fong, W.R. Jarnagin, L.H. Schwartz, L.H. Blumgart, R.P. DeMatteo, Diagnosis, management, and outcomes of 115 patients with hepatic hemangioma, *J. Am. Coll. Surg.* 197 (2003) 392–402.
- [7] M. Birth, J. Ortlepp, S. Bontikous, M. Amthor, H.F. Weiser, H.P. Bruch, Intermittent activity-induced hemobilia caused by liver hemangioma, *Dig. Surg.* 17 (2000) 292–296.
- [8] N. Corigliano, P. Mercantini, P.M. Amodio, G. Balducci, S. Caterino, G. Ramacciato, V. Ziparo, Hemoperitoneum from a spontaneous rupture of a giant hemangioma of the liver: report of a case, *Surg. Today* 33 (2003) 459–463.
- [9] Y. Kumashiro, M. Kasahara, K. Nomoto, M. Kawai, K. Sasaki, T. Kiuchi, K. Tanaka, Living donor liver transplantation for giant hepatic hemangioma with Kasabach–Merritt syndrome with a posterior segment graft, *Liver Transpl.* 8 (2002) 721–724.
- [10] E. Mor, P. Boccagni, S.N. Thung, P.A. Sheiner, S. Emre, S.R. Guy, M.E. Schwartz, C.M. Miller, Backtable resection of a giant cavernous hemangioma in a donor liver, *Transplantation* 60 (1995) 616–617.
- [11] N. Onaca, S. Mizrahi, N. Bar Nathan, I. Burstein, E. Mor, Liver transplantation after backtable resection of giant hemangioma, *Liver Transpl.* 11 (2005) 851–852.
- [12] L.F. Pacheco-Moreira, M. Enne, E. Balbi, G. Santalucia, J.M. Martinho, Hemangioma at the liver section plane. Is it a contraindication for living donor liver transplantation? *Surgery* 138 (2005) 113.
- [13] F.N. Aucejo, W.A. Ortiz, D. Kelly, D.C. Winans, D. Vogt, B. Egtesad, J.J. Fung, C.M. Miller, Expanding the donor pool: safe transplantation of a cadaveric liver allograft with a 10 cm cavernous hemangioma—a case report, *Liver Transpl.* 12 (2006) 687–689.
- [14] S. Nikeghbalian, K. Kazemi, H. Salahi, A. Bahador, H.R. Davari, H. Jalaeian, A.R. Rasekhi, S.M. Nejatollahi, S. Gholami, S.A. Malek-Hosseini, Transplantation of a cadaveric liver allograft with right lobe cavernous hemangioma, without back-table resection: a case report, *Transplant. Proc.* 39 (2007) 1691–1692.
- [15] Y. Sanada, K. Mizuta, T. Urahashi, M. Umehara, T. Wakiya, N. Okada, S. Egami, S. Hishikawa, T. Fujiwara, Y. Sakuma, M. Hyodo, Y. Yasuda, Pediatric living donor liver transplantation using liver allograft with hemangioma, *Ann. Transplant.* 16 (2011) 66–69.
- [16] B. Sun, X. Mu, X. Wang, Successful adult-to-adult liver transplantation of an otherwise discarded partial liver allograft with a cavernous hemangioma: new strategy for expanding liver donor pool, *Transpl. Int.* 26 (2013) e79–e80.
- [17] K. Tanaka, S. Uemoto, Y. Tokunaga, S. Fujita, K. Sano, T. Nishizawa, H. Sawada, I. Shirahase, H.J. Kim, Y. Yamaoka, Surgical techniques and innovations in living related liver transplantation, *Ann. Surg.* 217 (1993) 82–91.
- [18] Y. Soejima, M. Shimada, T. Suehiro, K. Kishikawa, R. Minagawa, S. Hiroshige, M. Ninomiya, S. Shiotani, N. Harada, K. Sugimachi, Feasibility of duct-to-duct biliary reconstruction in left-lobe adult-living-donor liver transplantation, *Transplantation* 75 (2003) 557–559.
- [19] N. Goldaracena, E. Quinonez, P. Mendez, M. Anders, F. Orozco Ganem, R. Mastai, L. McCormack, Extremely marginal liver grafts from deceased donors have outcome similar to ideal grafts, *Transplant. Proc.* 44 (2012) 2219–2222.
- [20] M.A. Khurram, A.O. Sanni, D. Rix, D. Talbot, Renal transplantation with kidneys affected by tumours, *Int. J. Nephrol.* 529080 (2011).

Open Access

This article is published Open Access at sciedirect.com. It is distributed under the [IJSCR Supplemental terms and conditions](#), which permits unrestricted non commercial use, distribution, and reproduction in any medium, provided the original authors and source are credited.