



## Ophthalmic artery occlusion after glabellar hyaluronic acid filler injection

Petra Davidova, Michael Müller, Yaroslava Wenner, Clara König, Ninel Kenikstul, Thomas Kohnen\*

Department of Ophthalmology, Goethe-University, Theodor-Stern-Kai 7, D-60590, Frankfurt Am Main, Frankfurt, Germany

### ARTICLE INFO

#### Keywords:

Filler  
Glabella  
Blindness  
Ophthalmoplegia  
Arteria ophthalmica  
Occlusion

### ABSTRACT

**Purpose:** Filler injections for aesthetic purposes are very popular, but can have far-reaching and irreversible consequences. This report describes the course of a patient with devastating complications after glabellar hyaluronic acid injection, their pathomechanism, management and outcome.

**Observations:** A healthy, 43-year-old woman underwent her first hyaluronic acid injection in the glabella and went blind on her left eye immediately thereafter. Massaging of the injection area and observation were performed, before she presented with swelling of the left forehead and upper lid, ptosis, complete ophthalmoplegia and blindness in our hospital. Immediate massaging of the globe and systemic therapy including acetylsalicylic acid, tinzaparin sodium and cortisone was initiated and hyaluronidase injections in the injection area were performed. In the further course, the patient developed necrotic and hemorrhagic skin and mucosal lesions, lagophthalmos, anterior and posterior segment ischemia and globe hypotonia with consecutive globe deformation. In the follow-up of 2.5 months, lid swelling, lagophthalmos and ptosis resolved and keratopathy improved but blindness, skin lesions and strabismus with reduced eye motility were still present and madarosis and early enophthalmos were detected.

**Conclusions and Importance:** The outcome of ophthalmic artery occlusion after hyaluronic acid filler injection is poor. Sufficient knowledge about facial anatomy, the implementation of filler injections and the management of complications is essential for the practitioner. The patient should be clarified about potential and even rare risks of these procedures.

### 1. Introduction

Minimally invasive facial aesthetic interventions, especially filler injections, gained popularity in recent years.<sup>1</sup> Since the number of patients treated with these procedures increases, the range of reported complications increases, too.

In general, the fillers can cause minor adverse events like bruising, swelling or infection,<sup>1,2</sup> but ophthalmic complications, including blindness, were also reported. The rate of these is extremely low,<sup>1,2</sup> but devastating for the patient. This case report illustrates fatal complications, their course, pathomechanism, management and outcome after hyaluronic acid filler injection in the glabella in a healthy woman.

### 2. Case report

A 43-year-old Caucasian female healthy patient underwent glabellar injection of 0.7 mL hyaluronic acid/lidocaine (Restylane®) by a

nonmedical practitioner. It was the patient's first filler injection, her former visual acuity was 20/20 on both eyes and no other diseases, including of the eyes, were present before the procedure. According to the patient, the visual field of her left eye already darkened during the procedure and massaging of the injection area with observation was performed, before she presented to our hospital 1 h later.

Swelling of the left forehead and upper lid, ptosis and complete ophthalmoplegia were detectable. The left eye had no light perception, the intraocular pressure was normal, the left pupil barely reacted to light and showed a relative afferent pupillary defect. The anterior segment did not show further pathological findings. In the funduscopy, the optic disc presented with sharp margins, the arteries were thinned, cherry red spot and retinal whitening were documented. Immediate massaging of the globe was attempted and further neurological diagnostic, including nuclear magnetic resonance imaging, was performed. Besides the ophthalmic pathologies, the neurological clinical findings were normal and in the medical imaging an ischemic optic neuropathy was suspected.

\* Corresponding author.

E-mail address: [kohnen@em.uni-frankfurt.de](mailto:kohnen@em.uni-frankfurt.de) (T. Kohnen).

<https://doi.org/10.1016/j.ajoc.2022.101407>

Received 25 November 2021; Received in revised form 29 January 2022; Accepted 7 February 2022

Available online 11 February 2022

2451-9936/© 2022 Published by Elsevier Inc. This is an open access article under the CC BY-NC-ND license (<http://creativecommons.org/licenses/by-nc-nd/4.0/>).

Therapy with acetylsalicylic acid, tinzaparin sodium, methylprednisolone, pantoprazole, pain management and antiseptic compresses for the forehead was initiated. The detailed dosage and further therapy adjustments are listed in Table 1. The dermatologists performed three hyaluronidase injections in the injection area. Two days after the glabellar hyaluronic acid injection, the periocular complications were still manifest with hemorrhagic changes on the upper lid (Fig. 1). The patient also developed skin lesions on the nose bridge, anterior segment ischemia and globe hypotonia. The conjunctiva was injected, the cornea had erosion, edema and Descemet folds, the pupil was average sized, ovally warped, showing no light reaction. A perforation was ruled out. In the next two days, the skin on the forehead and the inner third of the upper lid showed early necrotic changes, the vertical lid fissure width was 9 mm, levator function 5 mm and a lagophthalmos of 3 mm was visible. Exophthalmometry was symmetrical and eye movement could be achieved approximately 5° downwards. The conjunctiva showed chemosis, keratopathy worsened and anterior chamber flattened to mid depth (Fig. 2). A sonography revealed globe deformation and swelling of the choroidea. Due to the strong suspicion of an ophthalmic artery occlusion the otolaryngologists were involved in this case and found necrotic mucosal tissue at the top of the left middle nasal concha. The cranial nuclear magnetic resonance imaging was repeated, revealing a collapsed globe (Fig. 3) and edematous left optic nerve with diffusion restriction. In the angiography, an ophthalmic artery occlusion could not be confirmed or ruled out with certainty.

Ten days after the injection complete lid closure could be achieved, depression, elevation and abduction improved slightly, corneal erosion decreased, no iridal ischemic signs were detected, the lens had little lentodonesis and the sonographic findings were constant. Two and a half weeks after the hyaluronic acid injection, lid swelling and ptosis resolved completely, showing a symmetrical lid fissure width of 10 mm and normal levator function. Amaurosis and severe globe hypotonia

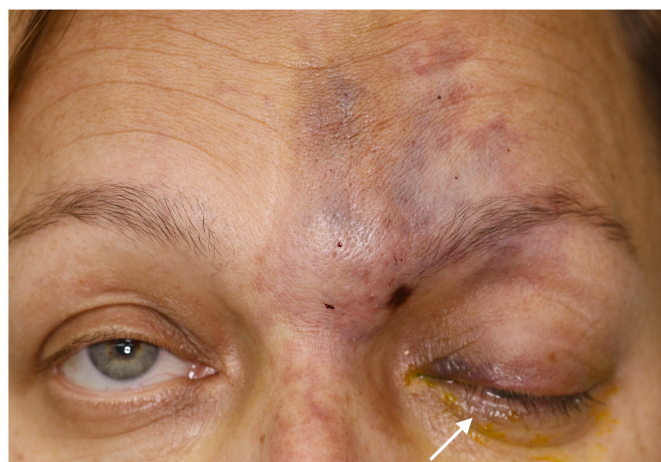


Fig. 1. Upper face region two days after ophthalmic artery occlusion after hyaluronic acid filler injection. There is swelling, redness and surface irregularity on the left side of the forehead, nose and left upper lid and distinct ptosis. The left eye is slightly depressed (arrow) while the right eye slightly elevated, indicating ophthalmoplegia.

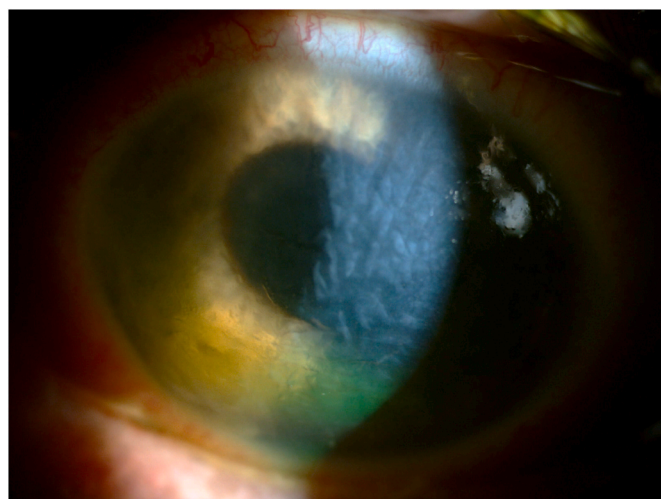


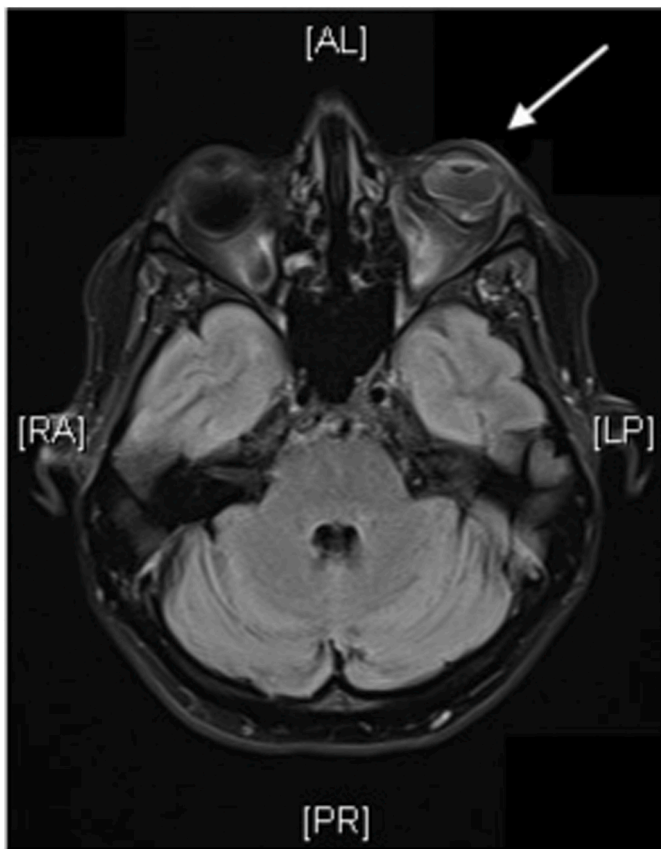
Fig. 2. Left eye with anterior segment ischemia, one week after ophthalmic artery occlusion after hyaluronic acid filler injection. The conjunctiva is injected and shows chemosis, the cornea is edematous and has Descemet folds. The anterior chamber has mid depth, the pupil is warped in nasal superior direction, average sized and the lens is clear.

Table 1  
Therapy adjustments in the course of filler induced ophthalmic artery occlusion.

Timeline after hyaluronic acid filler injection	Therapy adjustment
1 hour	acetylsalicylic acid 100 mg (s.i.d, per os) tinzaparin sodium 4.500 IE (s.i.d, subcutaneous) methylprednisolone 100 mg (s.i.d., intravenous for three days, then prednisone 90 mg per os) pantoprazole 40 mg (s.i.d, per os, during steroid medication)
2 days	dexpanthenol 5% eye ointment added (q.i.d.) ofloxacin 3mg/g eye ointment added (q.i.d.)
4 days	dexpanthenol 5% eye ointment increased (q2h) moisture chamber added (during lagophthalmos) clindamycin 300 mg added (q.i.d, per os, added by dermatologists) nasal spray containing sea water and dexpanthenol added
6 days	prednisolone 10 mg/ml eye drops added (t.i.d) atropine 0.5% eye drops added (b.i.d) prednisone reduced to 60 mg (s.i.d, per os)
10 days	dexpanthenol 5% eye ointment reduced (6 times daily) prednisolone 10 mg/ml eye drops reduced (b.i.d) atropine 0.5% eye drops reduced (s.i.d) prednisone reduced to 50 mg (s.i.d, per os, further reduction of 10 mg every three days, remaining on 10 mg) clindamycin 300 mg discontinued
2.5 weeks	ofloxacin 3mg/g eye ointment reduced (t.i.d) tinzaparin sodium 4.500 IE discontinued
6 weeks	prednisone reduced to 5 mg (s.i.d, per os, for two weeks, then discontinuation) prednisolone 10 mg/ml eye drops reduced (s.i.d) atropine 0.5% eye drops discontinued ofloxacin 3 mg/ml eye ointment discontinued
2.5 months	acetylsalicylic acid 100 mg discontinued prednisolone 10 mg/ml eye drops replaced with dexamethasone 1 mg/ml eye drops (s.i.d, without preservatives)

were still manifest. The conjunctiva was sparsely injected, the cornea was clear, stippled, without corneal erosion. Compared to the former medical findings, the anterior chamber deepened. The optic nerve was pale with indistinct margins, the retinal arteries were very thin and the retina was ischemic and edematous. No cherry red spot was visible and, in the sonography, the globe was still deformed.

A further control examination after 6 weeks revealed redness and surface irregularity on the forehead and madarosis on the inner third of the upper lid. Abduction of 25°, complete elevation, depression of 15° and terminally restricted adduction with strabismus showing esotropia and hypertropia was visible. In the exophthalmometry a 2 mm more posterior location of the affected eye was detected. The visual acuity kept unchanged, the globe started to build up intraocular pressure, the anterior chamber further deepened, mild hyperemia of the iris was detectable, the pupil was still warped, developing posterior synechiae in the inferior nasal quadrant (Fig. 4). The funduscopy showed partially a slightly increased retinal vein caliber with tortuosity and very poor to no

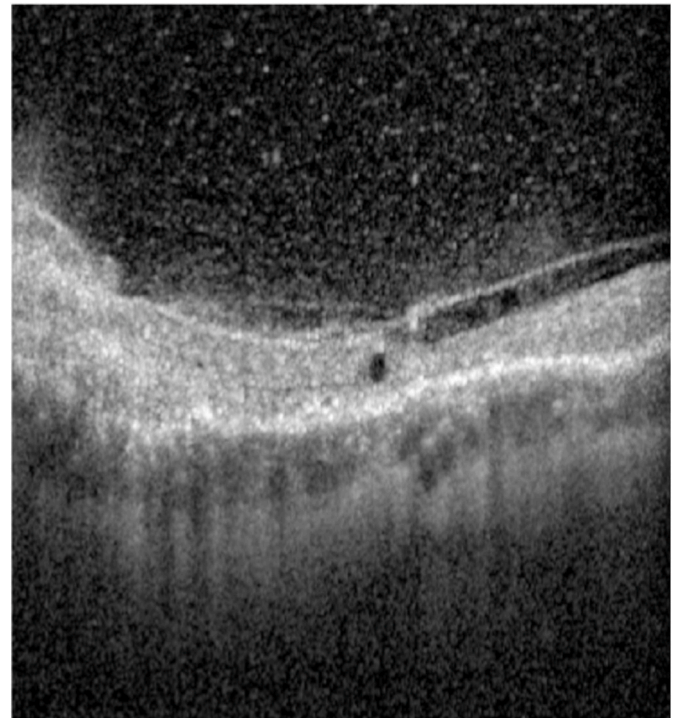


**Fig. 3.** Magnetic resonance brain imaging (T2 sequence, TIRM, dark-fluid, transverse section) 9 days after ophthalmic artery occlusion after hyaluronic acid filler injection. The extent of the deformed, collapsed left globe (arrow) gets obvious. Signal enhancement in the left orbit is detectable, indicating increased liquid content.

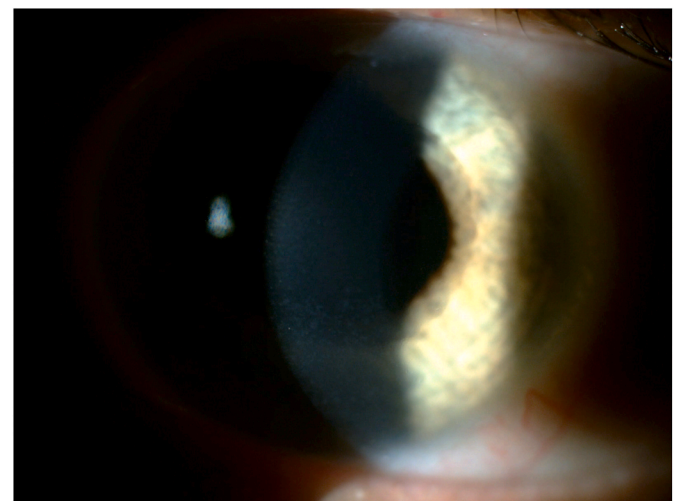
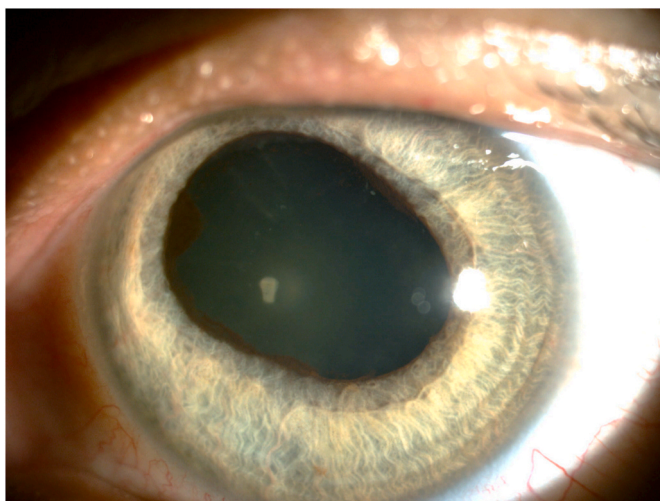
retinal artery filling with ischemic retinal areas. The OCT revealed internal and external retinal atrophy with loss of retinal architecture (Fig. 5). 2.5 months after the incident the clinical findings remained constant (Fig. 6).

### 3. Discussion

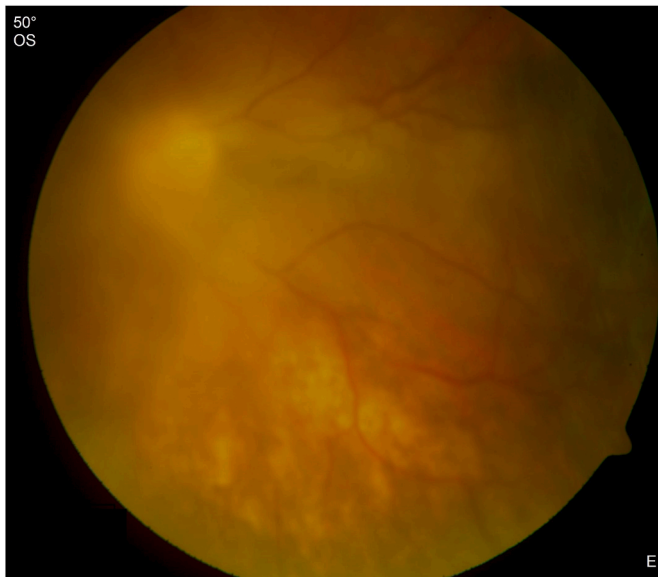
It was summarized, that the most frequent pattern of vascular involvement after hyaluronic acid injection associated vision loss was ophthalmic artery occlusion. Other occlusion types affect the central retinal artery, branch retinal artery, posterior ciliary artery or lead to anterior respectively posterior ischemic optic neuropathy or to combinations of these.<sup>1</sup> No vision loss after hyaluronic acid fillers was documented from lower face regions like lip, chin or jawline, but forehead, glabella, nose and nasolabial folds are high-risk zones for vascular



**Fig. 5.** OCT of the left eye 6 weeks after ophthalmic artery occlusion after hyaluronic acid filler injection. Atrophy of inner and outer retinal layers with loss of architecture and thickened posterior vitreous membrane with partial detachment of the vitreous body.



**Fig. 4.** a) Left eye 6 weeks after ophthalmic artery occlusion after hyaluronic acid filler injection with madarosis on the inner third of the upper lid. The conjunctiva is sparsely injected, the cornea is clear, mild hyperemia of the iris, the pupil warped in nasal superior direction, average sized (under atropine medication) developing posterior synechiae in the inferior nasal quadrant and the lens is clear.  
b) The cornea is stippled, clear and shows no Descemet folds. The anterior chamber deepened.



**Fig. 6.** Fundus of the left eye, 2.5 months after ophthalmic artery occlusion. The optic nerve is pale with indistinct margins, very poor to no retinal artery filling, partially slightly increased retinal vein caliber, no cherry red spot and ischemic areas are detectable. (For interpretation of the references to colour in this figure legend, the reader is referred to the Web version of this article.)

occlusion of branches of the ophthalmic artery.<sup>1</sup> A study analyzing different fillers even reported that the glabella area was the most common injection site leading to this complication.<sup>2</sup> The pathomechanism can be explained by the anatomical proximity of the supratrochlear artery and the glabella. The supratrochlear artery is a terminal branch of the ophthalmic artery and due to its superomedial location at the orbit and extensive vascular anastomoses on the forehead, it can be unintentionally injected<sup>3</sup> or the injection needle may break its wall.<sup>4</sup> An adequate amount of product in combination with the injection force, which can overcome the systolic arterial pressure, can press the droplet towards the ophthalmic artery and lead to retrograde occlusion<sup>1,2,4</sup> and consecutive anterograde multifocal obstruction at the end of the injection, when the pressure gradient changes and the arterial systolic pressure pushes the droplets anterogradely.<sup>2,4</sup> Injection volumes of <0.1 ml can fill the entire volume of the supratrochlear artery from injection site at the glabella to the level of the orbital apex<sup>3</sup> and it was reported that 0.2 ml and 0.4 ml of injected hyaluronic acid could already cause permanent and complete vision loss.<sup>1</sup> In our case, the injection of 0.7 ml of hyaluronic acid into the supratrochlear artery resulted in occlusion of the ophthalmic artery and its branches.

In our patient, skin lesions were still present after 2.5 months. Others reported skin lesions after ophthalmic artery occlusion even after a mean follow-up of 14.4 months<sup>2</sup> or even scarring.<sup>1</sup> Periocular manifestations like ptosis, ophthalmoplegia or strabismus are common complications of filler associated vascular obstruction.<sup>1,2</sup> It was stated that ocular movement was weakened in every direction, which is in accordance with our patient's findings.<sup>5</sup> Some reported normal levator function and extraocular muscle tone six months after vascular obstruction,<sup>5</sup> others reported strabismus in 56% of the ophthalmic artery obstruction cases after a mean follow-up of 14.4 months.<sup>2</sup> In our patient normal levator function, completely recovered ptosis and better, but still reduced, eye movement and strabismus were present after 2.5 months. Further reported complications of ophthalmic artery occlusion were anterior segment ischemia, as was found in our patient, iris atrophy and phthisis bulbi on the long term.<sup>2</sup> After 2.5 months, irregular widened pupil without iris atrophy or iris ischemia but mild hyperemia of the iris were obvious in our case. We found an early enophthalmos of the affected eye, which was also reported from another group after 6

months of follow-up.<sup>5</sup> A phthisis bulbi or even enucleation in the further course cannot be excluded. Further known complications like brain infarcts or hemorrhage<sup>1,2</sup> were ruled out in our patient.

It was summarized that visual improvement was documented in cases when “only” partial, compared to complete, vision loss occurred. But in cases with ophthalmic artery occlusion or central retinal artery obstruction, no partial vision loss or recovery was reported.<sup>1</sup> Intra-arterial hyaluronidase, retrobulbar hyaluronidase, subcutaneous hyaluronidase or subtenon hyaluronidase were injected without success in cases with complete vision loss.<sup>1</sup> Others treated patients with different vascular involvements with observation, anterior chamber paracentesis, intra-arterial thrombolysis, anticoagulant, corticosteroid therapy or intraocular pressure-lowering agents. In all patients with ophthalmic artery occlusion no light perception at the initial visit and after a mean follow-up of 14.4 months was reported.<sup>2</sup> In our case, the immediate therapy consisted of acetylsalicylic acid, tinzaparin sodium, corticosteroids and observation. Regarding the lack of thrombotic cause of the occlusion, no intra-arterial thrombolysis was recommended. Due to extensive ischemic retinal and neuropathic changes already at time of presentation, the lack of benefit according to literature and to minimize further, possible complications, no hyaluronidase injections, except on the forehead, were performed since visual rehabilitation was not to be expected.

In the angiography an ophthalmic artery occlusion could not be ascertained or ruled out. But the subsequent complications can be attributed to the branches of the ophthalmic artery, bearing in mind interindividual differences and anastomoses, and were also described in other studies as mentioned above. Further findings like the missing cherry rot spot due to retinal and choroidal insufficiency, extensive, whiteish, edematous retinal ischemia, poor or no retinal artery filling and disc edema<sup>2,6</sup> are seen in ophthalmic artery occlusion. Due to the restricted treatment possibilities and very poor outcome<sup>1,2</sup> the further course remains to be seen.

#### 4. Conclusion

The outcome of ophthalmic artery occlusion following glabellar hyaluronic acid filler injection is very poor. It is essential that the practitioner has sufficient knowledge about facial anatomy, the implementation of this procedure and management of complications. The practitioner should be aware of potential devastating consequences and inform the patient specifically about this rare complication, since they might be irreversible and far-reaching.

#### Patient consent

The patient consented to publication of the case and the images in writing.

#### Disclosures

No funding.

#### Authorship

All authors attest that they meet the current ICMJE criteria for Authorship.

#### Declaration of competing interest

T. Kohnen: *Consultant and Research for Abbott/J&J, Alcon/Novartis, Avedro, Oculentis, Oculus, Presbia, Santen, Schwind, Zeiss. Consultant for Allergan, Bausch & Lomb, Dompé, Geuder, Med Update, Merck, Rayner, Staar, Théa, Tear Lab, Thieme, Ziemer. Research for Avedro, Hoya.*

The following authors have no financial disclosures: PD, MM, CK,

NK, YW.

### Acknowledgements

We thank Franco Lopez for his effort concerning the images.

### References

1. Kapoor KM, Kapoor P, Heydenrych I, Bertossi D. Vision loss associated with hyaluronic acid fillers: a systematic review of literature. *Aesthetic Plast Surg.* 2020;44(3):929–944. <https://doi.org/10.1007/s00266-019-01562-8>.
2. Park KH, Kim YK, Woo SJ, et al. Iatrogenic occlusion of the ophthalmic artery after cosmetic facial filler injections: a national survey by the Korean Retina Society. *JAMA Ophthalmol.* 2014;132(6):714–723. <https://doi.org/10.1001/jamaophthalmol.2013.8204>.
3. Khan TT, Colon-Acevedo B, Mettu P, DeLorenzi C, Woodward JA. An anatomical analysis of the supratrochlear artery: considerations in facial filler injections and preventing vision loss. *Aesthetic Surg J.* 2017;37(2):203–208. <https://doi.org/10.1093/asj/sjw132>.
4. Li X, Du L, Lu JJ. A novel hypothesis of visual loss secondary to cosmetic facial filler injection. *Ann Plast Surg.* 2015;75(3):258–260. <https://doi.org/10.1097/SAP.0000000000000572>.
5. Myung Y, Yim S, Jeong JH, et al. The classification and prognosis of periocular complications related to blindness following cosmetic filler injection. *Plast Reconstr Surg.* 2017;140(1):61–64. <https://doi.org/10.1097/PRS.0000000000003471>.
6. Lamirel C, Newman NJ, Bioussé V. Vascular neuro-ophthalmology. *Neurol Clin.* 2010;28(3):701–727. <https://doi.org/10.1016/j.ncl.2010.03.009>.



Petra Davidova



Thomas Kohnen