

## Case report

## Langerhans cell histiocytosis presenting with complicated pneumonia, a case report

Mark Ottink<sup>a,\*</sup>, Simone Feijen<sup>b</sup>, Philippe Rosias<sup>b</sup>, Simon Robben<sup>c</sup>, Bernd Granzen<sup>d</sup>, Jan Heynens<sup>b</sup>, Rijn Jöbsis<sup>e</sup>

<sup>a</sup> Department of Paediatrics, Medisch Spectrum Twente, PO Box 50000, 7500 KA Enschede, The Netherlands

<sup>b</sup> Department of Paediatrics, Orbis Medical Centre, PO Box 5500, 6130 MB Sittard, The Netherlands

<sup>c</sup> Department of Radiology, Maastricht University Medical Centre, PO Box 5800, 6202 AZ Maastricht, The Netherlands

<sup>d</sup> Paediatric Oncology, Department of Paediatrics, Maastricht University Medical Centre, PO Box 5800, 6202 AZ Maastricht, The Netherlands

<sup>e</sup> Paediatric Pulmonology, Department of Paediatrics, Maastricht University Medical Centre, PO Box 5800, 6202 AZ Maastricht, The Netherlands

## ARTICLE INFO

## Article history:

Received 16 August 2012

Received in revised form

7 December 2012

Accepted 11 December 2012

## Keywords:

Langerhans cell histiocytosis

Pleural empyema

Cystic lung disease

Nail abnormalities

Children

## ABSTRACT

We describe a 2 ½ year old boy presenting with fever, abdominal pain and splinter haemorrhages of the nails. On further examination there were signs of pneumonia with pleural effusion. This was treated with mini-thoracotomy, drainage and intravenous antibiotics. Further diagnostic workup for underlying causes showed diffuse cystic lung disease, suggestive of Langerhans cell histiocytosis. This was confirmed on pathology specimens, which showed Langerhans cells in lung tissue, nail bed and skin biopsy samples, indicating multisystem Langerhans cell histiocytosis. The patient was treated with Prednisone and Vinblastin according to the LCH-III guidelines. In this case report we give a brief description on cystic lung disease in children, Langerhans cell histiocytosis and associated nail abnormalities.

© 2012 Elsevier Ltd. Open access under [CC BY-NC-ND license](http://creativecommons.org/licenses/by-nc-nd/4.0/).

## 1. Introduction

Langerhans cell histiocytosis (LCH) is a rare disease characterized by monoclonal proliferation of dendritic-cell related histiocytes (Langerhans cells). These histiocytes have destructive behaviour for the surrounding tissue which they infiltrate. Among the organs often involved are the skeletal system, skin, thyroid gland and risk organs like liver, lung, spleen and the haematopoietic system.

In this case we present a young toddler primarily presenting with signs of a complicated pneumonia, as the presenting sign of underlying systemic disease. Although lung involvement is frequently seen in multisystem LCH, it is not often the presenting sign.

## 2. Patient presentation

A 2 ½ -year-old boy was referred to the paediatric outpatient department for acute fever, abdominal pain, and decreased oral intake. Furthermore, he had linear splinter haemorrhages of the

nails for some weeks. Previous medical history was unremarkable besides a recent tonsillectomy. Physical examination showed an ill child with fever, tachypnoea (breathing rate 36/min), tachycardia (heart rate 165/min) and oxygen saturation in room air between 89 and 93%. With oxygen supplementation via nasal cannula of 1 L/min, oxygen saturation was 97–98%. Blood pressure was 121/76 mmHg. On auscultation there was decreased air-entry over the left hemithorax, pleural friction rub, and hepatomegaly. Laboratory data revealed elevated C-reactive protein of 333 mg/l (reference range <10 mg/l), erythrocyte sedimentation rate was 37 mm/h (reference range 3–13 mm/h), platelet count  $573 \times 10^9/l$  (reference range  $150\text{--}450 \times 10^9/l$ ), white blood cell count  $24.6 \times 10^9/l$  (reference range  $4.0\text{--}10.0 \times 10^9/l$ ). Differential blood count: neutrophils 86.6%, immature neutrophils 6%, lymphocytes 7.6%, monocytes 5.3%, eosinophils 0.3%, basophils 0.2%.

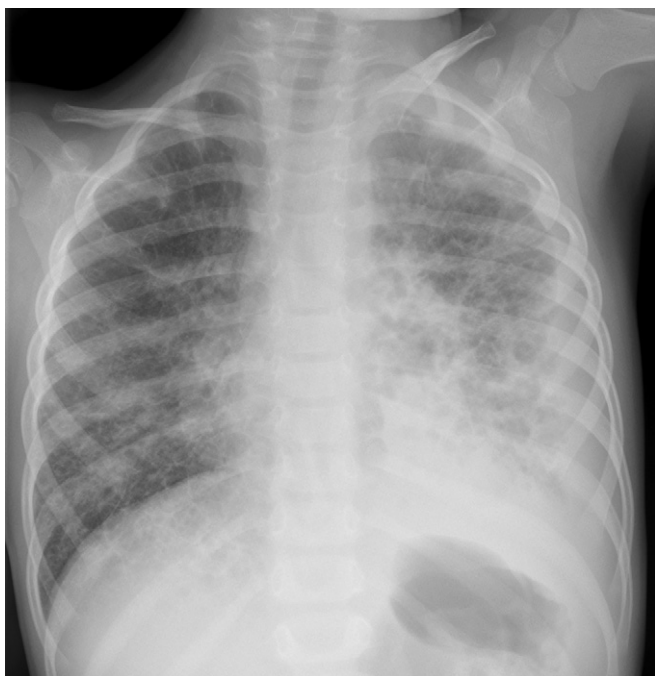
The chest radiograph revealed a basal consolidation in the left lower lobe and opacification along the lateral chest wall. Moreover, there was some right-sided displacement of the heart and mediastinum. This was suspect of pulmonary consolidation with pleural effusion. Additionally, the right lung and left upper lobe demonstrated an evident reticulonodular pattern (Fig. 1).

The diagnosis of pneumonia with pleural effusion was made. This was confirmed with ultrasound. At this point the decision was

Abbreviations: LCH, Langerhans cell histiocytosis; HRCT, High resolution computed tomography.

\* Corresponding author. Tel.: +31 53 4872310; fax: +31 53 4872326.

E-mail address: [md.ottink@mst.nl](mailto:md.ottink@mst.nl) (M. Ottink).



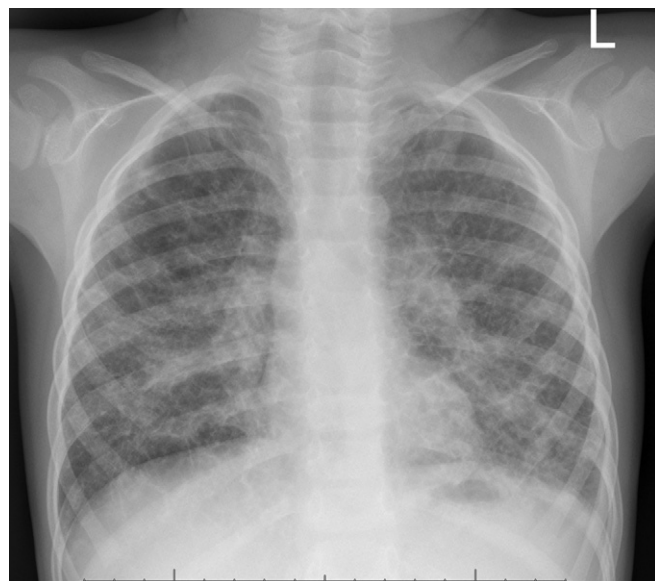
**Fig. 1.** Chest radiograph at presentation. Basal consolidation in the left lower lobe, opacification along the left lateral wall and mediastinal shift, indicating pneumonia and pleural effusion. Reticulonodular pattern in right lung and left upper lobe.

made not to perform a diagnostic pleural tap, but start treatment with broad-spectrum antibiotics, amoxicillin-clavulanic acid and gentamicin. Blood cultures remained negative. After initial improvement, the patient deteriorated after four days with dyspnoea and increased oxygen need. Chest ultrasound showed increased pleural effusion and progressive organisation of the effusion. Bacterial endocarditis was ruled out with negative blood cultures and a normal cardiac ultrasound. A mini-thoracotomy was performed with decortication of the left lung and placement of a pleural drain. Pleural fluid chemistry showed signs of pleural exudate (pH 6.92, glucose <0.6 mmol/l, protein 35.7 g/L, lactate dehydrogenase 2677 U/l)<sup>1</sup> Antibiotics were switched to flucloxacillin, gentamicin and clindamycin. Bacterial cultures of pleural fluid and blood remained negative. Afterwards, analysis of pleural fluid with polymerase chain reaction (16S-PCR) determined *Streptococcus pneumoniae* as the causative pathogen. The patient fully recovered within 10 days, had no oxygen need and was dismissed from hospital care with oral antibiotics.

Since the chest radiograph showed not only pneumonia and pleural effusion, but also interstitial abnormalities, a thorough diagnostic workup was performed to rule out underlying causes of pulmonary disease. The inflammatory markers had normalized. Serological tests for viral, atypical and bacterial pathogens were negative. Sweat test was negative. Tuberculin skin test was negative.

The immunological survey was normal. The patient had been vaccinated with a heptavalent pneumococcal conjugate vaccine (PCV-7, Prevenar®). There were normal pneumococcal antibody levels. Subtyping of the pneumococcal strand was not possible, since it was detected with 16S-PCR, not by culture.

Further imaging was planned to be performed after full recovery of the pleural empyema. Eight weeks after full recovery the chest radiograph was still abnormal with a reticulonodular pattern and features of honeycombing (Fig. 2). Therefore, a high resolution Computed Tomography (HRCT) was performed. The HRCT of the thorax revealed numerous bilateral cysts of different size and



**Fig. 2.** Chest radiograph, performed eight weeks after recovery, revealing persistent reticulonodular pattern with features of honeycombing.

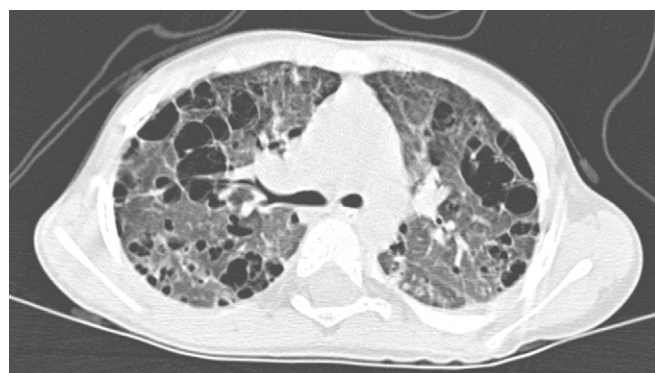varying wall thickness (Fig. 3). There were no signs of emphysema or bronchiectasis. Hence, Langerhans cell histiocytosis (LCH) was suspected.

Further diagnostic testing was performed to confirm the diagnosis. Abdominal ultrasound was normal, with no signs of hepatic involvement or hepatomegaly and normal liver function tests. The initial presentation with hepatomegaly had been caused by diaphragmatic flattening due to pulmonary hyperinflation.

Full body X-ray series showed no osteolytic lesions indicative for LCH. Under general anaesthesia an open lung biopsy, skin biopsy, nail bed biopsy, bone biopsy and bone marrow aspiration was performed.

The lung biopsy showed foci of histiocytes, mixed with eosinophilic granulocytes, with a stellar distribution. In these foci cysts were developing. CD1a staining was highly positive and S100 staining mildly positive, indicative of Langerhans Cell Histiocytosis. Skin- and nail bed specimens also showed presence of CD1a-positive cells. Bone marrow aspiration was negative.

The patient was treated following the LCH-III protocol (Histiocyte Society) with Vinblastin and Prednison. After six weeks, the patient responded well to chemotherapy at the first course evaluation. Nail and skin abnormalities improved, and chest CT remained stable. Bronchoalveolar lavage at 12 weeks treatment showed less



**Fig. 3.** High resolution CT. Diffuse bilateral cysts of varying size and wall thickness.

than 2% histiocytes in the bronchial lavage fluid. Repeated skin biopsy showed no signs of active histiocytosis. The clinical course was complicated by recurrent pneumothoraces of the right lung due to spontaneous cyst rupture, which were primarily treated with pleural drainage and finally with pleurodesis. Since the initial pneumonia/empyema was treated with a thoracotomy and decortication, the left lung was probably sufficiently protected against recurrent pneumothoraces.

The further course was uneventful under continuous treatment with vincristine, cytarabine and prednisolon. There are minimal signs of histiocytosis activity in the skin and radiological examinations of the lung did not show any progression. The child is in excellent condition, and we are currently tapering the medication.

### 3. Discussion

#### 3.1. Cystic lung disease

HRCT showed extensive pulmonary damage with numerous cysts. In cystic lung disease one should differentiate between cysts or cavities. The distribution can be focal, multifocal or diffuse. In adults, causes of diffuse cystic lung disease include end stage idiopathic pulmonary fibrosis, connective tissue disease-related pulmonary fibrosis, asbestosis, advanced sarcoidosis or metastatic disease. However, all these disease are very rare in children. Diffuse cystic lung disease in children can be caused by lymphangioleiomyomatosis and LCH.<sup>2,3</sup> Lymphangioleiomyomatosis has been described in adolescents and young adults, but is mainly described in smoking females and not in children. The diagnostic imaging in a child is suggestive for the diagnosis of LCH.

The most common early radiological finding in pulmonary LCH is a reticulonodular pattern, due to granulomatous nodules containing Langerhans histiocytes and eosinophils in the wall of bronchioles. Later, granulomas are replaced by fibrosis and the formation of thin-walled air-filled cysts.<sup>4</sup>

#### 3.2. Langerhans cell histiocytosis

Langerhans cell histiocytosis is a class I histiocytosis syndrome of dendritic origin. It is rare disorder characterized by monoclonal proliferation of dendritic-cell related histiocytes (Langerhans cells), with a variable admixture of other cells, which form granulomas with proliferative and locally destructive behaviour. These histiocytes can cause subsequent infiltration of various organs.<sup>5–8</sup> LCH is considered a clonal proliferation of Langerhans cells as a reactive, rather than a malignant process.<sup>7–9</sup>

Most often children are affected, with a peak incidence of 0.2–1.0/100.000 children per year from 1 to 4 years of age.<sup>7,10–12</sup>

According to the number of different organs involved, single system and multisystem disease are distinguished.<sup>5,7,9–11</sup> LCH predominantly affects the skeletal system and skin, although central nerve system, thyroid and the so-called risk organs (liver, spleen and haematopoietic system) may also be affected.

In children, lung involvement is present in about 15% of all patients and in 24% of patients with multisystem disease.<sup>13</sup> Pulmonary involvement is rarely the most predominant clinical manifestation.<sup>4,6</sup> Of the patients with multisystem LCH without pulmonary abnormalities, 8.8% develop pulmonary LCH within the next year.<sup>13</sup> Isolated pulmonary LCH occurs in only 1% of the cases.<sup>14–16</sup> In adults, pulmonary histiocytosis is closely related to smoking.<sup>17</sup>

Clinical presentation of symptomatic lung involvement in LCH in children is nonspecific, such as dyspnoea, cough, chest pain, fatigue, wheezing, and tachypnoea.<sup>4,5</sup> When cysts are situated in the periphery of the lung, the patient is at risk for cysts rupture

which could cause a pneumothorax, as has been the case in our patient.<sup>4,14</sup>

To obtain definite diagnosis, immunohistochemical demonstration of CD1a epitopes on the cell surface and/or demonstration of Birbeck granules in the cytoplasm by electron microscopy is required, in addition to conventional light microscopy (and positive staining for S100-protein). Once LCH is diagnosed, based on typical histopathological findings, stratification into single-system or multisystem disease is based on the number of organs involved.

Patients with localized disease have a good prognosis and may not require any treatment.<sup>18–20</sup> On the other hand, for multisystem LCH, the Histiocyte Society recommends an intensive treatment during the first 6 weeks of therapy and continuation treatment thereafter.

In children, prognosis mainly depends on two negative prognostic factors: risk organ involvement (dysfunction of liver, spleen and haematopoietic system), and poor response to initial treatment.<sup>7,11,18–20</sup> Involvement of risk organs is associated with a significantly increased mortality rate.<sup>7,19,20</sup> Patients with risk organ involvement who do not achieve a response to initial treatment have a 75% risk of fatal outcome.<sup>19</sup> In contrast, those who do respond to initial chemotherapy have an 88%–91% survival rate.<sup>19,21</sup>

Several studies and clinical observations have concluded that, in paediatric patients, lung involvement is the only risk organ that is not associated with increased mortality.<sup>6,15</sup> This was recently confirmed in a large retrospective study of 420 patients with multisystem LCH, in which pulmonary involvement did not alter 5-year survival rate.<sup>13</sup> Lung involvement will therefore no longer be seen as a risk organ.<sup>15</sup>

An age younger than 2 years at diagnosis was thought to be related to a potentially fatal outcome, although recent studies show that an unfavourable outcome is only related to those young children with a multisystem disease. Young age itself is no longer a risk factor for mortality.<sup>19</sup>

Permanent lung damage after pulmonary LCH in children is relatively uncommon, incidence ranging from 1 up to 33%.<sup>22,23</sup> However, considering the severe pulmonary abnormalities and recurring pneumothoraces in our patient, permanent damage and long term sequelae are very likely.

#### 3.3. Nail abnormalities

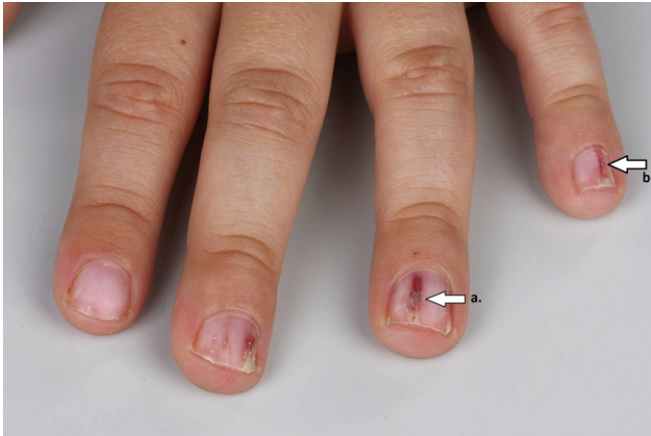Nail involvement in LCH is uncommon, and usually occurs in patients with multisystem disease and involvement of risk organs, therefore it is stated to be an unfavourable prognostic sign. The nail involvement may include subungual hyperkeratosis, purpuric striae and longitudinal grooving, onycholysis and loss of the nail plate (Fig. 4). Previous case reports have mostly reported destructive nail changes.<sup>20,24</sup>

##### 3.3.1. What this paper adds to the literature

In this case we have been able to illustrate the remarkable pulmonary abnormalities caused by pulmonary manifestation of Langerhans cell histiocytosis in a young child. We have described the differential diagnosis of diffuse cystic lung disease in children. Also, both skin and nail abnormalities can be the presenting signs of LCH, but are often missed on initial presentation.

#### 3.4. Summary

This case report describes a young child presenting with pneumonia, pleural effusion and nail abnormalities as the first presenting signs of Langerhans Cell histiocytosis. In this case, the histiocytosis was limited to the skin, nails and lungs. Although lung involvement develops in approximately half of the multisystem



**Fig. 4.** Detailed photograph of the nails of the patient, showing onycholysis (a) and splinter hemorrhages (b) of the nails.

disease LCH patients, the clinical presentation is nonspecific and usually does not predominate. The nail abnormalities are consistent with LCH, although uncommon.

#### Financial disclosure

No financial support was received.

#### Conflicts of interest

All authors declared no conflict of interest.

#### References

- McGrath EE, Anderson PB. Diagnosis of pleural effusion: a systematic approach. *Am J Crit Care* 2011;**20**(2):119–27. quiz 28.
- Cosgrove GP, Frankel SK, Brown KK. Challenges in pulmonary fibrosis. 3: cystic lung disease. *Thorax* 2007;**62**(9):820–9.
- Ryu JH, Swensen SJ. Cystic and cavitary lung diseases: focal and diffuse. *Mayo Clin Proc* 2003;**78**(6):744–52.
- Smets A, Mortelet K, de Praeter G, Francois O, Benoit Y, Kunnen M. Pulmonary and mediastinal lesions in children with Langerhans cell histiocytosis. *Pediatr Radiol* 1997;**27**(11):873–6.
- Lin CH, Lin WC, Chiang IP, Ho YJ, Peng CT, Wu KH. Langerhans cell histiocytosis with thyroid and lung involvement in a child: a case report. *J Pediatr Hematol Oncol* 2010;**32**(4):309–11.
- Oikonomou A, Prassopoulos P, Hytioglou P, Kirvassilis FV, Tsanakas JN. Atypical CT findings of isolated pulmonary Langerhans cell histiocytosis in a 4-year-old boy. *J Thorac Imaging* 2007;**22**(2):176–9.
- Salotti JA, Nanduri V, Pearce MS, Parker L, Lynn R, Windebank KP. Incidence and clinical features of Langerhans cell histiocytosis in the UK and Ireland. *Arch Dis Child* 2009;**94**(5):376–80.
- Weitzman S, Egeler RM. Langerhans cell histiocytosis: update for the pediatrician. *Curr Opin Pediatr* 2008;**20**(1):23–9.
- Burns P, Foster A, Moran T, Blayney A. Multifocal Langerhans' cell histiocytosis: a case report. *Ir J Med Sci* 2010;**179**(4):611–3.
- Egeler RM, D'Angio GJ. Langerhans cell histiocytosis. *J Pediatr* 1995;**127**(1):1–11.
- Grifo AH. Langerhans cell histiocytosis in children. *J Pediatr Oncol Nurs* 2009;**26**(1):41–7.
- Nagy B, Soos G, Nagy K, Dezso B. Natural course of isolated pulmonary Langerhans' cell histiocytosis in a toddler. 3-year follow-up. *Respiration; Int Rev Thorac Dis* 2008;**75**(2):215–20.
- Roncera L, Potschger U, Janka G, Gadner H, Minkov M. Pulmonary involvement in pediatric-onset multisystem Langerhans cell histiocytosis: effect on course and outcome. *J Pediatr* 2012;**161**(1):129–33 e1–3.
- Braier J, Latella A, Balancini B, Castanos C, Goldberg J. Isolated pulmonary Langerhans cell histiocytosis presenting with recurrent pneumothorax. *Pediatr Blood Cancer* 2007;**48**(2):241–4.
- Braier J, Latella A, Balancini B, Castanos C, Rosso D, Chantada G, et al. Outcome in children with pulmonary Langerhans cell histiocytosis. *Pediatr Blood Cancer* 2004;**43**(7):765–9.
- Chatkin JM, Bastos JC, Stein RT, Gaiger AM. Sole pulmonary involvement by Langerhans' cell histiocytosis in a child. *Eur Respir J Off J Eur Soc Clin Respir Physiol* 1993;**6**(8):1226–8.
- Suri HS, Yi ES, Nowakowski GS, Vassallo R. Pulmonary Langerhans cell histiocytosis. *Orphanet J Rare Dis* 2012;**7**:16.
- Gadner H, Grois N, Arico M, Broadbent V, Ceci A, Jakobson A, et al. A randomized trial of treatment for multisystem Langerhans' cell histiocytosis. *J Pediatr* 2001;**138**(5):728–34.
- Gadner H, Grois N, Potschger U, Minkov M, Arico M, Braier J, et al. Improved outcome in multisystem Langerhans cell histiocytosis is associated with therapy intensification. *Blood* 2008;**111**(5):2556–62.
- Mataix J, Betloch I, Lucas-Costa A, Perez-Crespo M, Moscardo-Guillem C. Nail changes in Langerhans cell histiocytosis: a possible marker of multisystem disease. *Pediatr Dermatol* 2008;**25**(2):247–51.
- Satter EK, High WA. Langerhans cell histiocytosis: a review of the current recommendations of the Histiocyte Society. *Pediatr Dermatol* 2008;**25**(3):291–5.
- Windebank K, Nanduri V. Langerhans cell histiocytosis. *Arch Dis Child* 2009;**94**(11):904–8.
- Haupt R, Nanduri V, Calevo MG, Bernstrand C, Braier JL, Broadbent V, et al. Permanent consequences in Langerhans cell histiocytosis patients: a pilot study from the Histiocyte Society-Late Effects Study Group. *Pediatr Blood Cancer* 2004;**42**(5):438–44.
- Ashena Z, Alavi S, Arzanian MT, Eshghi P. Nail involvement in Langerhans cell histiocytosis. *Pediatr Hematol Oncol* 2007;**24**(1):45–51.