



LETTER OPEN

The impact of postoperative EGFR-TKIs treatment on residual GGO lesions after resection for lung cancer

Signal Transduction and Targeted Therapy (2021)6:73

; <https://doi.org/10.1038/s41392-020-00452-9>

Dear Editor,

In recent years, the incidence of multifocal lung cancer is increasing, called multiple primary lung cancer (MPLC). Synchronous MPLC (sMPLC) is defined by multiple malignant lesions occurring at the same time.¹ In clinical practice, it was always extremely difficult to remove all lesions simultaneously for sMPLC patients. However, unresected GGO lesions after primary surgery frequently caught the risk of progression. Therefore, an effective postoperative treatment was necessary for these patients to prevent recurrence or progression of disease, especially for these patients who were unsuitable or unwilling to receive one more operation.

In multiple primary lung adenocarcinomas, there is a high proportion of patients harboring EGFR mutations, and most lesions present as multiple ground-glass opacity (GGO) in imaging examinations.² According to the Chinese Society of Clinical Oncology (CSCO) guideline, EGFR-TKIs are recommended to be used as adjuvant treatment after surgery of EGFR-mutated early-stage NSCLC. However, it is unclear whether postoperative EGFR-TKIs show efficacy on residual early-stage GGO lesions in patients who undergo resection of their main lesion(s) and harboring EGFR mutations. Therefore, the objective of this study was to observe whether postoperative EGFR-TKIs show efficacy on unresected persistent GGO lesions in sMPLC patients with EGFR mutations.

In this study, we retrieved patients who were considered to have MPLC and underwent resection of at least one EGFR-mutated lesion between 2014 and 2018 from the database. Included patients should have one or more residual malignant ground-glass nodules (<3 cm) whose malignancy were confirmed by both a radiologist and a thoracic surgeon (LHR and XS) (Supplementary Fig 1). The definition for MPLC is based on previously published clinical criteria (Supplementary Table 1).³ Treatment group included sMPLC patients treated with postoperative EGFR-TKIs, involving Gefitinib, Erlotinib, Icotinib, Afatinib and Osimertinib. Patients not treated with EGFR-TKIs after surgery were set as controls.

Low-dose thin-slice CT (1 mm thickness) was used for imaging examination in all patients, once every 2–3 months. As the largest diameter of most lesions was less than 1 cm, the definition of evaluable lesion of RECIST 1.1 criteria (1 cm or more in largest diameter) could not be met.⁴ Therefore, we expanded the lower limit of the diameter to 4 mm, as the thin-slice CT scan can precisely detect the minor changes in size by 2 mm. The definition of objective response rate (ORR) were identical to RECIST 1.1. In addition, the response rate (RR) of EGFR-TKIs was herein defined as the ratio of the patients/lesions with any diametrical reduction shown in CT scans to the whole cohorts of patients/lesions, respectively. Some specific section of the methods in this research such as the definition for MPLC, the set of some subgroup and the statistical analyses were placed in supplementary materials. Meanwhile, we measured the consistency of gene mutation between multiple lesions when multiple different lesions (≥ 2) were resected

in a same patient. This study was approved by the ethics committee of The First Affiliated Hospital of Guangzhou Medical University and the informed consent of patients was waived.

A total of 143 eligible patients with sMPLC were included. Among them, 66 patients with 134 unresected malignant GGO lesions were treated with postoperative EGFR-TKIs, while the other 77 patients received observation only. Baseline information of these 66 patients treated with EGFR-TKIs is shown in supplementary Table 2.

LESION-ORIENTED RESPONSE RATE OF EGFR-TKIS

We recorded the changes in size of 134 lesions in 66 patients treated with postoperative EGFR-TKIs. In terms of lesions, the response rate (RR) is 23.9% (32/134). As illustrated in the waterfall plot (Fig. 1a), 32 lesions reduced, 7 lesions increased, and 95 lesions had no change in size.

The RR and ORR in different subgroups were presented in supplementary Table 3. There were significant differences in two subgroups: (1) the diameter of lesions ≥ 8 mm or < 8 mm (42.9 vs 15.2%, $P < 0.01$) and (2) mixed or pure-GGO lesions (34.0 vs 17.9%, $P = 0.03$). Based on RECIST 1.1 criteria, the objective response rate of EGFR-TKIs is 14.9% (20/134), and the statistical results of these subgroups were similar to the RR. The drug use was recorded in the 22 patients with reduction in size of lesions (Fig. 1b).

PATIENT-ORIENTED RESPONSE RATE OF EGFR-TKIS

In terms of patients, 22 patients had reduction in size of any lesion and the response rate of patients treated with postoperative EGFR-TKIs was 33.3% (22/66). Supplementary Fig. 2 shows typical changes in CT scans of patients who had a significant response to EGFR-TKIs.

Of the different subgroups, there were significant differences between the patients with maximum diameter of residual GGO lesions ≥ 8 mm or < 8 mm (58.6 vs 13.5%, $P < 0.01$), patients with more than 2(max 5) or 1–2 remaining malignant GGO lesions (54.2 vs 21.4%, $P < 0.01$), and patients with major lesions at stage III or stage I–II (61.5 vs 26.4%, $P = 0.02$). According to RECIST 1.1 criteria, the objective response rate of EGFR-TKIs is 19.7% (13/66), and the statistical results of each subgroup was similar to that of the RR. For comparison, we observed 77 patients who did not receive EGFR-TKIs after surgery. 9.1% (7/77) had a reduction in size of residual GGO lesions, which was significantly lower than the EGFR-TKIs treatment group ($P < 0.01$).

INDEPENDENT PREDICTORS FOR RESPONSE OF EGFR-TKIS

As shown in supplementary Table 3, a multivariable logistic regression model was created using some following covariates. These covariates were chosen based on the results of Chi-Square test. The efficacy of EGFR-TKIs was associated with a greater number of residual lesions (OR = 4.33, $P < 0.01$), larger diameter of

Received: 31 July 2020 Accepted: 24 November 2020

Published online: 21 February 2021

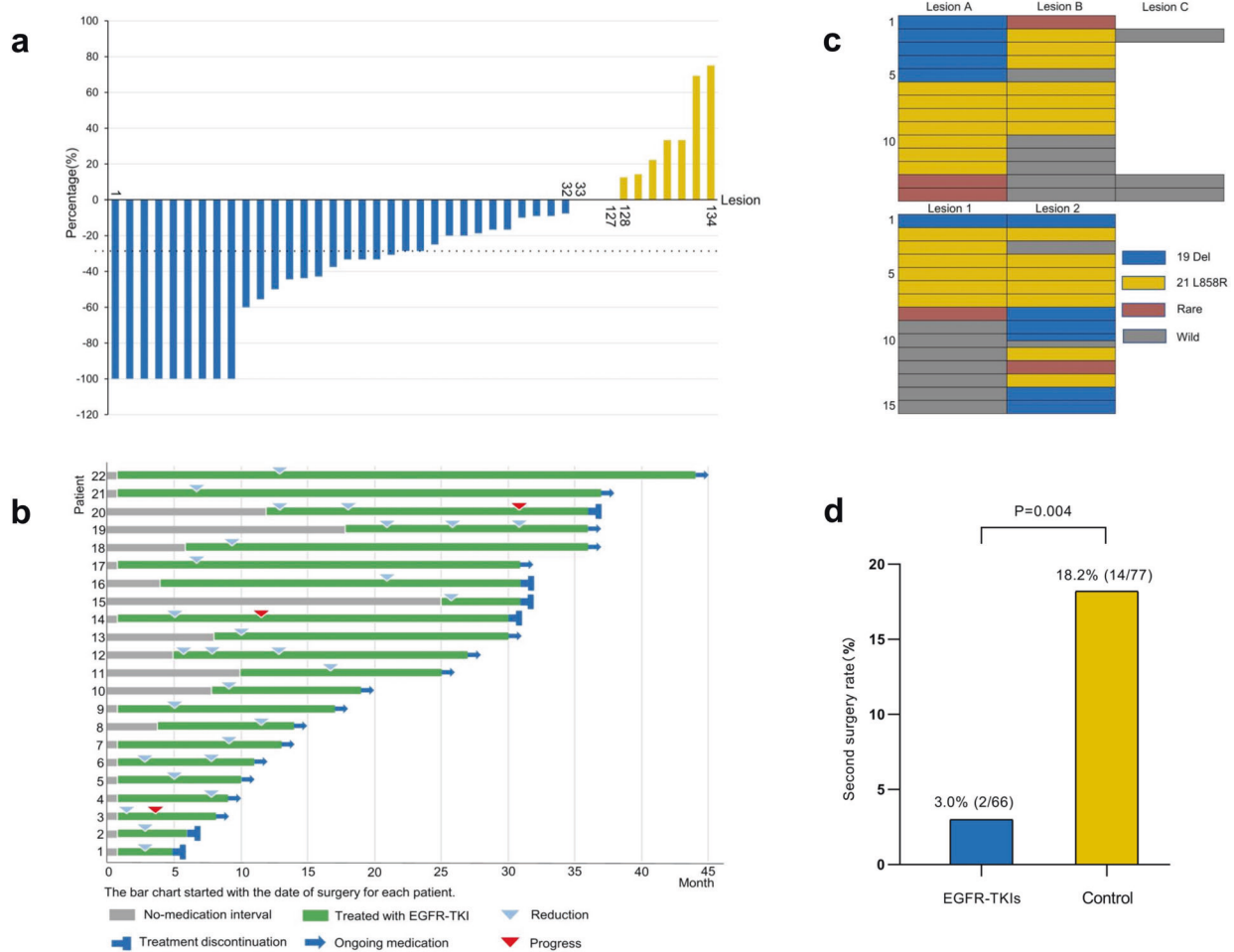


Fig. 1 **a** The changes in size of unresected GGO lesions during the medication. **b** The information of drug use was recorded in 22 patients with reduction in size of lesions. **c** The distribution of EGFR mutations in 29 patients with multiple lesions resected. The upper and lower tables show the types of mutation in patients who underwent one and two operations, respectively. The Lesion A, B and C represent different lesions resected in one same operation, while the Lesion 1 and 2 represent the lesions resected in the first and second operation. Meanwhile, for patients who underwent two operations, different colors were filled in the same table cell when multiple lesions were removed in one operation. **d** The second surgery rate of unresected lesions in the EGFR-TKIs treatment group and control group

the maximal residual lesion (OR = 9.07, $P < 0.01$), and higher stage of primary lesions (OR = 4.46, $P = 0.02$). In addition, in terms of the characteristics of lesions, lesions with mixed component (OR = 2.37, $P = 0.04$) and larger diameter of residual lesions (OR = 4.18, $P < 0.01$), were independent predictors for EGFR-TKIs efficacy.

Among 144 patients with postoperatively residual malignant GGO lesions, 29 patients underwent surgical resection of multiple lesions (2 or 3) and genetic testing. Interestingly, the consistency rate of 19 Del mutation was significantly lower than that of 21 L858R mutation (3.4 vs 31.0%, $P = 0.03$). Gene mutation types of these 29 patients are illustrated in Fig. 1c. Summary of cases sequentially using different EGFR-TKIs or surgery were recorded in Supplementary Table 4 and Supplementary Table 5. It's worth noting that the rate of second resection of residual lesions was significantly lower in the EGFR-TKIs treatment group compared to the control group (3.0 vs 18.2%, $P = 0.004$) (Fig. 1d).

To our knowledge, this study is the first study to observe the impact of postoperative EGFR-TKIs treatment on unresected GGO lesions in sMPLC patients after the surgery of major lesion(s) harboring EGFR-mutation. In our study, EGFR-TKIs show efficacy on these unresected GGO lesions but was limited. Notably, the response rate is lower compared with advanced stage patients in historical controls,⁵ this could be attributed to the genetic heterogeneity among lesions. However, patients with more

aggressive phenotypes have significant benefit from EGFR-TKIs in this study. Therefore, when considering postoperative EGFR-TKIs treatment for multifocal lung cancer, it is critical to determine the mutation status of each residual lesion.

In summary, postoperative EGFR-TKIs treatment show activity on persistent GGO lesions remaining after surgery and for these patients there was significant benefit if they presented with TNM stage III, had more than 2 remaining lesions, mixed component lesions, or the diameter of residual lesions ≥ 8 mm.

DATA AVAILABILITY

All data and materials are available to the researchers once published.

ACKNOWLEDGEMENTS

We thank Prof. Jun Liu, Prof. Weiqiang Yin and Prof. Hanzhang Chen from the First Affiliated Hospital of Guangzhou Medical University, Prof. Chi-Fu Jeffrey Yang from Stanford University Medical Center, Prof. Thomas D'Amico from Duke University Medical Center, Prof. Calvin S. H. Ng from Prince of Wales Hospital, Prof. Alessandro Brunelli from St. James's University Hospital, Prof. Gaetano Rocco from Istituto Nazionale Tumori in Italy, Prof. Rene Horsleben Petersen from University Hospital of Copenhagen, and Prof. Chia-chuan Liu from Sun Yat-Sen Cancer Center, for their valuable suggestions to this study. This work was supported by the following funding: The grant 2016YFC0905400 from the National Key R&D Program of China;

China National Science Foundation (Grant No. 81871893 & No. 81501996); Key Project of Guangzhou Scientific Research Project (Grant No. 201804020030); High-level university construction project of Guangzhou medical university (Grant No. 20182737, 201721007, 201715907, 2017160107); National key R & D Program (Grant No. 2017YFC0907903 & 2017YFC0112704).

AUTHOR CONTRIBUTIONS

B.C., C.L., and Y.Z. analyzed the data and wrote the manuscript. J.L., S.X. and H.L. searched and collected the information of patients and relevant literatures. Z.L. and W.Z. participated in the discussion. Jianxing He and Wenhua Liang designed the study. All authors have read and approved the final manuscript.

ADDITIONAL INFORMATION

The online version of this article (<https://doi.org/10.1038/s41392-020-00452-9>) contains supplementary material, which is available to authorized users.

Competing interests: The authors declare no competing interests.

Bo Cheng¹, Caichen Li¹, Yi Zhao¹, Jianfu Li¹, Shan Xiong¹,
Hengrui Liang¹, Zhichao Liu², Wenchuang Zeng¹,
Wenhua Liang¹ and Jianxing He¹

¹Department of Thoracic Surgery and Oncology, the First Affiliated Hospital of Guangzhou Medical University, State Key Laboratory of Respiratory Disease & National Clinical Research Center for Respiratory Disease, Guangzhou 510120, China and ²Department of Thoracic Surgery, Shanghai Chest Hospital, Shanghai Jiao Tong University, Shanghai, China

These authors contributed equally: Bo Cheng, Caichen Li, Yi Zhao
Correspondence: Wenhua Liang (liangwh1987@163.com) or
Jianxing He (drjianxing.he@gmail.com)

REFERENCES

- Jiang, L. et al. Prognosis of synchronous and metachronous multiple primary lung cancers: systematic review and meta-analysis. *Lung Cancer* **87**, 303–310 (2015).
- Kim, H. K. et al. Management of multiple pure ground-glass opacity lesions in patients with bronchioloalveolar carcinoma. *J. Thorac. Oncol.* **5**, 206–210 (2010).
- Detterbeck, F. C. et al. The IASLC lung cancer staging project: background data and proposed criteria to distinguish separate primary lung cancers from metastatic foci in patients with two lung tumors in the forthcoming eighth edition of the TNM classification for lung cancer. *J. Thorac. Oncol.* **11**, 651–665 (2016).
- Eisenhauer, E. A. et al. New response evaluation criteria in solid tumours: revised RECIST guideline (version 1.1). *Eur. J. Cancer* **45**, 228–247 (2009).
- Gao, G. et al. Epidermal growth factor receptor-tyrosine kinase inhibitor therapy is effective as first-line treatment of advanced non-small-cell lung cancer with mutated EGFR: a meta-analysis from six phase III randomized controlled trials. *Int. J. Cancer* **131**, E822–E829 (2012).



Open Access This article is licensed under a Creative Commons Attribution 4.0 International License, which permits use, sharing, adaptation, distribution and reproduction in any medium or format, as long as you give appropriate credit to the original author(s) and the source, provide a link to the Creative Commons license, and indicate if changes were made. The images or other third party material in this article are included in the article's Creative Commons license, unless indicated otherwise in a credit line to the material. If material is not included in the article's Creative Commons license and your intended use is not permitted by statutory regulation or exceeds the permitted use, you will need to obtain permission directly from the copyright holder. To view a copy of this license, visit <http://creativecommons.org/licenses/by/4.0/>.

© The Author(s) 2021