



Adverse effects following dental local anesthesia: a literature review

Jean-Pierre T.F. Ho^{1,2}, Tom C.T. van Riet¹, Youssef Afrian¹, Kevin T.H. Chin Jen Sem¹, René Spijker³, Jan de Lange¹, Jerome A. Lindeboom^{1,4}

¹Department of Oral and Maxillofacial Surgery, Amsterdam University Medical Center, Amsterdam, The Netherlands

²Department of Oral and Maxillofacial Surgery, Northwest Clinics, Alkmaar, The Netherlands

³Medical Library, Amsterdam University Medical Center, University of Amsterdam, The Netherlands

⁴Department of Oral and Maxillofacial Surgery, Amstelland Hospital, Amstelveen, The Netherlands

Local anesthesia is indispensable in dentistry. Worldwide, millions of local anesthetic injections are administered annually, and are generally considered safe invasive procedures. However, adverse effects are possible, of which dentists should be aware of. This scoping review aimed to provide an extensive overview of the reported literature on the adverse effects of dental local anesthesia. The types of papers, what is reported, and how they are reported were reviewed. Additionally, the incidence and duration of adverse effects and factors influencing their occurrence were also reviewed. An electronic search for relevant articles was performed in PubMed and Embase databases from inception to January 2, 2020. The titles and abstracts were independently screened by two reviewers. The analysis was narrative, and no meta-analysis was performed. This study included 78 articles. Ocular and neurological adverse effects, allergies, hematomas, needle breakage, tissue necrosis, blanching, jaw ankylosis, osteomyelitis, and isolated atrial fibrillation have been described. Multiple adverse effects of dental local anesthesia have been reported in the literature. The results were heterogeneous, and detailed descriptions of the related procedures were lacking. Vital information concerning adverse effects, such as the dosage or type of anesthetic solution, or the type of needle used, was frequently missing. Therefore, high-quality research on this topic is needed. Finally, the adverse effects that are rarely encountered in real-world general practice are overrepresented in the literature.

Keywords: Adverse Effects; Dental Care; Local Anesthesia; Review.



This is an Open Access article distributed under the terms of the Creative Commons Attribution Non-Commercial License (<http://creativecommons.org/licenses/by-nc/4.0/>) which permits unrestricted non-commercial use, distribution, and reproduction in any medium, provided the original work is properly cited.



INTRODUCTION

Dental local anesthesia is an essential part of dentistry, and approximately 300 million cartridges of anesthesia are used annually for dental treatment in the United States alone [1].

The first anesthetic, cocaine, was obtained in 1859 from the coca plant by Albert Niemann and used locally by Carl Koller during an ophthalmic procedure in 1884

[2,3]. Subsequently, Sigmund Freud applied cocaine topically to the tongue and noted a numbing effect [4,5]. Halsted was the first surgeon to administer a nerve block in the mandible for successful and painless wisdom tooth extraction [6,7]. Halsted and his students performed nerve blocks experimentally on each other and administered a local anesthetic solution containing cocaine. It has become clear that cocaine is addictive and causes several adverse effects [8,9]. Unfortunately, there have also been reports of local anesthetic failures during interventions

Received: August 6, 2021 • Revised: September 16, 2021 • Accepted: October 5, 2021

Corresponding Author: Jerome A. Lindeboom, DDS, MD, PhD, Department of Oral and Maxillofacial Surgery, Amsterdam University Medical Center, Amsterdam, and Amstelland Hospital Amstelveen, Meibergdreef 9, 1105 AZ, Amsterdam, The Netherlands

Tel: 0031205664098 E-mail: j.a.lindeboom@amsterdamumc.nl

Copyright© 2021 Journal of Dental Anesthesia and Pain Medicine

[10] and, in the early years, several cases of systemic intoxication and even death [11].

Dental local anesthesia has various purposes [12]. It is most frequently used to prevent pain during dental treatments, which contributes to the well-being of patients and facilitates treatment for the patient and dentist. Dental local anesthesia can also have a therapeutic effect, such as temporarily suppressing pain from pulpitis. Finally, dental local anesthesia can be used as a diagnostic tool to differentiate between dental pain and temporomandibular joint dysfunction.

The active substances of dental local anesthetics can be divided into the ester and amide types. Plasma cholinesterase is responsible for the metabolism of ester local anesthetics, and the liver breaks down amide local anesthetics [13]. Local anesthetics block conduction in fibers that transmit nerve impulses by inhibiting sodium ion inflow through ion channels [14,15]. This inhibition is temporary because specific enzymes inactivate the local anesthetic [16,17].

As with any invasive procedure, adverse effects can arise after the administration of dental local anesthesia [18]. The severity can range from mild and tolerable, such as blanching, to severe and dangerous, such as anaphylactic shock and toxicity [19]. The duration of adverse effects can also be temporary or permanent [20]. General dental practitioners should be aware of the possible adverse effects associated with the administration of dental local anesthesia.

This scoping literature review aimed to (1) provide an extensive overview of the different types of available papers reporting adverse effects following dental local anesthesia, (2) describe what and how these adverse effects were reported, and (3) review the incidence and duration of various adverse effects and the factors influencing their occurrence.

METHODS

This study was reported in accordance with the

Preferred Reporting Items for Systematic Reviews and Meta-Analyses guidelines [21].

1. Search strategy

An electronic search was performed using two bibliographic databases for the selection of relevant studies. PubMed and Embase databases were both used, with search terms chosen in cooperation with a technical librarian. The indexing terms, keywords, and free-text words used for the search strategy (Table 1) were as follows: “anesthetics, local,” “local anesthetics,” “articaine,” “prilocaine,” “complications,” “adverse effects,” “dentistry,” “prosthodontics,” “periodontics,” “implantology,” “endodontics,” and “root canal.” The search was performed on studies published up to January 2, 2020.

The search involved four steps. First, an initial search was conducted in PubMed and Embase using free-text words, keywords, and indexing terms (e.g., MeSH terms). Second, articles were selected based on their relevance, by screening titles and abstracts. Third, the selected articles were then screened for inclusion based on the inclusion and exclusion criteria (described below) after review of the full article. Finally, a search for additional studies was conducted by examining the reference lists of the included articles.

2. Selection criteria

Articles selected for this systematic review included observational studies, such as case reports, case series, cross-sectional studies, cohort studies, and non-randomized and randomized controlled trials. All intraoral techniques for the administration of local anesthesia were included, except for topical anesthesia. Because of the large variety and severity of adverse effects, defining the term “adverse effects” was difficult. In this review, it was defined as the occurrence of undesired effects after the administration of dental local anesthesia. Therefore, whenever an article referred to this circumstance, it was considered to describe an adverse effect and deemed eligible for inclusion in this review. Furthermore, it was presumed that adverse effects occurred due to the

Table 1. The search strategies performed on PubMed and Embase

Database	Search strategy
PUBMED	<p>#1 ("Anesthetics, local"[pharmacological action] OR "local anesthetics"[TIAB] OR "articaine"[TIAB] OR "prilocaine"[TIAB])</p> <p>#2(("Complications"[Subheading] OR "complications"[TIAB]) OR "adverse effects"[Subheading] OR ("adverse"[TIAB] AND "effects"[TIAB]) OR "adverse effects"[TIAB])</p> <p>#3 ("Dentistry"[Mesh] OR "community dentistry"[Mesh] OR "dental care for disabled"[Mesh] OR "dental Care for chronically ill"[Mesh] OR "dental care for children"[Mesh] OR "dental Care for aged"[Mesh] OR "dentistry"[TIAB] OR "prosthodontics"[TIAB] OR "periodontics"[TIAB] OR "implantology"[TIAB] OR "endodontology"[TIAB] OR "endodontics"[TIAB] OR "root canal treatment"[TIAB])</p> <p>#4 #1 AND #2 AND #3</p>
EMBASE	<p>#1 (exp local anesthetic agent/ OR (local anesthetic* OR articaine or prilocaine).ti,ab,kw)</p> <p>#2 ((safe or safety or side-effect* or undesirable effect* or treatment emergent or tolerability or toxicity or adrs or (adverse adj2 (effect or effects or reaction or reactions or event or events or outcome or outcomes))).ti,ab. OR (ae or to or tm).fs.)</p> <p>#3 exp "Dentistry"/ or ("dentistry prosthodontics" or "periodontics" or "implantology" or "endodontology" or "endodontics" or "root canal treatment").ti,ab,kw.</p> <p>#4 #1 AND #2 AND #3</p>

administration of local anesthetics instead of technical errors, unless stated otherwise.

The exclusion criteria were studies of patients receiving general anesthesia, those not reporting original findings (e.g., reviews, letters to the editor, or expert opinions), in vitro studies or reports of animal trials, studies that included participants younger than 18 years, and studies in languages other than English or Dutch.

3. Study selection and data extraction

Screening of the titles and abstracts was done using Rayyan QCRI (Qatar Computing Research Institute) [22]. Two reviewers (YA and KCJS) independently screened the titles and abstracts of the studies. If there were discrepancies between the two reviewers, a discussion followed by a third reviewer (JPTFH) resolved the discrepancies. The included articles were managed using EndNote (version X9, Clarivate Analytics, Philadelphia, USA).

For systematic data collection from all included studies, a data extraction form was developed in Microsoft Excel 365 (version 2002, Microsoft Corporation, Redmond, Washington, USA). For each article, the following features were extracted and recorded: first author, title and year of publication, study design, length of follow-up, sample size, setting, practitioner, intervention, technique,

anesthetic solution and dose, adverse effect symptoms, duration, and incidence, and participant age, sex, and comorbidities.

4. Data analysis

The analysis of the included studies is presented in narrative format. No statistical tests were used, and no meta-analysis was performed.

RESULTS

The results were divided into two parts to provide a comprehensive overview: the results of the search and an overview of the extracted data and a summary of the different types of adverse effects and reported incidences.

1. Search results and overview of extracted data

The database search yielded 1,572 articles. After removal of duplicates, 1,466 articles remained. The titles and abstracts of the articles were screened, and 159 full-text articles were assessed for eligibility using the inclusion and exclusion criteria. A summary of the search results is presented in the flow diagram in Fig. 1.

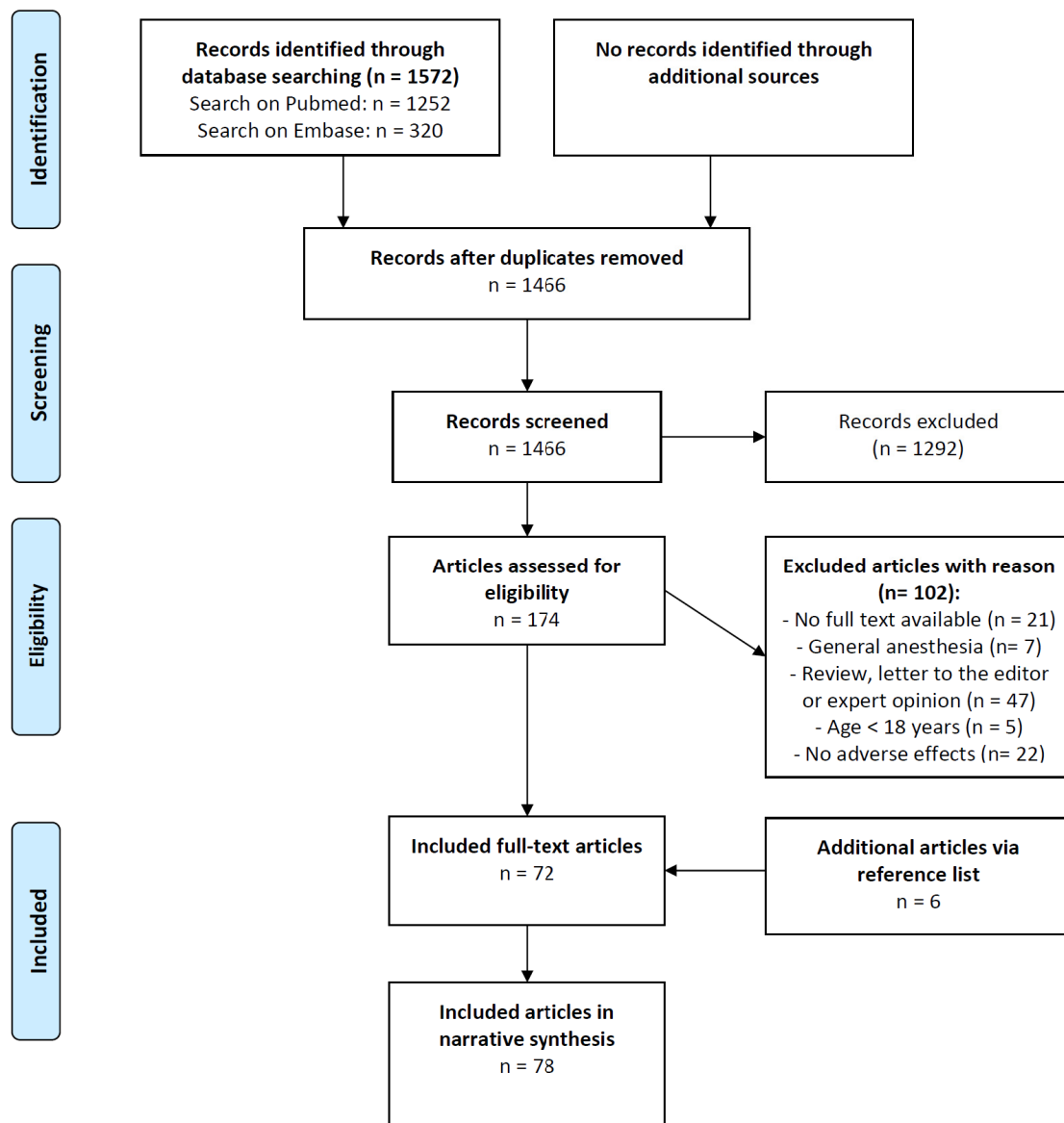


Fig. 1. The figure shows a flow diagram of the search strategy and selection process.

1) Study designs and participants

The narrative synthesis included 78 articles. The included articles were published between 1966 and 2019 (Fig. 2). In the last two decades, the number of publications has increased in comparison to that in previous decades. The number and proportion of articles by type were as follows: 44 case reports (56.4%), 14 case series (17.9%), 13 cross-sectional studies (16.7%), 4 non-randomized clinical trials (5.1%), 2 randomized clinical trials (2.6%), and a cohort study (1.3%). A total

of 18,926 participants were included in the articles, and the sex of 18,625 (98.4%) participants was reported. The ratio of men (48.5%) to women (51.5%) was 1:1.06, and the mean age of the participants was 37.9 years (range: 18 to 78 years).

2) Practitioners and settings of care

The practitioner was mentioned in 66 of 78 articles (84.6%). In 44 articles (56.4%), the dentist administered local anesthesia. Oral and maxillofacial surgeons were mentioned in 13 articles (16.7%) and dental students in

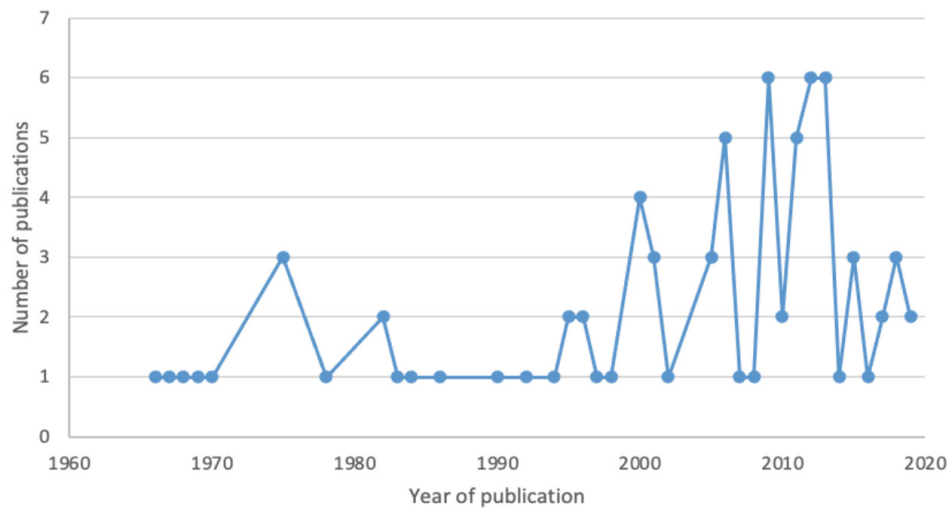


Fig. 2. The figure shows the number of publications on adverse effects following dental local anesthesia per year between 1966 and 2019.

4 articles (5.1%). Multiple administrations were mentioned in 5 articles (6.4%). The setting of care was specified in 66 of 78 articles (84.6%), and adverse effects occurred in general dental clinics (53.9%), hospital departments of oral and maxillofacial surgery (20.5%), dental university clinics (6.4%), and a clinical army center (1.3%). Two articles (2.6%) reported multiple care settings.

3) Local anesthetic solutions, techniques, and dental treatments

The local anesthetic solution was described in 70 of 78 studies (89.7%). Adverse effects occurred after the administration of lidocaine (amide-type) in 24 articles (30.8%). Articaine (amide-type) was mentioned in 14 articles (17.9%), mepivacaine (amide-type) in 5 articles (6.4%), procaine (ester-type) in 4 articles (5.1%), and prilocaine (amide-type) in 2 articles (2.6%). One article mentioned diphenhydramine (first-generation antihistamine with a chemical structure similar to that of ester and amide-type local anesthetics) (1.3%) and xylocaine (amide-type) (1.3%). Adverse effects following the administration of multiple solutions were reported in 19 articles (24.4%).

The local anesthetic technique was specified in 72 of 78 articles (92.3%). In 31 articles (39.7%) an inferior alveolar nerve block (IANB) was solely administered. Twenty articles (25.6%) revealed administration of

infiltration anesthesia alone and one (1.3%) detailed the use of intraosseous anesthesia. In 20 articles (25.6%), multiple techniques were used to administer local anesthesia.

The type of dental procedure was reported in 73 of 78 studies (93.6%). Adverse reactions following the administration of dental local anesthesia for tooth extraction were most frequently reported (39.7%). Adverse reactions following administration of dental local anesthesia for endodontic treatments (11.5%), restorations (10.3%), and student-to-student local anesthetic training (1.3%) have also been described. In 24 articles (30.8%), the treatment was described as one or more routine dental procedures—but not otherwise specified—performed in one treatment session.

2. Summary of reported adverse effects and incidences

1) Type of adverse effect

Because of the large scale of adverse effects associated with the administration of dental local anesthesia, the different types of adverse effects were grouped into 12 categories (Table 2).

2) Ocular adverse effects

A total of 23 articles reported ocular adverse effects following dental local anesthesia (Table 3). Dental local

Table 2. Number of articles reporting adverse effects, by category of effect

Type of adverse effect	Number of articles (%)	Reference
Ocular	23 (29.4)	23-45
Neurological	19 (23.4)	46-62,101,103
Allergy	10 (12.8)	63-72
Hemorrhage/hematoma	4 (5.1)	73-76
Needle breakage	3 (3.8)	77-79
Tissue necrosis	2 (2.6)	80,81
Blanching	2 (2.6)	82,83
Ankylosis	1 (1.3)	84
Osteomyelitis	1 (1.3)	85
Pregnancy-related adverse effects	1 (1.3)	86
Isolated atrial fibrillation	1 (1.3)	87
Other adverse effects	11 (14.1)	88-98

Table 3. Technique of administration, symptoms, and durations of ocular adverse effects following dental local anesthesia

Study	N	Technique of administration	Symptoms	Duration
Dogan, et al.[23]	1	Infiltration	Lacrimation, miosis, diplopia, and partial enophthalmia	6 hours
Blaxter, et al.[24]	2	IANB (n = 2)	Amaurosis and mydriasis (n = 1), diplopia (n = 1)	20 minutes to 4 hours
Choi, et al.[25]	1	IANB	Diplopia	15 minutes
Goldenberg [26]	1	IANB	Diplopia, amaurosis, and inability to abduct eye	20 minutes
Kini, et al.[27]	1	Infiltration	Diplopia, ptosis, and strabismus	3 hours
Magliocca, et al. [28]	1	Infiltration	Diplopia, inability to abduct eye (paresis of abducens nerve)	1 day
Odabaşı, et al.[29]	1	IANB	Amaurosis and diplopia	5 minutes
Seres, et al.[30]	1	IANB + infiltration	Diplopia and limited abduction of eye	4 hours
Steenen, et al.[31]	1	IANB + infiltration	Diplopia and blurry vision	6 hours
Chisci, et al.[32]	1	Infiltration	Diplopia	2 hours
Kronman, et al.[33]	1	Infiltration	Diplopia	50 minutes
Wilkie, et al. [34]	1	IANB	Mydriasis, ptosis, ophthalmoplegia, diplopia, uniocular blindness	30 minutes
Hyams, et al. [35]	1	Infiltration	Mydriasis, ptosis, and diplopia	120 days
Goldenberg, et al. [36]	1	Infiltration	Dizziness, diplopia, numbness of eyelid and eyebrow, inability to abduct eye	3 hours
Pandey, et al. [37]	1	IANB	Amaurosis	30 minutes
Verma, et al. [38]	2	IANB + infiltration (n = 2)	Amaurosis (n = 2)	2.5-3 hours
Williams, et al.[39]	1	IANB	Ophthalmoplegia, mydriasis, amaurosis, ptosis of upper eyelid	2 hours
Ngeow, et al.[40]	2	IANB (n = 2)	Blurry vision and loss of power accommodation (n = 2)	10-15 minutes
Uckan, et al.[41]	2	IANB (n = 2)	Burning sensation in eye (n=1), uniocular blindness and pain in eye (n = 1)	15-45 minutes
Rishiraj, et al.[42]	1	IANB + infiltration	Vision loss	Permanent
Penarrocha-Diago, et al.[43]	14	Infiltration (n = 14)	Miosis, ptosis and enophthalmos (n = 3), ptosis, mydriasis, external rectus muscle palsy (n = 3), impairment of superior oblique muscle (n = 1), external rectus muscle palsy (n = 7)	20-130 minutes
Prakasm, et al.[44]	1	Infiltration +greater palatine nerve block	Mydriasis, ptosis	Unknown
Zhang, et al.[45]	1	Infiltration	Lagophthalmos of the right eye	2 hours

IANB, inferior alveolar nerve block.

anesthesia was administered through infiltration (39.1%), IANB (39.1%), or a combination of both (17.4%). In one study, the technique used for administration was a combination of infiltration and a greater palatine nerve block (4.3%).

Multiple visual disturbances were described after the administration of dental local anesthesia. Diplopia was reported as an adverse effect in 14 studies, but disappeared after 15 min to 24 h [23-36]. Complete or partial loss of vision [24,26,29, 37-39], strabismus [27],

blurred vision [31,40], and uniocular blindness [34,41] were also reported, but were all temporary. Rishiraj et al. [42] described a case of permanent vision loss in one eye after administration through a combination of IANB and infiltration anesthesia. Prilocaine was administered, and after extraction of multiple teeth, the patient reported loss of vision in his left eye. After 2 months, the vision loss persisted.

Disturbance of the eye muscles has also been reported in several articles. Ngeow et al. [40] described two cases of lost ability to accommodate the eyes on the ipsilateral side after an IANB. Four articles reported an inability to abduct the eyes or a limitation on abduction [26,28,30,36]. Penarrocha-Diago et al. [43] reported 10 patients who developed external rectus muscle palsy and one patient who could not look down following a disablement of the superior oblique muscle. Posteriorly displaced eyeballs resulting from the loss of eye muscle function have also been described [23,43]. Paralysis of the extraocular muscles has been reported in two articles [34,39].

Drooping of the eyelids has been reported in several studies [27, 34,35,39,43,44], and one article described an inability to close the eyelids [45]. Goldenberg [36] reported a case of eyelid and eyebrow numbness following infiltration anesthesia. Excessive contraction of the pupil was reported in two articles [23,43], and excessive dilation of the pupil has also been described [24,34,35,39,43,44]. Uckan et al. [41] reported pain or burning sensation in the eye after administration of dental local anesthesia. The overall estimated incidence of ocular adverse effects was 0.07%–0.09% [43].

3) Neurological adverse effects

Trigeminal nerve injury from the administration of dental local anesthesia has been reported in various articles, varying from mild and temporary to severe and permanent. Hillerup et al. [46] described 54 patients with trigeminal nerve injury after IANB administration. The lingual nerve was affected in 77.8% of cases and the inferior alveolar nerve in 22.2% of cases. The symptoms

of nerve injury include paresthesia, dysesthesia, and allodynia. Garisto et al. [47] reported lingual nerve involvement in 89% and inferior alveolar nerve involvement in 11% of cases. Kingon et al. [48] described five cases with dysesthesia and paresthesia after an IANB or a mental nerve block with anesthetic solutions. One case of permanent nerve injury with facial numbness, hearing loss, facial palsy, and ataxia on the ipsilateral side of the injection was reported [49]. The overall reported incidence of permanent nerve injury from mandibular local anesthesia was 0.000007%–0.003% [47.50-53]. Moorthy et al. [54] reported a case of paresthesia in the maxillary region after infiltration anesthesia. The patient experienced numbness in the upper lip and gingiva in the anterior left region of the maxilla. One case of inflammatory trigeminal lesions was described. The symptoms were paresthesia and numbness of the tongue, lip, face, hand, and forearm on the ipsilateral side, and all were temporary [55].

Paralysis of the facial and sympathetic nerves has been reported in several studies. Hemifacial palsy following an IANB was reported by Tiwari et al. [56]. Hearing was impaired, the angle of the mouth was drooping, and hemifacial muscles were immobile. Tzermpos et al. [57] also reported temporary facial nerve palsy after an IANB, in which the patient could not raise the left eyebrow, and generalized weakness on the left side and drooping of the corner of the mouth were visible. One article reported hemifacial palsy after infiltration anesthesia [58]. Bell's sign and lower motor neuron weakness of the facial nerve were observed. Baart et al. [59] described two cases of transient paresis following IANB. The first patient could not purse the lips at the site of injection, and the facial nerve was paralyzed. The symptoms resolved after the treatment. The second patient developed paralysis of the vagus nerve and experienced tightness and difficulty in swallowing. A case of numbness in the area of the neck, swallowing difficulties, and pressure in the chest was reported after diffusion of anesthetic fluid in the parapharyngeal space [60]. Another article reported Harlequin syndrome after IANB [61].

Table 4. Symptoms and durations of allergic reactions to dental local anesthetic solutions

Study	N	Anesthetic solution	Symptoms	Duration
Wellins et al.[63]	1	Lidocaine 2%	Urticaria cheek, facial edema, closed orbits, and mild respiratory distress	30 hours
Campbell et al.[64]	1	Lidocaine 2%	Intense pain, unilateral facial edema, and swollen eye	7 days
Schwartz et al.[72]	1	Procaine (unknown %)	Itching, flushing, anxiety, shortness of breath, and urticaria	30 minutes
Curley et al.[65]	1	Lidocaine 2%, Prilocaine 3% Mepivacaine 3%	Soft tissue edema over the zygoma, and cheek edema	2 days 3 days 2 days
Milam et al.[66]	1	Lidocaine Mepivacaine Prilocaine	Generalized urticaria	Unknown
El-Qutob et al.[67]	1	Articaine (unknown %)	Facial edema and erythema	2 days
He et al.[68]	1	Articaine (unknown %)	Dizziness, pain on chest, palpitations, discomfort and breathing difficulty, erythema, and papules	3 days
Malanin and Kalimo[69]	1	Articaine 4%	Skin itching, papules and redness on chest, abdomen, and hands	5 hours
Bina et al.[70]	1	Diphenhydramine hydrochloride 1%	Edema on site of administration	3 days
Ross [71]	2	Case 1: mepivacaine 2% Case 2: mepivacaine 2%	Case 1: fever, severe headache, vomiting, joint pains, nausea, and malaise (general) Case 2: headache, nausea, malaise, local swelling and joint pain	Case 1: 12 hours Case 2: 8 hours

Sanchis et al. [62] described a case of uvular paralysis following IANB administration. A couple of minutes after the administration, the patient experienced swallowing difficulties and a strange sensation in the throat. The uvula was deviated towards the unimpaired side, and the soft palate was paralyzed. The dental treatment was continued, and the symptoms resolved after approximately 1 h.

4) Allergy

Various cases of allergic reactions following dental local anesthesia have been reported (Table 4). Components of dental local anesthetic solutions may lead to allergic reactions [1]. Local anesthetic solutions that have been linked to allergic reactions include lidocaine [63-66], articaine [67-69], diphenhydramine hydrochloride [70], prilocaine [65,66], mepivacaine [65,66,71], and procaine [72]. One case of anaphylactic shock following lidocaine administration was reported [63]. Twenty minutes after the administration of local anesthesia, the orbits were closed, facial edema appeared, and urticaria on the cheek was visible. The patient

experienced mild respiratory difficulties.

Three studies described an allergic reaction to articaine [67-69]. Symptoms included erythema, facial edema, dizziness, chest pain, palpitations, discomfort, respiratory distress, and itching and redness on the chest, abdomen, and hands. One case of an allergic reaction to diphenhydramine injection as a local anesthetic solution was reported [70]. Diffuse swelling on the side of the injection appeared 24 h after the administration. Ross et al. [71] reported two cases of serum-type allergic reactions to mepivacaine. The first patient complained of fever, headache, vomiting, nausea, and malaise, and the second complained of local edema, headache, malaise, joint pain, and nausea.

Two cases of allergic reactions to bisulfites have been reported [64,72]. The first patient experienced intense pain, unilateral facial swelling, and swelling of the eye after administration of dental local anesthesia. The second patient developed shortness of breath and urticaria and experienced a sense of itching, flushing, and anxiety. An allergic reaction to multiple local anesthetic solutions has been reported in two case reports [65,66]. Both patients

experienced an allergic reaction after the administration of lidocaine, prilocaine, and mepivacaine. Symptoms included generalized urticaria and soft tissue edema on the cheek and zygoma.

5) Hemorrhage/hematoma

Baikin et al. [73] conducted a study to assess the safety of dental local anesthesia in patients taking anticoagulants. The study group (n = 279) consisted of patients with a therapeutic international normalized ratio (INR) of 2–4, and the control group (n = 73) consisted of patients with a subtherapeutic INR (<2). Only two minor hematomas were found in the study group, and no prolonged hemorrhage was observed. Dougall et al. [74] determined the safety of buccal infiltration anesthesia in patients with hemophilia based on the severity of hemophilia (mild, moderate, or severe). The clinical experience of practitioners was categorized as less or more than 3 years of experience. No hematomas larger than 2 mm were reported after the administration of buccal infiltration. Furthermore, no differences in superficial bleeding times were reported based on the severity of hemophilia or practitioner experience. Brodsky et al. [75] reported on a patient with ear problems following a Gow-Gates injection during a practice exercise at a dental university. The patient experienced increased pressure in the region of the ear and experienced hearing difficulties. The efficacy and side effects of articaine, lidocaine, and mepivacaine were compared in a randomized clinical trial conducted by Srisurang et al. [76]. No serious adverse effects were reported, and only two ecchymoses were found at the site of injection 1 h after the administration of local anesthesia.

6) Needle breakage

Fractures of local anesthetic needles may occur during administration. Pogrel [77] described 16 cases of needle breakage that were reported over a period of 25 years. Twelve of these cases were excluded from this review because of the criterion that patients had to be ≥ 18 years

old. The four included cases were aged between 21 and 28 years. Needle breakage following an IANB was described in three of these four cases and after infiltration in the fourth. Pogrel [77] estimated the incidence of needle breakage to be 0.000007%. Zijderveld et al. [78] reported a case of needle breakage after an IANB, and Rahman et al. [79] reported a case of a 65-year-old man in which the needle fractured during the administration of an IANB.

7) Tissue necrosis

Woodmansey et al. [80] described a case of osteonecrosis following intraosseous anesthesia. Adequate anesthesia with a conventional IANB was difficult, and intraosseous anesthesia was performed. During perforation of the cortical bone, the metal perforator became stuck at the site of injection and was separated from the plastic base. An incision was made, and a small portion of the bone was removed to retrieve the metal perforator. During the follow-up appointment, exposed necrotic bone was noted at the previous injection site. Another study reported a case of skin necrosis following dental local anesthesia [81]. The patient felt a stinging sensation in the mouth and chin 3 h later. Erosion of the skin was noted superficially, and a follow-up appointment was scheduled. Three days later, the symptoms disappeared completely.

8) Blanching

Webber et al. [82] reported a case of blanching after IANB administration. The patient experienced dizziness and light-headedness shortly after the administration. Paleness of the infraorbital region, lip, nose, and lower eyelid was visible, and the patient experienced hemifacial numbness. Another case report described paleness of the skin above the lip on the ipsilateral site of injection after an IANB [83]. Blanching of the skin resolved during treatment, and the patient recovered completely.

9) Ankylosis

Luchetti et al. [84] conducted a study investigating the

relationship between dental local anesthetic injections and ankylosis of the jaw in patients with fibrodysplasia ossificans progressiva. Five patients reported permanent ossification and ankylosis of the jaw following the administration of local anesthesia. Three of these patients were excluded from this review because they were under 18 years of age. The included patients were two women aged 20–26 years. The symptoms were stiffening and marked swelling of the jaw, leading to a persistent loss of jaw movement.

10) Osteomyelitis

Barnard et al. [85] described a case of osteomyelitis following infiltration anesthesia in the maxilla. Fluctuant swelling of the cheek and pain developed 1 week after administration. Trismus was visible, and the opening of the mouth was limited to 8 mm. Paresthesia of the mental nerve on the ipsilateral side was also ascertained. The ramus, coronoid process, and condyle on the ipsilateral side appeared to be “moth-eaten” on radiographs. Long-term follow-up revealed disappearance of symptoms, and no recurrence was observed.

11) Pregnancy-related adverse effects

A comparative cohort study was conducted by Hagai et al. [86] to evaluate pregnancy-related adverse effects after administration of dental local anesthesia. The experimental group ($n = 210$) was exposed to local anesthetics and compared to the unexposed control group ($n = 794$). The relative numbers of major anomalies in both groups were compared. Cardiac septal anomalies, twin-to-twin transfusion syndromes, and intrauterine neoplasms were defined as major anomalies. The frequencies of stillbirth, miscarriage, ectopic pregnancy, and induced abortion were also compared. Exposure in the experimental group occurred during the first (53%) and second trimesters (45%). Exposure was not known in 2% of cases. The rate of major anomalies in the experimental group was 4.8% versus 3.3% in the control group, and no statistical differences ($P = 0.300$) were found.

12) Isolated atrial fibrillation

Manani et al. [87] reported a case of isolated atrial fibrillation after administration of dental local anesthesia. Bilateral maxillary infiltration with mepivacaine was administered, and the patient complained of lightheadedness, palpitations, and abdominal discomfort. Paresthesia of the lower limb and hearing difficulties have also been reported. Electrocardiogram findings showed isolated atrial fibrillation, which disappeared approximately 12 h later.

13) Other nonspecified adverse effects

Eleven articles described adverse effects that could not be placed in the 11 previously discussed categories of adverse effects. Martínez-Rodríguez et al. [88] compared the tolerance and anesthetic properties of lidocaine and articaine. Adverse effects were observed in two patients in the articaine group. The first patient experienced tachycardia and subsequently suffered from sweating, bradycardia, and fainting. The second patient experienced swelling and pain in the region of the right ear, and facial swelling was visible. Peñarrocha-Oltra et al. [89] compared the adverse effects of conventional dental local anesthesia and intraosseous anesthesia. The participants experienced significantly more intense pain following intraosseous anesthesia. Trismus was observed significantly more often after conventional anesthesia. Self-inflicted injury, dizziness, sweating, and leg weakness did not differ significantly between the two anesthetic methods. In another study, the efficacy of 2% and 4% articaine was compared, and no adverse effects were observed [90]. Van der Bijl et al. [91] reported two cases of adverse effects associated with higher concentrations of norepinephrine. The first patient developed severe headache and pulsating pain after administration of local anesthesia. The patient turned pale and felt cold. The second patient experienced severe headache. Another study described a case of inherited atypical plasma cholinesterase [92]. Procaine was administered prior to dental extractions, and the patient

Table 5. Reported incidences of adverse effects following dental local anesthesia

Adverse effect	Reported incidence (%)	Reference No.
Overall	4.5–26.2	94-97
Physical		
Fist clenching	14.6	93
Clutching to dental unit	4.9	93
Clutching to hand of assistant or partner	3.9	93
Moaning	12.6	93
Crying	1.9	93
Sweating	1.9–6.1	93,95
Turning pale	5-7.8	93,95
Dizziness	1.3–4.4	94,95
Agitation	1.1	94
Nausea	0.8	94
Tremor	0.7	94
Syncope	0.4–1	94-96
Headache	2.7	95
Self-inflicted injury		
Self-inflicted injury to the lip	2.9	97
Self-inflicted injury to the cheek	1.2	97
Self-inflicted injury to the tongue	0.6	97
Neurological		
Permanent nerve injury	0.000007–0.003	47,50-53
Needle touched nerve	2.5–3.8	93,98
Abnormal sensation (postoperative)	1.6	95
Transient paralysis of facial nerve	1–1.1	95,96
Seizure	0.04	94
Cardiovascular		
Tachycardia	1.1–1.2	94,95
Positive blood aspiration	2.9–3	96,98
Hypertension	0.6	97
Palpitation	6.1	95
Inadequate anesthesia	1.7–17	96,97
Pain		
Pain during administration	1	96
Postoperative pain	1.6	95
Psychological		
Confusion	2.2	95
Bronchospasm	0.04	95
Ocular adverse effects	0.07–0.09	43
Blanching	1	96
Needle breakage	0.000007	77
Hematoma	1	96

experienced shortness of breath, weakness, and nausea, became cyanotic, and passed out.

14) Reported incidences of adverse effects

Several observational studies have reported various adverse effects and their incidences following dental local anesthesia (Table 5). Multiple physical reactions during

and after administration of local anesthesia have been observed, including fist clenching; clutching of the hand to the dental unit, an assistant, or partner; and moaning, crying, sweating, turning pale, dizziness, agitation, nausea, tremor, syncope, and headache [93-96]. Self-inflicted injury to the lip, cheek, or tongue has also been observed after administration of dental local anesthesia [97]. Multiple

studies have reported adverse cardiovascular effects, including tachycardia, positive blood aspiration, hypertension, and palpitation [94-98]. Inadequate anesthesia, pain during administration, and postoperative pain have been described [95-99]. Other reported adverse effects included confusion and bronchospasm [94-96]. The overall rate of adverse effects following dental local anesthesia was 4.5%-26.2% [94-96].

DISCUSSION

The reported adverse effects covered in this review were divided into 12 categories because of their large scale and variety. Ocular adverse effects were cited most frequently and reported in 23 articles [23-45]. Ocular alterations consisted of visual disturbances, paralysis of the eye muscles, and numbness of the eyelids or eyebrows. Several hypotheses explaining the principle of ocular adverse effects have been described in the literature. The most common approach is the accidental injection of local anesthetic solutions into an artery [35]. Retrograde flow of an anesthetic solution may occur from the inferior alveolar artery or maxillary artery to the ophthalmic artery via the middle meningeal artery, leading to transient ischemia [99]. Another hypothesis is that anesthetic solutions are unintentionally injected into the cavernous sinus via venous circulation. The third, fourth, and sixth cranial nerves are bathed in the cavernous sinus, and their function may be diminished because of the anesthetic solution [100]. A third hypothesis is the diffusion of an anesthetic solution into the orbit via the pterygopalatine fossa [29]. Subsequently, lateral rectus palsies may occur, leading to eye muscle disturbances. Furthermore, activation of sympathetic fibers due to vascular trauma following injection and leading to vasospasm of vessels is also an explanation reported in the literature [33]. Most ocular adverse effects were transient and resolved within a few days. One case of permanent vision loss was reported; however, the occurrence of this adverse effect is extremely rare. Patients experiencing ocular adverse effects should

be monitored and observed regularly [39]. If there is no improvement, the patient should be referred to an ophthalmologist.

In terms of neurological adverse effects, 11 articles described direct injury to two branches of the trigeminal nerve following dental local anesthesia [46-55,101]. Involvement of the lingual nerve was reported more often than involvement of the inferior alveolar nerve [46,47]. One possible explanation for the more frequent injury to the lingual nerve is that deflection of this nerve is assumed to be impossible because of the tight stretching of the soft tissues when the mouth is opened widely for an injection [102]. Other possible explanations for trigeminal nerve injury are neurotoxicity, intraneural hematoma formation, or direct trauma from the anesthetic needle [53]. After administration of dental local anesthesia, paralysis of the facial and sympathetic nerves can also occur [56-61,103]. Facial paralysis may be delayed or immediate, based on the time between the injection and the beginning of the symptoms [104-105]. Immediate paralysis occurs when the branches of the facial nerve are directly anesthetized [106]. It has also been reported that reactivation of a latent viral infection, ischemic neuritis from arterial spasms, or breakdown products of anesthetic solutions may lead to delayed facial paralysis [57]. Finally, paralysis of sympathetic nerves may develop because of the administration of a stellate ganglion block [103].

Ten articles reported hypersensitivity reactions to anesthetic solutions, ranging from flushing and itching to respiratory distress and malaise [63-73]. Allergic reactions are divided into four subcategories and can be immediate (types I, II, and III) or delayed (type IV) [107]. In these events, the immune system overreacts abnormally to certain allergens or substances. Para-aminobenzoic acid, a metabolite, is a known allergen in ester anesthetics and leads to a higher occurrence of allergic reactions [108]. Therefore, amide local anesthetics are currently mostly used in dentistry and appear to be safer [109]. Another possible allergen, metabisulfite, may provoke allergic reactions and is used

as a preservative in local anesthetic solutions containing vasoconstrictors. However, the incidence of allergies to anesthetic solutions is <1%, and allergic reactions are rare [110]. Taking the patients' medical history is necessary to detect any previous allergies to anesthetic solutions. If an allergic reaction is suspected, skin tests should be performed by an allergist to confirm an allergy, and acceptable alternatives should be identified.

The reported allergic reactions disappeared within a few hours to a few days. If anaphylactic shock (type I hypersensitivity) occurs, dental treatment should be discontinued, and an intramuscular injection of epinephrine should be administered [111]. Patients experiencing anaphylactic shock should immediately be transferred to an emergency room.

Hematomas from local anesthetic injections have been reported in four articles [73-76]. Several large blood vessels and soft tissues are present in the pterygomandibular space, and hematomas may occur when an anesthetic needle punctures these tissues during an IANB. Bajkin et al. [73] found no signs of hematomas after an IANB in patients with an INR of 2-4 on anticoagulants. A possible explanation is that hematomas may be prevented by the vasoconstrictors in anesthetic solutions when a vessel is punctured. In another article describing patients with hemophilia, infiltration anesthesia appeared to be a safe technique [74]. These observations suggest that the administration of dental local anesthesia is safe in patients with hemophilia. If a hematoma following dental local injection occurs, the affected site should be treated with a cold compress. Furthermore, the authors of one study suggested that antibiotics should be prescribed to prevent infection of the hematoma [112].

Another reported adverse effect was breakage of dental anesthetic needles during the administration of dental local anesthesia. Modern disposable anesthetic needles are flexible, and needle breakage is rare. However, some factors may affect the occurrence of needle breakage. Needle bending before insertion or short and thin needles are factors associated with needle breakage. Bending of

needles leads to the activation of a breaking point and can trigger breakage [113]. When a needle is broken, needle fragments may migrate and damage deeper tissues [114]. Patients may also develop trismus, pain, infection, or life-threatening hematomas [78]. Therefore, removal of needle fragments is highly recommended. If simple removal of these fragments is not possible, patients should be referred to an oral and maxillofacial surgeon for the localization of fragments with radiographs and surgical removal of the fragments [77].

Accidental intra-arterial injection may lead to blanching [82,83] or trigger cardiovascular alterations [87]. Contact between the anesthetic needle and blood vessel or contraction of smooth muscles in the arterial wall can lead to transient ischemia [82]. As a result, decreased blood flow may lead to blanching of the skin at the injection site. This phenomenon disappears once the anesthesia wears off. However, adverse cardiovascular effects may develop because of the intravascular injection of anesthetic solutions containing vasoconstrictors. Neves et al. [115] compared anesthetic solutions with or without epinephrine and found no significant differences in heart rate, arrhythmias, or blood pressure in patients with cardiovascular compromise. A possible explanation for these cardiac alterations is the experience of fear, anxiety, or pain during dental treatment. These alterations could be mistaken for the adverse effects following intra-arterial injection. Regardless, aspiration prior to the administration of dental local anesthesia should be performed.

Ankylosis of the jaw following dental local anesthesia in patients suffering from fibrodysplasia ossificans progressiva has also been described. Fibrodysplasia ossificans progressiva is characterized by heterotopic bone formation and may lead to movement restrictions due to joint immobilization [116]. Exacerbation of this disease may be stimulated by injection trauma, but it can occur spontaneously [117]. Although fibrodysplasia ossificans progressiva has a low incidence, as a rule of thumb, it is important to administer atraumatic injections as much as possible, and caution is advised.

Because of misperceived or inadequate knowledge, many patients do not seek dental treatment during pregnancy, even when treatment is required or urgent [118]. Hagai et al. [86] conducted a cohort study of pregnancy-related adverse effects of local anesthetics and found no difference between exposed and unexposed patients. These findings are in accordance with the committee opinion of the American College of Obstetricians and Gynecologists [119] that dental treatment during pregnancy is safe and that immediate treatments leading to pain relief should be performed. To prevent misperceived knowledge, the general practitioner should inform pregnant patients about the safety of local anesthetics.

One major difficulty in conducting this review was the use of multiple different phrases in the literature when referring to the occurrence of undesired effects after administration of dental local anesthesia [120]. Therefore, all articles that considered the occurrence of undesired effects from dental local anesthesia as adverse effects were included. This broad definition can explain the relatively heterogeneous results in terms of incidence. The articles that considered physical reactions such as fist clenching and moaning as adverse effects reported high incidence rates. It is debatable whether these effects should be considered as true adverse effects, and these results could be interpreted as an overestimation. Second, details concerning the adverse effects were lacking in some articles; hence, some of the results were difficult to interpret, especially with regard to technical errors. In the current study, it was presumed that no technical errors occurred during the administration of local anesthetics, unless stated otherwise. The authors believe that technical errors may be underreported and that some adverse effects may be attributed to such errors. Future reports on adverse effects should contain at least the following information: technique of administration, educational level of the administrator (dentist/assistant), type of anesthetic used, dosage, intended dental treatment, and, preferably, detailed information about the provided solution and the duration of the effects.

Ocular adverse effects were reported most frequently and were found in 23 articles. However, the reported incidence of ocular adverse effects was only 0.07%–0.09% [43]. Other adverse effects, such as blanching, were described less frequently but had higher reported incidences. This review shows that frequently reported adverse effects in the clinic are underrepresented in the literature, necessitating further research in this field.

Finally, a relatively large number of articles were excluded because of the inaccessibility of their full texts, which may have led to the underreporting of certain adverse effects. However, the authors believe that given the broad extent of this literature review and its systematic approach, the results are meaningful and could serve as a highly informative overview for the general dentist regarding adverse effects following dental local anesthesia.

CONCLUSION

A review of the literature on adverse effects following dental local anesthesia was performed to provide an overview of the reported literature. A total of 78 articles on this topic were included, showing a wide variety of adverse effects. A total of 44 case reports and 14 case series were included, representing almost 75% of all papers. This illustrates that studies on this topic are very heterogeneous and, more importantly, that there is an absence of high-quality research available on this topic. In addition, it was found that systemically vital information concerning adverse effects, such as the dosage, type of anesthetic solution, or type of needle used, was frequently not reported in the paper. Finally, adverse effects that are rarely encountered in real-world general practice are overrepresented in the literature.

AUTHOR ORCID*s*

Jean-Pierre Ho: <https://orcid.org/0000-0001-8396-2501>
Tom C.T. van Riet: <https://orcid.org/0000-0001-8271-4821>
Youssef Afrian: <https://orcid.org/0000-0002-1498-0463>
Kevin T.H. Chin Jen Sem: <https://orcid.org/0000-0001-7092-5082>
René Spijker: <https://orcid.org/0000-0003-4445-1201>
Jan de Lange: <https://orcid.org/0000-0003-0096-8217>
Jerome Lindeboom: <https://orcid.org/0000-0001-8249-3774>

AUTHOR CONTRIBUTIONS

Jean-Pierre Ho: Conceptualization, Data curation, Project administration, Supervision
Tom C.T. van Riet: Conceptualization, Data curation, Formal analysis, Methodology, Writing - review & editing
Youssef Afrian: Conceptualization, Data curation, Formal analysis, Methodology, Writing - original draft
Kevin T.H. Chin Jen Sem: Conceptualization, Data curation, Formal analysis, Writing - original draft
René Spijker: Data curation, Formal analysis, Methodology
Jan de Lange: Conceptualization, Supervision, Writing - review & editing
Jerome Lindeboom: Conceptualization, Writing - original draft, Writing - review & editing

DECLARATION OF INTEREST: The authors have no conflicts of interest to declare.

REFERENCES

1. Malamed SF. Allergy and toxic reactions to local anesthetics. *Dent Today* 2003; 22: 114-6, 118-21.
2. Fink BR. Leaves and needles: the introduction of surgical local anesthesia. *Bull Anesth Hist* 2001; 19: 7-11.
3. Redman M. Cocaine: what is the Crack? a brief history of the use of cocaine as an anesthetic. *Anesth Pain Med* 2011; 1: 95-7.
4. Hall M. "Coca koller". The beginning of local anesthesia. *Anesth Prog* 1972; 19: 65-7.
5. López-Valverde A, de Vicente J, Martínez-Domínguez L, de Diego RG. Local anaesthesia through the action of cocaine, the oral mucosa and the Vienna group. *Br Dent J* 2014; 217: 41-3.
6. Singh P. An emphasis on the wide usage and important role of local anesthesia in dentistry: a strategic review. *Dent Res J* 2012; 9: 127-32.
7. López-Valverde A, De Vicente J, Cutando A. The surgeons Halsted and Hall, cocaine and the discovery of dental anaesthesia by nerve blocking. *Br Dent J* 2011; 211: 485-7.
8. Watt G. Hydrochlorate of Cocaine. *Am J Dent Sci* 1886; 19: 422-5.
9. Tobe M, Suto T, Saito S. The history and progress of local anesthesia: multiple approaches to elongate the action. *J Anesth* 2018; 32: 632-6.
10. Lieblich S. Providing anesthesia in the oral and maxillofacial surgery office: a look back, Where we are now and a look ahead. *J Oral Maxillofac Surg* 2018; 76: 917-25.
11. Grzybowski A. Cocaine and the eye: a historical overview. *Ophthalmologica* 2008; 222: 296-301.
12. Heavner JE. Local anesthetics. *Curr Opin Anaesthesiol* 2007; 20: 336-42.
13. Covino BG. Physiology and pharmacology of local anesthetic agents. *Anesth Prog* 1981; 28: 98-104.
14. Shandler L. Mechanism of action of local anesthetic. *J Am Dent Soc Anesthesiol* 1965; 12: 62-6.
15. Becker DE, Reed KL. Local anesthetics: review of pharmacological considerations. *Anesth Prog* 2012; 59: 90-101; quiz 102-3.
16. Giovannitti JA Jr, Rosenberg MB, Phero JC. Pharmacology of local anesthetics used in oral surgery. *Oral Maxillofac Surg Clin North Am* 2013;25:453-65, vi.
17. Golembiewski J. Local anesthetics. *J Perianesth Nurs* 2013; 28: 409-12.
18. Haas DA. An update on local anesthetics in dentistry. *J Can Dent Assoc* 2002; 68: 546-51.
19. Finder RL, Moore PA. Adverse drug reactions to local anesthesia. *Dent Clin North Am* 2002; 46: 747-57.
20. Smith MH, Lung KE. Nerve injuries after dental injection: a review of the literature. *J Can Dent Assoc* 2006; 72: 559-64.
21. Moher D, Liberati A, Tetzlaff J, Altman DG; PRISMA Group. Preferred reporting items for systematic reviews and meta-analyses: the PRISMA statement. *PLoS Med* 2009; 6: e1000097.

22. Ouzzani M, Hammady H, Fedorowicz Z, Elmagarmid A. Rayyan-a web and mobile app for systematic reviews. *Syst Rev* 2016; 5: 210.
23. Dogan EA, Dora B. Transient partial ophthalmoplegia and Horner's syndrome after intraoral local anesthesia. *J Clin Neurosci* 2005; 12: 696-7.
24. Blaxter PL, Britten MJ. Transient amaurosis after mandibular nerve block. *Br Med J* 1967; 1: 681.
25. Choi EH, Seo JY, Jung BY, Park W. Diplopia after inferior alveolar nerve block anesthesia: report of 2 cases and literature review. *Oral Surg Oral Med Oral Pathol Oral Radiol Endod* 2009; 107: e21-4.
26. Goldenberg AS. Diplopia resulting from a mandibular injection. *J Endod* 1983; 9: 261-2.
27. Kini YK, Kharkar VR, Kini AY. Transient diplopia with ipsilateral abducent nerve palsy and ptosis following a maxillary local anesthetic injection: a case report and review of literature. *Oral Maxillofac Surg* 2012; 16: 373-5.
28. Magliocca KR, Kessel NC, Cortright GW. Transient diplopia following maxillary local anesthetic injection. *Oral Surg Oral Med Oral Pathol Oral Radiol Endod* 2006; 101: 730-3.
29. Odabaşı O, Şahin O, Polat ME. Transient amaurosis and diplopia after inferior alveolar nerve block. *J Craniofac Surg* 2017; 28: e632-e4.
30. Seres L, Petho G, Peto Z, Peto T. A case of transient diplopia and ophthalmoplegia following dental anesthesia. *Niger J Clin Pract* 2019; 22: 1172-4.
31. Steenen SA, Dubois L, Saeed P, de Lange J. Ophthalmologic complications after intraoral local anesthesia: case report and review of literature. *Oral Surg Oral Med Oral Pathol Oral Radiol* 2012; 113: e1-5.
32. Chisci G, Chisci C, Chisci V, Chisci E. Ocular complications after posterior superior alveolar nerve block: a case of trochlear nerve palsy. *Int J Oral Maxillofac Surg* 2013; 42: 1562-5.
33. Kronman JH, Kabani S. The neuronal basis for diplopia following local anesthetic injections. *Oral Surg Oral Med Oral Pathol* 1984; 58: 533-4.
34. Wilkie GJ. Temporary uniocular blindness and ophthalmoplegia associated with a mandibular block injection. A case report. *Aust Dent J* 2000; 45: 131-3.
35. Hyams SW. Oculomotor palsy following dental anesthesia. *Arch Ophthalmol* 1976; 94: 1281-2.
36. Goldenberg AS. Transient diplopia from a posterior alveolar injection. *J Endod* 1990; 16: 550-1.
37. Pandey R, Dixit N, Dixit KK, Roy S, Gaba C. Amaurosis, an unusual complication secondary to inferior alveolar nerve anesthesia: a case report and literature review. *J Endod* 2018; 44: 1442-4.
38. Verma DK, Rajan R, Prabhu S. Ipsilateral, isolated amaurosis after inferior alveolar nerve block: report of two rare cases. *Oral Maxillofac Surg* 2013; 17: 73-5.
39. Williams JV, Williams LR, Colbert SD, Revington PJ. Amaurosis, ophthalmoplegia, ptosis, mydriasis and periorbital blanching following inferior alveolar nerve anaesthesia. *Oral Maxillofac Surg* 2011; 15: 67-70.
40. Ngeow WC, Shim CK, Chai WL. Transient loss of power of accommodation in 1 eye following inferior alveolar nerve block: report of 2 cases. *J Can Dent Assoc* 2006; 72: 927-31.
41. Uckan S, Cilasun U, Erkman O. Rare ocular and cutaneous complication of inferior alveolar nerve block. *J Oral Maxillofac Surg* 2006; 64: 719-21.
42. Rishiraj B, Epstein JB, Fine D, Nabi S, Wade NK. Permanent vision loss in one eye following administration of local anesthesia for a dental extraction. *Int J Oral Maxillofac Surg* 2005; 34: 220-3.
43. Peñarrocha-Diago M, Sanchis-Bielsa JM. Ophthalmologic complications after intraoral local anesthesia with articaine. *Oral Surg Oral Med Oral Pathol Oral Radiol Endod* 2000; 90: 21-4.
44. Prakasm M, Managutti A, Dolas RS, Agrawal MG. Temporary pupillary dilatation and ptosis: complications of PSA nerve block: a case report and review of literature. *J Maxillofac Oral Surg* 2009; 8: 181-3.
45. Zhang Q, Li Z, Zhao S. Difficulty in closing eyelid after local upper dental infiltration anaesthesia with articaine: case report. *Br J Oral Maxillofac Surg* 2016; 54: 713-4.
46. Hillerup S, Jensen R. Nerve injury caused by mandibular block analgesia. *Int J Oral Maxillofac Surg* 2006; 35: 437-43.
47. Garisto GA, Gaffen AS, Lawrence HP, Tenenbaum HC, Haas DA. Occurrence of paresthesia after dental local

- anesthetic administration in the United States. *J Am Dent Assoc* 2010; 141: 836-44.
48. Kingon A, Sambrook P, Goss A. Higher concentration local anaesthetics causing prolonged anaesthesia. Do they? a literature review and case reports. *Aust Dent J* 2011; 56: 348-51.
 49. Shenkman Z, Findler M, Lossos A, Barak S, Katz J. Permanent neurologic deficit after inferior alveolar nerve block: a case report. *Int J Oral Maxillofac Surg* 1996; 25: 381-2.
 50. Krafft TC, Hickel R. Clinical investigation into the incidence of direct damage to the lingual nerve caused by local anaesthesia. *J Craniomaxillofac Surg* 1994; 22: 294-6.
 51. Pogrel MA, Thamby S. Permanent nerve involvement resulting from inferior alveolar nerve blocks. *J Am Dent Assoc* 2000; 131: 901-7.
 52. Sambrook PJ, Goss AN. Severe adverse reactions to dental local anaesthetics: prolonged mandibular and lingual nerve anaesthesia. *Aust Dent J* 2011; 56: 154-9.
 53. Pogrel MA, Bryan J, Regezi J. Nerve damage associated with inferior alveolar nerve blocks. *J Am Dent Assoc* 1995; 126: 1150-5.
 54. Moorthy A, Stassen LF. The occurrence of paraesthesia of the maxillary division of the trigeminal nerve after dental local anaesthetic use: a case report. *J Ir Dent Assoc* 2015; 61: 34-5.
 55. Blair NF, Parratt JD, Garsia R, Brazier DH, Cremer PD. Inflammatory trigeminal nerve and tract lesions associated with inferior alveolar nerve anaesthesia. *J Clin Neurosci* 2013; 20: 1608-10.
 56. Tiwari IB, Keane T. Hemifacial palsy after inferior dental block for dental treatment. *Br Med J* 1970; 1: 798.
 57. Tzermpos FH, Cocos A, Kleftogiannis M, Zarakas M, Iatrou I. Transient delayed facial nerve palsy after inferior alveolar nerve block anesthesia. *Anesth Prog* 2012; 59: 22-7.
 58. Cakarer S, Can T, Cankaya B, Erdem MA, Yazici S, Ayintap E, et al. Peripheral facial nerve paralysis after upper third molar extraction. *J Craniofac Surg* 2010; 21: 1825-7.
 59. Baart JA, van Diermen DE, van Eijden TM. Transient paresis after mandibular block anaesthesia. *Ned Tijdschr Tandheelkd* 2006; 113: 418-20.
 60. Dorner BJ, Barker BC. A rare local anesthetic misadventure. Case report and anatomic considerations. *Oral Surg Oral Med Oral Pathol* 1976; 41: 300-8.
 61. Huang RY, Chen YJ, Fang WH, Mau LP, Shieh YS. Concomitant horner and harlequin syndromes after inferior alveolar nerve block anesthesia. *J Endod* 2013; 39: 1654-7.
 62. Sanchis JM, Peñarrocha M. Uvular paralysis after dental anesthesia. *J Oral Maxillofac Surg* 2002; 60: 1369-71.
 63. Wellins SL. Hypersensitivity to lidocaine hydrochloride. Report of a case. *Oral Surg Oral Med Oral Pathol* 1969; 28: 761-3.
 64. Campbell JR, Maestrello CL, Campbell RL. Allergic response to metabisulfite in lidocaine anesthetic solution. *Anesth Prog* 2001; 48: 21-6.
 65. Curley RK, Macfarlane AW, King CM. Contact sensitivity to the amide anesthetics lidocaine, prilocaine, and mepivacaine. Case report and review of the literature. *Arch Dermatol* 1986; 122: 924-6.
 66. Milam SB, Giovannitti JA, Bright D. Hypersensitivity to amide local anesthetics? Report of a case. *Oral Surg Oral Med Oral Pathol* 1983; 56: 593-6.
 67. El-Qutob D, Morales C, Peláez A. Allergic reaction caused by articaine. *Allergol Immunopathol (Madr)* 2005; 33: 115-6.
 68. He HX, Feng L, Liu HC. Allergic reaction in the use of primacaine adrenaline. *Postepy Dermatol Alergol* 2015; 32: 134-6.
 69. Malanin K, Kalimo K. Hypersensitivity to the local anesthetic articaine hydrochloride. *Anesth Prog* 1995; 42: 144-5.
 70. Bina B, Hersh EV, Hilario M, Alvarez K, McLaughlin B. True allergy to amide local anesthetics: a review and case presentation. *Anesth Prog* 2018; 65: 119-23.
 71. Ross NM. Serum-type allergic reactions to local anesthetic injections-report of two cases. *Anesth Prog* 1966; 13: 139-40.
 72. Schwartz HJ, Sher TH. Bisulfite sensitivity manifesting as allergy to local dental anesthesia. *J Allergy Clin Immunol* 1985; 75: 525-7.

73. Bajkin BV, Todorovic LM. Safety of local anaesthesia in dental patients taking oral anticoagulants: is it still controversial? *Br J Oral Maxillofac Surg* 2012; 50: 65-8.
74. Dougall A, Apperley O, Smith G, Madden L, Parkinson L, Daly B. Safety of buccal infiltration local anaesthesia for dental procedures. *Haemophilia* 2019; 25: 270-5.
75. Brodsky CD, Dower JS, Jr. Middle ear problems after a Gow-Gates injection. *J Am Dent Assoc* 2001; 132: 1420-4.
76. Srisurang S, Narit I, Prisana P. Clinical efficacy of lidocaine, mepivacaine, and articaine for local infiltration. *J Investig Clin Dent* 2011; 2: 23-8.
77. Pogrel MA. Broken local anesthetic needles: a case series of 16 patients, with recommendations. *J Am Dent Assoc* 2009; 140: 1517-22.
78. Zijderveld SA, Dubois L. Needle breakage during local anaesthesia. *Ned Tijdschr Tandheelkd* 2018; 125: 587-90.
79. Rahman N, Clarke M, Stassen LF. Case report: management of broken dental needles in practice. *J Ir Dent Assoc* 2013; 59: 241-5.
80. Woodmansey KF, White RK, He J. Osteonecrosis related to intraosseous anesthesia: report of a case. *J Endod* 2009; 35: 288-91.
81. Pattni N. Superficial skin necrosis and neurological complications following administration of local anaesthetic: a case report. *Aust Dent J* 2013; 58: 522-5.
82. Webber B, Orlansky H, Lipton C, Stevens M. Complications of an intra-arterial injection from an inferior alveolar nerve block. *J Am Dent Assoc* 2001; 132: 1702-4.
83. Scott JK, Moxham BJ, Downie IP. Upper lip blanching and diplopia associated with local anaesthesia of the inferior alveolar nerve. *Br Dent J* 2007; 202: 32-3.
84. Luchetti W, Cohen RB, Hahn GV, Rocke DM, Helpin M, Zasloff M, et al. Severe restriction in jaw movement after routine injection of local anesthetic in patients who have fibrodysplasia ossificans progressiva. *Oral Surg Oral Med Oral Pathol Oral Radiol Endod* 1996; 81: 21-5.
85. Barnard JD. Osteomyelitis of the jaws as a sequel to dental local anaesthetic injections. *Br J Oral Surg* 1976; 13: 264-70.
86. Hagai A, Diav-Citrin O, Shechtman S, Ornoy A. Pregnancy outcome after in utero exposure to local anesthetics as part of dental treatment: A prospective comparative cohort study. *J Am Dent Assoc* 2015; 146: 572-80.
87. Manani G, Facco E, Casiglia E, Cancian M, Zanette G. Isolated atrial fibrillation (IAF) after local anaesthesia with epinephrine in an anxious dental patient. *Br Dent J* 2008; 205: 539-41.
88. Martínez-Rodríguez N, Barona-Dorado C, Martín-Arés M, Cortés-Bretón-Brinkman J, Martínez-González JM. Evaluation of the anaesthetic properties and tolerance of 1:100,000 articaine versus 1:100,000 lidocaine. A comparative study in surgery of the lower third molar. *Med Oral Patol Oral Cir Bucal* 2012; 17: e345-51.
89. Peñarrocha-Oltra D, Ata-Ali J, Oltra-Moscardó MJ, Peñarrocha-Diago M, Peñarrocha M. Side effects and complications of intraosseous anesthesia and conventional oral anesthesia. *Med Oral Patol Oral Cir Bucal* 2012; 17: e430-4.
90. Kämmerer PW, Schneider D, Palarie V, Schiegnitz E, Daubländer M. Comparison of anesthetic efficacy of 2 and 4 % articaine in inferior alveolar nerve block for tooth extraction-a double-blinded randomized clinical trial. *Clin Oral Investig* 2017; 21: 397-403.
91. van der Bijl P, Victor AM. Adverse reactions associated with norepinephrine in dental local anesthesia. *Anesth Prog* 1992; 39: 87-9.
92. Zsigmond EK, Eilderton TE. Abnormal reaction to procaine and succinylcholine in a patient with inherited atypical plasma cholinesterase: case report. *Can Anaesth Soc J* 1968; 15: 498-500.
93. Brand HS, Bekker W, Baart JA. Complications of local anaesthesia. An observational study. *Int J Dent Hyg* 2009; 7: 270-2.
94. Daubländer M, Müller R, Lipp MD. The incidence of complications associated with local anesthesia in dentistry. *Anesth Prog* 1997; 44: 132-41.
95. Kaufman E, Goharian S, Katz Y. Adverse reactions triggered by dental local anesthetics: a clinical survey. *Anesth Prog* 2000; 47: 134-8.
96. Brand HS, te Veldhuis AH, Baart JA. Adverse effect of local anaesthetics. *Ned Tijdschr Tandheelkd* 2009; 116: 235-8.
97. Boynes S, Riley A, Milbee S. Evaluating complications

- during intraoral administration of local anesthetics in a rural, portable special needs dental clinic. *Spec Care Dentist* 2014; 34: 241-5.
98. Lustig JP, Zusman SP. Immediate complications of local anesthetic administered to 1,007 consecutive patients. *J Am Dent Assoc* 1999; 130: 496-9.
 99. Alamanos C, Raab P, Gamulescu A, Behr M. Ophthalmologic complications after administration of local anesthesia in dentistry: a systematic review. *Oral Surg Oral Med Oral Pathol Oral Radiol* 2016; 121: e39-50.
 100. Boynes SG, Echeverria Z, Abdulwahab M. Ocular complications associated with local anesthesia administration in dentistry. *Dent Clin North Am* 2010; 54: 677-86.
 101. Hillerup S, Jensen RH, Ersbøll BK. Trigeminal nerve injury associated with injection of local anesthetics: needle lesion or neurotoxicity? *J Am Dent Assoc* 2011; 142: 531-9.
 102. Ham SD, Durham TM. Incidence of lingual nerve trauma and postinjection complications in conventional mandibular block anesthesia. *J Am Dent Assoc* 1990; 121: 519-23.
 103. Campbell RL, Mercuri LG, Van Sickels J. Cervical sympathetic block following intraoral local anesthesia. *Oral Surg Oral Med Oral Pathol* 1979; 47: 223-6.
 104. Ling KC. Peripheral facial nerve paralysis after local dental anesthesia. *Oral Surg Oral Med Oral Pathol* 1985; 60: 23-4.
 105. Crean SJ, Powis A. Neurological complications of local anaesthetics in dentistry. *Dent Update* 1999; 26: 344-9.
 106. Bernsen PL. Peripheral facial nerve paralysis after local upper dental anaesthesia. *Eur Neurol* 1993; 33: 90-1.
 107. Canfield DW, Gage TW. A guideline to local anesthetic allergy testing. *Anesth Prog* 1987; 34: 157-63.
 108. Eggleston ST, Lush LW. Understanding allergic reactions to local anesthetics. *Ann Pharmacother* 1996; 30: 851-7.
 109. Moore PA, Hersh EV. Local anesthetics: pharmacology and toxicity. *Dent Clin North Am* 2010; 54: 587-99.
 110. Becker DE. Drug allergies and implications for dental practice. *Anesth Prog* 2013; 60: 188-97.
 111. Lieberman P, Nicklas RA, Oppenheimer J, Kemp SF, Lang DM, Bernstein DI, et al. The diagnosis and management of anaphylaxis practice parameter: 2010 update. *J Allergy Clin Immunol* 2010; 126: 477-80. e1-42.
 112. Biočić J, Brajdić D, Perić B, Đanić P, Salarić I, Macan D. A large cheek hematoma as a complication of local anesthesia: case report. *Acta Stomatol Croat* 2018; 52: 156-9.
 113. Augello M, von Jackowski J, Grätz KW, Jacobsen C. Needle breakage during local anesthesia in the oral cavity—a retrospective of the last 50 years with guidelines for treatment and prevention. *Clin Oral Investig* 2011; 15: 3-8.
 114. Casey JT, Lupo JE, Jenkins HA. Retained dental needle migration across the skull base to the cochlea presenting as hearing loss. *Otol Neurotol* 2015; 36: e42-5.
 115. Neves RS, Neves IL, Giorgi DM, Grupi CJ, César LA, Hueb W, et al. Effects of epinephrine in local dental anesthesia in patients with coronary artery disease. *Arq Bras Cardiol* 2007; 88: 545-51.
 116. Rogers JG, Geho WB. Fibrodysplasia ossificans progressiva. A survey of forty-two cases. *J Bone Joint Surg Am* 1979; 61: 909-14.
 117. Cohen RB, Hahn GV, Tabas JA, Peeper J, Levitz CL, Sando A, et al. The natural history of heterotopic ossification in patients who have fibrodysplasia ossificans progressiva. A study of forty-four patients. *J Bone Joint Surg Am* 1993; 75: 215-9.
 118. Steinberg BJ, Hilton IV, Iida H, Samelson R. Oral health and dental care during pregnancy. *Dent Clin North Am* 2013; 57: 195-210.
 119. Committee Opinion No. 569: oral health care during pregnancy and through the lifespan. *Obstet Gynecol* 2013; 122: 417-22.
 120. Loke YK, Price D, Herxheimer A; Cochrane Adverse Effects Methods Group. Systematic reviews of adverse effects: framework for a structured approach. *BMC Med Res Methodol* 2007; 7: 32.