

# ABC of flexible cystoscopy for junior trainee and general practitioner

Nourdin Kadi  
Pravin Menezes

Urology Department, Sunderland  
Royal Hospital, Sunderland, England,  
UK

**Introduction:** Flexible cystoscopy is a diagnostic procedure usually performed under local anesthesia and has been used in the outpatient setting since the 1980s.

**Methods:** We performed an electronic search of MEDLINE® and the Cochrane Central Search Library between 1990 and 2010. Duplicate references were removed. One reviewer extracted the publications relevant to general clinical practice.

**Results:** MEDLINE search using the MeSH (Medical Subject Headings) words “flexible” and “cystoscopy” revealed 274 titles, and there were 42 titles in the Cochrane Central Search Library. However, interestingly, only 13 published papers addressing the clinical practice of flexible cystoscopy in the English literature were identified.

**Conclusions:** Flexible cystoscopy is a real revolution in the field of diagnostic urology.

**Keywords:** clinical practice, urology, fiberscope, urethroscopy

## Introduction

The early suggestion of use of fiberscope urethroscopy was by Marshall in 1964.<sup>1</sup> The first use of the fiberscope in urology was by Tsuchida and Sugawara in 1973<sup>2</sup> to examine the bladder neck.<sup>3-5</sup> Nevertheless, the regular use of the fiberscope in urology was in the first few years of the 1980s.<sup>6,7</sup>

Few authors thought at the time that the fiberscope would replace the rigid scope; however, we should mention that the fiberscope has its limitations, especially in heavy bleeding, as it is usually not possible to identify the ureteric orifices.<sup>8,9</sup>

## Methods

We performed an electronic search of MEDLINE® and the Cochrane Central Search Library between 1990 and 2010. We retrieved citations using combinations of the search term “flexible” and “cystoscopy.” For MEDLINE, we limited the search to the English language, using the limits function.

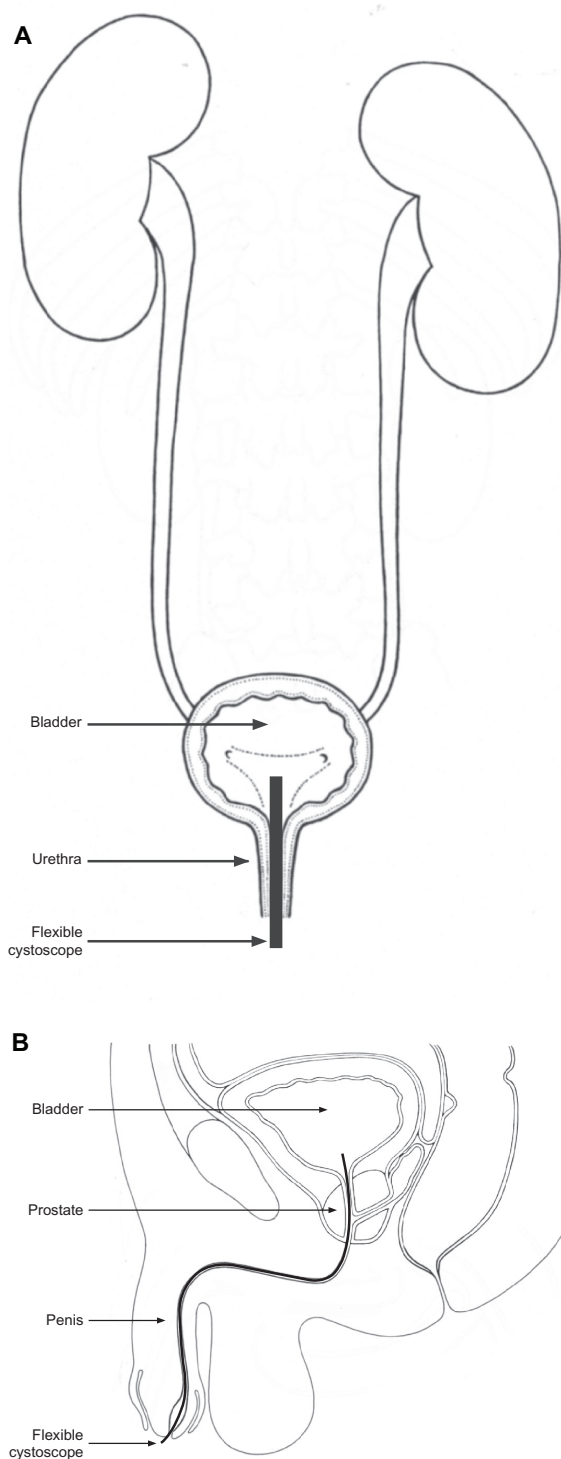
The search was done in the Cochrane Central Search Library using “flexible cystoscopy.” Duplicate references were removed.

One reviewer (NK) extracted from these data the relevant publications to clinical practice. Data were characterized in the following categories: indication, procedure, complications, and the need for prophylaxis antibiotic before flexible cystoscopy.

## Results

The MEDLINE search between 1990 and 2010 with limited search to the English language revealed 274 titles, while the Cochrane Central Search Library search for “flexible cystoscopy” revealed 42 results.

Correspondence: Nourdin Kadi  
5 Melton Court, Derby, England  
DE22 3EB, UK  
Tel +44 191 565 6256  
Fax +44 191 514 0220  
Email [nourdin@hotmail.co.uk](mailto:nourdin@hotmail.co.uk)



**Figure 1** Cystoscopy. (A) Female. (B) Male.

Interestingly, only 13 articles were directly relevant to clinical practice. From these articles, there was one prospective randomized study regarding instillation of anesthetic gel necessary in flexible cystoscopy examination, one randomized double-blind controlled trial regarding the need

**Table 1** The main relevant articles

Authors	Journal	Year of publication
Grasso et al <sup>11</sup>	<i>J Endourol</i>	1993
Beagler and Grasso <sup>12</sup>	<i>Urology</i>	1994
Kraklau and Wolf <sup>20</sup>	<i>Tech Urol</i>	1999
Wedderburn et al <sup>13</sup>	<i>J Urol</i>	1999
Almallah et al <sup>16</sup>	<i>Urology</i>	2000
Rané et al <sup>21</sup>	<i>Eur Urol</i>	2001
Burke et al <sup>17</sup>	<i>BJU Int</i>	2002
Kobayashi et al <sup>18</sup>	<i>Urology</i>	2003
Kumar et al <sup>10</sup>	<i>Urol Int</i>	2004
Wilson et al <sup>22</sup>	<i>J Endourol</i>	2005
Cohen et al <sup>14</sup>	<i>J Urol</i>	2007
Richey et al <sup>23</sup>	<i>BMJ</i>	2008
Patel et al <sup>19</sup>	<i>J Urol</i>	2008

of prophylaxis antibiotic for flexible cystoscopy, and one meta-analysis of prospective randomized controlled trials regarding the use of local anesthetic gel versus plain lubricating gel for pain reduction during flexible cystoscopy. The main relevant articles are shown in Table 1.

## Discussion

Interestingly, the search of the recent published literature revealed few articles that address the clinical practice of flexible cystoscopy. We categorized the data into the following categories.

### The common indication of flexible cystoscopy

Flexible cystoscopy is used mainly to investigate patients presenting with microscopic hematuria and frank hematuria, recurrent urinary tract infections, irritative lower urinary tract symptoms, and for follow up (surveillance) of bladder tumors.<sup>11</sup>

Other indications for flexible cystoscopy include removal of JJ ureteric stents and insertion of urethral catheter over a guidewire (in cases of difficult urethral catheterization). Flexible cystoscopy can also be used to get bladder biopsies and to treat small low-grade superficial bladder cancers using diathermy (cystodiathermy).

More recently, flexible cystoscopy has been used for intradetrusor injection of botulinum toxin under local anesthetic. However, the commonest indication for flexible cystoscopy remains its role in the follow up (surveillance) of bladder tumors.<sup>11–14</sup>

### Procedure

Flexible cystoscopy should be carried out after obtaining informed consent; we recommend using the British

Association of Urological Surgeons consent form.<sup>15</sup> The published literature also recommend a urinalysis before the procedure to exclude active urinary tract infection, which is a relative contraindication because of the small risk of septicemia.<sup>16,17</sup>

Following preparation of the genitalia using antiseptic solution, the area is covered with sterile drapes. Local anesthetic is slowly instilled into the male urethra; female urethra simply requires lubrication.<sup>18,19</sup>

The scope is then gently advanced through the urethra in aseptic technique. The urethra is inspected along its length for any abnormalities such as strictures (narrowing), false passages, and growths. The bladder is then filled with sterile liquid (water, saline, or glycine solution) until the mucosal folds open up. The bladder is then carefully inspected in a systematic manner. This involves inspection of all the walls of the bladder, as well as both ureteric orifices. The bladder neck is examined by performing the J maneuver with the scope. Once the inspection has been fully carried out, the scope is gently withdrawn to examine the urethra on the way out as well.

## Complications

Flexible cystoscopy is generally considered safe. The complications include pain on voiding (dysuria) (50%), hematuria (19%), and frequency (37%), all of which are usually self-limiting. The risk of urinary tract infection post flexible cystoscopy is approximately 2.7%.<sup>17</sup>

To reduce the potential severe complications after flexible cystoscopy, patients are advised to increase their fluid intake post-procedure and to seek medical help if they feel unwell with increasing pain on voiding (dysuria), rigors, or fever.

## Do we need prophylaxis antibiotic before flexible cystoscopy?

The use of prophylaxis antibiotic before flexible cystoscopy is very controversial.<sup>20-22</sup> In the UK, there is no guideline for the use of prophylactic antibiotic before flexible cystoscopy, and each hospital follows its own protocol. There is not enough evidence to support the routine use of prophylactic antibiotic before flexible cystoscopy; however, it should be considered in immunocompromised patients or those with suspected urinary tract infections.

NICE (National Institute for Health and Clinical Excellence) guidelines no longer recommend the routine use of prophylactic antibiotic for patients with artificial

heart valves.<sup>23</sup> If prophylaxis is used, the choice, route of administration, and duration of use of antibiotic should be based on local microbiological advice.

## Conclusion

Flexible cystoscopy can be done under local anesthesia in the outpatient setting, and thus it has revolutionized the field of diagnostic urology procedures.

## Disclosure

The authors report no conflicts of interest in this work.

## References

1. Marshall VF. Fiberoptics in urology. *J Urol.* 1964;91:110-114.
2. Tsuchida S, Sugawara H. A new flexible fibercystoscope for visualization of the bladder neck. *J Urol.* 1973;109:830-831.
3. Snyder JA, Smith AD. Supine flexible cystoscopy. *J Urol.* 1986;135:251-253.
4. Fowler OG, Badenoch DF, Thakar DR. Practical experience with flexible fibroscope cystoscopy in outpatients. *Br J Urol.* 1984;56:618-621.
5. Wilbur HJ. The flexible choledochoscope, a welcome addition to the urologic armamentarium. *J Urol.* 1981;126:380-381.
6. Fowler CG. Fibroscope urethroscopy. *Br J Urol.* 1984;56:304-307.
7. Fowler CG. Fibroscopes in urology. *Br J Hosp Med.* 1984;32:202-205.
8. Dayman RV, Reddy P, Lange PH. Flexible fiberoptic and rigidrod lens endoscopy of the lower urinary tract: a prospective controlled comparison. *J Urol.* 1984;131:715.
9. Webb DR, Butler MR, Fitzpatrick JM. Flexible cystourethroscopy: advantages and limitations. *Eur Urol.* 1984;10:336-337.
10. Kumar V, Patel HR, Nathan SM, Miller RA, Lawson AH. Do we need to perform cystoscopy on all adults attending urology centres as outpatients? *Urol Int.* 2004;73(3):198-200; discussion 200.
11. Grasso M, Beagler M, Bagley DH, Strup S. Actively deflectable, flexible cystoscopes: no longer solely a diagnostic instrument. *J Endourol.* 1993;7(6):527-530.
12. Beagler M, Grasso M 3rd. Flexible cystoscopic bladder biopsies: a technique for outpatient evaluation of the lower urinary tract urothelium. *Urology.* 1994;44(5):756-759.
13. Wedderburn AW, Ratan P, Birch BR. A prospective trial of flexible cystodiathermy for recurrent transitional cell carcinoma of the bladder. *J Urol.* 1999;161(3):812-814.
14. Cohen BL, Rivera R, Barboglio P, Gousse A. Safety and tolerability of sedation-free flexible cystoscopy for intradetrusor botulinum toxin-A injection. *J Urol.* 2007;177(3):1006-1010; discussion 1010.
15. The British Association of Urological Surgeons. <http://www.baus.org.uk>. Accessed May 7, 2011.
16. Almallah YZ, Rennie CD, Stone J, Lancashire MJ. Urinary tract infection and patient satisfaction after flexible cystoscopy and urodynamic evaluation. *Urology.* 2000;56(1):37-39.
17. Burke DM, Shackley DC, O'Reilly PH. The community-based morbidity of flexible cystoscopy. *BJU Int.* 2002;89(4):347-349.
18. Kobayashi T, Nishizawa K, Ogura K. Is instillation of anesthetic gel necessary in flexible cystoscopic examination? A prospective randomized study. *Urology.* 2003;61(1):65-68.
19. Patel AR, Jones JS, Babineau D. Lidocaine 2% gel versus plain lubricating gel for pain reduction during flexible cystoscopy: a meta-analysis of prospective, randomized, controlled trials. *J Urol.* 2008;179(3):986-990.
20. Kraklau DM, Wolf JS Jr. Review of antibiotic prophylaxis recommendations for office-based urologic procedures. *Tech Urol.* 1999;5(3):123-128.

21. Rané A, Cahill D, Saleemi A, Montgomery B, Palfrey E. The issue of prophylactic antibiotics prior to flexible cystoscopy. *Eur Urol*. 2001; 39(2):212–214.
22. Wilson L, Ryan J, Thelning C, Masters J, Tuckey J. Is antibiotic prophylaxis required for flexible cystoscopy? A truncated randomized double-blind controlled trial. *J Endourol*. 2005;19(8):1006–1008.
23. Richey R, Wray D, Stokes T. Guideline Development Group. Prophylaxis against infective endocarditis: summary of NICE guidance. *BMJ*. 2008;336(7647):770–771.

### International Journal of General Medicine

Dovepress

#### Publish your work in this journal

The International Journal of General Medicine is an international, peer-reviewed open-access journal that focuses on general and internal medicine, pathogenesis, epidemiology, diagnosis, monitoring and treatment protocols. The journal is characterized by the rapid reporting of reviews, original research and clinical studies across all disease areas.

A key focus is the elucidation of disease processes and management protocols resulting in improved outcomes for the patient. The manuscript management system is completely online and includes a very quick and fair peer-review system. Visit <http://www.dovepress.com/testimonials.php> to read real quotes from published authors.

Submit your manuscript here: <http://www.dovepress.com/international-journal-of-general-medicine-journal>