

Case Report

Bilateral Adduction Palsy in a Patient with Myotonic Dystrophy Type 1

Hong-Jeon Kim, Jung-Hwan Oh and Sa-Yoon Kang*

Department of Neurology, Jeju National University School of Medicine, Jeju 63241, Korea

Myotonic dystrophy type 1 (DM1) is caused by CTG repeat expansion in the *DMPK* gene in chromosome 19q13.3. External ophthalmoplegia is a rare manifestation in DM1. We report a DM1 patient confirmed by the presence of 650 CTG triplet expansions in the *DMPK* gene and had limitation of adduction gaze bilaterally. Brain MRI showed bilateral medial rectus muscles atrophy. Our patient provides additional evidence of ocular motor muscle involvement in DM1.

Key words: Atrophy, MRI, Myotonia, Myotonic dystrophy, Ophthalmoplegia

INTRODUCTION

Myotonic dystrophy type 1 (DM1) is autosomal dominant, multisystemic diseases with a core pattern of clinical presentation including myotonia, muscular dystrophy, cardiac conduction defects, posterior iridescent cataracts, cerebral involvement and endocrine disorders. DM1 is caused by the expansion of an unstable trinucleotide (CTG) repeats in the 3' untranslated region of the myotonin protein kinase (*DMPK*) gene on chromosome 19q13.3 [1].

The extraocular muscles differ from other striated skeletal muscles in terms of motor receptors and motor control. Different extraocular muscles are known to be involved in various disorders such as myasthenia gravis, mitochondrial myopathies and thyroid-associated myopathy [2]. DM1 is rarely associated with external ophthalmoplegia. We report a patient with DM1 who developed unusual ophthalmologic feature showing bilateral adduction

weakness.

CASE REPORT

A 49-year-old man was referred with dysarthria and gait disturbance. At age 30 years, he recognized upper limb weakness and dysarthria. At age 45, gait difficulty was recognized. These symptoms have progressed slowly, and he was unable to walk alone at age 48. His mother and maternal uncle showed dysarthria and gait disturbance, which were almost similar to his clinical symptoms. On neurologic examination, he showed a characteristic facial appearance with frontal baldness, bilateral ptosis, and long lean face. He had percussion myotonia of the thenar eminence, but grip myotonia was absent. Muscle weakness and wasting was observed in all four limbs, more marked in upper limbs. Motor power of upper extremity was Medical Research Council (MRC) grade 3 in flexor carpi ulnaris, extensor carpi radialis and abductor pollicis brevis muscles and lower extremity was MRC grade 4. There was an apparent limitation of horizontal gaze characterized by bilateral adduction weakness and exotropia of both eyes (Fig. 1A). However, there was no dissociated horizontal nystagmus on lateral gaze and abnormality of vertical eye movements. The ophthalmoplegia was not overcome by

Received March 24, 2016, Revised May 13, 2016,
Accepted May 15, 2016

*To whom correspondence should be addressed.
TEL: 82-64-754-8175, FAX: 82-64-717-1630
e-mail: neurokang@jejunu.ac.kr

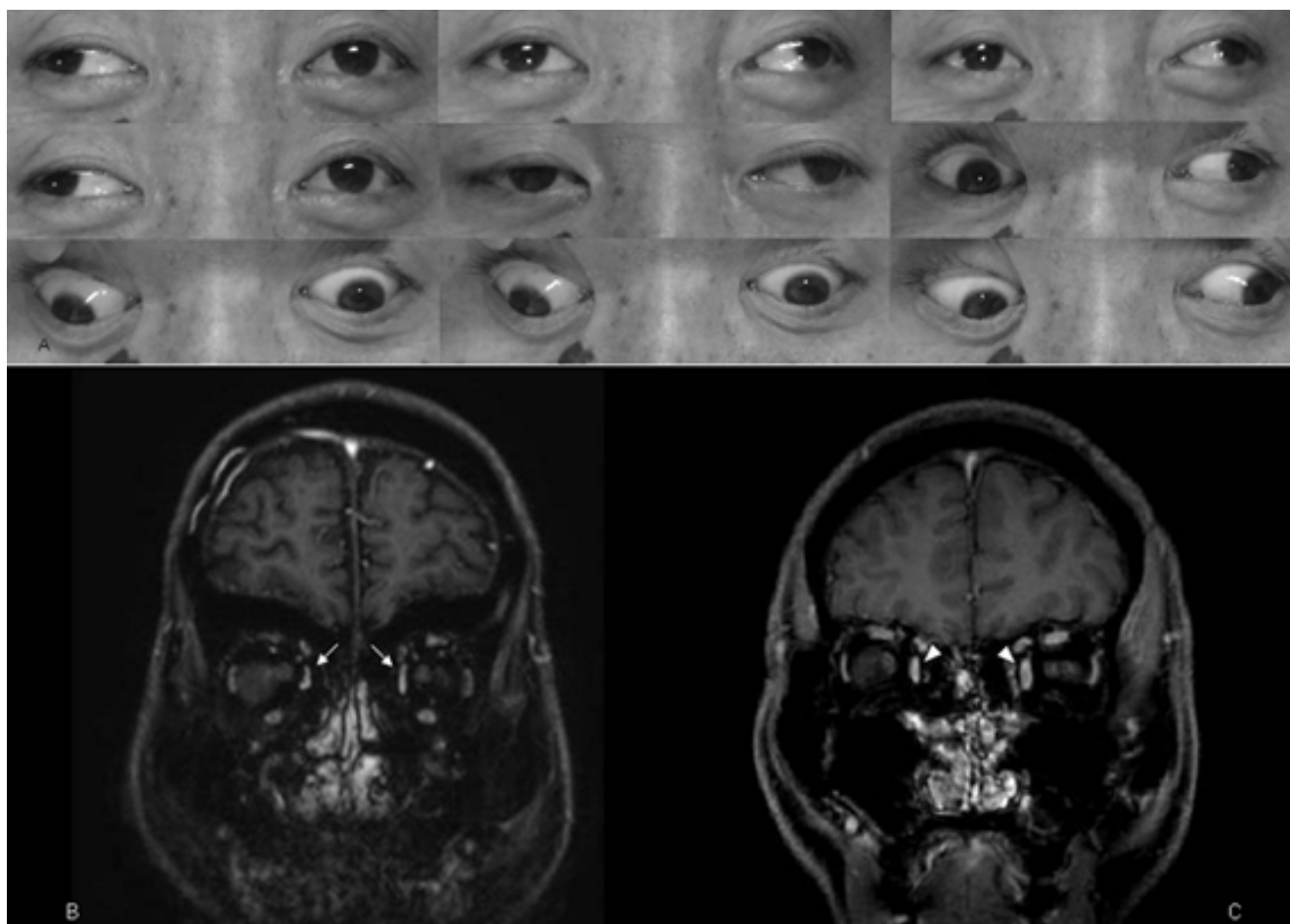


Fig. 1. Ocular motor examination of patient shows limitation of adduction gaze bilaterally (A). Brain T1-weighted coronal MRI in (B) myotonic dystrophy patient and (C) age-matched healthy control subject. MRI shows the small and thin extraocular muscles bilaterally comparing with healthy subject (arrow head), especially prominent in medial rectus muscles (arrow).

oculocephalic maneuver and he did not complain diplopia. On slit lamp examination, a bilateral cataract was noted. EMG revealed typical myotonic discharges. Brain MRI showed no responsible lesion for ophthalmoplegia except bilateral extraocular muscles atrophy, especially prominent in medial rectus muscles (Fig. 1B). The muscle biopsy performed in deltoid muscle demonstrated nonspecific myopathic changes including atrophy of type I fibers, but did not show the ragged-red fibers, rimmed vacuole, and central nuclei consistent with congenital myopathies. Repetitive nerve stimulation test was normal. Anti-acetylcholine receptor and anti-MuSK antibodies were not detected. The result of thyroid function test, serum glucose and creatine kinase (CK 109 IU/L) were normal. Electrocardiography showed sinus rhythm with first degree atrioventricular block, but echocardiography was unremarkable. We performed genetic testing for DM1 and PABPN1 gene. The diagnosis for myotonic dystrophy type 1 was confirmed by the presence of 650 CTG triplet expansion in the

DMPK gene on chromosome 19q 13.3.

DISCUSSION

The core features in classic DM1 are distal muscle weakness, leading to difficulty with performing tasks requiring fine dexterity of the hands and foot drop, and facial weakness and wasting, giving rise to ptosis and the typical hatchet appearance. A reliable feature of the eye involvement is the presence of iridescent posterior subcapsular cataracts that are identifiable by slit lamp examination in almost all adult patients [1]. In addition to cataracts, DM1 has been associated with ptosis, slow saccades, and decreased intraocular pressure, with both central and peripheral mechanisms proposed for the eye movement abnormalities [3,4]. Regarding ocular muscle functions in DM1, ptosis is the most described deficit. Strabismus, vergence deficits, smooth pursuit movement with catch-up saccades and slow saccadic eye

movement have also been described in adult DM1 patients. The relative sparing of extraocular muscles is well known in DM1 [5]. Frank ophthalmoplegia is extremely rare in DM1 and not observed in myotonic dystrophy type 2. External ophthalmoplegia is present in some severe cases like congenital form [6-8]. However, it is not relevant that our patient appears to have a congenital form of DM1, given its onset age and severity.

The extraocular muscles have a number of structural and functional properties that distinguish them from skeletal and cardiac muscles. These differences may be important in the preferential involvement of extraocular muscles in some disease states, and their sparing in others [9]. The presence or absence of external ophthalmoplegia is therefore useful in formulating the differential diagnosis of neuromuscular disorders. The representative disorders associated with external ophthalmoplegia include progressive external ophthalmoplegia, oculopharyngeal muscular dystrophy, and myasthenia gravis. They can usually be distinguished on the basis of clinical characteristics and laboratory investigations. In our patient, these disorders are differentiated as assumptive diagnoses. There is no evidence of ragged red fibers, rimmed vacuole and centronuclear feature on muscle biopsy. Anti-acetylcholine receptor and anti-MuSK antibodies were not detected and no significant response to neostigmine was demonstrated.

Brain MRI of the patient showed small, atrophic extraocular muscles as compared with that obtained from the age-matched healthy volunteer, among them medial rectus muscles revealed more prominent atrophic change. These findings confirm the pathologic relevance of extraocular muscle atrophy for ophthalmoplegia found in our patient. The histological features of muscle biopsy in DM1 are characterized by muscle fiber atrophy, bags of myonuclei, and ring and split fibers, though not pathognomonic. In DM1, type I muscle fibers are predominantly affected [1]. There is a moderate correlation between longer CTG repeat expansions and an earlier age of onset and more severe disease. However, phenotype cannot be accurately predicted based solely on the number of repeats. This is especially true when the number of repeats is beyond 600 in DM1 [10]. We report on a 49-year-old man in whom ophthalmoplegia was the neuromuscular manifestation of DM1 and MRI revealed atrophic extraocular muscles. This case provides additional evidence of

oculomotor muscle involvement in DM1. Therefore, DM1 should be considered in patient with unexplained ophthalmoplegia of muscle origin.

REFERENCES

1. Turner C, Hilton-Jones D (2014) Myotonic dystrophy: diagnosis, management and new therapies. *Curr Opin Neurol* 27:599-606.
2. Jones KJ, North KN (1997) External ophthalmoplegia in neuromuscular disorders: case report and review of the literature. *Neuromuscul Disord* 7:143-151.
3. Shaunak S, Orrell R, Henderson L, Kennard C (1999) Saccades and smooth pursuit in myotonic dystrophy. *J Neurol* 246:600-606.
4. Versino M, Romani A, Bergamaschi R, Callieco R, Scolari S, Poli R, Lanfranchi S, Sandrini G, Cosi V (1998) Eye movement abnormalities in myotonic dystrophy. *Electroencephalogr Clin Neurophysiol* 109:184-190.
5. Di Costanzo A, Toriello A, Mottola A, Di Iorio G, Bonavita V, Tedeschi G (1997) Relative sparing of extraocular muscles in myotonic dystrophy: an electrooculographic study. *Acta Neurol Scand* 95:158-163.
6. Thiriez C, Vignal C, Papeix C, Yaici S, Vidailhet M, Roze E (2010) Ophthalmoplegia as the presenting muscle-related manifestation of myotonic dystrophy. *Rev Neurol (Paris)* 166:538-541.
7. Lessell S, Coppeto J, Samet S (1971) Ophthalmoplegia in myotonic dystrophy. *Am J Ophthalmol* 71:1231-1235.
8. Yamashita T, Matsubara E, Nagano I, Shoji M, Abe K (2004) Bilateral extraocular muscle atrophy in myotonic dystrophy type 1. *Neurology* 63:759-760.
9. Kaminski HJ, Richmonds CR, Kusner LL, Mitsumoto H (2002) Differential susceptibility of the ocular motor system to disease. *Ann NY Acad Sci* 956:42-54.
10. Harley HG, Rundle SA, MacMillan JC, Myring J, Brook JD, Crow S, Reardon W, Fenton I, Shaw DJ, Harper PS (1993) Size of the unstable CTG repeat sequence in relation to phenotype and parental transmission in myotonic dystrophy. *Am J Hum Genet* 52:1164-1174.