



Reconstruction Guide for the Measurement of Segmental Labral Insufficiency: An Alternative Technique for Acetabular Labral Reconstruction

Thomas Alter, B.S., Edward C. Beck, M.P.H., Nabil Mehta, M.D.,
Jourdan M. Cancienne, M.D., Sara Sarmast, P.A., Joseph N. Liu, M.D., and
Shane J. Nho, M.D., M.S.

Abstract: The acetabular labrum is a dynamic structure important for both hip stability and functional motion. Given its importance, injuries to the labrum result in significant symptomatic dysfunction caused by altered hip kinematics. Although labral repair represents the standard for symptomatic labral tears with underlying bony deformity, complex labral tears or those with significant degeneration may not be amenable to repair and require labral reconstruction. Labral reconstruction has been shown to restore intra-articular fluid pressurization to levels similar to those in the intact state, and cohort studies have increasingly demonstrated significant improvement in patient-reported outcomes at midterm follow-up. A critical component of successful labral reconstruction is accurate measurement of the graft length to restore native anatomy and kinematics of the hip. The purpose of this Technical Note is to describe a way to accurately measure graft length required for labral reconstruction.

Acetabular labral tears are increasingly diagnosed because of advances in imaging and arthroscopic techniques and represent a common cause of hip pain, particularly in young, active individuals with femoroacetabular impingement syndrome.¹ The acetabular labrum plays a critical role in preserving articular cartilage and hip joint stability by reducing femoroacetabular joint contact pressures, ensuring a negative intra-articular pressure and suction seal, and providing a wider coverage of the femoral head.²⁻⁴ Labral injuries and deficiency lead to an imbalance of hip kinematics and accelerated degenerative changes

within the hip joint.⁵ Given the functional importance of the labrum to the long-term health of the hip, labral repair has become the gold standard for symptomatic labral pathology.⁶ However, certain labral pathologies with severe degeneration, as in the setting of an ossified labrum, described in this Technical Note, preclude repair and necessitate a labral reconstruction. Ongoing research has shown that successful labral reconstruction results in restored hip stability and suction seal similar to those in an intact state, and cohort studies have revealed significant improvement in patient-reported outcomes at midterm follow-up.⁷⁻¹⁰ A critical component of labral reconstruction is accurately matching the graft length to the patient's native anatomy.¹¹ Mismatch between graft length and acetabular rim size can cause the graft to be overconstrained or too loose, making fixation more challenging and possibly compromising the suction seal between the graft and the femoral head.¹¹ The purpose of this Technical Note is to describe a method to measure intra-articular graft length during labral reconstruction.

From the Section of Young Adult Hip Surgery, Division of Sports Medicine, Department of Orthopedic Surgery, Rush University Medical Center (T.A., E.C.B., N.M., J.M.C., S.S., S.J.N.), Chicago, Illinois, U.S.A.; the Department of Orthopedic Surgery, Loma Linda University Medical Center (J.N.L.), Loma Linda, California, U.S.A.

The authors report no conflicts of interest in the authorship and publication of this article. Full ICMJE author disclosure forms are available for this article online, as [supplementary material](#).

Received August 31, 2018; accepted October 24, 2018.

Address correspondence to Shane J. Nho, M.D., M.S., Department of Orthopaedics, Rush University Medical Center, 1611 W Harrison St, Ste 300, Chicago, IL 60612, U.S.A. E-mail: ebeck1@uic.edu

© 2018 by the Arthroscopy Association of North America. Published by Elsevier. This is an open access article under the CC BY-NC-ND license (<http://creativecommons.org/licenses/by-nc-nd/4.0/>).

2212-6287/181087

<https://doi.org/10.1016/j.eats.2018.10.017>

Surgical Technique

Our preferred surgical technique using the Superior Capsule Reconstruction (SCR) Guide (Arthrex, Naples, FL) can be seen in detail in [Video 1](#). Pearls and pitfalls associated with this technique are noted in [Table 1](#).

Table 1. Pearls and Pitfalls

- Pathologic labrum should be resected until healthy tissue with stable margins is observed.
- A burr should be used to prepare a fresh, bleeding bony surface on the acetabulum to enhance healing of the graft.
- Careful and accurate placement of the initial posterolateral anchor is required because it will serve as the initial measuring point for the remainder of the graft.
- A suture manipulator should be used to trace the acetabular rim with the measuring suture for accurate graft length estimation and anchor placement.

Patient Positioning

The patient is placed supine on a traction table, and general anesthesia is induced for complete muscle relaxation. The patient is then positioned on the table (Smith & Nephew, Memphis, TN) with a well-padded perineal post and boots. The pelvis is slightly translated toward the contralateral, nonoperative hip, and gentle distraction is applied across the this limb. The operative limb is then placed in 20° of abduction and 20° of flexion, and manual distraction is applied. Gentle oscillations are then used as the limb is slowly extended and adducted to obtain distraction up to 10 mm. The optimal position for the hip during this procedure is neutral adduction, extension of the extremity parallel to the floor, and internal rotation of 45° for maximal femoral neck length.

Arthroscopic Technique

After sterile preparation and patient draping have been completed, the anterior superior iliac spine is marked, and a vertical line is extended down the thigh toward the center of the patella. The greater trochanter is then outlined. The anterolateral (AL) portal is first established under fluoroscopic visualization,

penetrating the capsule at the 12 o'clock position. Standard cannulation allows for intra-articular visualization with a 70° arthroscope (Smith & Nephew). Under direct visualization, the anterior portal is then created at the 2 o'clock position as close as possible to the AL portal to minimize the size of the interportal capsulotomy. The arthroscope is then switched to the anterior portal to view the position of the AL portal and ensure that it is in adequate position, and once an adequate position is confirmed, a standard interportal capsulotomy is performed. The camera is then switched back to the AL portal and the capsulotomy is completed. A diagnostic arthroscopy is performed to evaluate the status of the labrum and any concomitant intra-articular pathology. The capsulolabral recess is then reflected, and the labrum and pincer deformity are visualized.

Acetabular Preparation and Anchor Placement

After confirmation of a nonsalvageable labrum, an arthroscopic shaver device is used to resect the degenerated labrum and any redundant capsule, leaving behind any remaining healthy labrum. In the case presented, the patient had an ossified, nonrepairable labrum and was a candidate for labral reconstruction after labral resection (Fig 1). The labrum is then completely resected using a combination of arthroscopic baskets and shavers. A 5.5-mm arthroscopic burr is then used to address the pincer morphology and create a healthy bleeding bony bed along the acetabular rim in preparation for graft placement. During viewing from the midanterior portal, the burr is used through the anterolateral portal down to the posterior border of the transverse acetabular ligament. Once this is complete, the camera

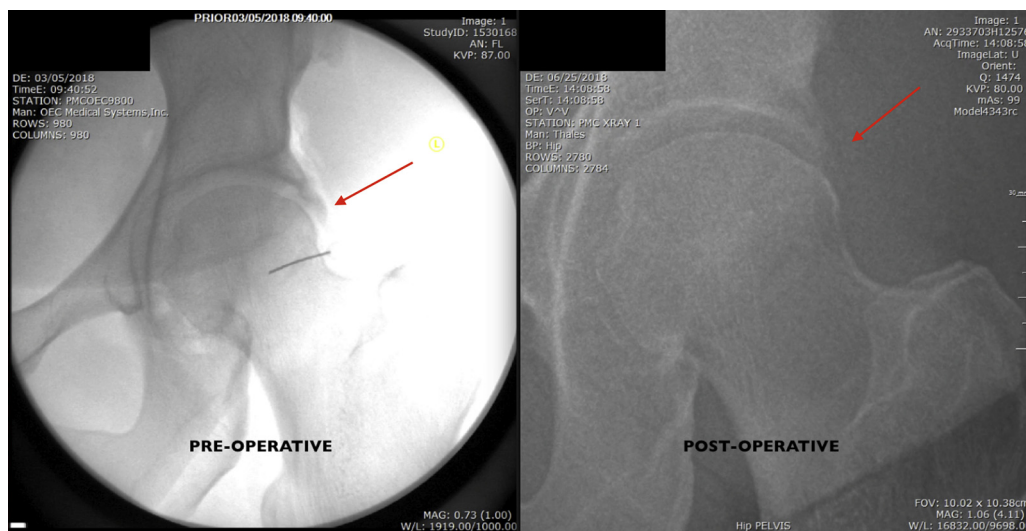


Fig 1. Anteroposterior fluoroscopic view of a left hip showing an ossified labrum (left), incapable of providing adequate suction seal and indicated for reconstruction, and postoperative radiograph showing removal of ossified labrum (right). A 5.5-mm arthroscopic burr is used to address the acetabular pincer morphology.

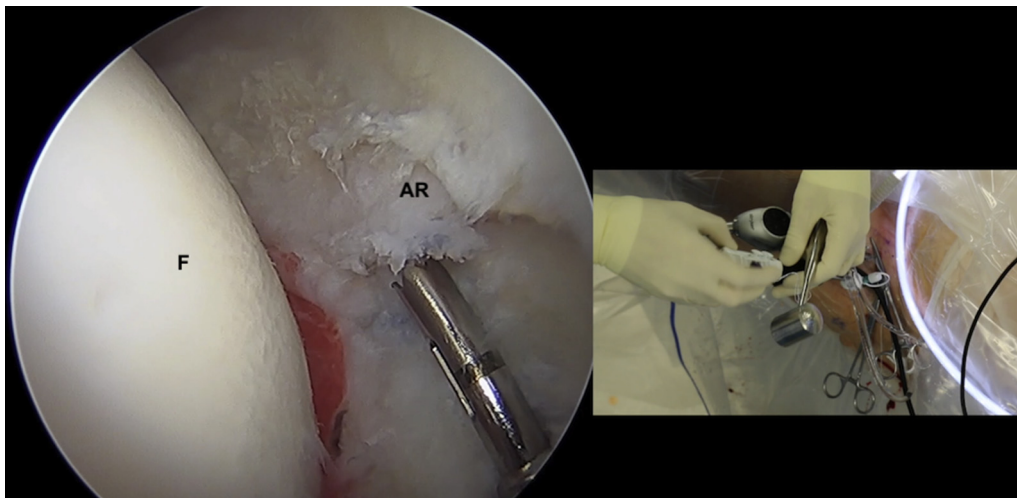


Fig 2. Arthroscopic view (left) and clinical view (right) from the midanterior portal of a left hip, showing the AR after labral debridement and correction of pincer deformity. A 1.4-mm Pivot anchor (Pivot Medical) is inserted through the AL portal at the most posterolateral position of labral deficiency on the acetabulum. The femoral head is seen to the left of the acetabular rim. (AL, anterolateral; AR, acetabular rim; F, femoral head.)

is removed from the anterior portal and placed in the anterolateral portal, and the anterior portal is used as a working portal through which to resect the labrum with a combination of arthroscopic basket and shaver. Again, the burr is used to prepare a bleeding bony surface for the graft. A distal anterolateral accessory (DALA) portal is then created percutaneously under direct visualization by using a standard cannulation technique. During the time of acetabular rim preparation, the graft is prepared on the back table. After

labral resection, acetabular rim trimming, and preparation of the bony bed, an 8.5 × 90-mm plastic cannula is placed in the anterolateral portal. A 1.4-mm drill guide is used to make a pilot hole into the acetabular rim at the most posterolateral position of the deficient labrum adjacent to the posterior aspect of the transverse acetabular ligament (Fig 2). Care is taken to ensure that the drill does not violate the articular surface of the acetabulum. A 1.4-mm Pivot anchor (Pivot Medical, Sunnyvale, CA) is then seeded

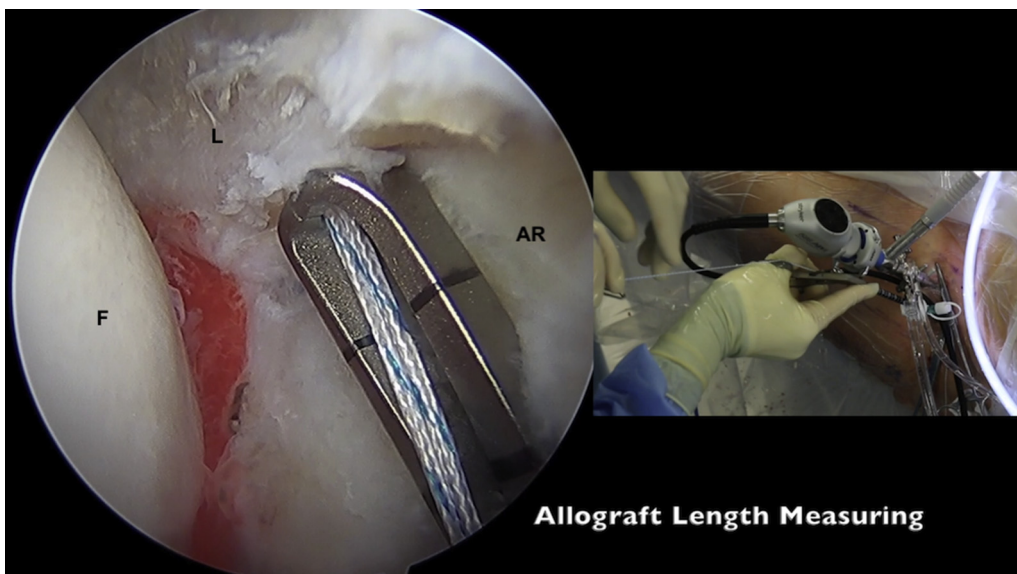


Fig 3. Arthroscopic and clinical views from the midanterior portal of a left hip, showing both suture limbs of the anchor threaded through the end of the Superior Capsule Reconstruction (SCR) guide (Arthrex) and the guide inserted to the base of the suture. This is used to measure the labral graft that will replace the damaged labrum being removed. In the arthroscopic image, the femoral head (F) is on the left, the undamaged labrum (L) is on the top, and the acetabular rim (AR) is on the right. (AR, acetabular rim; F, femoral head; L, labrum.)

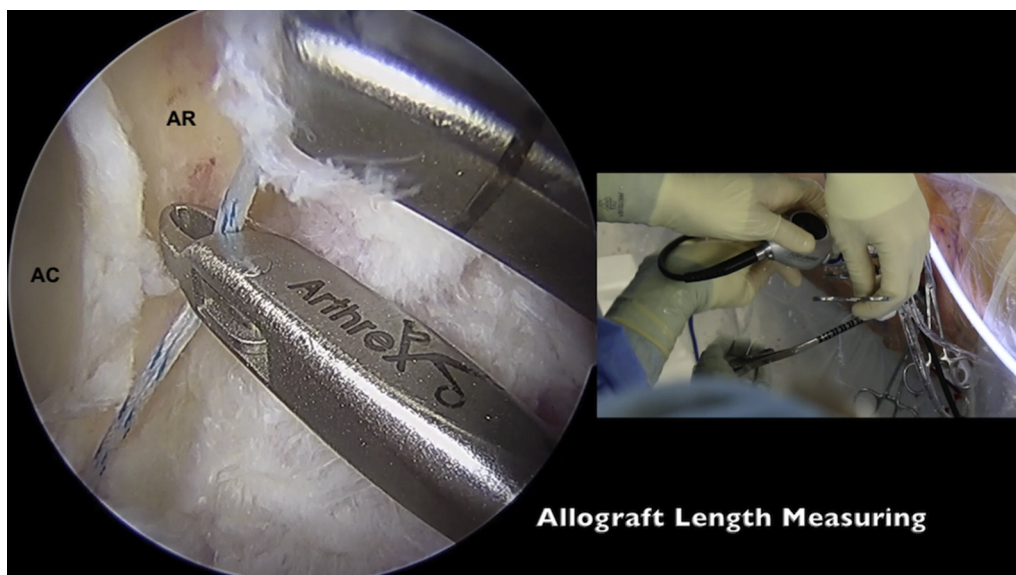

Fig 4. Arthroscopic and clinical views from the midanterior portal of a left hip with a suture manipulator used through a distal anterolateral accessory portal to position the suture along the acetabular rim in 10-mm increments, measured using the Superior Capsule Reconstruction guide (Arthrex). In the arthroscopic image, the AC is on the left and the AR is on the right. (AC, acetabular cartilage; AR, acetabular rim.)

into the pilot hole and impacted into place through the cannula.

Defect Measurement Using the SCR Guide

To determine the allograft length, the suture ends from this anchor are threaded through the SCR guide, and the guide is inserted through the cannula to the base of the suture limbs at the anchor insertion site (Arthrex). The suture ends are then clamped at the 10-cm position of the SCR guide with hemostat forceps (Miltex, New York, NY) (Fig 3). The SCR guide is then walked along the

acetabular rim, and a suture manipulator is passed through the DALA portal to position the suture along the acetabular rim. Once the SCR has traveled 10 mm, as measured from the hemostat forceps on the guide, the suture manipulator is repositioned to this planned anchor point, and the SCR guide is walked another 10 mm along the rim (Fig 4). This is repeated and the rim is measured and remeasured to ensure proper graft length throughout the length of the defect. Anchors are then placed as previously described along the acetabular rim at 10-mm intervals for future graft fixation (Fig 5).

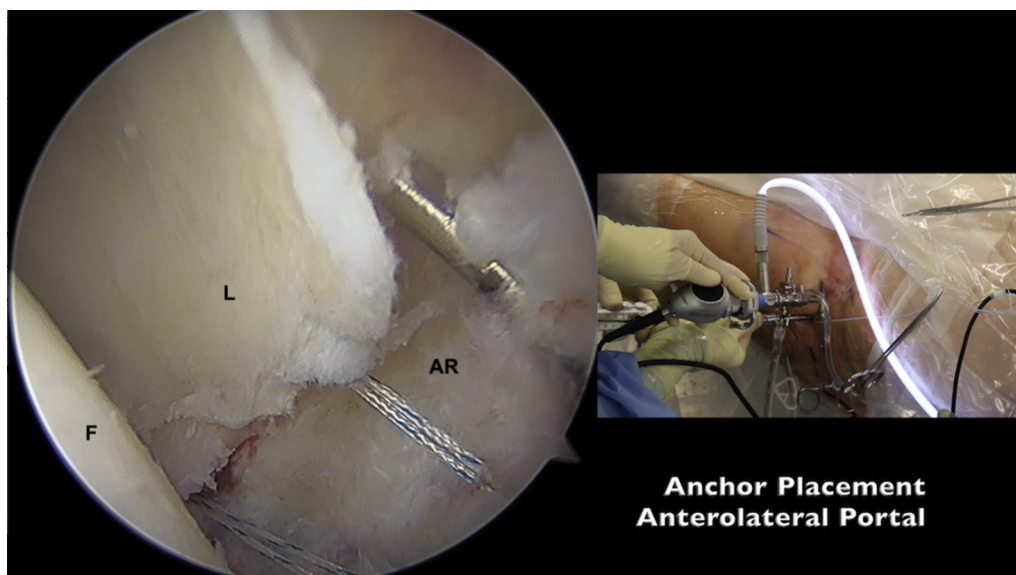


Fig 5. Arthroscopic and clinical views from the midanterior portal of a left hip, showing anchor insertion in 10-mm increments using the AL portal. In the arthroscopic image, the femoral head is on the left, the undamaged labrum is in the center, and the AR is on the right. (AL, anterolateral; AR, acetabular rim; F, femoral head; L, labrum.)




Fig 6. Clinical view of a prepared 40-mm tensor fascia lata graft before insertion through the distal anterolateral accessory portal cannula.

The first 3 1.4-mm Pivot anchors are placed through the anterolateral portal, and the final 2, through a DALA portal. (In this case, 5 anchors were placed along the acetabular rim in preparation for graft insertion, for a graft length of 40 mm.) The most anteromedial and posterolateral suture limbs are then pulled through the DALA portal in preparation for graft passage.

Graft Preparation and Passage

In this case, a tensor fascia lata allograft was used (Fig 6). However, the described technique can be used with autogenous grafts as well. The graft is cut and prepared to the previously described length and tubularized to a thickness of 5 to 6 mm. Sutures are placed at each end of the graft to aid in the tubularization process. A continuous interlocking suture technique is performed with a 2.0 Vicryl suture (Ethicon, Somerville, NJ) to fix the graft in place. Once graft preparation is complete, the graft is remeasured for accuracy and adjusted as needed. A free needle is used to pass 1 suture arm through each graft end from the previously placed far anteromedial and posterolateral anchors. Next, the 40-mm tensor fascia lata allograft is shuttled into the joint through the distal accessory anterolateral portal with an arthroscopic knot pusher, with the anteromedial end of the graft preceding the posterolateral end. The graft is then secured to the acetabulum at the anteromedial end with a standard arthroscopy half-hitch knot-tying technique. This step is then repeated using 1 of the suture arms from the posterolateral end of the graft. The remaining suture anchors are then passed around the graft and secured to the acetabular rim in standard fashion. Traction is then released, and the reconstruction is evaluated dynamically in all planes to assess fixation and position of the graft (Fig 7).

Osteoplasty and Capsular Plication

After fixation of the labrum has been confirmed, traction is released to access the peripheral compartment. For this portion of the procedure, the hip is typically flexed to 40°. The arthroscope is placed into

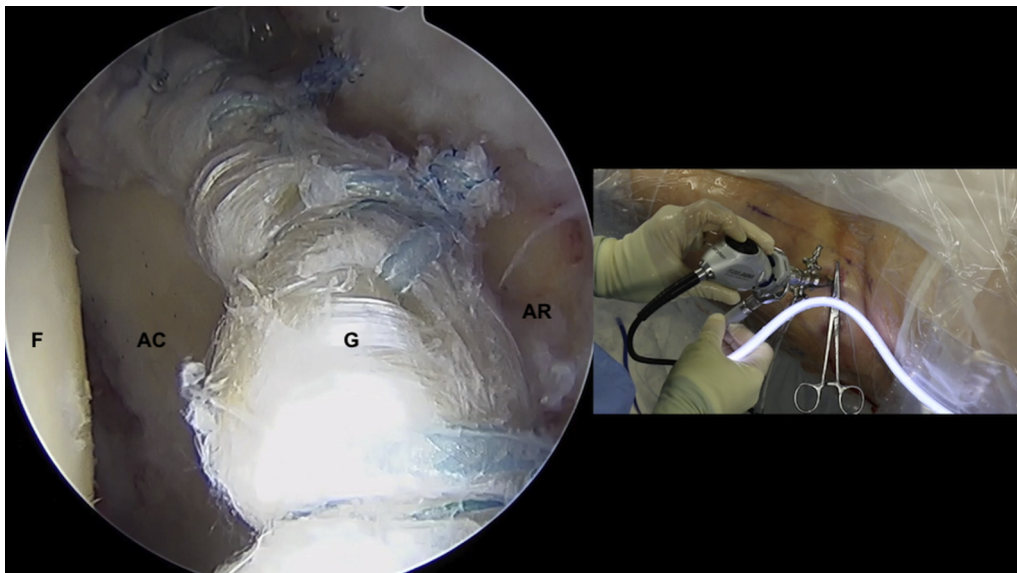


Fig 7. Arthroscopic and clinical views from the midanterior portal of a left hip after fixation of the graft. In the arthroscopic image, the femoral head is on the left, the graft is in the center, the AR is on the right, and the AC is to the left of the graft. (AC, acetabular cartilage; AR, acetabular rim; F, femoral head; G, graft.)

Table 2. Advantages and Limitations

Advantages	Limitations
<ul style="list-style-type: none"> • Precise measurement of labral deficiency • Avoids additional labral truncation step after fixation • Avoids unnecessary graft harvest or use • Decreases the technical demand of fixing the graft by avoiding excessive graft in the joint 	<ul style="list-style-type: none"> • Requires an extra instrument • Requires an assistant to clamp sutures

the peripheral compartment, and a T-capsulotomy is performed between the 12 o'clock and 2 o'clock positions approximately 4 cm in length, approximately 5 to 8 mm from the labrum using an arthroscopic knife. An arthroscopic injector device (Injector; Pivot Medical) is then used to reflect the capsule with the aid of 2 No. 2 high-molecular-weight polyethylene sutures.

At this point, the arthroscope is used to identify the extent of the cam deformity. Intraoperative fluoroscopy can be used to confirm the location of the instruments before the cam resection is performed. An arthroscopic 5.5-mm burr is used to perform femoral osteochondroplasty from the lateral to the medial synovial fold in standard fashion. A combination of intraoperative fluoroscopy and dynamic hip examination throughout the osteochondroplasty procedure confirms complete removal of all bony morphology.

After osteochondroplasty, a complete capsular plication is performed incorporating both the vertical and interportal limbs. During viewing from the anterior portal, an 8.5 × 110-mm plastic cannula is placed in the DALA portal, and an 8.5 × 90-mm plastic cannula is placed in the AL portal. The vertical portion of the T-capsulotomy is closed first, beginning at the base of the iliofemoral ligament using a capsule-closure device (Injector) loaded with a No. 2 high-molecular-weight polyethylene suture. It is important to ensure that full-thickness passes are made through the capsular limbs. Once these sutures have been passed, they are tied using standard arthroscopic tying techniques. The vertical portion of the T-capsulotomy is typically closed with 2 to 4 sutures. The interportal capsulotomy is repaired next. The Injector is placed through the AL portal to close the lateral aspect of the interportal capsulotomy by passing suture through the acetabular limb of the capsule and then through the lateral leaflet of the iliofemoral ligament. In the same fashion, the Injector is used to close the medial aspect of the interportal capsulotomy by passing a suture through the acetabular limb and then through the medial leaflet of the iliofemoral ligament utilizing the DALA portal. With the capsule completely repaired, the femoral head articular cartilage should no longer be visible.

Postoperative Rehabilitation

Rehabilitation is started on postoperative day 1 for all patients as previously described.¹² Patients go through a 4-phase rehabilitation protocol that lasts an average of 16 to 18 weeks. Rehabilitation phase 1 prioritizes joint protection and soft tissue mobilization techniques. Phase 2 focuses on normal gait maintenance, full range-of-motion restoration, improvement of neuromuscular control, and maintenance of pelvic and core stability. Phase 3 incorporates single leg squats and strengthening, soft tissue and joint mobilization, and cardiovascular fitness. Phase 4 emphasizes return to preinjury level of sports participation. Patients are cleared to return to sports if they are able to participate in sports without pain, have full dynamic functional control, and pass all return to sports tests.

Discussion

We report a technique to measure labral defect size that utilizes an arthroscopic shoulder instrument to increase the accuracy by which intra-articular graft length is measured. Ongoing labral reconstruction research has continued to show good clinical medium- and short-term outcomes with good survivorship.^{8-10,13} Furthermore, these outcomes are dependent on precise technique and proper fitting of the graft within the labral defect to re-create the patient's native anatomy. Conventional labral reconstruction techniques involve using a burr or an object of known length to incrementally measure the defect size and to determine the graft length.¹¹ This technique can be prone to substantial measurement error from estimation and assumption of standardized length of common surgical devices. Perets et al.¹⁴ describe a measureless technique using 1 anterior Arthrex PushLock anchor, a variable number of Knotless SutureTaks (Arthrex), and a semitendinosus graft that is amputated to the desired length using electrocautery after fixation. Although this technique reduces surgical time and measurement steps, it can cause graft displacement if overtightened and increases the technical difficulty of an already challenging procedure. Additional graft in the joint during fixation could compromise visibility and make graft tensioning and repair more difficult. The consequences of this imprecision are critical because a slight mismatch will disrupt the creation of a suction seal and can lead to worse outcomes and progressive joint degeneration.

The advantages of the current technique are multiple (Table 2). This technique offers a more precise and efficient way to measure labral defect size by utilizing principles of graft measurement used in superior capsular reconstruction in the shoulder. Furthermore, this technique does not require any additional portals and allows an exact circumferential measurement of the labral defect that does not require postfixation

truncation. In the case of autogenous graft use, this technique avoids the morbidity of unnecessary graft harvest that might be later truncated using other methods. In our experience, this technique results in a more efficient and precise measurement that adds minimal time to the procedure and avoids the need for any postfixation steps. The disadvantages of this technique include the cost of the instrument, the learning curve associated with using a new instrument, and the need for assistance in clamping suture ends during measurement. The major risk of using this technique is undermeasurement of the graft needed to perform the reconstruction. Surgeons should only use this technique if they are comfortable with using the SCR guide, and we recommend practicing this technique before performing the surgery in vivo. Re-creation of the critical suction seal function of the hip labrum is contingent upon having adequate length and quality of labrum. Thus, if the graft length is not measured precisely, the benefits of the procedure will be compromised. The advantages and limitations of this technique are summarized in Table 2.

References

- Groh MM, Herrera J. A comprehensive review of hip labral tears. *Curr Rev Musculoskelet Med* 2009;2:105-117.
- Ferguson SJ, Bryant JT, Ganz R, Ito K. The influence of the acetabular labrum on hip joint cartilage consolidation: A poroelastic finite element model. *J Biomech* 2000;33:953-960.
- Ferguson SJ, Bryant JT, Ganz R, Ito K. An in vitro investigation of the acetabular labral seal in hip joint mechanics. *J Biomech* 2003;36:171-178.
- Ferguson SJ, Bryant JT, Ganz R, Ito K. The acetabular labrum seal: A poroelastic finite element model. *Clin Biomech (Bristol, Avon)* 2000;15:463-468.
- McCarthy JC, Noble PC, Schuck MR, Wright J, Lee J. The Otto E. Aufranc Award: The role of labral lesions to development of early degenerative hip disease. *Clin Orthop Relat Res* 2001;393:25-37.
- Krych AJ, Thompson M, Knutson Z, Scoon J, Coleman SH. Arthroscopic labral repair versus selective labral debridement in female patients with femoroacetabular impingement: A prospective randomized study. *Arthroscopy* 2013;29:46-53.
- Locks R, Chahla J, Bolia IK, Briggs KK, Philippon MJ. Outcomes following arthroscopic hip segmental labral reconstruction using autologous capsule tissue or indirect head of the rectus tendon. *J Hip Preserv Surg* 2018;5:73-77.
- White BJ, Stapleford AB, Hawkes TK, Finger MJ, Herzog MM. Allograft use in arthroscopic labral reconstruction of the hip with front-to-back fixation technique: Minimum 2-year follow-up. *Arthroscopy* 2016;32:26-32.
- Geyer MR, Philippon MJ, Fagrelus TS, Briggs KK. Acetabular labral reconstruction with an iliotibial band autograft: Outcome and survivorship analysis at minimum 3-year follow-up. *Am J Sports Med* 2013;41:1750-1756.
- Matsuda DK, Burchette RJ. Arthroscopic hip labral reconstruction with a gracilis autograft versus labral refixation: 2-year minimum outcomes. *Am J Sports Med* 2013;41:980-987.
- Karns MR, Patel SH, Kolaczko J, et al. Acetabular rim length: An anatomical study to determine reasonable graft sizes for labral reconstruction. *J Hip Preserv Surg* 2017;4:106-112.
- Frank RM, Lee S, Bush-Joseph CA, Kelly BT, Salata MJ, Nho SJ. Improved outcomes after hip arthroscopic surgery in patients undergoing T-capsulotomy with complete repair versus partial repair for femoroacetabular impingement: A comparative matched-pair analysis. *Am J Sports Med* 2014;42:2634-2642.
- Philippon MJ, Briggs KK, Hay CJ, Kuppersmith DA, Dewing CB, Huang MJ. Arthroscopic labral reconstruction in the hip using iliotibial band autograft: Technique and early outcomes. *Arthroscopy* 2010;26:750-756.
- Perets I, Hartigan DE, Chaharbakhshi EO, Walsh JP, Close MR, Domb BG. Circumferential labral reconstruction using the knotless pull-through technique-surgical technique. *Arthrosc Tech* 2017;6:e695-e698.