



Müller Muscle-conjunctival Resection with or without Tarsectomy and Combined with Bandage Contact Lens Use in Ptosis Patients with Corneal Graft

Mehmet Serhat Mangan¹, Serap Yurttaser Ocak², Ece Turan Vural³, Elvin Yildiz³

¹Division of Ophthalmic Plastic and Reconstructive Surgery, Sadik Eratik Eye Clinic, Haydarpasa Numune Education and Research Hospital, University of Health Sciences, Istanbul, Turkey

²Division of Cornea, Department of Ophthalmology, Okmeydani Education and Research Hospital, University of Health Sciences, Istanbul, Turkey

³Division of Cornea, Sadik Eratik Eye Clinic, Haydarpasa Numune Education and Research Hospital, University of Health Sciences, Istanbul, Turkey

Purpose: To examine the efficacy of ptosis correction with a Müller muscle-conjunctival resection with or without tarsectomy (MMCR±T), combined with bandage contact lens (BCL) use, in corneal graft patients.

Methods: Seven patients with corneal grafts who underwent MMCR±T for treatment of ptosis were evaluated retrospectively. A BCL was applied to the grafts at the end of the surgery. The collected data included preoperative and postoperative visual acuity, marginal reflex distance 1 (MRD-1), presence of Hering's dependency by the phenylephrine test, symmetry outcomes, and complications after MMCR±T.

Results: The average duration between the penetrating keratoplasty and MMCR±T was 14 months, with a follow-up time of 10.4 months after MMCR±T. Hering's dependency was observed in four (57.2%) patients before MMCR±T, and MRD-1 was increased in all patients based on preoperative phenylephrine tests. The mean preoperative MRD-1 was -0.14 ± 0.55 mm, and the mean postoperative MRD-1 was 2.35 ± 0.89 mm ($p < 0.0001$). Symmetry outcomes of perfect (<0.5 mm), good (0.5–1 mm), and fair (≥ 1 mm) were noted after MMCR±T in three, three, and one patients, respectively. During the follow-up, no obvious corneal epitheliopathy, keratitis, or corneal graft rejection/failure were noted in any cases. BCL use was well tolerated by all patients.

Conclusions: Most patients achieved good surgical outcomes with the application of the BCL to protect the graft and with the use of the phenylephrine test and Hering's dependency to predict the final eyelid position and symmetry. MMCR±T combined with BCL may therefore represent an alternative approach for correction of ptosis in patients with corneal graft.

Key Words: Blepharoptosis, Contact lenses, Müller muscle-conjunctival resection, Penetrating keratoplasty, Tarsectomy

Received: September 17, 2020 Final revision: October 7, 2020

Accepted: October 29, 2020

Corresponding Author: Mehmet Serhat Mangan, MD, FEBOPht. Sadik Eratik Eye Clinic, Haydarpasa Numune Education and Research Hospital, University of Health Sciences, Tibbiye Cad. No:23, Uskudar, Istanbul 34668, Turkey. Tel: 90-530-109-3800, Fax: 90-216-336-0565, E-mail: meh-metsmangan@yahoo.com

Corneal transplantation is the most common type of tissue transplantation performed worldwide [1]. One form of this transplantation, penetrating keratoplasty (PK), is a sight-saving surgery in many patients with corneal blindness [2]. Overall, approximately 90% of all corneal transplantation procedures performed in 95 reporting countries

© 2021 The Korean Ophthalmological Society

This is an Open Access article distributed under the terms of the Creative Commons Attribution Non-Commercial License (<http://creativecommons.org/licenses/by-nc/3.0/>) which permits unrestricted non-commercial use, distribution, and reproduction in any medium, provided the original work is properly cited.

are PK, regardless of the surgical indication [3,4].

Patients who undergo PK may experience eyelid ptosis [5-7] and blepharoptosis that may restrict the visual acuity (VA) and the visual field that was improved with the PK [5,6]. Subsequent correction of ptosis has been demonstrated to increase the patient quality of life [8], but surgeons may be unwilling to treat ptosis because of concerns about complications resulting from lagophthalmos and exposure keratopathy. Overcorrection following ptosis surgery may also increase the risk of corneal graft rejection [6,7].

Most of the previous studies have reported eyelid ptosis following anterior segment surgery, and especially after cataract and glaucoma surgery [9-23]. However, a few reports have appeared regarding ptosis correction surgeries in patients after keratoplasty [6,7]. For example, Michels et al. [6] reported the use of Müller muscle-conjunctival resection (MMCR) without tarsectomy to treat ptosis in patients with a prior history of corneal surgery; however, they did not investigate the use of a bandage contact lens (BCL) after MMCR to protect the corneal grafts. Possible problems arising from the MMCR are associated with the presence of suture material on the palpebral conjunctiva [24-26]. Another related study by Paik et al. [7] reported results for levator resection in ptosis cases with grafted corneas, and they noted that the main problem was that patients who underwent levator resection could experience a change in eyelid position but this was not entirely predictable [27]. We therefore considered using the phenylephrine test and Hering's test to predict the final eyelid position and symmetry achieved with MMCR with or without tarsectomy (MMCR±T). We also decided to make use of the BCL following MMCR±T because we considered that it might improve the patient's comfort and protect the corneal graft during the postoperative period.

To the best of our knowledge, no studies have yet examined the combined use of a tarsectomy and MMCR to adjust the final eyelid position or the application of a BCL after MMCR±T to protect the corneal graft. Here, we present the results showing the efficacy of ptosis correction with MMCR±T combined with BCL use in patients with corneal grafts.

Materials and Methods

Study design

This study was approved by the Research Ethics Committee of the University of Health Sciences, Haydarpasa Numune Education and Research Hospital (HNEAH-KAEK 2020/118) and was conducted in accordance with the tenets of the Declaration of Helsinki. Informed written consent was obtained from all participants.

Patients with corneal graft included in the study had ptosis and underwent unilateral MMCR±T combined with BCL use to correct the ptosis between June 2016 and March 2020. Patients were recruited from two tertiary referral hospital and evaluated retrospectively. All patients had severe ptosis (marginal reflex distance 1 [MRD-1] \leq 1 mm) and underwent MMCR±T on the ptotic eyelid. The exclusion criteria for the study were the following: (1) PK surgery with less than 6 months of follow-up, (2) previous upper eyelid surgery including blepharoplasty or browpexy, (3) poor or moderate levator function (LF) of less than 13 mm, (4) congenital, myogenic, mechanical, neurogenic causes, (5) conjunctival and/or ocular surface disorders (e.g., ocular cicatricial pemphigoid, Stevens-Johnson syndrome), or (6) a short tear break uptime test (\leq 5 seconds) or a corneal epitheliopathy on the corneal graft determined by fluorescein staining.

Patient evaluation

Prior to the MMCR±T, VA, LF, and MRD-1 were measured for both eyelids and a Hering's test was conducted in all patients. MRD-1 was measured to the nearest 0.5 mm with the patient in a sitting position to ensure the brow was stabilized to prevent recruitment of the frontalis muscle clinically and in the primary position of gaze. Hering's test was performed using the phenylephrine test of the ptotic eye and the test results were considered positive if there was a droop occurred in the contralateral eyelid height (called Hering's dependency). The value of the Hering's effect was recorded.

The amount of resection for the MMCR±T was determined based on the phenylephrine test results. The phenylephrine test consisted of administration of two drops, at 5-minute intervals, of 2.5% phenylephrine into the upper conjunctival fornix with the more ptotic eyelid. At 5 min-

utes after administration of the drops, the MRD-1 was re-evaluated. The amount of resection by MMCR±T was determined according to phenylephrine test. The suggestion by Putterman and Urist [28], the conjunctiva and Müller muscle was resected 8 mm in cases where the application of phenylephrine elevated the eyelid to the height of the other nonptotic eyelid. If the phenylephrine test resulted in a 1-mm undercorrection, 9 mm was resected; and if the test resulted in a 1-mm overcorrection, 7 mm was resected. If required, Müller muscle-conjunctival resection was combined with tarsectomy to improve the elevation with the consideration that excision of 1 mm of the tarsus may cause an almost 1 mm elevation of the eyelid [24].

The analysis included measurement of MRD-1, height asymmetry, and complications following MMCR±T. Postoperative eyelid height asymmetry after MMCR±T was also evaluated, as follows: perfect results were a difference of less than 0.5 mm between the 2 upper eyelid margins, good results were a difference of between 0.5 and 1 mm, and fair results were a difference equal to or greater than 1 mm. Any complications were also recorded.

Surgical procedures

MMCR±T and lateral tarsal strip surgery were performed by a single surgeon. If needed, a lower lid lateral tarsal strip surgery was combined with MMCR±T to improve the lower lid laxity. All surgeries were performed under local anesthesia using 2% lidocaine infiltrated subconjunctivally and subcutaneously. A 4-0 silk traction suture was inserted in the central portion of the upper lid margin to assist lid eversion over a Desmarres retractor. The desired amount of resection was marked and grasped with a Putterman ptosis clamp. If a tarsectomy is to be done, the desired amount of tarsal tissue to be resected is including the clamp as well. A 6-0 polypropylene suture was passed in a continuous horizontal mattress pattern approximately 1 mm below the clamp. The suture was passed 2 mm apart. However, if a tarsectomy is also performed, the suture passes on the tarsal side are closer. The conjunctival and Müller muscle with or without tarsus were excised, and the suture was externalized and tied over a bolster. A BCL (Senofilcon A silicone hydrogel contact lens; Johnson & Johnson Vision, FL, USA) was applied to the cornea in all patients at the end of the surgery. The suture and BCL were removed 10th day after surgery.

Statistical analysis

IBM SPSS Statistics ver. 21.0 (IBM Corp., Armonk, NY, USA) was used for the statistical analysis. The Shapiro-Wilk test was used to assess the normality of data distribution. Differences between preoperative and postoperative values were compared by using a paired-samples *t*-test for normally distributed values. Values of $p < 0.05$ were considered to be statistically significant.

Results

The clinical features of the patients are presented in Table 1. The patients comprised three women (42.8%) and four men (57.2%) with a mean age of 58.24 years (range, 47–68 years). The mean preoperative LF was 15.29 and 16 mm in the operated and nonoperated eyes, respectively. Hering's dependency was observed in four patients (57.2%) before MMCR±T and MRD-1 was increased postoperatively in all patients, as determined with the phenylephrine test. The average duration between the PK and MMCR±T was 14 months (range, 7.5–20.8 months) and the follow-up time after MMCR±T was 10.4 months (range, 3.5–17.8 months). PK was performed for Fuchs' endothelial dystrophy in two eyes and for aphakic/pseudophakic bullous keratopathy in five eyes.

A total of seven eyelids of seven patients who underwent unilateral MMCR±T for correction of the ptosis following PK were analyzed in this study (Fig. 1A, 1B, 2A, 2B, 3A, 3B). A tarsectomy (42.8%) was added to the surgery in three patients. MMCR±T, combined with lateral tarsal strip procedure (28.5%), was performed in two patients.

The VA was improved in five (71.4%) patients and MRD-1 was increased in all cases after MMCR±T (Table 1). The mean preoperative MRD-1 was -0.14 ± 0.55 , and the mean postoperative MRD-1 was 2.35 ± 0.89 in operated eyelid. There was a statistically significant improvement between preoperative and postoperative MRD-1 ($p < 0.0001$). A visual field test was not performed after MMCR±T, but four patients stated that their visual field was improved subjectively. Symmetry outcomes of perfect (<0.5 mm), good (0.5–1 mm) and fair (≥ 1 mm) were assessed after MMCR±T in three, three, and one patients, respectively. Only one patient was unsatisfied with the symmetry and eyelid appearance following MMCR±T, but

Table 1. Clinical features of the patients with corneal grafts who underwent MMCR±T for correction of ptosis

Sex	Age (yr)	LF	Pre, MRD-1, operated eyelid	Pre, MRD-1, non-operated eyelid	Hering value	Pt, MRD-1, operated eyelid	Pt, MRD-1, non-operated eyelid	MMCR±T	Post, MRD-1, operated eyelid	Post, MRD-1, non-operated eyelid
M	56	17	0.5	3.0	0	3.0	3.0	8.0	3.0	3.0
F	66	13	0	2.5	0.5	1.0	2.0	9±1	1.5	2.0
M	58	14	-0.5	3.0	0	1.5	3.0	9±2	2.5	3.0
F	68	13	-1.0	2.0	0.5	1.0	1.5	9.0	1.0	1.5
F	47	18	0.5	4.0	0.5	3.0	3.5	9.0	3.5	3.5
M	57	15	-0.5	3.5	1.0	2.0	2.5	9.0	2.0	3.0
M	53	17	0	3.0	0	1.5	3.0	9±2	3.0	3.0

LF = levator function; Pre = preoperative; MRD-1 = marginal reflex distance 1; Pt = phenylephrine test; MMCR±T = Müller muscle-conjunctiva resection with or without tarsectomy; Post = postoperative.

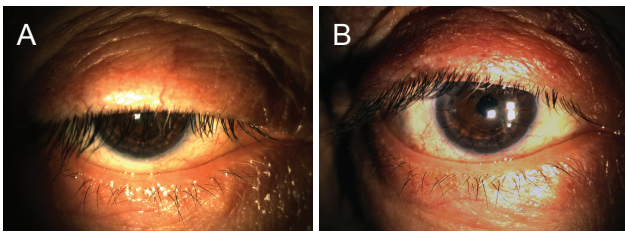


Fig. 1. Anterior segment photography. (A) Anterior segment photography of patient showing corneal graft and severe ptosis before eyelid surgery. (B) Anterior segment photography of patient showing clear corneal graft and improvement of the marginal reflex distance 1 after eyelid surgery. Written informed consent for publication of the clinical images was obtained from the patient.

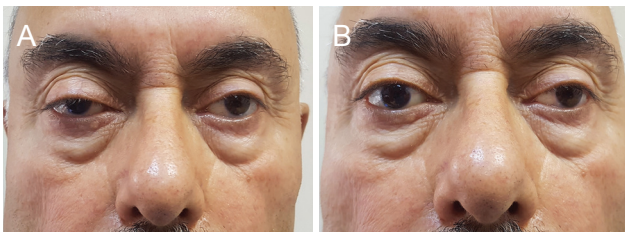


Fig. 2. Preoperative view of the patient. (A) Preoperative view of a 56-year-old man with corneal graft and ptosis on his right eye. (B) Good response to phenylephrine testing on the right eye before ptosis surgery. Written informed consent for publication of the clinical images was obtained from the patient.

he declined a second operation. A symmetrical lid contour was achieved in all patients. Minimal transient lagophthalmos was seen in three cases after MMCR±T. During the postoperative follow-up time, no obvious corneal epitheliopathy, keratitis, or corneal graft rejection/failure were ob-

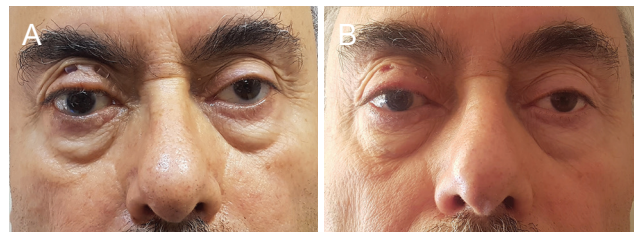


Fig. 3. Postoperative view of the patient. (A) He had Müller muscle-conjunctival resection without tarsectomy on his right eye. (B) View of the patient after removal the suture and bandage contact lens; upper eyelid height symmetry was achieved. Written informed consent for publication of the clinical images was obtained from the patient.

served in any patient. BCL use was tolerated well in all patients.

Discussion

In this study, we present an alternative approach for correction of ptosis in patients with corneal graft. We used a BCL after MMCR±T to protect the corneal graft, and we used the phenylephrine test and Hering's test to predict the final eyelid position and symmetry. MMCR±T was performed for correction of ptosis using a previously described algorithm and technique [24,28]. Most patients achieved good surgical outcomes and no corneal graft complications were observed.

Eyelid ptosis may decrease the VA and visual field that was improved with PK [5,6]. The main goal in these pa-

tients are to improve their vision and quality of life. The second goal is to achieve a satisfactory upper eyelid height and symmetry. In our study, five of seven patients had increased VA, and four of seven patients subjectively reported an improvement in their visual field, which may be related to the mechanical elevation of the eyelids.

In this study, six cases (85.7%) had good or perfect upper eyelid height symmetry. In our study, the reason for obtaining a satisfactory result may be the use of phenylephrine and the Hering's test to predict the final eyelid position and symmetry. In the present study, prior to the MMCR±T, the mean upper eyelid height was increased in all patients according to the phenylephrine test. The contralateral eyelid droop was also measured and recorded preoperatively with the Hering's test. These findings demonstrate the achievement of eyelid height symmetry in most of the patients after MMCR±T, even when the MRD-1 varied to different extents in the phenylephrine test in both eyelids prior to MMCR±T, by the use of a previously described algorithm and technique [24,28] and the Hering's test with phenylephrine. In a previous study, Michels et al. [6] reported the use of MMCR without tarsectomy to treat ptosis in patients with a prior history of a corneal surgery; however, the preoperative and postoperative measurements were not clear for both eyelids in that study and the Hering's test was not used. A detailed analysis of their data revealed that while some patients had only interpalpebral distance measurements, the others had only MRD-1 measurements in operated eyelid and, contralateral eyelid measurements were not recorded most cases. The use of the MMCR algorithm and technique was not clearly described and no symmetry outcomes were reported. Michels et al. [6] reported that MMCR was performed in 12 cases with a history of PK; however, five of the 12 patients had no eyelid measurements taken.

Another important issue is which approach is more effective and safer for patients with ptosis following PK. The primary purpose of the surgery was to treat a mild undercorrection in patients following a corneal graft. However, exposure keratopathy and lagophthalmos can occur following overcorrection and may negatively affect the corneal graft [7]. For example, Paik et al. [7] reported the results of levator resection in nine ptosis cases with grafted corneas and noted that an undercorrective levator resection was the best method for treatment of ptosis in patients with grafted corneas. However they did not use the Her-

ing's test preoperatively and not evaluate the contralateral eyelid position or the symmetry outcomes postoperatively. The main problem in these cases is achieving the desired eyelid height symmetry and the limited predictability of the eyelid position after surgery. Patients undergoing levator resection can experience a change in eyelid position and this is not entirely predictable [27]. In addition, the contralateral eyelid position following ptosis repair depends on several factors that affect upper eyelid position, including the orbicularis oculi, the frontalis muscle, a sympathetic response by the Müller's muscle, and coexisting mild ptosis in the contralateral eyelid [29-32]. Pan et al. [33] reported that a preoperative assessment of Hering's law may improve the results of levator surgery in patients with asymmetric ptosis. In our study, none of the patients were observed to have an overcorrection. This result may be related to our use of the algorithm, phenylephrine, and Hering's test for determination of the extent of the resection of the conjunctiva, Müller muscle, and/or tarsus.

In the present study, we used the Hering's test with phenylephrine to predict the final eyelid position achieved with MMCR±T. Nemet [31] also reported that the Hering's law effect was more common with the levator approach than with MMCR. Consistent with that study, we considered MMCR±T as possibly more predictable than levator resection surgery. In our study, the relation between the MRD value following the phenylephrine test before MMCR±T and the MRD value after MMCR±T were consistent. This finding may support the greater predictability of MMCR±T as a surgery choice.

Asymmetry of the eyelid marginal contour is often visible in patients on an individual basis following levator surgery, and reports of ptosis outcomes are notable [34]. Choudhary et al. [35] reported that MMCR±T restores eyelid contour. Consistent with that study, eyelid contour abnormality was not observed in all our patients. Furthermore, the addition of a tarsectomy to the MMCR procedure improved the upper eyelid height position [24,36]. Similar to the findings in previous studies [24,36], if the eyelid responds to the phenylephrine test but the eyelid remains more ptotic, a tarsectomy was added to the surgery. In our study, three cases remained more ptotic after the phenylephrine test but these patients achieved good results with the addition of tarsectomy. Patel et al. [36] reported that levator aponeurosis plication is the main mechanism for treatment of eyelid ptosis in posterior lamella tech-

niques and that tarsectomy increases the potency of this elevation. Michels et al. [6] reported that revisional levator surgery was performed on five eyelids in patients with corrected MMCR, but none of our patients required revisional surgery in our study. This possible be related to the improved surgical outcome of MMCR combined with tarsectomy.

In our study, we did not observe any obvious corneal epitheliopathy, keratitis, or graft rejection/failure of the donor cornea during the follow-up. Possible problems regarding the MMCR±T are associated with the presence of suture material on the palpebral conjunctiva. This material may give rise to complications that can include keratopathy, suture granuloma, infection, and the need for suture removal [24-26]. La Porta Weber et al. [37] reported that also a contact lens can act as a protective covering for the cornea by controlling evaporation and maintaining direct contact between the fluid and the corneal epithelium. The contact lens also protects the cornea from abrasions and mechanical trauma. The contact between the corneal graft and eyelid sutures may increase the epitheliopathy with eye blinking. For that reason, we used the BCL in all patients to protect the corneal grafts.

The average duration between the PK and ptosis repair was 14 months in our study. By contrast, Paik et al. [7] reported an average duration of only 8.5 months. A longer duration may have decreased the risk of graft-related complications in our study. Furthermore, lower lid laxity may negatively affect the corneal graft [5]. In our study, MMCR±T, combined with lateral tarsal strip procedure, was performed in two patients with eyelid laxity to improve the BCL position for adequate coverage of the corneal graft.

The risk of ptosis after any anterior segment surgery increases for many reasons, including older age, race, gender, operative time, type of anesthesia, eyelid edema, orbital inflammation, frequent use of topical steroid eye drops, anesthesia type (i.e., retrobulbar vs. topical), use of a lid speculum, use of a superior rectus bridle suture, and type of surgery [7,9-23,38]. Recent studies have shown less surgery-related ptosis, which likely reflects the use of more modern surgical techniques [9,10]. Consistent with previous studies [9,10], a total seven eyelids of seven patients underwent PK in our study, but none of the patients underwent endothelial keratoplasty (EK). PK surgery may possibly require a longer operative time, a more invasive ap-

proach, more suturing, more inflammation treatments, and more frequent use of topical steroid eye drops when compared with EK. EK is a more modern surgical techniques compared with PK; however, further studies require evaluation of the postoperative ptosis rate between PK and EK.

The limitations of our study include the small number of patients and the nonrandomized, retrospective design. In addition, the clinical measurement of the MRD-1 may have reduced objective evaluation.

To our knowledge, this is the first study to evaluate the outcomes of the MMCR±T procedure in combination with BCL use for the management of ptosis in patients with corneal graft. The application of BCL to protect the graft and the use of phenylephrine and the Hering's test to predict the final eyelid position, together with a previously described algorithm and technique [24,28] for MMCR±T resulted in good surgical outcomes for most of our patients. MMCR±T combined with BCL may therefore represent an alternative approach for treatment of ptosis in patients with corneal graft.

Conflict of Interest

No potential conflict of interest relevant to this article was reported.

References

1. Tahvildari M, Amouzegar A, Foulsham W, Dana R. Therapeutic approaches for induction of tolerance and immune quiescence in corneal allotransplantation. *Cell Mol Life Sci* 2018;75:1509-20.
2. Crnej A, Omoto M, Dohlman TH, et al. Effect of penetrating keratoplasty and keratoprosthesis implantation on the posterior segment of the eye. *Invest Ophthalmol Vis Sci* 2016;57:1643-8.
3. Mathews PM, Lindsley K, Aldave AJ, Akpek EK. Etiology of global corneal blindness and current practices of corneal transplantation: a focused review. *Cornea* 2018;37:1198-203.
4. Gain P, Jullienne R, He Z, et al. Global survey of corneal transplantation and eye banking. *JAMA Ophthalmol* 2016;134:167-73.
5. Lim JM, Bang GM, Cortina MS, et al. Successful Muller muscle-conjunctiva resection in patients with Boston kera-

- toprosthesis type I. *Cornea* 2014;33:240-2.
6. Michels KS, Vagefi MR, Steele E, et al. Muller muscle-conjunctiva resection to correct ptosis in high-risk patients. *Ophthalmic Plast Reconstr Surg* 2007;23:363-6.
 7. Paik JS, Doh SH, Kim MS, Yang SW. Outcomes of levator resection in blepharoptosis patients with grafted corneas. *Jpn J Ophthalmol* 2010;54:452-7.
 8. Bahceci Simsek I. Association of upper eyelid ptosis repair and blepharoplasty with headache-related quality of life. *JAMA Facial Plast Surg* 2017;19:293-7.
 9. Kashkouli MB, Abdolalizadeh P, Es'haghi A, et al. Postoperative blepharoptosis after modern phacoemulsification procedure. *Am J Ophthalmol* 2020;213:17-23.
 10. Roddy GW, Zhao B, Wang F, et al. Increased rate of ptosis following glaucoma drainage device placement and other anterior segment surgery: a prospective analysis. *Graefes Arch Clin Exp Ophthalmol* 2020;258:1533-41.
 11. Huo L, Cui D, Yang X, et al. Etiology and treatment of post-surgical blepharoptosis. *Eye Sci* 2013;28:134-9.
 12. Altieri M, Truscott E, Kingston AE, et al. Ptosis secondary to anterior segment surgery and its repair in a two-year follow-up study. *Ophthalmologica* 2005;219:129-35.
 13. Hosal BM, Tekeli O, Gursel E. Eyelid malpositions after cataract surgery. *Eur J Ophthalmol* 1998;8:12-5.
 14. Mehat MS, Sood V, Madge S. Blepharoptosis following anterior segment surgery: a new theory for an old problem. *Orbit* 2012;31:274-8.
 15. Naruo-Tsuchisaka A, Maruyama K, Arimoto G, Goto H. Incidence of postoperative ptosis following trabeculectomy with mitomycin C. *J Glaucoma* 2015;24:417-20.
 16. Marques-Fernandez V, Garcia-Zamora M, Calabuig-Goena M, et al. An objective evaluation of the upper eyelid position after phacoemulsification cataract surgery. *Semin Ophthalmol* 2019;34:442-5.
 17. Hunt A, Wilscek G, Francis I. Upper eyelid ptosis repair after cataract extraction and the importance of Hering's test. *Plast Reconstr Surg* 2003;111:1366-7.
 18. Parsa FD, Wolff DR, Parsa NN, Elahi aE E. Upper eyelid ptosis repair after cataract extraction and the importance of Hering's test. *Plast Reconstr Surg* 2001;108:1527-36.
 19. Wang Y, Lou L, Liu Z, Ye J. Incidence and risk of ptosis following ocular surgery: a systematic review and meta-analysis. *Graefes Arch Clin Exp Ophthalmol* 2019;257:397-404.
 20. Patel JI, Blount M, Jones C. Surgical blepharoptosis: the bridle suture factor? *Eye (Lond)* 2002;16:535-7.
 21. Godfrey KJ, Korn BS, Kikkawa DO. Blepharoptosis following ocular surgery: identifying risk factors. *Curr Opin Ophthalmol* 2016;27:31-7.
 22. Ahuero AE, Hatton MP. Eyelid malposition after cataract and refractive surgery. *Int Ophthalmol Clin* 2010;50:25-36.
 23. Song MS, Shin DH, Spoor TC. Incidence of ptosis following trabeculectomy: a comparative study. *Korean J Ophthalmol* 1996;10:97-103.
 24. Perry JD, Kadakia A, Foster JA. A new algorithm for ptosis repair using conjunctival Mullerectomy with or without tarsectomy. *Ophthalmic Plast Reconstr Surg* 2002;18:426-9.
 25. Kavanagh MC, Ohr MP, Czyz CN, et al. Comparison of fibrin sealant versus suture for wound closure in Muller muscle-conjunctiva resection ptosis repair. *Ophthalmic Plast Reconstr Surg* 2009;25:99-102.
 26. Czyz CN, Rich NE, Foster JA, et al. Comparison of postoperative eyelid position using fibrin sealant versus suture for wound closure in Muller's muscle-conjunctiva resection ptosis repair. *Plast Reconstr Surg* 2011;128:423-30.
 27. Putterman AM. Re: "Effect of unilateral blepharoptosis on contralateral eyelid position". *Ophthalmic Plast Reconstr Surg* 2005;21:324.
 28. Putterman AM, Urist MJ. Muller's muscle-conjunctival resection ptosis procedure. *Ophthalmic Surg* 1978;9:27-32.
 29. Bodian M. Lip droop following contralateral ptosis repair. *Arch Ophthalmol* 1982;100:1122-4.
 30. Cetinkaya A, Kersten RC. Surgical outcomes in patients with bilateral ptosis and Hering's dependence. *Ophthalmology* 2012;119:376-81.
 31. Nemet AY. The effect of Hering's law on different ptosis repair methods. *Aesthet Surg J* 2015;35:774-81.
 32. Schmidtke K, Buttner-Ennever JA. Nervous control of eyelid function: a review of clinical, experimental and pathological data. *Brain* 1992;115 Pt 1:227-47.
 33. Pan E, Yu J, Zhang S, et al. Retrospective analysis of the effect of Hering's law on outcomes of surgical correction of ptosis. *Ann Plast Surg* 2018;80:242-4.
 34. Scoppettuolo E, Chadha V, Bunce C, et al. British Oculoplastic Surgery Society (BOPSS) national ptosis survey. *Br J Ophthalmol* 2008;92:1134-8.
 35. Choudhary MM, Chundury R, McNutt SA, Perry JD. Eyelid contour following conjunctival mullerectomy with or without tarsectomy blepharoptosis repair. *Ophthalmic Plast Reconstr Surg* 2016;32:361-5.
 36. Patel RM, Aakalu VK, Setabutr P, Putterman AM. Efficacy of Muller's muscle and conjunctiva resection with or

- without tarsectomy for the treatment of severe involucional blepharoptosis. *Ophthalmic Plast Reconstr Surg* 2017;33:273-8.
37. La Porta Weber S, Becco de Souza R, Gomes JA, Hofling-Lima AL. The use of the esclera scleral contact lens in the treatment of moderate to severe dry eye disease. *Am J Ophthalmol* 2016;163:167-73.
38. Wouters RJ, van den Bosch WA, Mulder PG, Lemij HG. Upper eyelid motility in blepharoptosis and in the aging eyelid. *Invest Ophthalmol Vis Sci* 2001;42:620-5.