

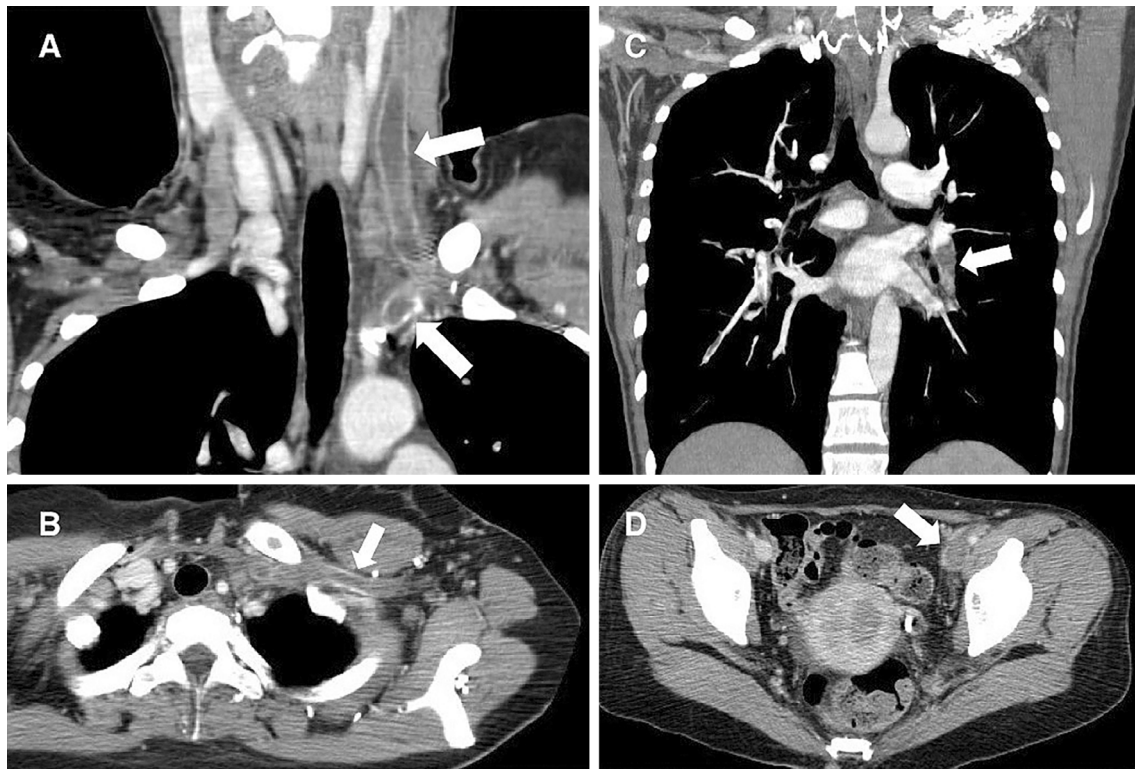
Multiple Deep Vein Thrombosis

Shumpei Onishi, Toshihisa Ichiba and Hiroshi Naito

Key words: deep vein thrombosis, oral contraceptive pill, endometrial carcinoma

(Intern Med 55: 3685-3686, 2016)

(DOI: 10.2169/internalmedicine.55.7691)



Picture.

A 46-year-old woman with a history of abnormal vaginal bleeding and who was taking oral contraceptive pills presented to the emergency department complaining of pain in her upper and lower extremities. Three weeks previously, she had experienced pain and swelling in her left lower extremity. Ten days previously, she had experienced left neck pain and facial swelling, but the symptoms disappeared a few days later. She subsequently experienced pain in her left upper extremity. Contrast-enhanced computed tomography (CT) showed deep vein thrombosis (DVT) in the internal jugular vein with extension to the left brachiocephalic and

subclavian veins (Picture A and B). The CT scan also showed pulmonary embolism (Picture C), DVT in the left lower extremity, and the mass of an endometrial carcinoma (Picture D). Hormone replacement therapy and cancer increase the risk of multiple vein thrombosis (1, 2). She stopped taking the contraceptive pills, and anticoagulation therapy was initiated.

The authors state that they have no Conflict of Interest (COI).

References

1. Sweetland S, Beral V, Balkwill A, et al. Venous thromboembolism risk in relation to use of different types of postmenopausal hormone therapy in a large prospective study. *J Thromb Haemost* **10**: 2277-2286, 2012.
2. Hingorani AP, Ascher E, Markevich N, et al. Prospective evaluation of combined upper and lower extremity DVT. *Vasc Endovascular Surg* **40**: 131-134, 2006.

The Internal Medicine is an Open Access article distributed under the Creative Commons Attribution-NonCommercial-NoDerivatives 4.0 International License. To view the details of this license, please visit (<https://creativecommons.org/licenses/by-nc-nd/4.0/>).

© 2016 The Japanese Society of Internal Medicine
<http://www.naika.or.jp/imonline/index.html>