

## Hepatosplenic Candidiasis Without Prior Documented Candidemia: An Underrecognized Diagnosis?

JOFFREY VAN PREHN,<sup>a</sup> C. WILLEMIEN MENKE-VAN DER HOUVEN VAN OORDT,<sup>b</sup> MADELON L. DE ROOIJ,<sup>c</sup> ELLEN MEIJER,<sup>d</sup> MARIJE K. BOMERS,<sup>c</sup> KARIN VAN DIJK<sup>a</sup>

Departments of <sup>a</sup>Medical Microbiology and Infection Control, <sup>b</sup>Medical Oncology, <sup>c</sup>Internal Medicine, and <sup>d</sup>Hematology, VU University Medical Center, Amsterdam, The Netherlands

Disclosures of potential conflicts of interest may be found at the end of this article.

**Key Words.** Hepatosplenic candidiasis • *Candida* • Candidemia • Invasive candidiasis

### ABSTRACT

**Introduction.** Patients with a history of chemotherapy or stem cell transplantation (SCT) and prolonged neutropenia are at risk for hepatic and/or splenic seeding of *Candida*. In our experience, hepatosplenic candidiasis (HSC) without documented candidemia often remains unrecognized.

**Case presentations.** We describe three cases of HSC without documented candidemia and the challenges in establishing the diagnosis and adequately treating this condition. The first patient had a history of SCT for treatment of breast cancer and was scheduled for hemihepatectomy for suspected liver metastasis. A second opinion at our institute resulted in the diagnosis of hepatic candidiasis without prior documented candidemia, for which she was treated successfully with fluconazole. The second case demonstrates the limitations of (blood and tissue) cultures and the value of molecular methods to confirm the diagnosis. Case 3 illustrates treatment challenges, with ongoing dissemination and insufficient source control despite months of antifungal therapy, eventually resulting in a splenectomy.

**Literature review.** A structured literature search was performed for articles describing any patient with HSC and

documented blood culture results. Thirty articles were available for extraction of data on candidemia and HSC. Seventy percent (131/187) of patients with HSC did not have documented candidemia. The majority of HSC events were described in hematologic patients, although some cases were described in patients with solid tumors treated with SCT ( $n = 1$ ) or chemotherapy and a history of leukopenia ( $n = 2$ ). Current guidelines and practices for diagnosis and treatment are described.

**Conclusion.** Clinicians should be aware that HSC most often occurs without documented candidemia. In case of persistent or unexplained fever or lesions in the liver and/or spleen, a history of neutropenia should place disseminated candidiasis in the differential diagnosis. HSC is not limited to hematological patients and may occur in patients with solid tumors treated with bone marrow-suppressing chemotherapy or SCT. In the latter group, HSC as alternative diagnosis for hepatic metastasis should be considered when lesions are not typical for metastasis. This might prevent unnecessary surgery or inappropriate treatment. *The Oncologist* 2017;22:989–994

**Implications for Practice:** Timely diagnosis of hepatosplenic candidiasis (HSC) is challenging, but can prevent further complications and dissemination, and may even prevent unnecessary invasive procedures. Clinicians should realize that HSC often occurs without documented candidemia and that sensitivity of blood cultures for candidemia is limited. HSC is not strictly limited to hematologic patients and might also occur in patients with solid tumors treated with intensive chemotherapy or stem cell transplantation. Increased awareness for HSC in patients with any history of neutropenia is of importance to increase detection and prevent serious sequelae.

### INTRODUCTION

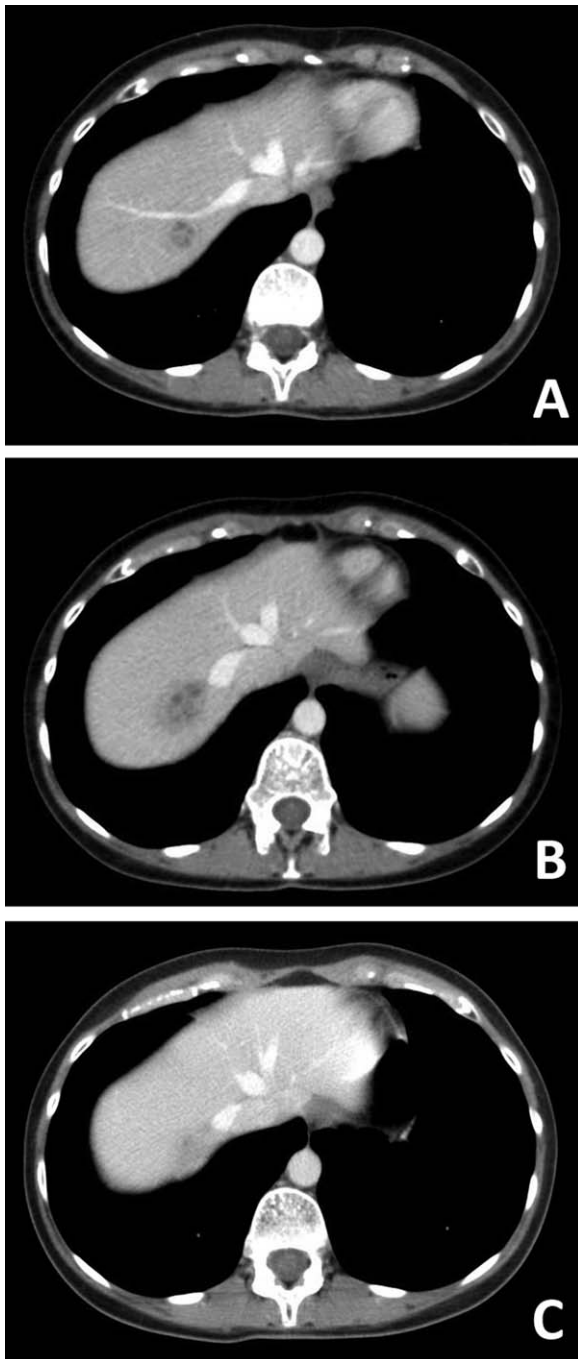
*Candida spp.* are able to cause invasive disease and candidemia, which can result in deep-seated infections [1]. As sensitivity of blood cultures for candidemia is limited, many invasive *Candida* infections may develop without positive blood cultures [2, 3].

Hematologic and also oncologic patients who receive chemotherapy and/or stem cell transplantation (SCT) often experience a (prolonged) period of neutropenia and mucositis. The combination of compromised cellular defense and

Correspondence: Joffrey van Prehn, M.D., Ph.D., Department of Medical Microbiology and Infection Control, VU University Medical Center, PK 1 X 124, P.O. Box 7057, 1007 MB Amsterdam, The Netherlands. Telephone: 31-0-20-44-40488; e-mail: j.vanprehn@vumc.nl Received January 10, 2017; accepted for publication February 16, 2017; published Online First on May 3, 2017. ©AlphaMed Press 1083-7159/2017/\$20.00/0 <http://dx.doi.org/10.1634/theoncologist.2017-0019>

This is an open access article under the terms of the Creative Commons Attribution-NonCommercial-NoDerivs License, which permits use and distribution in any medium, provided the original work is properly cited, the use is non-commercial and no modifications or adaptations are made.

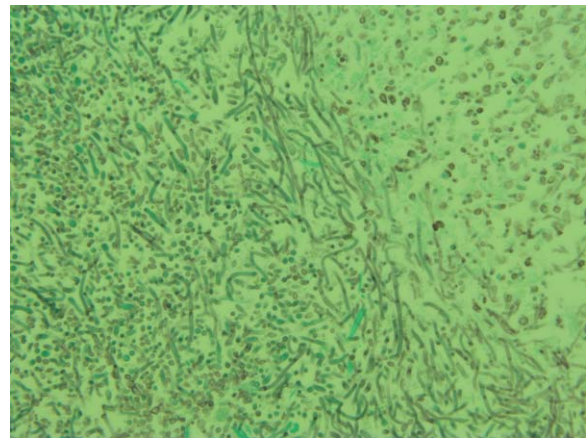
The copyright line for this article was changed on 26 June 2017 after original online publication. This notice is included in the online and print versions.



**Figure 1.** Case 1: Contrast-enhanced abdominal computed tomography scans of the lesion in segment VII at  $t = 14$  months after diagnosis of breast cancer (A), at  $t = 18$  months (B), and at  $t = 27$  months when fluconazole treatment was completed (C). Initial growth and, after treatment, regression of liver lesions was seen.

breach in intestinal mucosal integrity results in an increased risk of *Candida* translocation and deep-seated infections, most commonly involving the liver and spleen [4, 5]. Hepatosplenic candidiasis (HSC) often becomes apparent only after neutrophil recovery, adding to the challenge in making the diagnosis [5, 6].

Clinicians might not be aware that HSC often occurs without prior documented candidemia. Underrecognized HSC may be mistaken for metastases and can have serious consequences for patients, especially when additional, inappropriate treatment

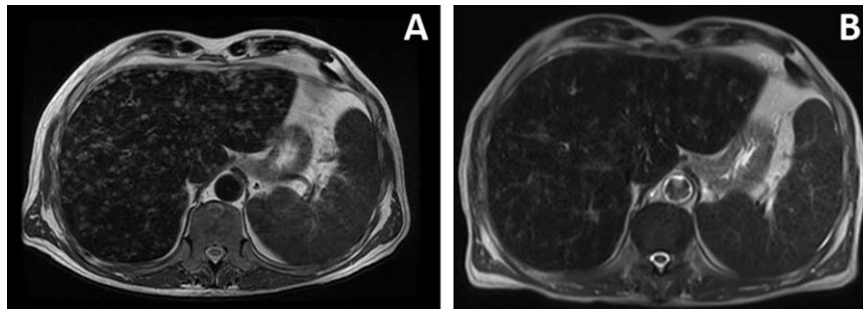


**Figure 2.** Case 1: Microscopic image of Grocott methenamine silver stain of fine needle aspirate of a liver lesion. Multiple fungal spores intermingled with hyphae and pseudohyphae can be seen, consistent with *Candida spp.*

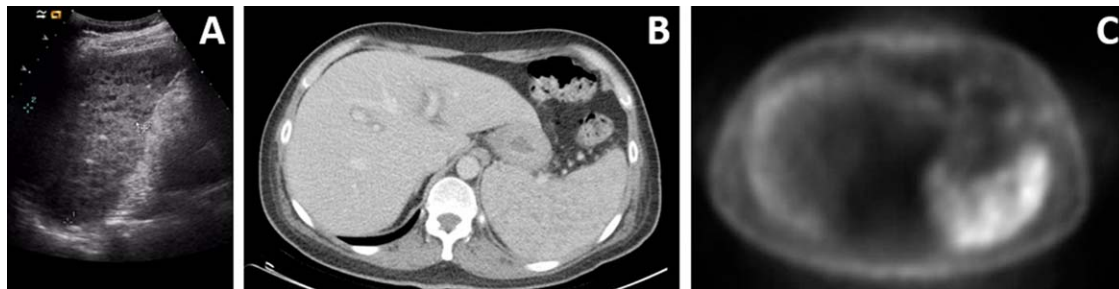
such as surgery and chemo- or immunotherapy is initiated. To emphasize the importance of diagnosing HSC without prior documented candidemia, we here present three illustrative cases and a review of the literature on HSC and candidemia.

#### CASE 1

A 37-year-old female presented for a second opinion at our institute with respect to liver lesions, for which a hemihepatectomy was scheduled elsewhere, as metastases from a previous breast cancer or aspergilloma were suspected. Nineteen months prior (at  $t = 0$ ), a cT2N<sub>micro</sub> (sentinel node) triple-negative breast cancer was diagnosed, for which neoadjuvant chemotherapy was initiated. She received dose dense doxorubicin + cyclophosphamide followed by twice low-dose cyclophosphamide + thiotepa + carboplatin followed by SCT. She subsequently developed pulmonary consolidations 4 months after treatment, for which voriconazole was initiated. Antifungal treatment was ceased soon thereafter because of rapid clinical recovery and negative microbiological results for *Aspergillus* infection. Breast-conserving surgery at 5 months revealed complete pathological response (yTON0) and was followed by radiotherapy. At 11 months, she was admitted for a short period of time with an influenza B infection. Computed tomography (CT) imaging during admission revealed several liver lesions, which, in retrospect, were already present on previous imaging. Fine needle aspiration biopsy (FNAB) showed necrosis; tumor necrosis was not ruled out. Additionally, possible fungal hyphae were seen. Core needle biopsy of a liver lesion showed fibrosis, chronic inflammation, and hemorrhage, but no signs of fungi. Follow-up CT at 14 months showed decline of the liver lesions, although at 18 months a lesion in segment VII had increased from 1.5 to 3.5 cm in diameter (Fig. 1A and 1B), while a lesion in segment VIII remained 1 cm in diameter. At presentation for second opinion, the patient was in good health. Routine blood cell count, inflammation parameters, and renal and liver tests were normal, with only a mild thrombocytopenia. Revision of the FNAB and core needle biopsy taken elsewhere resulted in the conclusion that the Grocott stain of the FNAB showed spores intermingled with hyphae and pseudohyphae, consistent with *Candida spp.* (Fig. 2) [7]. Panfungal and *Candida* polymerase chain reaction (PCR) testing on an unstained histological slide



**Figure 3.** Case 2: T2-weighted magnetic resonance image of the liver before (A) and after (B) 2 weeks of empirical treatment of liver abscesses with ciprofloxacin, metronidazole, and anidulafungin. Hepatosplenomegaly and multiple focal hepatic lesions can be seen. The lesions decreased during antibiotic treatment.



**Figure 4.** Case 3: Ultrasound (A), contrast-enhanced computed tomography (B), and fluorodeoxyglucose (FDG) positron emission tomography (FDG-PET) (C) images of splenic lesions. Ultrasound shows multiple hypoechoic lesions, CT shows splenomegaly with inhomogeneous enhancement of the spleen, and FDG-PET shows extensive multifocal FDG uptake in the spleen, consistent with inflammation.

was inhibited and therefore not interpretable. The diagnosis of hepatic candidiasis was supported by positive *Candida* antibody (mannan) serology (23.4 AU/mL, cut-off for positive test is >5.0 AU/mL). Serum *Candida* antigen (anti-mannan) and beta-D-glucan tests were negative. Outpatient treatment with fluconazole 400 mg once daily administered orally was initiated at 21 months. Follow-up CT at 27 months showed regression of the liver lesions (Fig. 1C), and fluconazole therapy was ceased. The patient remains in good health at the time of writing this paper, with stable follow-up imaging.

## CASE 2

A 63-year-old male had received two courses of remission-induction chemotherapy for myelodysplastic syndrome (MDS)-refractory anemia with excess blasts 1 according to standard protocol (first course idarubicin + cytarabine and second course daunorubicin + cytarabine) plus lenalidomide (HOVON 132 trial, EudraCT number 2013-002843-26). The first course was complicated with an *Enterococcus faecium* catheter-related bloodstream infection (CRBSI), with 2 days of intensive care unit admission. Antibiotic treatment consisted of meropenem, vancomycin, and anidulafungin, which was soon ceased after catheter removal. During the second course, he experienced fever and night sweats while in neutropenia without a clear focus of infection and was treated empirically with meropenem, vancomycin, and liposomal amphotericin-B. Blood cultures were positive with *E. faecium* and *Staphylococcus hominis*, and a peripheral-inserted central catheter was first exchanged and later removed, as another CRBSI was suspected. Surveillance throat cultures were positive for *Candida albicans* and *C. glabrata*. After discharge from the hospital, the night sweats ceased, although at the time of neutrophil recovery, increasingly

elevated liver enzymes were seen, in particular ALP (755 U/L) and GGT (224 U/L). Ultrasound imaging showed no focal liver lesions, but subsequent magnetic resonance imaging (MRI) revealed hepatosplenomegaly and multiple T2 hyperintense lesions (Fig. 3A). The scheduled allogeneic SCT was postponed. Histopathological analysis of a core needle biopsy of the liver was consistent with abscess. Microbiological analysis with microscopy and culture showed no evidence for infection with (myco)bacteria or fungi, and serology did not indicate a parasitic infection. As no pathogen had been identified, the patient was treated empirically with 3 weeks of intravenous (IV) ciprofloxacin, metronidazole, vancomycin, and anidulafungin (200 mg daily). Additional molecular analysis (PCR) of the biopsy was negative for *Aspergillus* and mycobacteria, and the material was sent to a mycological reference center (Radboud University, Nijmegen, The Netherlands) for panfungal PCR. Panfungal PCR result was positive, and subsequent sequencing indicated presence of *C. albicans* and *C. tropicalis* DNA. Meanwhile, an MRI 2 weeks after start of empirical antimicrobial treatment showed a decrease of the hepatic lesions (Fig. 3B); unfortunately, this scan also revealed a mass suspect for colon carcinoma. As the diagnosis of disseminated candidiasis was made, the patient received 2 months of additional treatment with fluconazole (400 mg daily). During this period, he underwent a hemicolectomy for a pT3N0 colon carcinoma. MDS treatment will be continued once he has recovered from surgery. Follow-up CT imaging did not show focal liver lesions, and liver tests (ALP and GGT) have improved drastically.

## CASE 3

Eight years ago, a 47-year-old male with mantle cell lymphoma (MCL) was treated with three courses of rituximab +

cyclophosphamide + doxorubicin + vincristine + prednisone (R-CHOP) followed by two courses of high-dose cytarabine combined with rituximab. During the latter course, he developed fever and was treated empirically with imipenem, pending the culture results. Soon after initiation of antibiotic therapy, he developed purple skin lesions, suggestive of candidemia, for which voriconazole was added to the antibiotic treatment. No candidemia or bacteremia was demonstrated; however, *C. tropicalis* was cultured from a skin biopsy. Ophthalmic examination revealed no ocular candidiasis. However, abdominal ultrasound showed splenomegaly with multiple hypoechogenic splenic lesions with a hyperechogenic center, consistent with *Candida* micro-abscesses (Fig. 4A). On fluorodeoxyglucose (FDG) positron emission tomography (PET) CT (FDG-PET-CT), splenomegaly was visible with inhomogenous enhancement of the spleen and extensive multifocal FDG uptake in the spleen (Fig. 4B and 4C). Furthermore, regression of lymphoma masses was seen. On the presumptive diagnosis of splenic candidiasis, the patient was treated consecutively with caspofungin, high-dose fluconazole (800 mg daily), and conventional amphotericin-B, as fever either persisted or quickly recurred after initial response. After 5 weeks of conventional amphotericin-B therapy, the maximum cumulative dose was reached and therapy was ceased. After discharge, the patient developed fever and was readmitted and high-dose fluconazole (600 mg twice daily) was initiated, as persistent invasive candidiasis was suspected. FDG-PET imaging revealed additional FDG-positive lesions in the bones, which could be *Candida* seeding or lymphoma. Treatment was switched to IV anidulafungin 100 mg daily for 2 months, and additionally a splenectomy was performed in an attempt to control the presumptive source of the ongoing *Candida* seeding. Cultures remained negative, but pus from the spleen was calcofluor positive (fungal stain for microscopy). Imaging performed after splenectomy revealed progression of lesions, with new renal and myocardial localization. Eventually, treatment was prolonged with fluconazole 800 mg orally twice daily for a year. Follow-up imaging (FDG-PET CT) 6 months after splenectomy finally showed complete resolution of all infectious foci. Unfortunately, in December 2014, recurrent MCL was diagnosed. The patient was retreated with three courses of R-CHOP followed by two courses of high-dose cytarabine combined with rituximab consolidated by BEAM chemotherapy (carmustine + etoposide + cytarabine + melphalan) and autologous SCT, with achievement of complete remission.

## DISCUSSION

### Clinical Presentation

The cases presented underline that a patient without documented candidemia but with a history of neutropenia may well suffer from HSC. A wide range of presenting signs, ranging from imaging abnormalities only (case 1) to abnormal liver tests (cases 2) to persistent fever of unknown origin (case 3), challenge the diagnosis of chronic disseminated candidiasis [8]. In many cases, HSC becomes apparent only after neutrophil recovery [5, 6]. Deep-seated infections may remain localized without positive blood cultures [9]. Because of these challenges, we believe that many cases of HSC remain unrecognized.

### Diagnosis

The diagnosis of invasive fungal disease is often difficult to establish, as illustrated by the consensus definitions of the EORTC/MSG study group that divides invasive fungal disease into “possible,” “probable,” and “proven” [10]. Any culture of yeast from a normal sterile body site or blood, or a histopathologic, cytopathologic, or direct microscopic aspirate or biopsy that contains yeast cells, classifies as “proven” invasive fungal disease. There are several diagnostic techniques available for the diagnosis of chronic disseminated candidiasis. The European Society for Clinical Microbiology and Infectious Diseases recommends the following investigations as essential for the diagnosis of chronic disseminated candidiasis: blood cultures, direct microscopy, histopathology, and culture of tissues/sterile body fluids [2]. Further recommended investigations are beta-D-glucan serology and mannan/anti-mannan serology (mannan is a *Candida* cell wall constituent, beta-D-glucan is a fungal cell wall constituent, not specific for *Candida*) [2]. No recommendations are made regarding PCR-based techniques, because the available data are limited and hampered by the use of different PCR techniques. However, as we demonstrate in case 2, a positive (validated) PCR result on a biopsy of normally sterile tissue can confirm the diagnosis. In many cases, the presumptive diagnosis of HSC is based on imaging only, as invasive procedures are not always possible, blood cultures remain negative due to lack of sensitivity or use of empiric antifungal therapy, serologic tests might not be available, and confirmation by biopsy lacks sensitivity due to sampling error [8, 11]. Imaging abnormalities may range from focal hepatic (case 1) and/or splenic lesions to multifocal lesions of the entire liver and/or spleen (cases 2 and 3) and may involve other organs such as the kidneys and heart (case 3).

### Literature Review of HSC and Candidemia

To investigate to what extent HSC occurs without documented candidemia, we systematically searched the literature for studies that included patients with HSC and documented blood culture results. A PubMed search was conducted on January 23, 2017, with the following details: hepatosplenic [All Fields] AND (“candidiasis”[MeSH Terms] OR “candidiasis”[All Fields]). The search yielded 138 hits after removal of 1 duplicate (see supplemental online Table). Sixty-six studies were excluded because no full-text article was available ( $n = 43$ ) or the full-text article was not written in English ( $n = 23$ ). After screening of full-text articles, another 42 studies were excluded because the studies did not describe patients with HSC ( $n = 19$ ), did not study disease caused by *Candida spp.* ( $n = 2$ ), or did not include data on candidemia, that is, did not mention whether blood cultures were positive or negative ( $n = 21$ ). Thirty articles, describing 187 patients with HSC and available blood culture results, remained for extraction of data. Documented positive blood cultures with *Candida* were present in only 56 (30%) of these patients. Of these 187 included patients, 181 patients had a hematological malignancy; three of the 181 patients had undergone a previous SCT. Three patients had solid tumors: two had received chemotherapy for rhabdomyosarcoma (cyclophosphamide, dacarbazine, and doxorubicin; severely neutropenic) and osteosarcoma (vincristine, prednisone, and ifosfamide; rapidly dropping leukocyte count), respectively, and one underwent autologous SCT for testicular cancer [8, 12]. One patient without an underlying malignancy

had primary sclerosing cholangitis and Crohn's disease treated with prednisone 10–20 mg during the year prior to diagnosis of HSC [13]. Loss of integrity of intestinal mucosa in combination with prednisone may have contributed to *Candida* seeding in this patient. In conclusion, the majority of cases has been describe in patients with hematological malignancies, although HSC is not limited to hematological patients and may occur in patients with solid tumors receiving intensive chemotherapy affecting leukocyte and neutrophil counts.

### Improving Detection

Detection of HSC may first be improved by acknowledging the limited sensitivity of blood cultures for candidemia. This limited sensitivity can be partly overcome by taking repeated blood cultures in a neutropenic patient with unexplained or persistent fever. Awareness that in 70% of HSC cases there is no prior documented candidemia may increase clinical suspicion. Multifocal lesions of parenchymatous organs on imaging in any patient with a history of neutropenia should prompt clinicians to put disseminated candidiasis in the differential diagnosis. This is especially important in patients with solid tumors in which candidiasis might be mistaken for metastasis. If a patient with a history of neutropenia has liver lesions and imaging or biopsy is not typical for metastasis, one should try to confirm the diagnosis of HSC. A repeated biopsy may be contemplated, as the negative test could have been a result of sampling error. In our opinion, when there are no other signs or symptoms of metastatic disease, empirical treatment with fluconazole may even be warranted before additional surgery or chemotherapy is planned. Finally, when microbiological cultures remain negative, molecular PCR testing (on biopsy) and *Candida* serology could help to establish the diagnosis.

### Treatment

There is little evidence about the optimal treatment, and the optimal duration of treatment likely depends on the level of immunosuppression at the moment of diagnosis as well as the months following diagnosis. Empirical treatment is usually initiated with either liposomal amphotericin-B or an echinocandin, followed by “step-down” therapy with oral fluconazole [11, 14]. We feel initial therapy with oral fluconazole for those without severe, systemic symptoms is a reasonable alternative; besides extent and severity of infection, other deciding factors include previous antifungal therapy and culture results, toxicity, and costs. The Infectious Diseases Society of America advises that treatment should be continued until radiologic lesions are

calcified or resolved, although others define response to treatment as resolution of clinical and biological signs with stable or reduced lesions on imaging [8, 14]. Antifungal therapy should be continued throughout additional chemotherapy courses or SCT to prevent relapse [14].

In case 1, 6 months of oral fluconazole treatment was sufficient and resulted in near resolution of all the liver lesions initially noted. Moreover, a scheduled hemihepatectomy was prevented. Case 2 responded well to 3 weeks of intravenous echinocandin treatment followed by 2 months of fluconazole. In case 3, treatment remained troublesome (of note, meanwhile in our hospital, conventional amphotericin-B has been replaced by less toxic liposomal amphotericin-B) and dissemination was hard to control, finally resulting in a splenectomy.

### CONCLUSION

In conclusion, timely diagnosis of HSC is challenging but can prevent further complications and dissemination and may even prevent unnecessary invasive procedures. Clinicians should realize that HSC often occurs without documented candidemia and that sensitivity of blood cultures for candidemia is limited. HSC is not strictly limited to hematologic patients and might also occur in patients with solid tumors treated with intensive chemotherapy or SCT. Increased awareness for HSC in patients with any history of neutropenia is of importance to increase detection and prevent serious sequelae.

### AUTHOR CONTRIBUTIONS

**Conception/Design:** Joffrey van Prehn, C. Willemien Menke-van der Houven van Oordt, Madelon L. de Rooij, Ellen Meijer, Marije K. Bomers, Karin van Dijk  
**Provision of study material or patients:** Joffrey van Prehn, C. Willemien Menke-van der Houven van Oordt, Madelon L. de Rooij, Ellen Meijer, Marije K. Bomers, Karin van Dijk  
**Collection and/or assembly of data:** Joffrey van Prehn, C. Willemien Menke-van der Houven van Oordt, Madelon L. de Rooij, Ellen Meijer, Marije K. Bomers, Karin van Dijk  
**Data analysis and interpretation:** Joffrey van Prehn, C. Willemien Menke-van der Houven van Oordt, Madelon L. de Rooij, Ellen Meijer, Marije K. Bomers, Karin van Dijk  
**Manuscript writing:** Joffrey van Prehn, C. Willemien Menke-van der Houven van Oordt, Madelon L. de Rooij, Ellen Meijer, Marije K. Bomers, Karin van Dijk  
**Final approval of manuscript:** Joffrey van Prehn, C. Willemien Menke-van der Houven van Oordt, Madelon L. de Rooij, Ellen Meijer, Marije K. Bomers, Karin van Dijk

### DISCLOSURES

The authors indicated no financial relationships.

### REFERENCES

1. Kullberg BJ, Arendrup MC. Invasive Candidiasis. *N Engl J Med* 2015;373:1445–1456.
2. Cuenca-Estrella M, Verweij PE, Arendrup MC et al. ESCMID\* guideline for the diagnosis and management of *Candida* diseases 2012: Diagnostic procedures. *Clin Microbiol Infect* 2012;18(suppl 7):9–18.
3. Leroy O, Gangneux JP, Montravers P et al. Epidemiology, management, and risk factors for death of invasive *Candida* infections in critical care: A multicenter, prospective, observational study in France (2005–2006). *Crit Care Med* 2009;37:1612–1618.
4. Anttila VJ, Elonen E, Nordling S et al. Hepatosplenic candidiasis in patients with acute leukemia: Incidence and prognostic implications. *Clin Infect Dis* 1997;24:375–380.
5. Sallah S, Semelka RC, Wehbie R et al. Hepatosplenic candidiasis in patients with acute leukaemia. *Br J Haematol* 1999;106:697–701.
6. Ramaert B, Desjardins A, Lortholary O. New insights into hepatosplenic candidosis, a manifestation of chronic disseminated candidosis. *Mycoses* 2012;55:e74–e84.
7. Guarner J, Brandt ME. Histopathologic diagnosis of fungal infections in the 21st century. *Clin Microbiol Rev* 2011;24:247–280.
8. De Castro N, Mazoyer E, Porcher R et al. Hepatosplenic candidiasis in the era of new antifungal drugs: A study in Paris 2000–2007. *Clin Microbiol Infect* 2012;18:E185–E187.
9. Clancy CJ, Nguyen MH. Finding the “missing 50%” of invasive candidiasis: How nonculture diagnostics will improve understanding of disease spectrum and transform patient care. *Clin Infect Dis* 2013;56:1284–1292.
10. De Pauw B, Walsh TJ, Donnelly JP et al. Revised definitions of invasive fungal disease from the European Organization for Research and Treatment of Cancer/Invasive Fungal Infections Cooperative Group and the National Institute of Allergy and Infectious Diseases Mycoses Study Group (EORTC/MSG) Consensus Group. *Clin Infect Dis* 2008;46:1813–1821.
11. Ullmann AJ, Akova M, Herbrecht R et al. ESCMID\* guideline for the diagnosis and management of *Candida* diseases 2012: Adults with haematological malignancies and after haematopoietic stem cell transplantation (HCT). *Clin Microbiol Infect* 2012;18(suppl 7):S3–67.

12. Thaler M, Pastakia B, Shawker TH et al. Hepatic candidiasis in cancer patients: The evolving picture of the syndrome. *Ann Intern Med* 1988;108:88–100.

13. Spindel SJ, Darouiche RO, Saeed ZA. Hepatosplenic candidiasis in non-neutropenic patients: A case report and literature survey. *Int J Antimicrob Agents* 1996;7:149–152.

14. Pappas PG, Kauffman CA, Andes DR et al. Clinical practice guideline for the management of candidiasis: 2016 update by the Infectious Diseases Society of America. *Clin Infect Dis* 2016;62:e1–e50.



See <http://www.TheOncologist.com> for supplemental material available online.

**For Further Reading:**

Grainne M. O’Kane, Catherine Labbé, Mark K. Doherty. Monitoring and Management of Immune-Related Adverse Events Associated With Programmed Cell Death Protein-1 Axis Inhibitors in Lung Cancer. *The Oncologist* 2017;22:70–80.

**Abstract:**

Monoclonal antibodies targeting programmed cell death protein-1 (PD-1) represent a new treatment paradigm in non-small cell lung cancer. Three phase III trials have demonstrated a survival benefit and improved tolerability of nivolumab and pembrolizumab when compared with standard second-line chemotherapy. Nevertheless, the adverse events associated with PD-1 inhibitors are unique; early recognition and treatment are essential. This review summarizes the required monitoring and appropriate management of immune-related adverse events in lung cancer patients receiving these agents.