

Original research

Confocal biomicroscopic changes of the corneal layers following femtosecond laser-assisted MyoRing implantation in keratoconus

Heidar Siatiri, Mahmoud Jabbarvand, Mehrdad Mohammadpour, Amirhossein Mollazadeh, Nasim Siatiri, Arash Mirmohammadsadeghi*

Eye Research Center, Farabi Eye Hospital, Tehran University of Medical Sciences, Tehran, Iran

Received 4 June 2016; revised 19 November 2016; accepted 28 November 2016

Available online 28 December 2016

Abstract

Purpose: To evaluate the effect of the femtosecond laser-assisted MyoRing implantation on the confocal biomicroscopic findings in different corneal layers of the patients with keratoconus.

Methods: Twelve eyes of 12 patients with mild to moderate keratoconus (keratometry between 48 and 52 diopters) and intolerance to hard contact lens entered the study. All the included patients underwent femtosecond laser-assisted MyoRing (Dioptex GmbH, Linz, Austria) implantation. The confocal biomicroscopy of the cornea was performed for all corneal layers in the center and periphery preoperatively and 3 and 6 months postoperatively. The cell counts and the qualitative findings in each layer of the cornea were compared between preoperative and 3 and 6 months postoperative images.

Results: Compared with preoperative values, the central epithelial and the central and peripheral midstromal cell counts were significantly decreased 6 months after MyoRing implantation ($P = 0.015$, $P = 0.010$ and 0.005 , respectively). Furthermore, compared with preoperative values, the peripheral posterior stromal cell count was significantly decreased 3 months after MyoRing implantation ($P = 0.033$). In the qualitative analysis, highly reflective nuclei in the basal epithelium, transient disruption in the subepithelial nerve plexus, increase in the reflectivity of the stromal keratocyte, and normal endothelial cell morphology were seen.

Conclusions: Our study demonstrated some findings similar to that reported in intrastromal corneal ring segments (ICRS): decreased central epithelial cell counts, highly reflective nuclei in the basal epithelium, transient disruption in the subepithelial nerve plexus, and normal endothelial cell count and morphology. In addition, a decrease in the central and peripheral midstromal, transient decrease in posterior stromal cell counts, and absence of amorphous depositions were in contrast with the findings reported in ICRS.

Copyright © 2017, Iranian Society of Ophthalmology. Production and hosting by Elsevier B.V. This is an open access article under the CC BY-NC-ND license (<http://creativecommons.org/licenses/by-nc-nd/4.0/>).

Keywords: Keratoconus; Confocal biomicroscopy; MyoRing

Introduction

Confocal biomicroscopy is a non-invasive tool that evaluates histologic changes in multiple layers of cornea.¹ This imaging tool is also valuable to assess histopathologic changes in the keratoconus.^{2–4} In the keratoconus, confocal microscopy showed lower density of basal epithelial cells, sub-basal

long nerves, anterior, mid- and posterior stromal keratocytes, and endothelial cells, and thicker subbasal and stromal nerves.^{2,3}

The MyoRing is a complete intrastromal ring that has been successfully used in the management of the patients with different grades of keratoconus.^{5–9} This instrument has been used to treat the corneal ectasia after refractive surgery.^{10,11} The MyoRing may have some beneficial or adverse effects on the structures in multiple levels of cornea. To our knowledge, no study evaluated the changes of different corneal layers following MyoRing implantation (with the help of

* Corresponding author. Farabi Eye Hospital, Ghazvin square, Tehran, Iran.
E-mail address: alsadeghi@yahoo.com (A. Mirmohammadsadeghi).

Peer review under responsibility of the Iranian Society of Ophthalmology.

femtosecond laser) in keratoconus. In this study, confocal biomicroscopy was used to detect changes of different corneal layers after femtosecond laser-assisted MyoRing implantation in a group of patients with keratoconus.

Methods

In a prospective study, approved by Institutional Review Board of the Farabi Eye Research Center, 15 consecutive patients diagnosed with mild to moderate keratoconus (Kmax between 48 and 52 diopters) and intolerance to hard contact lens in 2013 at the cornea clinic of the Farabi Eye Hospital were included. The patients under 20 years of age, with corneal thickness <380 μm in the center or <400 μm in the incision site, central corneal scar, previous ophthalmic surgery, pregnancy and lactation, history of herpes simplex keratitis, collagen cross-linking, immunologic or connective tissue diseases, and patients that did not return for follow-up were excluded from the study. The study was compliant with the principles of the Declaration of Helsinki. Informed consent was obtained from all patients.

Age and gender of the patients were noted in history taking. Complete ophthalmologic examinations were done in each visit. The visual acuity findings were converted to logarithm of the minimum angle of resolution (logMAR) for analysis. All the included patients underwent femtosecond laser-assisted MyoRing (Dioptex GmbH, Linz, Austria) implantation. All surgical procedures were done under topical anesthesia by one of the authors (M.J.). An intrastromal pocket with 9 mm diameter in the depth of 280–300 μm from the corneal surface was created with the help of femtosecond laser. Then a 4.5 mm tunnel incision was created in the steep meridian of the cornea and the MyoRing, with the diameter of 5 mm and thickness of 280 μm was inserted into the pocket. No suture was placed in the incision site. Therapeutic contact lens was applied for 3 days after the surgery. Antibiotic and steroid eyedrops were prescribed until two weeks after the operation. The patients were followed at 3 and 6 months after the surgery.

The confocal biomicroscopy of the cornea was performed with the Heidelberg HRT3 Rostock Cornea Module (Heidelberg Engineering GmbH, Dossenheim, Germany). After topical anesthesia with tetracaine 0.5% eyedrop and instillation of the acrylic gel on the objective part (40 \times) of the instrument, the patient fixated on an external target, and the microscope was placed in contact with the cornea by a disposable cup. This imaging was performed for all corneal layers in the center and periphery preoperatively and 3 and 6 months postoperatively. The epithelial and endothelial images were performed at the distance of 1–5 μm and 470–500 μm , respectively, from the corneal surface. According to the Ruckhofer and colleagues study,¹² in the corneal stroma, the keratocytes were evaluated in three different levels. Anterior stroma was defined as the layer four frames below the basal epithelial layer (40–70 μm below the corneal surface). Mid-stroma was defined as the portion with the distance of several frames from the endothelium and epithelium (140–170 μm below the corneal surface). Posterior stroma was defined as the

layer just anterior to Descemet's membrane (370–420 μm below the corneal surface). All confocal images were obtained by one experienced technician and interpreted by one cornea specialist (H.S.). The cells in each level of cornea were counted in five fields. The mean of the cell count in these five fields was calculated and used in the analysis as the cell count for that level. This cell count and the qualitative findings were compared between preoperative and 3 and 6 months postoperative images.

Statistical analysis

The statistical analysis was performed with SPSS version 20 (SPSS Inc., Chicago, IL). Wilcoxon matched pairs test was used to evaluate the differences of pre- and postoperative logMAR, spherical equivalent, and cell counts in each level of cornea. Spearman correlation was used to assess correlation between age or refraction and cell counts in each level of cornea. Mann–Whitney U test was used to evaluate distribution of cell counts across subgroups based on gender and laterality. The level of significance was considered 0.05.

Results

From 15 patients, three patients were excluded from the study: two patients due to previous collagen cross-linking and one due to loss to follow-up. Therefore, 12 eyes of 12 patients (5 males) entered the study. The mean age of the patients was 24.91 ± 2.96 years (range, 20–29 years). Preoperative uncorrected visual acuity was between 20/800 and 20/100 in all patients. The MyoRing was implanted in right eye in 6 patients and in left eye in 6 patients. The mean preoperative spherical equivalent of the patients was -9.11 ± 3.27 diopters (range, -2 to -13.75 diopters). Postoperative uncorrected visual acuity was between 20/50 and 20/20 in all patients. Compared with the preoperative values, the uncorrected visual acuity (logMAR) was significantly improved 6 months after the surgery ($P = 0.001$). The mean postoperative spherical equivalent of the patients was -2.08 ± 0.76 diopters (range, -0.75 to -3.00 diopters). Compared with the preoperative values, the spherical equivalent was significantly improved 6 months after the surgery ($P = 0.001$). In the 6 months follow-up after the surgery, in all cases, the keratometric results showed no significant change and no progression in keratoconus was seen. No intraoperative or postoperative complication was observed in these patients. The mean, standard deviation, and range of cell counts in different levels of cornea are summarized in Table 1.

The P -values of comparing pre- and 3 and 6 months postoperative cell counts in different levels of cornea are demonstrated in Table 2. Compared with preoperative values, the central epithelial ($P = 0.015$) and the central and peripheral midstromal cell counts ($P = 0.010$ and 0.005 , respectively) significantly decreased 6 months after MyoRing implantation. Furthermore, compared with preoperative values, the peripheral posterior stromal cell count was significantly decreased 3 months after MyoRing implantation

Table 1

The mean, standard deviation, and range of cell counts in different levels of corneas that underwent MyoRing implantation.

Variable	Mean \pm SD	Range
Preoperative central epithelial cell count	5977.50 \pm 573.86	4697–6777
3 months postoperative central epithelial cell count	5670.08 \pm 548.92	4610–6536
6 months postoperative central epithelial cell count	5572.00 \pm 701.16	4420–6571
Preoperative peripheral epithelial cell count	5786.83 \pm 569.35	4710–6235
3 months postoperative peripheral epithelial cell count	5740.25 \pm 563.04	4510–6296
6 months postoperative peripheral epithelial cell count	5581.50 \pm 600.05	4450–6496
Preoperative central anterior stromal cell count	1085.00 \pm 71.24	912–1186
3 months postoperative central anterior stromal cell count	1087.25 \pm 88.34	888–1208
6 months postoperative central anterior stromal cell count	1140.33 \pm 77.79	1044–1281
Preoperative peripheral anterior stromal cell count	1108.25 \pm 59.60	974–1179
3 months postoperative peripheral anterior stromal cell count	1117.00 \pm 67.06	1007–1198
6 months postoperative peripheral anterior stromal cell count	1122.08 \pm 110.05	989–1333
Preoperative central midstromal cell count	635.75 \pm 66.31	552–764
3 months postoperative central midstromal cell count	562.00 \pm 76.16	437–715
6 months postoperative central midstromal cell count	551.41 \pm 67.07	464–676
Preoperative peripheral midstromal cell count	630.75 \pm 81.20	528–806
3 months postoperative peripheral midstromal cell count	584.50 \pm 81.78	435–733
6 months postoperative peripheral midstromal cell count	561.58 \pm 40.23	504–603
Preoperative central posterior stromal cell count	373.91 \pm 20.23	354–415
3 months postoperative central posterior stromal cell count	372.58 \pm 35.62	321–453
6 months postoperative central posterior stromal cell count	378.08 \pm 17.89	356–413
Preoperative peripheral posterior stromal cell count	369.66 \pm 16.73	343–394
3 months postoperative peripheral posterior stromal cell count	378.58 \pm 23.72	323–403
6 months postoperative peripheral posterior stromal cell count	378.50 \pm 17.85	361–417
Preoperative central endothelial cell count	3116.75 \pm 331.66	2608–3666
3 months postoperative central endothelial cell count	2948.33 \pm 388.91	2128–3344
6 months postoperative central endothelial cell count	3060.41 \pm 350.21	2432–3543
Preoperative peripheral endothelial cell count	2953.83 \pm 276.64	2254–3260
3 months postoperative peripheral endothelial cell count	2936.16 \pm 315.30	2201–3196
6 months postoperative peripheral endothelial cell count	2999.50 \pm 252.04	2381–3262

SD: Standard deviation.

($P = 0.033$). The differences between other pre- and postoperative values were not statistically significant (Table 2).

In the qualitative analysis, in all patients, the nuclei of both central and peripheral basal epithelial cells at 3 months follow-

Table 2

The P -values of comparing pre- and 3 and 6 months postoperative cell counts in different levels of corneas that underwent MyoRing implantation. The significant values were demonstrated with bold numbers.

Cell counts in different levels of cornea	Preop. and 3 months postop. P -value	Preop. and 6 months postop. P -value	3 and 6 months postop. P -value
Central epithelial	0.099	0.015	0.69
Peripheral epithelial	0.53	0.18	0.099
Central anterior stromal	0.81	0.27	0.20
Peripheral anterior stromal	0.87	0.84	0.87
Central midstromal	0.06	0.010	0.13
Peripheral midstromal	0.13	0.005	0.48
Central posterior stromal	0.52	0.30	0.41
Peripheral posterior stromal	0.033	0.092	0.87
Central endothelial	0.084	0.34	0.63
Peripheral endothelial	0.69	0.27	0.07

Preop: Preoperative

Postop: Postoperative.

up were more prominent and reflective than preoperative nuclei (Fig. 1). This prominence was decreased in 6 months follow-up, and the nuclei were approximately similar to preoperative nuclei (Fig. 1).

At 3 months follow-up, compared with the preoperative appearance, the subepithelial nerves were disrupted, irregular, and thin (Fig. 2). In 6 months follow-up, the nerves were partly recovered in regularity and thickness, but were again thinner and more tortuous than preoperative nerves (Fig. 2).

At 3 and 6 months postoperative follow-up, in the central and peripheral anterior and mid-stromal layers, the keratocytes showed more reflectivity than preoperative images (Figs. 3 and 4). These changes were less prominent in the posterior stromal layer (Fig. 5). The endothelial layer showed no significant postoperative change in the histopathologic appearance (Fig. 6).

There was no significant correlation between age of the patients and pre- and postoperative cell counts in different levels of cornea (all $P > 0.05$). Moreover, there was no significant correlation between spherical equivalent of the patients and pre- and postoperative cell counts in different levels of cornea (all $P > 0.05$). The distribution of cell counts in different levels of cornea was the same across most subgroups based on laterality (right or left eye MyoRing implantation) and gender (all $P > 0.05$).

Discussion

To our knowledge, this study was the first study that evaluated central and peripheral corneal histopathologic changes after femtosecond laser-assisted MyoRing implantation. In addition, this study was the first study that assessed preoperative corneal cell counts and their changes in the patients that underwent intracorneal implantation [intrastromal corneal ring segments (ICRS) or Myoring].

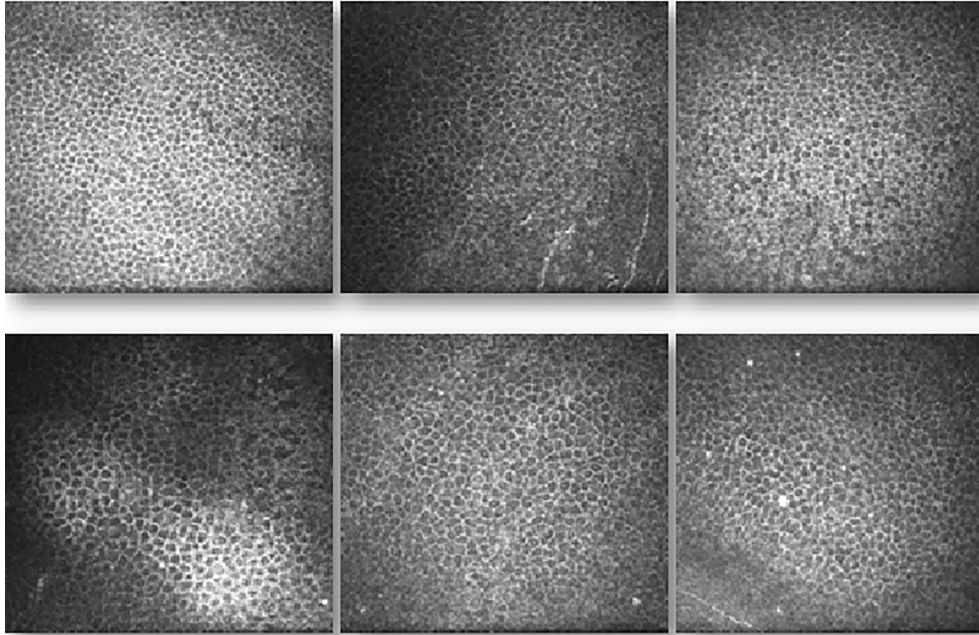


Fig. 1. Confocal microscopic images of corneal epithelium before and after femtosecond laser-assisted MyoRing implantation in keratoconus. Top left: preoperative image, central cornea. Top center: 3 months postoperative image, central cornea. Top right: 6 months postoperative image, central cornea. Bottom left: preoperative image, peripheral cornea. Bottom center: 3 months postoperative image, peripheral cornea. Bottom right: 6 months postoperative image, peripheral cornea.

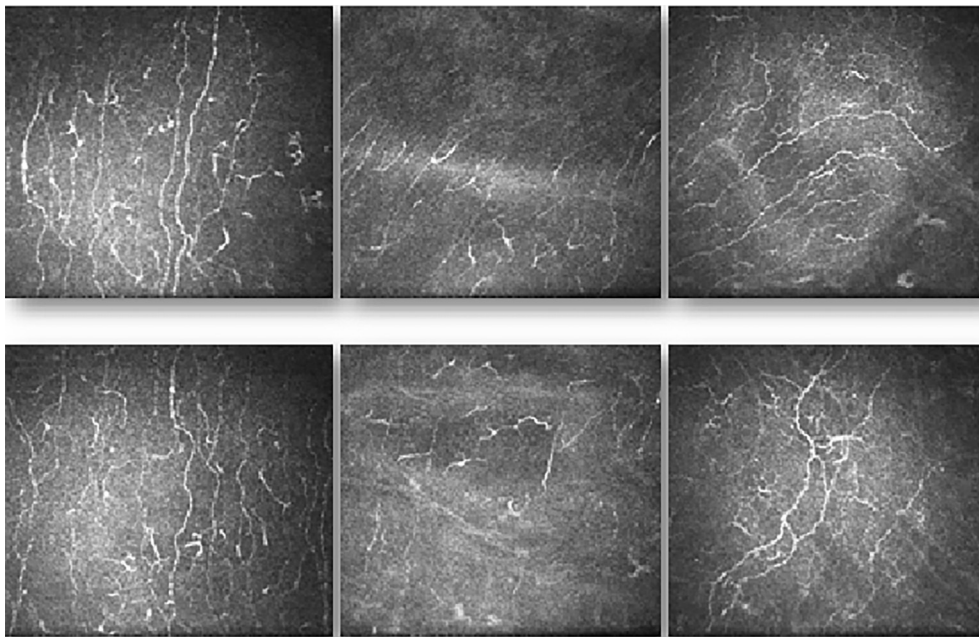


Fig. 2. Confocal microscopic images of corneal subepithelial nerve plexus before and after femtosecond laser-assisted MyoRing implantation in keratoconus. Top left: preoperative image, central cornea. Top center: 3 months postoperative image, central cornea. Top right: 6 months postoperative image, central cornea. Bottom left: preoperative image, peripheral cornea. Bottom center: 3 months postoperative image, peripheral cornea. Bottom right: 6 months postoperative image, peripheral cornea.

The MyoRing [sometimes called intracorneal continuous ring (ICCR)] was used for the patients with keratoconus in several studies with successful visual outcomes.^{5–9} Our study demonstrated additional information, including improved uncorrected visual acuity and spherical equivalent 6 months after the operation, about effectivity of the procedure. The improvement in the uncorrected visual acuity and spherical

equivalent after the procedure was similar to other studies.^{5–9} Thus, the femtosecond laser-assisted MyoRing implantation might be an effective procedure to treat patients with keratoconus.

The decrease in the central epithelial cells at 6 months and the prominence of the nuclei in central and peripheral basal epithelium at 3 months after the surgery were other findings in this study. The qualitative finding (prominent nuclei) was

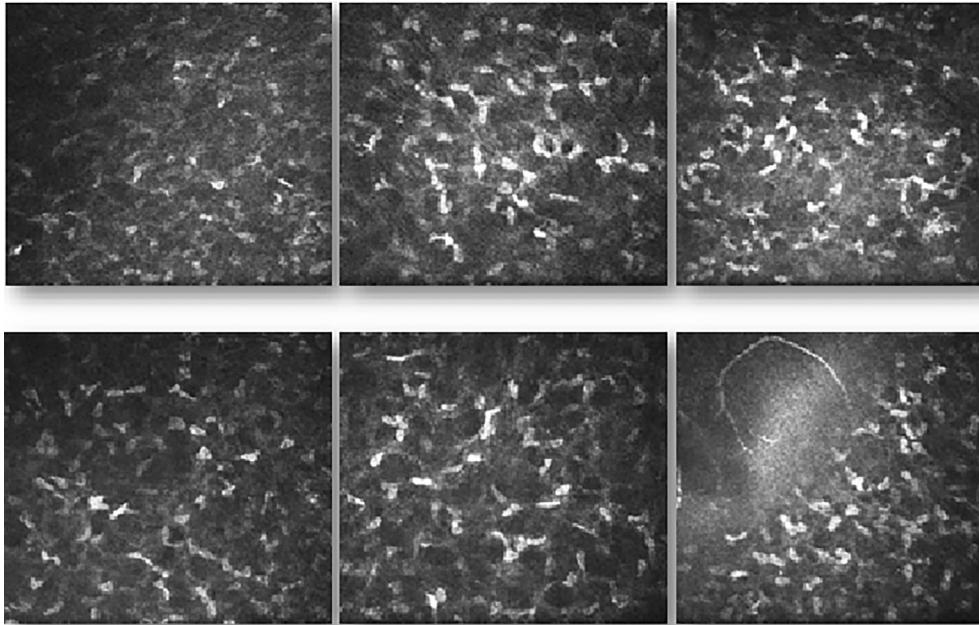


Fig. 3. Confocal microscopic images of anterior corneal stroma before and after femtosecond laser-assisted MyoRing implantation in keratoconus. Top left: preoperative image, central cornea. Top center: 3 months postoperative image, central cornea. Top right: 6 months postoperative image, central cornea. Bottom left: preoperative image, peripheral cornea. Bottom center: 3 months postoperative image, peripheral cornea. Bottom right: 6 months postoperative image, peripheral cornea.

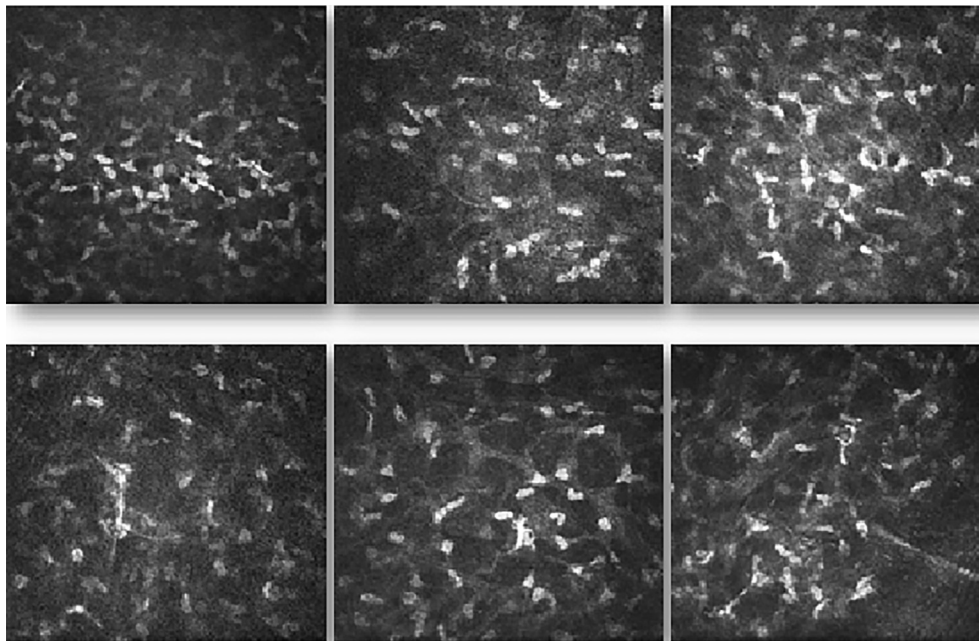


Fig. 4. Confocal microscopic images of corneal mid-stroma before and after femtosecond laser-assisted MyoRing implantation in keratoconus. Top left: preoperative image, central cornea. Top center: 3 months postoperative image, central cornea. Top right: 6 months postoperative image, central cornea. Bottom left: preoperative image, peripheral cornea. Bottom center: 3 months postoperative image, peripheral cornea. Bottom right: 6 months postoperative image, peripheral cornea.

similar to the postoperative peripheral epithelium histopathology in 35% of the cases in the study of Ruckhofer and colleagues on ICRS and low myopic patients.¹² These prominent and highly reflective nuclei were a sign of increased mitotic activity and were not seen in the eyes without any implant.¹² The biologic stress, induced by the

implant, could cause the increased epithelial mitosis.¹² On the other hand, the reason of the decrease in central epithelial count was not clear. The postoperative corneal flattening, tear film irregularity, progression in keratoconus, laser effect, or disturbances in the subepithelial nerve plexus might play a role in these changes.

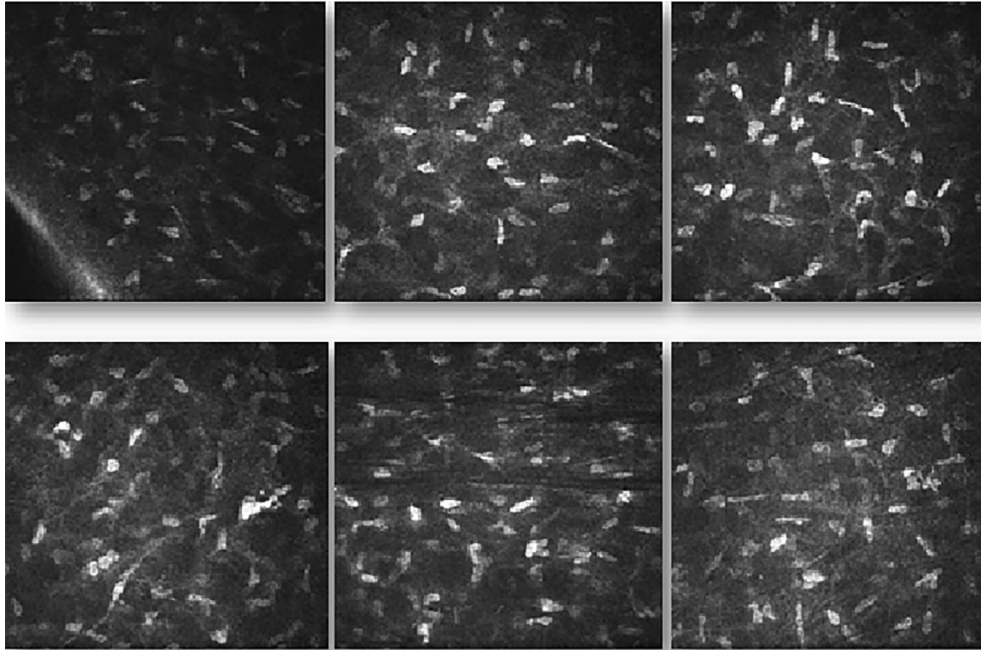


Fig. 5. Confocal microscopic images of posterior corneal stroma before and after femtosecond laser-assisted MyoRing implantation in keratoconus. Top left: preoperative image, central cornea. Top center: 3 months postoperative image, central cornea. Top right: 6 months postoperative image, central cornea. Bottom left: preoperative image, peripheral cornea. Bottom center: 3 months postoperative image, peripheral cornea. Bottom right: 6 months postoperative image, peripheral cornea.

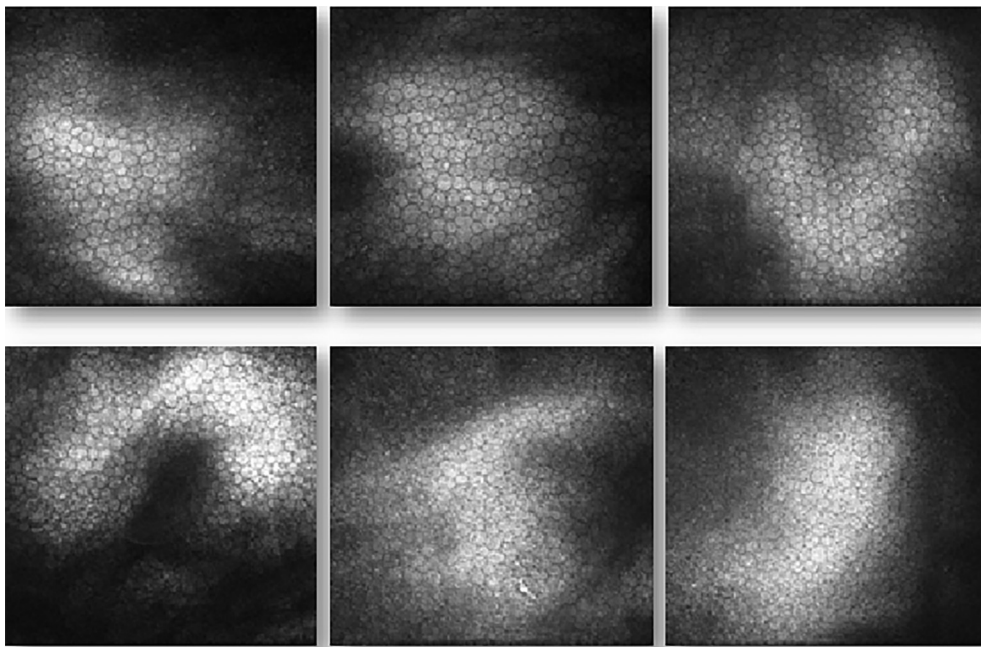


Fig. 6. Confocal microscopic images of corneal endothelium before and after femtosecond laser-assisted MyoRing implantation in keratoconus. Top left: preoperative image, central cornea. Top center: 3 months postoperative image, central cornea. Top right: 6 months postoperative image, central cornea. Bottom left: preoperative image, peripheral cornea. Bottom center: 3 months postoperative image, peripheral cornea. Bottom right: 6 months postoperative image, peripheral cornea.

The postoperative disruption in the subepithelial nerve plexus was another important finding in this study. The nerves were partly recovered in the 6 months follow-up, but were not reached the preoperative thickness. The changes of the susceptible nerves could be expected in the surgeries involving

corneal stroma.^{4,12} In the Ruckhofer and colleagues' study on ICRS in low myopes, the subepithelial nerves showed regular beaded appearance.¹² In the Kymionis and colleagues' study on ICRS in keratoconus, tortuous subbasal nerves were seen in one case.³ Due to resolution of this disturbance in the 6

months follow-up, longer follow-up might show full recovery of the nerves structure.

The decrease in the central and peripheral midstromal and posterior stromal cell counts after the surgery was another finding in our study. The stromal keratocytes also demonstrated postoperative increase in reflectivity. The decrease in the peripheral posterior stromal cell counts was only prominent in 3 months and was not persistent in 6 months follow-up. The increase in the keratocytes reflectivity was also less prominent in the posterior stroma. These changes were in contrast with the normal number of cells in the Ruckhofer and colleagues' study on ICRS and low myopic patients.¹² These disturbances might be due to MyoRing implantation or laser effects. In addition, the progression of the keratoconus could decrease the anterior, mid-, and posterior stromal keratocyte density.^{2,3} Because of the possible asymmetric progression in the keratoconus, the contralateral eye was not a suitable control to evaluate this concept. Larger studies on the keratoconus cases with and without MyoRing could elucidate the findings of our study.

The endothelial cell count and morphologic characteristics were unchanged in 3 and 6 months follow-up. These findings demonstrated that, despite the possible decrease in the endothelial cell density in keratoconus,² similar to the ICRS,^{4,12} MyoRing implantation might have no harmful effect on the corneal endothelium.

The amorphous depositions seen in the study of Ruckhofer and colleagues¹² on ICRS were not seen in the present study. These depositions consisted of lipid secreted by keratocytes as a non-specific response to stress.¹² The absence of these depositions in the corneas that underwent MyoRing implantation might indicate less biologic stress on keratocytes and less abnormal secretion.

In the present study, confocal microscopic changes after MyoRing implantation showed some similarities with the changes after corneal collagen cross-linking.^{13–15} After both procedures, early loss of subepithelial nerve plexus, subsequent regeneration of nerve plexus, and early decrease in stromal keratocyte density were seen.^{13–15} These two procedures halt the progression of keratoconus with different mechanisms, but the result on cornea may be similar. In this study, all the patients were between 20 and 29 years old and had stable keratomeries after the surgery. The risk of keratoconus progression in this age range was high. Thus, although follow-up time was short to detect progression, MyoRing implantation might decrease the progression of keratoconus. Comparative studies with longer follow-up should be performed to detect effectivity of each procedure.

The limitations of our study were low sample size, relatively short follow-up time, and the absence of control group with keratoconus and without MyoRing implantation, or the control group that underwent implantation of other rings. The alterations seen in different layers of cornea may be resolved in longer follow-up. In addition, this study was a preliminary study and the future studies with control groups can differentiate that the histopathologic features are specific for MyoRing implantation or sign of keratoconus.

In conclusion, postoperative confocal microscopy in the patients that underwent the femtosecond laser-assisted MyoRing implantation demonstrated some findings that were similar to the findings reported in ICRS, such as: decreased central epithelial cell counts, highly reflective nuclei in the basal epithelium, transient disruption in the subepithelial nerve plexus, and normal endothelial cell count and morphology. In addition, decrease in the central and peripheral midstromal, transient decrease in posterior stromal cell counts, and absence of amorphous depositions were in contrast with the findings reported in ICRS. These differences might be due to MyoRing or laser effects. Further studies are required to evaluate these differences.

References

1. Cavanagh HD, Petroll WM, Jester JV. Confocal microscopy: uses in measurement of cellular structure and function. *Prog Retin Eye Res.* 1995; 14:527–565.
2. Mocan MC, Yilmaz PT, Irkeç M, Orhan M. In vivo confocal microscopy for the evaluation of corneal microstructure in keratoconus. *Curr Eye Res.* 2008 Nov;33(11):933–939.
3. Ozgurhan EB, Kara N, Yildirim A, Bozkurt E, Uslu H, Demirok A. Evaluation of corneal microstructure in keratoconus: a confocal microscopy study. *Am J Ophthalmol.* 2013;156(5):885–893.
4. Kymionis GD, Siganos CS, Tsiklis NS, et al. Long-term follow-up of Intacs in keratoconus. *Am J Ophthalmol.* 2007;143(2):236–244.
5. Jabbarvand M, Salamatrad A, Hashemian H, Khodaparast M. Continuous corneal intrastromal ring implantation for treatment of keratoconus in an Iranian population. *Am J Ophthalmol.* 2013;155(5):837–842.
6. Daxer A, Mahmoud H, Venkateswaran RS. Intracorneal continuous ring implantation for keratoconus: one-year follow-up. *J Cataract Refract Surg.* 2010;36(8):1296–1302.
7. Jabbarvand M, Salamatrad A, Hashemian H, Mazloumi M, Khodaparast M. Continuous intracorneal ring implantation for keratoconus using a femtosecond laser. *J Cataract Refract Surg.* 2013;39(7):1081–1087.
8. Jabbarvand M, Hashemi H, Mohammadpour M, Khojasteh H, Khodaparast M, Hashemian H. Implantation of a complete intrastromal corneal ring at 2 different stromal depths in keratoconus. *Cornea.* 2014; 33(2):141–144.
9. Behrouz MJ, Hashemian H, Khodaparast M, Rad AS, Shadravan M. Intacs followed by MyoRing implantation in severe keratoconus. *J Refract Surg.* 2013;29(5):364–366.
10. Jabbarvand M, Hashemian M, Hashemian H, Bazvand F, Khodaparast M. Femtosecond laser-assisted MyoRing implantation in postoperative LASIK ectasia. *J Refract Surg.* 2014;30(7):462–466.
11. Alio JL, Piñero DP, Daxer A. Clinical outcomes after complete ring implantation in corneal ectasia using the femtosecond technology: a pilot study. *Ophthalmology.* 2011;118(7):1282–1290.
12. Ruckhofer J, Böhnke M, Alzner E, Grabner G. Confocal microscopy after implantation of intrastromal corneal ring segments. *Ophthalmology.* 2000; 107(12):2144–2151.
13. Sharma N, Suri K, Sehra SV, et al. Collagen cross-linking in keratoconus in Asian eyes: visual, refractive and confocal microscopy outcomes in a prospective randomized controlled trial. *Int Ophthalmol.* 2015 Feb 24 [Epub ahead of print].
14. Aminifard MN, Khallaghi H, Mohammadi M, Jafarzadeh R. Comparison of corneal keratocytes before and after corneal collagen cross-linking in keratoconus patients. *Int Ophthalmol.* 2015 Feb 4 [Epub ahead of print].
15. Jordan C, Patel DV, Abeysekera N, McGhee CN. In vivo confocal microscopy analyses of corneal microstructural changes in a prospective study of collagen cross-linking in keratoconus. *Ophthalmology.* 2014 Feb; 121(2):469–474.